Case Report

DOI: 10.17354/ijss/2015/290

Large Ovarian Tumor: A Case Report

Swati Parmanand Agrawal[1], S K Rath[2], G S Aher[3], U G Gavali[4]

[1]Postgraduate Student, Department of Obstetrics and Gynaecology, PDVVPF's Medical College and Hospital, Vilad Ghat, Ahmednagar, Maharashtra, India, [2]Professor and Head, Department of Obstetrics and Gynaecology, PDVVPF's Medical College and Hospital, Vilad Ghat, Ahmednagar, Maharashtra, India, [3]Professor, Department of Obstetrics and Gynaecology, PDVVPF's Medical College and Hospital, Vilad Ghat, Ahmednagar, Maharashtra, India, [4]Assistant Professor, Department of Obstetrics and Gynaecology, PDVVPF's Medical College and Hospital, Vilad Ghat, Ahmednagar, Maharashtra, India

Abstract

Although ovarian masses are commonly found in gynecology, the patient reports for consultation only when it becomes too large in the absence of any other symptom. This could be partially attributed to complacence and partly, to the unaffordability of surgical treatment on the part of the patient. Presentation at advanced stages creates a psycho-physio-biological impact on the patient. Surgical removal of these tumors leads to good post-operative recovery and survival rates. Herein, we present a case where the patient neglected initial symptoms and presented with a huge abdominal swelling when it caused immense discomfort. This tumor was surgically removed and the post-operative period was uneventful.

Key words: Benign neoplasm, Cancer of ovary, Ovarian neoplasm, Serous cystadenoma

INTRODUCTION

In the current era of medical practice, giant ovarian tumors have become rare due to early discovery on routine check-ups. Depending on the age of the patient, size and histopathology of the cyst, management is decided.[1] Detection of ovarian tumors causes panic amongst patients because of the fear of malignancy leading to psycho-somatic stress disorders. In addition to this, large size of these tumors causes mechanical pressure symptoms on the gastrointestinal, respiratory and urinary tract. Hence, a comprehensive approach to the management of such tumors is essential to negate the secondary effects along with treatment of the primary ovarian tumour.[2]

We report a case of a post-menopausal woman with a history of progressive abdominal swelling over a period of 6 months along with radiological reports suggestive of a large tumor arising from the right ovary.

Access this article online

IJSS

www.ijss-sn.com

Month of Submission : 04-2015
Month of Peer Review : 05-2015
Month of Acceptance : 06-2015
Month of Publishing : 06-2015

CASE REPORT

A 65-year-old Indian housewife, P5L5, married since 40 years, postmenopausal since 20 years, weighing 65 kg, came to our outpatient department in March 2015 with complaints of a gradually increasing huge abdominal swelling which she had noticed 6 months back. The swelling was accompanied with dull aching pain in the lower back. She also complained of breathlessness, insidious in onset, which worsened on recumbency leading to decreased sleep. She had the sensation of fullness of abdomen, leading to decreased appetite. She also complained of incomplete voiding of urine and usually remained constipated. There was a history of generalized weakness. There was no history of vomiting or other gastrointestinal disturbances, colicky pain or fainting attacks. The patient had no history of the previous medial or surgical illnesses. There was no family history of malignancies. Despite all these symptoms, the patient did not seek for medical attention earlier owing to low socioeconomic status. It was only when she started having decreased appetite that her relatives brought her to the hospital.

The patient was found to be averagely built, weighing 65 kg. Physical examination revealed pale skin; the patient was afebrile with a pulse rate of 78 b/min, blood pressure of 128/66 mm Hg and respiratory rate of 22 cycles/min. Her abdomen was distended, and tense with an abdominal girth

Corresponding Author: Swati Parmanand Agrawal, PG Girls hostel, Room No 52, PDVVPF's Medical College Campus, Ahmednagar, Maharashtra, India. Phone: +91-7738393939. E-mail: doctor.swatiagrawal@gmail.com

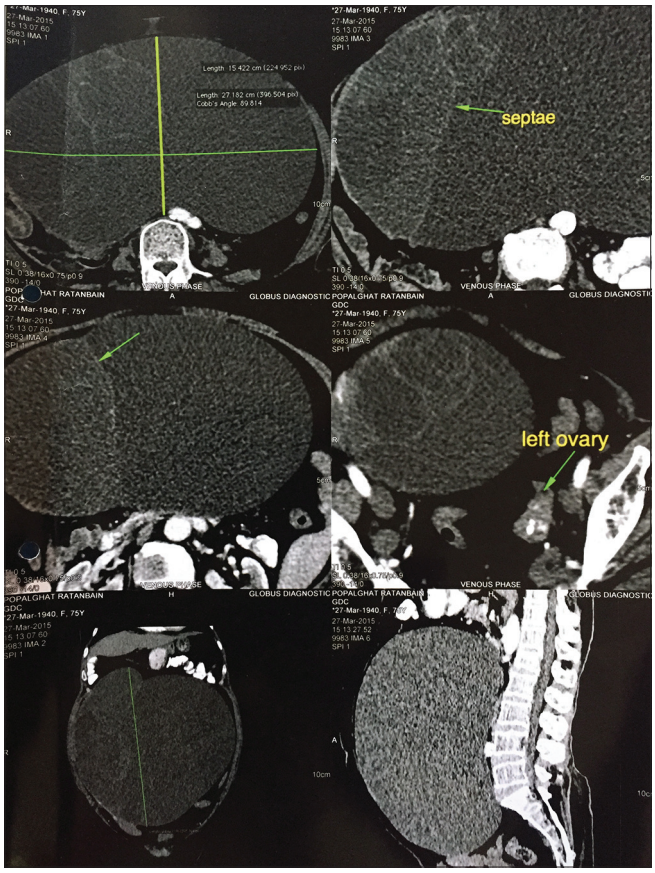

Figure 1: Multidetector computerized tomographic images of the abdomen and pelvis (plain + Contrast) showing large cystic lesion with thin internal enhancing septations measuring approximately 15.4 cm × 27.1 cm × 27.5 cm

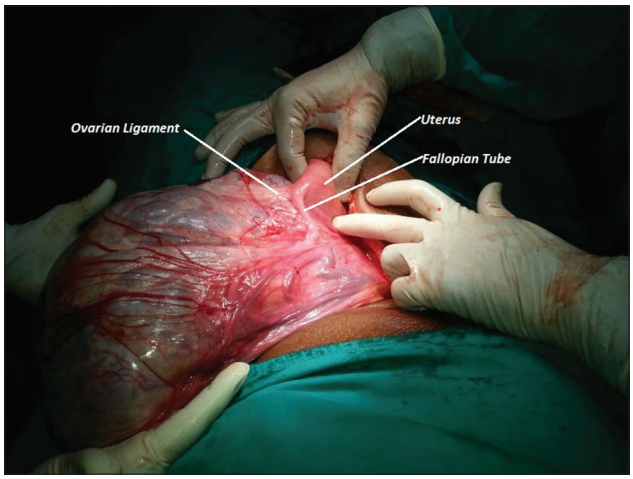

Figure 2: Intra-operative image of the specimen showing an atrophied uterus with stretched out ovarian ligament

of 125 cm with a dull note on percussion and presence of superficial dilated veins. Plain radiograph of the chest (P-A view) was within normal limits. CA-125 was 31.3 IU/ml.

An ultrasound done suggested a large well-defined cystic lesion of about 32 cm × 35 cm × 28 cm arising from pelvis,

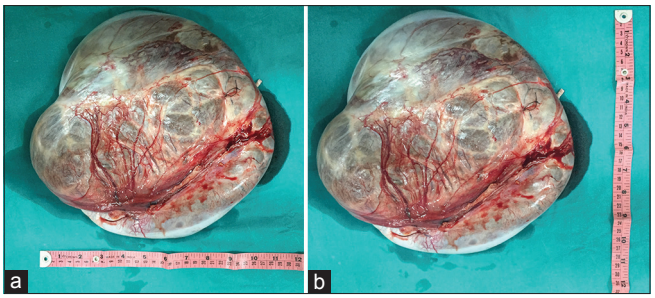

Figure 3: (a and b) Post-operative specimen of right ovary measuring 28 cm × 27 cm × 15 cm after controlled drainage of 4 l of fluid

reaching up to the epigastrium, displacing liver and spleen supero-laterally, and kidneys posteriorly and bowel loops peripherally. On Doppler, septa did not show vascularity. Peripheral low impedance with continuous vascularity was present. Uterus was seen separately. Ovaries were not seen separately.

Multiple detector computed tomography scan of abdomen and pelvis (plain + contrast) (Figure 1) was suggestive of a large cystic lesion with thin internal enhancing septations in abdomen and pelvis measuring approximately 25.4 cm × 27.1 cm × 27.5 cm. The right ovary was not seen separately from this lesion. Superiorly the lesion reached up to subhepatic region. Displacement of small bowel loops with compression of *inferior vena cava* (IVC) and left renal vein was seen. Left ovary measuring 32 mm × 26 mm with internal calcifications seen. CA-125 was 31.3 IU/ml.

Exploratory laparotomy was done. A huge multicystic tumor arising from the right ovary was seen occupying the abdomen, from the pelvis up to the diaphragm. The cyst was multiloculated, and tumor was seen displacing spleen, liver and bowel loops. The extent of the tumor was identified (Figure 2). Gross evidence of malignancy was ruled out. Decompression of the cyst was done by controlled drainage of 4 liters of fluid intra-operatively after which the tumor measuring 29 cm × 28 15 cm and weighing 7 kg was removed en bloc. Total abdominal hysterectomy along with bilateral salpingo-oophorectomy and partial omentectomy was done. Lymph nodes were not involved. The left ovary was seen measuring 3 cm × 2 cm. An abdominal drain was placed *in situ* for 3 days (Figure 3). The post-operative period was uneventful. Patient weighed 55 kg on day 7 post operation. Histopathological examination revealed serous cystadenoma of the ovary.

DISCUSSION

In a women's lifetime, ovarian tumors can present at any age. The size of an ovarian cyst can range from a small ping pong ball to a mass larger than a full term pregnancy.

The definition of large ovarian cysts varies from those measuring more than 10 cm in diameter in preoperative scans to those reaching above the umbilicus.[3] On the basis of cell of origin, ovarian neoplasms are divided into epithelial, stromal and germ cell neoplasms. Ovarian epithelial tumors constitute about half of all the ovarian tumors. Of these, 40% constitute benign tumors and 86% constitute malignant tumors. Benign serous tumors comprise 25% benign ovarian neoplasms and 58% ovarian serous tumors. Depending on the age, 70% serous tumors are benign, about 10% have borderline malignant potential and about 20% are malignant. Serous tumors are bilateral in 10% cases.[4] The epithelium of cysts is cylindrical and mono- or multi-stratified. Cuboidal epithelium occurs due to the pressure inside the cyst. These cells have clear cytoplasm with the hyperchromatic nucleus at the base. Cancer antigen (CA)-125 helps in identifying and following malignant epithelial tumors of the ovary.[5] Cystadenomas are thin walled cysts, containing serum like fluid. Some papillary projections might appear on the internal surface of the cyst. Usually, serous cystadenomas are multilocular.[6] In approximately 25% cases of ovarian serous cystadenoma, some evidence of estrogenic activity has been found. 44% cases of serous cystadenoma present with postmenopausal bleeding and 73% have an abnormally high cornification index.[7] Tumors arise from within the pelvis, and patients commonly seek medical aid at advanced stages.[8] In the year 1922, Spohn reported a large ovarian cyst weighing 148.6 kg which are possibly the largest.[9] Many intra-operative complications occur during surgical removal of large ovarian tumors. Crossen and Crossen reported splanchnic dilatation and venous pooling after the sudden removal of large intra-abdominal masses.[10] Howard *et al.* showed that hypotension can occur due to decreased venous return resulting from obstructed IVCl.[11] Poulias and Prombonas showed that sudden re-expansion of a chronically collapsed lung, which occurred due compression by the elevated abdomen might result in pulmonary oedema.[12]

Various imaging modalities are used in making a diagnosis of ovarian tumors. Ultrasonography is used to diagnose and infer about possible malignancy. Computed tomography and magnetic resonance imaging scans can be used for larger masses and metastatic involvement. Serial measurements of the biomarker CA-125 can be of great help.[13] Surgery is inevitable for large tumors even if benign. Surgical management includes excision. The contralateral ovary should also be examined. Hunter *et al.* reported that rupture of the cyst capsule and greater dissemination can be prevented by gradual decompression. Repeated paracentesis have been associated with tumor seeding of the peritoneal cavity, bleeding, infection, and increased adhesions resulting in difficult cyst removal.[14]

CONCLUSION

In developing countries, patients having ovarian tumors seek medical help usually during advanced stages of the disease. Fortunately in our case, the tumor was removed successfully without any dissemination despite a delay in diagnosis. Reporting such cases with unusual presentations helps to increase the suspicion of its possibility and avoid any misdiagnosis or improper treatment and its complications.

REFERENCES

1. Kamel RM. A massive ovarian mucinous cystadenoma: A case report. Reprod Biol Endocrinol 2010;8:24.
2. Sebastian A, Thomas A, Regi A. Giant benign mucinous cystadenoma: A case report. Open J Obstet Gynecol 2012;2:220-2.
3. Singla DK, Kansal R, Bansal I, Thami G, Agrawal N. Case report: Laparoscopic management of a giant ovarian cyst. Asian Pac J Health Sci 2014;1:43-6.
4. Sujatha VV, Babu SC. Giant ovarian serous cystadenoma in a postmenopausal woman: A case report. Cases J 2009;2:7875.
5. de Lima SH, Dos Santos VM, Darma, Vitorino Modestodesto FR. A 57-year-old Brazilian woman with a giant mucinous cystadenocarcinoma of the ovary: A case report. J Med Case Rep 2014;8:82.
6. Papaziogas B, Souparis A, Grigoriou M, Tsiaousis P, Kogia E, Panagiotopoulou K, A rare triple coexistence of a collision tumor, a benign mature cystic teratoma and a hemorrhagic follicular cyst of the ovaries. Internet J Surg 2007;14:1.
7. Fox H. Estrogenic activity of the serous cystadenoma of the ovary. Cancer 1965;18:1041-7.
8. Agah J, Esfehani RJ, Kamalimanesh B, Abdizadeh MF, Jalilian AR. Mismanagement of a huge ovarian serous cystadenoma in a young girl; A case report. J Midwifery Reprod Health 2015;3:315-7.
9. Spohn AE. Multicystic ovarian tumour weighing 328 lb. Tex State J Med 1905-1906;1:273-4.
10. Crossen HS, Crossen RJ. Operative Gynecology. 6th ed. St. Louis: Mosby Co.; 1946.
11. Howard BK, Goodson JH, Mengert WF. Supine hypotensive syndrome in late pregnancy. Obstet Gynecol 1953;1:371-7.
12. Poulias GE, Prombonas E. Massive unilateral pulmonary oedema as a rapid re-expansion sequel (the post-expansion syndrome). Report of a case and review of the literature. Scand J Thorac Cardiovasc Surg 1974;8:67-9.
13. Kotis A, Karatapanis S, Papamargaritis V, Lisgos P, Sisamotos G. A case of a large ovarian tumour. BMJ Case Rep 2011;2011:.
14. Hunter DJS. Management of a massive ovarian cyst. Obstet Gynecol l980; 56: 254-255.

How to cite this article: Agrawal SP, Rath SK, Aher GS, Gavali UG. Large Ovarian Tumor: A Case Report. Int J Sci Stud 2015;3(3):143-145.

Source of Support: Nil, **Conflict of Interest:** None declared.