

# Effectiveness and Complication of Subconjunctival Application of Mitomycin C in Pterygium Surgery: A Prospective Study

Sudhir Kumar<sup>1</sup>, Ravi Ranjan<sup>2</sup>, Sriti Sinha<sup>3</sup>

<sup>1</sup>Assistant Professor, Department of Ophthalmology, Nalanda Medical College, Patna, Bihar, India, <sup>2</sup>Professor, Department of Ophthalmology, UP Rural Institute of Medical Sciences and Research, Saifai, Etawah, Uttar Pradesh, India, <sup>3</sup>Medical Officer, District Hospital, Etawah, Uttar Pradesh, India

## Abstract

**Introduction:** Pterygium excision surgery poses distinct problem like high post-operative recurrence. Many surgical approaches have been tried to decrease recurrences. Currently, intraoperative Mitomycin C (MMC) application is used as adjunct apart from the standard limbal-conjunctival autograft.

**Purpose:** To study the efficiency and MMC related complications when MMC was applied on the under surface of the conjunctiva of dissected pterygium.

**Materials and Methods:** This is a non-comparing prospective interventional case series of 38 patients. The patients underwent standard pterygium excision with intraoperative MMC application on the under surface of dissected pterygium conjunctiva and followed for 1-year.

**Result:** Out of 38 patients no one had a recurrence of pterygium. Only one patient has post-operative increased corneal astigmatism ( $P > 0.05$ ).

**Conclusion:** Intraoperative application of MMC in the strength of 0.2 mg/ml for 90 s is effective in preventing the recurrence of pterygium without any post-operative major complication.

**Key words:** Astigmatism, Conjunctiva, Mitomycin C, Recurrent pterygium, Streptomyces

## INTRODUCTION

Pterygium is a common ocular disorder treated by surgical excision. It is more prevalent in the equatorial region. Ultraviolet B-ray is the most important environmental factor. P53 and human papilloma virus and deficiency of limbal stem cell may be other factors causing pterygium. They may cause gene mutation resulting in abnormal expression of the conjunctival epithelium.

One of the major problems with pterygium surgery is a high rate of recurrence. It ranges from 30% to

89%.<sup>1,2</sup> Various methods have been developed to tackle this problem. Intraoperative or post-operative use of Mitomycin C (MMC) is one of the adjunctive treatments that can significantly reduce the rate of recurrence.<sup>3,4</sup> MMC is an antibiotic isolated from *Streptomyces caespitosus*. It is an alkylating agent. Pathological changes in pterygium occur in conjunctival epithelium.<sup>2</sup>

The aim of this study was to evaluate efficacy and MMC related complications when MMC was applied on the under surface of conjunctiva of dissected pterygium.

## MATERIALS AND METHODS

The study is a prospective non-comparative interventional case series. A total of 38 consecutive patients were included through the period of 3 years. Patients with dry eye, inflamed eye, and immune disorder were excluded. After taking, informed consent patients under went

Access this article online

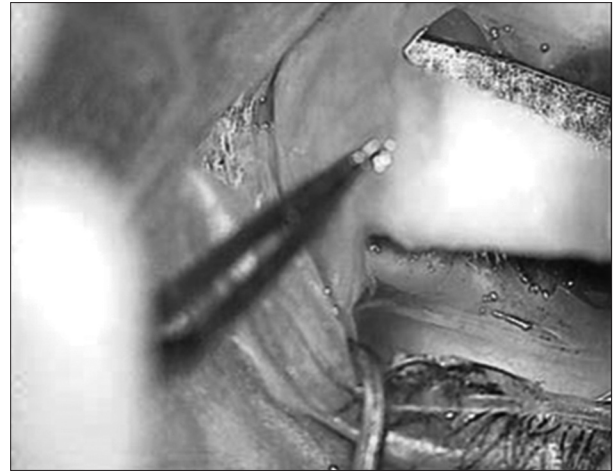


www.ijss-sn.com

**Month of Submission :** 04-2016  
**Month of Peer Review :** 05-2016  
**Month of Acceptance :** 05-2016  
**Month of Publishing :** 06-2016

**Corresponding Author:** Dr. Sudhir Kumar, Department of Ophthalmology, Nalanda Medical College, Patna, Bihar, India.  
Phone: +91-9431074060. E-mail: sudhirkumar10000@gmail.com

standard pterygium excision. Overlying conjunctiva was separated from underlying tissue and flesh of the pterygium was excised. Tip of the conjunctiva was sacrificed. Intraoperative MMC of 0.2 mg/ml strength for 90 s was applied on the under surface of dissected pterygium conjunctiva while protecting the sclera from MMC exposure by the use of spatula over the sclera during MMC application (Figure 1). Then, it was washed thoroughly. Freely mobile conjunctiva was anchored. The patients were followed up on 1<sup>st</sup> week, 4<sup>th</sup> week, 3<sup>rd</sup> month and after 1-year. Patients were looked for bleaching, thinning, dellen, ulceration, persistent epithelial defect, visual acuity, and recurrence. Recurrence was defined as fibrotic vascularization tissue crossing through the limbus.



**Figure 1: Method of application of Mitomycin C**

## RESULT

An average duration of surgery was 13 min. Pre-operative best-corrected vision was <6/60 in 22 patients and better than 6/36 in 16 patients. 26 patients had a cataract. Age ranged from 22 to 69 years. Male-female ratio was 3:1. No epithelial defect was present by the 7<sup>th</sup> day. No case of dellen, thinning, ulceration or ble-aching was seen. Visual acuity increased in all the patients after surgery with a decrease in astigmatism. Astigmatism increased in one eye of a patient who was operated for recurrence of pterygium in his both the eyes after 3 months.

## DISCUSSION

The recurrence rate for bare sclera excision alone is unacceptably high, 30-80%.<sup>1,2</sup> Singh *et al.* introduced the use of MMC as an adjunct to pterygium surgery to ophthalmology in 1988. Although MMC significantly reduced the rate of recurrence to a range of <10%, severe complications such as ocular surface disorder, corneal perforation, scleral calcification, corectopia, iritis, cataract, photophobia, pain and glaucoma were reported by Singh *et al.*<sup>3,5</sup> These complications were mostly related to uncontrolled use of high and cumulative dose of MMC and its application over sclera.<sup>6,7</sup> Despite the fact that early complications can be avoided and controlled, one cannot implicate the outcome of MMC application years after its use (remember beta radiation). The recurrence rate in conjunctival autograft varied from 2% to 39%<sup>1</sup> which is comparable to MMC use.<sup>8</sup> Inter surgeon variation contributed to recurrence rate reported in conjunctival and amniotic membrane graft. We applied MMC on the under surface of conjunctiva while protecting the sclera from MMC exposure assuming that we should target proliferating subconjunctival tissue rather than innocent sclera. All the recurrences occur during the first 6 months

of surgery when MMC is not applied.<sup>3</sup> MMC is effective even if applied 0.2 mg/ml for 30 s.<sup>9</sup> Based on this, we applied MMC in the strength of 0.2 mg/ml for 90 s.

In our study, no recurrence was seen during 36 months of follow-up. No complications related to MMC use were seen. Average surgical time was only 13 min in this study. Visual acuity increased in all cases following pterygium surgery due to decreased astigmatism. 26 patients underwent cataract surgery 4 weeks after pterygium surgery. There was an increase in astigmatism in one eye of case number one 2 weeks after pterygium excision, may be due to increase in fibrosis but remained stable in following visits. The technique is fast and simple, while conjunctival or amniotic membrane graft is not only time consuming but requires special skill.

## CONCLUSION

Application of MMC in the strength of 0.2 mg/ml for 90 s is effective in preventing the recurrence and causes no harm to the vital parts of the eye.

## REFERENCES

1. Ang LP, Chua JL, Tan DT. Current concepts and techniques in pterygium treatment. *Curr Opin Ophthalmol* 2007;18:308-13.
2. Singh G, Wilson MR, Foster CS. Mitomycin eye drops as treatment for pterygium. *Ophthalmology* 1988;95:813-21.
3. Raiskup F, Solomon A, Landau D, Ilsar M, Frucht-Pery J. Mitomycin C for pterygium: Long term evaluation. *Br J Ophthalmol* 2004;88:1425-8.
4. Gupta VP, Saxena T. Comparison of single-drop mitomycin C regime with other mitomycin C regimes in pterygium surgery. *Indian J Ophthalmol* 2003;51:59-65.
5. Singh G, Wilson MR, Foster CS. Long-term follow-up study of mitomycin eye drops as adjunctive treatment of pterygia and its comparison with conjunctival autograft transplantation. *Cornea* 1990;9:331-4.
6. Safianik B, Ben-Zion I, Garzozzi HJ. Serious corneoscleral complications after pterygium excision with mitomycin C. *Br J Ophthalmol*

- 2002;86:357-8.
7. Frucht-Pery J, Ilsar M. The use of low-dose mitomycin C for prevention of recurrent pterygium. *Ophthalmology* 1994;101:759-62.
  8. Sharma A, Gupta A, Ram J, Gupta A. Low-dose intraoperative mitomycin-C versus conjunctival autograft in primary pterygium surgery: Long term follow-up. *Ophthalmic Surg Lasers* 2000;31:301-7.
  9. Cheng HC, Tseng SH, Kao PL, Chen FK. Low-dose intraoperative mitomycin C as chemoadjuvant for pterygium surgery. *Cornea* 2001;20:24-9.

**How to cite this article:** Kumar S, Ranjan R, Sinha S. Effectiveness and Complication of Subconjunctival Application of Mitomycin C in Pterygium Surgery: A Prospective Study. *Int J Sci Stud* 2016;4(3):6-8.

**Source of Support:** Nil, **Conflict of Interest:** None declared.