

# Visual Outcome and Complications of YAG Laser Therapy for Posterior Capsular Opacification Following Cataract Surgery

G S Gopinath<sup>1</sup>, K Satish<sup>1</sup>, Nirati Srivastava<sup>2</sup>, Savita Patil<sup>2</sup>, Raheela Afshan<sup>2</sup>

<sup>1</sup>Associate Professor, Department of Ophthalmology, Mysore Medical College and Research Institute, Mysore, Karnataka, India,

<sup>2</sup>Post-graduate Student, Department of Ophthalmology, Mysore Medical College and Research Institute, Mysore, Karnataka, India

## Abstract

**Introduction:** Cataract is one of the most leading cause of curable blindness all over the world. In the developing world, most popular method of cataract operation is extracapsular cataract extraction with posterior chamber intraocular lens (IOL) (PCIOL). Posterior capsule opacification (PCO) is caused by a proliferation of lens epithelial cells which causes fibrotic changes and wrinkling of the posterior capsule. PCO is one of the common complications of extracapsular cataract extraction surgery and develops usually within 2 years after cataract extraction in the majority of the cases. Neodymium yttrium aluminium garnet (Nd: YAG) laser posterior capsulotomy is a good technique for making an opening in the opacified posterior capsule.

**Materials and Methods:** Retrospective analysis of all patients who underwent cataract surgery and presented with visually significant PCO were included in the study.

**Results:** 50 eyes of 50 patients that had undergone extracapsular cataract extraction underwent Nd: YAG laser posterior capsulotomy, out of which majority was Elschnig pearl type of PCO. Complications like inadvertent corneal burn, IOL pitting, cystoids macular edema, intraocular pressure spikes and floaters were seen.

**Conclusion:** Nd: YAG laser capsulotomy is a safe and effective method to treat PCO.

**Key words:** Cataract surgery, Neodymium-doped yttrium aluminium garnet laser, Capsular opacification

## INTRODUCTION

A cataract is one of the most leading cause of curable blindness all over world. In the developing world, most popular method of cataract surgery is extracapsular cataract extraction with posterior chamber intraocular lens (IOL) (PCIOL). An estimated 18-50% late capsular opacification has been reported after extracapsular cataract extraction. Sir Harold Ridley documented this complication in his first case. Posterior capsule opacification (PCO) is a common long-term complication of cataract surgery that causes decreased vision, glare and other symptoms similar to that

of the original cataract.<sup>1</sup> PCO is caused by a proliferation of lens epithelial cells which causes fibrotic changes and wrinkling of the posterior capsule.<sup>2,3</sup> PCO is one of the common complications of extracapsular cataract extraction surgery and develops within 2 years after cataract extraction in 50% of the cases.<sup>4,7</sup> It causes a reduction in visual acuity (VA) and contrast sensitivity by obscuring the view or by scattering the light that is perceived by patients as glare.<sup>4,5,8</sup> It also decreases the field of view during therapeutic and diagnostic procedures and also causes unocular diplopia.<sup>9</sup> In younger age group, it develops earlier but in elderly, its incidence declines.<sup>10</sup>

The development of the neodymium yttrium aluminium garnet (Nd: YAG) laser as an ophthalmic instrument and its application in discussion of the posterior capsule coincided with the conversion from intracapsular to extra capsular surgical techniques in cataract surgery. Before the introduction of the Nd: YAG laser, only surgical cutting or polishing of the posterior capsule could

Access this article online



www.ijss-sn.com

**Month of Submission :** 04-2015  
**Month of Peer Review :** 05-2015  
**Month of Acceptance :** 05-2015  
**Month of Publishing :** 06-2015

**Corresponding Author:** Dr. G S Gopinath, Department of Ophthalmology, K R Hospital, Mysore - 570 001, Karnataka, India.  
 Phone: +91-9448101419. E-mail: gsgopinath61@gmail.com

manage opacification of the posterior capsule following extracapsular cataract extraction. Nd: YAG laser posterior capsulotomy introduced a technique for closed-eye, effective, and relatively safe opening of the opacified posterior capsule, and laser capsulotomy rapidly became the standard of care.

It should be noted that capsular opening created with Nd: YAG laser tends to increase in size with smoothing of edges from capsular tag retraction and may become circular.<sup>10,11</sup>

Complications of Nd: YAG laser posterior capsulotomy causing decreased vision are uncommon but include elevated intraocular pressure, cystoid macular edema (CME), retinal detachment, IOL damage, endophthalmitis, iritis, vitritis, macular holes, and corneal edema.

This prompted us to conduct this study so as to observe, document and analyse such events.

## MATERIAL AND METHODS

### Type of Study

Retrospective analysis of the patients with PCO who underwent Nd:YAG capsulotomy during the study period.

### Source of Data

All patients who had visually significant PCO and underwent Nd:YAG laser capsulotomy following cataract surgery during the study period in the Department of Ophthalmology, K. R. Hospital, Mysore.

### Sampling Method

Convenient sampling.

### Inclusion Criteria

All patients who were previously operated for cataract by small incision cataract surgery (SICS)/phacoemulsification with visually significant PCO like Elschnig pearls and fibrous PCO and presented to Department of Ophthalmology, K. R. Hospital, Mysore from October 2012 to 2014 were included in the study.

### Exclusion Criteria

Patients with thick PCO who needed surgical intervention were excluded from the study. Patients with ocular comorbidities like corneal opacities, retinal or optic nerve pathologies, and high myopia were also excluded from the study.

### Methodology

The extent of PCO needing laser capsulotomy was determined clinically and by its functional impairment and

symptoms of patients. After a thorough history, all patients were evaluated clinically. After recording VA (Snellen's), slit lamp examination, fundoscopy, and applanation tonometry (Goldman's) were carried out. The type and extent of PCO were carefully noted after pupil dilation. NIDEK YC-1600 Ophthalmic Nd:YAG laser was used for capsulotomy. The Helium-Neon laser beam was used for accurate aiming and focusing of the invisible therapeutic beam. The parameters of laser system were adjusted accordingly to the needs of patients depending upon the type and extent of PCO. As capsulotomy was done for the optical purpose, its size was restricted to 2-3 mm in diameter. Post laser evaluation was carried out including slit lamp examination and intraocular pressure (IOP) examination. Topical fluorometholone (FML eye drops) was advised four times daily. If IOP was found raised, then topical brimonidine was advised. After control of IOP and inflammation, post laser best corrected VA (BCVA) was recorded after 1-week.

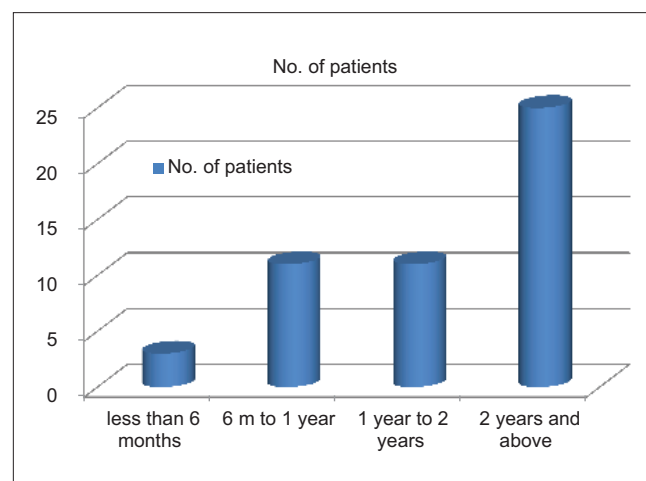
## RESULTS

We used the Nd:YAG laser to perform posterior capsulotomies on 50 eyes of 50 patients that had undergone extracapsular cataract extraction.

31 (62%) of our cases were male and 19 (38%) were female. The average age of these patients was 52 years, the range being from 18 years to 83 years (Figure 1).

The posterior capsulotomy was performed on an average of 23 months after cataract extraction (Figure 2).

Out of 50 patients, 94% was Elschnig pearl and 6 % was fibrous PCO (Table 1).



**Figure 1: Time period between cataract extraction and neodymium yttrium aluminium garnet laser capsulotomy (n = 50)**

Maximum PCO frequency was seen in patients who had undergone MSICS previously (Table 2).

It affected PCO frequency with rigid/PMMA as 96% cause of PCO postoperatively (Figures 3 and 4).

Post laser BCVA improved to 6/12 to 6/24 in the maximum number of patients followed by 6/6-6/12 (Table 3).

It showed the maximum number of patients had IOP spikes followed by IOL pitting. Inadvertent corneal burns, floaters, and CME were seen in few (Table 4).

Maximum IOP spikes were in the range of 21-27 mm Hg.

## DISCUSSION

The incidence of PCO varies with different studies. Sinsky and Cain reported that 43% of their patients required discussion, with an average follow-up of 26 months and a range from 3 months to 4 years. Emery, Wilhelmus, and

Rosenberg found opacification in 28% of their patients with 2-3 years of follow-up. Late opacification of the posterior capsule after 3-5 years has been reported to be approximately 50%. In our study, we found average time period between cataract extraction and Nd:YAG laser capsulotomy as 23 months.

Phacoemulsification is associated with lower rates of PCO than extracapsular cataract extraction which is similar to the finding in our study.

Elevated IOP is recognized as the most common, although usually transient, complication following Nd: YAG laser capsulotomy. This is similar to our study where we found increased IOP in 30% patients, but the rise was mostly in the range of 21-27 mm Hg.

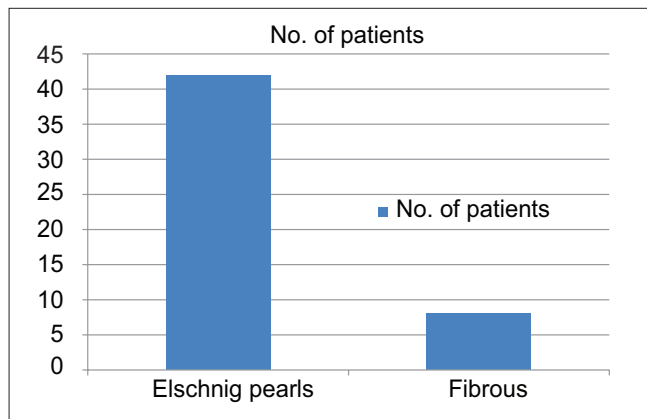


Figure 2: Types of posterior capsule opacification

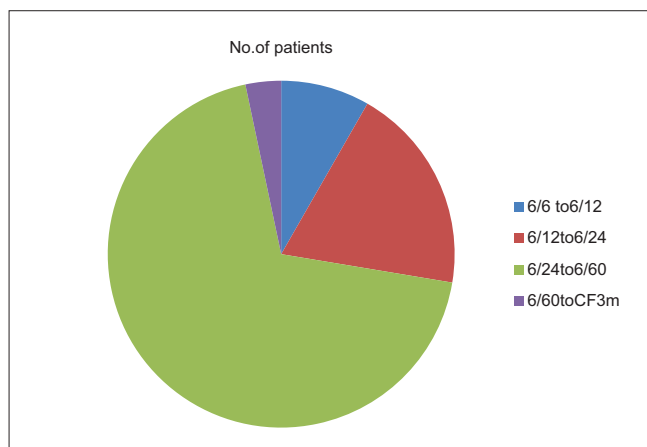


Figure 3: Pre laser best corrected visual acuity and number of patients showed maximum number of patients having vision of 6/24 to 6/60 followed by 6/12 to 6/24

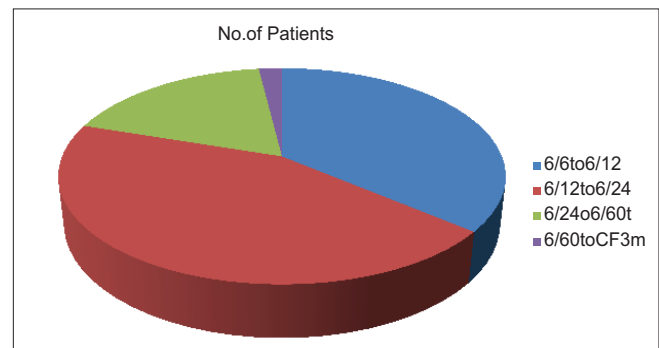


Figure 4: Post laser best corrected visual acuity and number of patients

Table 1: Type of cataract surgery and PCO frequency

MSICS	47
Phacoemulsification	3

PCO: Posterior capsule opacification, MSICS: Manual small incision cataract surgery

Table 2: Type of IOL implantation during cataract surgery

Rigid/PMMA IOL in the bag	48
Foldable IOL in the bag	2

IOL: Intraocular lens, PMMA: Polymethyl methacrylate

Table 3: Complications and number of patients

Inadvertent corneal burn	3
IOL pitting	10
Floaters	3
CME	1
Post laser IOP spikes	15

IOP: Intraocular pressure, IOL: Intraocular lens, CME: Cystoids macular edema

Table 4: Post laser IOP spikes and pressure range

21-27 mm Hg	11
27-35 mm Hg	4

IOP: Intraocular pressure

The IOP typically begins to rise immediately after the laser capsulotomy, peaks at 3-4 h, decreases but may remain elevated at 24 h, and usually returns to baseline at 1-week.<sup>12</sup> Rarely, the IOP may remain persistently elevated, causing visual field loss or requiring glaucoma surgery or both.

CME has been reported to develop in 0.55-2.5% of eyes following Nd: YAG laser posterior capsulotomy.<sup>13</sup> CME may occur between 3 weeks and 11 months after the capsulotomy. In our study, CME was seen in 2% of patients.

Pitting of IOLs occurs in 15-33% of eyes during Nd: YAG laser posterior capsulotomy.<sup>13</sup> We found pitting of IOL in 20% of our patients. The pitting usually was not visually significant.

Retinal detachment may complicate Nd: YAG laser posterior capsulotomy in 0.08-3.6% of eyes. However, in our study we had not found any patient with RD.

## CONCLUSION

Nd: YAG laser capsulotomy is a closed-eye, safe and effective method to treat PCO. It is non-invasive and avoids all the complications associated with surgical capsulotomy and local anaesthesia. However, Nd: YAG laser capsulotomy also carries risks like IOL pitting, CME, IOP spikes, inadvertent corneal burns and retinal detachment. Thus by minimising energy and number of precisely focused shots with proper follow-up, Nd: YAG

capsulotomy becomes the management of choice for PCO.

## REFERENCES

1. Aslam TM, Patton N. Methods of assessment of patients for Nd: YAG laser capsulotomy that correlate with final visual improvement. *BMC Ophthalmol* 2004;4:13.
2. Oner FH, Gunenc U, Ferliel ST. Posterior capsule opacification after phacoemulsification: Foldable acrylic versus poly (methyl methacrylate) intraocular lenses. *J Cataract Refract Surg* 2000;26:722-6.
3. Knorz MC, Soltan JB, Seiberth V, Lorgner C. Incidence of posterior capsule opacification after extracapsular cataract extraction in diabetic patients. *Metab Pediatr Syst Ophthalmol* 1991;14:57-8.
4. Apple DJ, Solomon KD, Tetz MR, Assia EI, Holland EY, Legler UF, et al. Posterior capsule opacification. *Surv Ophthalmol* 1992;37:73-116.
5. Paulsson LE, Sjöstrand J. Contrast sensitivity in the presence of a glare light. Theoretical concepts and preliminary clinical studies. *Invest Ophthalmol Vis Sci* 1980;19:401-6.
6. Sundelin K, Sjöstrand J. Posterior capsule opacification 5 years after extracapsular cataract extraction. *J Cataract Refract Surg* 1999;25:246-50.
7. Hasan KS, Adhi MI, Aziz M, Shah N, Farooqui M. Nd:YAG laser posterior capsulotomy. *Pak J Ophthalmol* 1996;12:3-7.
8. Tan JC, Spalton DJ, Arden GB. Comparison of methods to assess visual impairment from glare and light scattering with posterior capsule opacification. *J Cataract Refract Surg* 1998;24:1626-31.
9. Knaski JJ. *Clinical Ophthalmology: A Systemic Approach*. 4<sup>th</sup> ed. London: Butterworth - Heinemann; 1999. p. 169-70.
10. Capone A Jr, Rehkopf PG, Warnicki JW, Stuart JC. Temporal changes in posterior capsulotomy dimensions following neodymium: YAG laser dissection. *J Cataract Refract Surg* 1990;16:451-6.
11. Clayman HM, Jaffe NS. Spontaneous enlargement of neodymium: YAG posterior capsulotomy in aphakic and pseudophakic patients. *J Cataract Refract Surg* 1988;14:667-9.
12. Richter CU, Arzeno G, Pappas HR, Steinert RF, Puliafito C, Epstein DL. Intraocular pressure elevation following Nd: YAG laser posterior capsulotomy. *Ophthalmology* 1985;92:636-40.
13. Keates RH, Steinert RF, Puliafito CA, Maxwell SK. Long-term follow-up of Nd: YAG laser posterior capsulotomy. *J Am Intraocul Implant Soc* 1984;10:164-8.

**How to cite this article:** Gopinath GS, Satish K, Srivastava N, Patil S, Afshan R. Visual Outcome and Complications of YAG Laser Therapy for Posterior Capsular Opacification Following Cataract Surgery. *Int J Sci Stud* 2015;3(3):65-68.

**Source of Support:** Nil, **Conflict of Interest:** None declared.