

Analysis of the Outcome of Mandible Fracture Management

R Senthilkumar¹, A Kavitha Priya², Heber Anandan³

¹Associate Professor, Department of Plastic Surgery, Tirunelveli Medical College Hospital, Tamil Nadu, India, ²Assistant Professor, Department of Plastic Surgery, Coimbatore Medical College Hospital, Tamil Nadu, India, ³Senior Clinical Scientist, Department of Clinical Research, Dr. Agarwal's Healthcare Limited, Tamil Nadu, India

Abstract

Introduction: The mandible is the second most common facial fracture, with the nasal bone being the first. Knowledge of the anatomy of the mandible and the muscular forces applied to it is the key to proper reduction of mandibular fractures. The goal in reduction is to restore premorbid occlusion, allowing patients to resume masticatory functions.

Aim: The aim of this study is to analyze the outcome of mandibular fracture fixation with eyelets, arch bars, miniplates, and screws.

Methods: A total of 67 patients who reported to the trauma ward and the department of plastic and reconstructive surgery for the treatment of fracture mandible were included in this study. Information was collected from the clinical and surgical notes of each of the patients in a standardized and systematic pattern.

Results: Of the 15 patients treated conservatively, 11 (73.3%) had single fracture and 4 (26.6%) had double fractures. In the surgically treated patients, 30 (57.6%) had single fracture, 17 (32.6%) had double fractures, and 15 (28.8%) had segmental fractures. In the conservative group, the visual analog score for chewing improved from 9 to 6 in 6 weeks' time, and in the surgical group, the score improved in 4 weeks' time since we removed maxillomandibular fixation soon after surgery. The mouth opening becomes near normal (45-50 mm) in single fractures both in conservative and surgical groups. In double fractures of both the groups, the mouth opening was 40-45 mm in 6 weeks' time.

Conclusion: An adequate knowledge of the diagnosis and management of various types of mandibular fracture is needed so as to provide the desired treatment to prevent unfavorable and adverse complications.

Key words: Closed reduction, Facial trauma, Mandible, Maxillofacial, Maxillomandibular fixation, Occlusion, Plating

INTRODUCTION

The face is the most admirable part of our body. Facial injury is the most common cause of disfigurement and affects the personality of the individual very much. The most frequently injured facial bone is mandible after the nasal bone because it is the most mobile and prominent facial bone.¹ Mandible fractures are a frequent injury because of the mandible's prominence and relative lack

of support. As with any facial fracture, consideration must be given for the need of emergency treatment to secure the airway or to obtain hemostasis if necessary before initiating definitive treatment of the fracture.² The mandibular fractures outnumber zygomatic and maxillary fractures by a ratio of 6:2:1, respectively.³ Fractures of mandible invariably produce malocclusion if not treated properly. Knowledge of the dentition is thus an absolute prerequisite for the proper treatment of jaw fractures. Various techniques that are advocated in the literature to manage mandibular fractures vary ranging from bandages and external appliances, extra- and intra-oral appliances, monomaxillary wiring, intermaxillary wiring, plates, and screws.⁴ Restoration of the occlusion usually indicates anatomic reduction and proper positioning of the mandible and facial bones.

Access this article online



www.ijss-sn.com

Month of Submission : 04-2017

Month of Peer Review : 05-2017

Month of Acceptance : 06-2017

Month of Publishing : 06-2017

Corresponding Author: A Kavitha Priya, Assistant Professor, Department of Plastic Surgery, Coimbatore Medical College Hospital, Tamil Nadu, India. Phone: 9486232101. E-mail: kavithapriyaplastic@gmail.com

Our goal should be restoration of the function without any morbidity at the earliest.

Aim

The aim of this study is to analyze the outcome of mandibular fracture fixation with eyelets, arch bars, miniplates, and screws.

MATERIALS AND METHODS

This study was conducted in the Department of Plastic and Reconstructive Surgery, Coimbatore Medical College and Hospital. A total of 67 patients who reported to the trauma ward and the Department of Plastic and Reconstructive Surgery for the treatment of fracture mandible were included in this study. Information was collected from the clinical and surgical notes of each of the patients in a standardized and systematic pattern. The demographic variables, such as age, gender, and residence, were assessed. Clinical information included diagnosis and etiology, and anatomical distribution of mandibular fractures was assessed. The mandibular fractures were classified according to the sites such as the ramus, condyle, coronoid symphysis, body, para symphysis, and angle. Inclusion criteria were all adult patients between 25 and 55 years, patients reporting within first 7-10 days from the day of trauma, dentulous/partially edentulous patients, and patients giving consent for a follow-up period of 3 months postoperatively. Exclusion criteria were compound fractures, patients with other facial bone fractures, patients with systemic/debilitating diseases, and patients with head injury. Clinical evaluation includes history of incident, inspection-swelling, laceration, malocclusion, sublingual hematoma, deformity and trismus, palpation-step deformity/tenderness, paresthesia/dysesthesia/anesthesia of mental nerve, and TMJ examination to find any condyle fracture. All patients with suspected mandible fracture were subjected to orthopantomogram and computed tomography facial bones. The mandibular fractures were classified according to the site such as the ramus, condyle, symphysis, body, parasymphysis, and angle.

RESULTS

A total of 67 patients who underwent treatment for both conservatively and surgically were included in the study. The number of patients in the conservative group was 15 and surgically treated was 52. In this study, both in conservative and surgical majority of the injured patients were in the age group between 25 and 30 (42.6%). The youngest patient was 25 years and the oldest was 54 years. About 55 patients (82%) were in the age group of 25-40 years (Table 1).

Table 1: Age distribution of mandible fractures

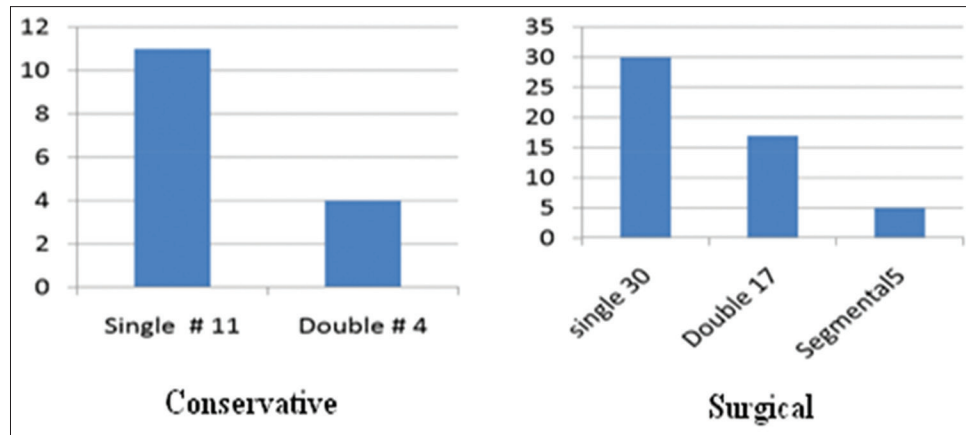
Age	Conservative	Surgical
25-30	6	25
31-35	1	10
36-40	3	10
41-45	0	3
46-50	4	3
51-55	1	1
Total	15	52

Of the 15 patients treated conservatively, all were male, and in the 52 patients treated surgically, 43 were male (82.6%) and 9 were female. Road traffic accident (RTA) was the most common mode of injury in both conservative and surgically treated patients, which was followed by fall and assault. RTA was about 76.6% in both the groups (67 patients).

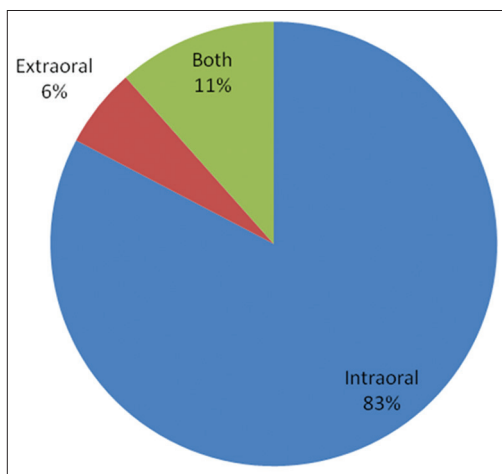
Of the 15 patients treated conservatively, 11 (73.3%) had single fracture and 4 (26.6%) had double fractures. In the surgically treated patients, 30 (57.6%) had single fracture, 17 (32.6%) had double fractures, and 15 (28.8%) had segmental fractures (Graph 1). In single fracture, right side (58.5%) was the most frequently involved. In both the groups, parasymphysis (48%) was the most common site of involvement in single fracture. The combinations in conservative double fractures were parasymphysis with subcondylar and bilateral parasymphysis fracture. In surgically treated double fractures the following were the combinations, bilateral parasymphysis -6, parasymphysis with angle - 4, parasymphysis with body - 4, parasymphysis with ramus - 2, and parasymphysis with subcondylar - 1. Bilateral parasymphysis was the most common fracture. All the combinations had parasymphysis fracture. There were 5 cases of segmental fracture. Of which bilateral parasymphysis with one side subcondylar - 2, bilateral subcondylar with one side parasymphysis - 2 and bilateral parasymphysis with bilateral subcondylar fracture - 1 (Figure 1).

In the patients treated conservatively, maxillomandibular fixation (MMF) done within 24-48 h. If the patients surgically treated, patients were operated in an average period of 7 days (Graph 2).

Out of the 52 patients treated surgically, 43 patients underwent intraoral approach, 3 patients underwent extraoral approach (Figure 2) (Risdon approach), and 6 patients underwent both the approaches. (Graph 1) In both single and double fractures treated conservatively, the prefixation score of 9 improved to 1 by the end of 5 weeks in single fractures, but it took one more week in double fracture (Graph 3). In surgically treated patients (single, double, and segmental fractures), the results were same as conservatively treated single and double fractures, but



Graph 1: Distribution of number of fractures



Graph 2: Distribution of surgical approach

the pain score was remaining high in the second and third weeks. In the conservative group, the visual analog score for chewing improved from 9 to 6 in 6 weeks' time, and in the surgical group, the score improved in 4 weeks' time since we removed MMF soon after surgery. The mouth opening becomes near normal (45-50 mm) in single fractures both in conservative and surgical groups. In double fractures of both the groups, the mouth opening was 40-45 mm in 6 weeks' time.

Angle Class I occlusion was achieved in 13 patients (86.6%) in conservatively treated patients and 49 patients (94.2%) in surgically treated patients. There were 2 cases of open bite (13.3%) in conservatively treated patients and 3 cases of open bite (5.7%) in surgically treated patients (Table 2).

DISCUSSION

The mandible although considered the heaviest and the strongest facial bone, is more prone for fractures because it is an open arch, located in the lower portion of the face

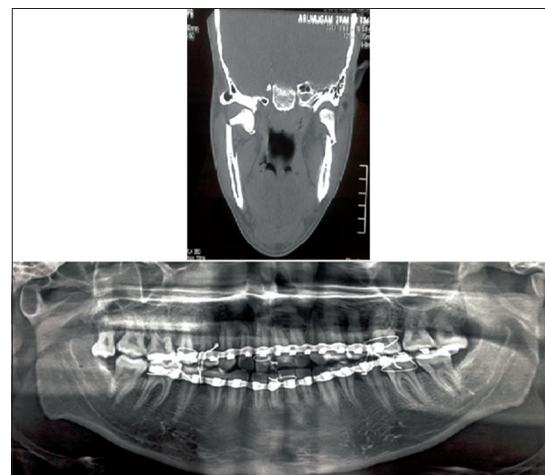


Figure 1: Bilateral subcondylar fracture managed conservatively treated resulting, adequate mouth opening after maxillomandibular fixation removal

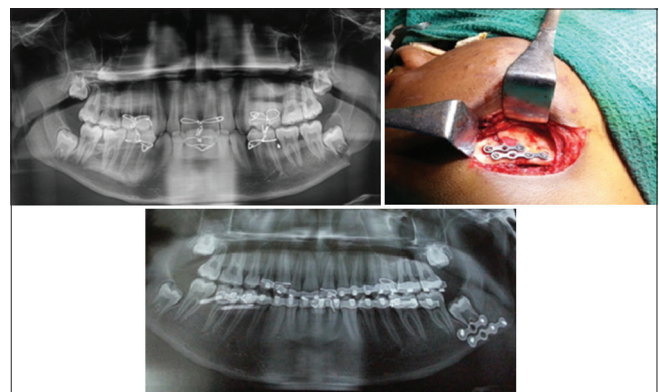
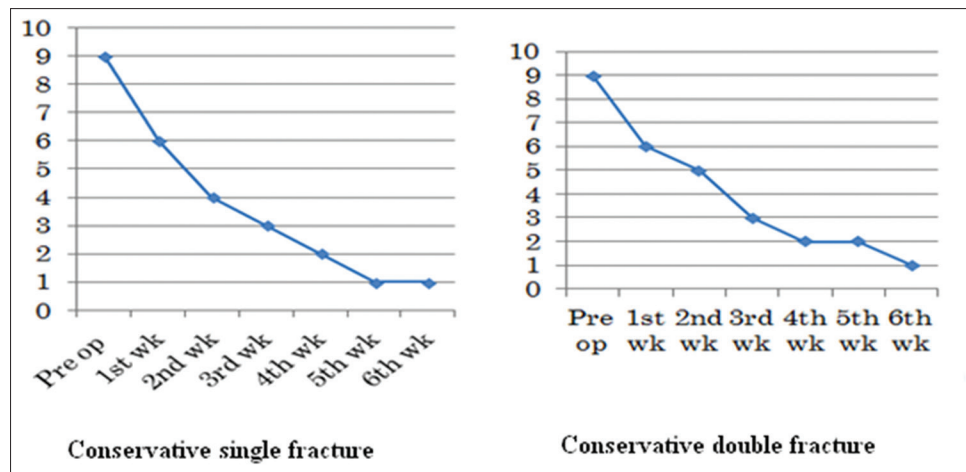


Figure 2: Left angle fracture ORIF done with 2 plates and screws. Post-op in good mouth opening and occlusion

and atrophies with age. Facial injuries not only involve soft tissues but also damage the bone, leading to fractures. The mandible is connected by the strong muscles for various functions. They act as a splint and give protection to the mandible, and on the other hand, these powerful muscles



Graph 3: Visual analog score for pain

Table 2: Distribution of complications

Complications	Conservative	Surgical
Malocclusion	2 (13.3)	4 (7.6)
Infection	0	5 (9.6)
Nonunion	0	0
Malunion	1 (6.6)	0
Paresthesia-Mental nerve involvement	2 (13.3)	4 (7.6)
Marginal mandibular nerve involvement	-	0
Hardware exposure	0	0

can cause massive displacement of the fracture fragments.⁵ The human face constitutes the first contact point in several human interactions, and thus, injuries and mutilation of the facial structures may have a disastrous influence on the affected person.⁶ Knowledge of the dentition is thus an absolute prerequisite for the proper treatment of mandible fractures. Fractures of the mandible invariably produce malocclusion if not treated properly. The most common facial fractures were the mandible (61%), followed by the maxilla (46%), the zygoma (27%), and the nasal bones (19.5%).^{7,8} Road traffic injury was the most common mode of injury in our study (76.6%) followed by fall and assault. Adekeye has reported that 74% of mandibular fractures were due to RTA.⁹ This was also reported by Subhashraj *et al.* in a study done in South Indian city.¹⁰ The mechanism of hyperextension and hyperflexion of the head in traffic accidents makes it more vulnerable to fracture.¹¹ This male predominance may be due to the greater mobility of the male and their aggressive behavior. In our study, we found that the age group between 25 and 30 years was the most commonly involved. This was supported by Ajmal *et al.*⁴ and Sirimaharaj *et al.*¹⁰ There were 61.6% of single mandibular fractures and 40.6% of multiple mandibular fractures, with an average of 1.34 fractures per person. This is similar to that of Sirimaharaj *et al.*¹⁰ who reported 1.4 fractures per person. Ajmal *et al.*⁴ reported 1.5 fractures per person. Parasymphiseal fractures were the

most common fractures in our study followed by the body and angle. Among double fractures, the most common combination is bilateral parasymphysis. In segmental fractures, bilateral parasymphysis fracture was the most common one. Right-side involvement was common. Ajmal *et al.*⁴ also reported that parasymphiseal fractures were the most frequently involved followed by the body and angle. This was also supported by Mittal *et al.*¹² study. Deranged occlusion followed by bony deformity was the most common mode of clinical presentation. This finding was supported by Laurentjoye *et al.*¹³ All the parasymphysis, symphysis, and body fractures were approached intraorally. Extraoral approach was used for angle fractures. Care was taken not to injure the mental nerve during intraoral and marginal mandibular nerve during Risdon approach. In our study, undisplaced fractures, condylar, and subcondylar fractures were treated with MMF, with good functional results as comparable with Ghodke.¹⁴ Out of 67 patients, 15 (22.3%) underwent conservative treatment with eyelets, arch bars, and MMF. The duration of MMF was 4-6 weeks in adults, 2-3 weeks in condylar fractures.⁴ Benjamin *et al.*¹⁵ study from Nigeria have also reported the usage of arch bars and eyelets with the same results. The average recommended period of immobilization of fractured mandible is 4-6 weeks.^{16,17} Although this is only empirical, it is usually influenced by several factors such as age of patient, type, number and severity of fracture, presence or otherwise of retained teeth in fracture line, and presence or absence of infection amongst others.¹² In both the conservative and surgical single fracture patients, the visual analog score - pre-operative pain score of 9 - has come down to 1 during 5th week. In surgical group, the pain score was remaining high in the 1st week due to surgical trauma and then it has reduced to 2 during the 3rd week due to stability of fixation. In surgical double fracture, the pre-operative pain score of 9 has come down to 1 in 5 weeks. However, it took 1 more week for the conservative double

fracture to come down to one. In conservative group, the pre-operative chewing score improved from 9 to 0 in 10 weeks. In the surgical group, it improved from 9 to 0 in 4-6 weeks. After removal of the MMF (6 weeks) in the conservative group and in the 3rd post-operative week in the surgical group, patients were encouraged to do early physiotherapy. They had impairment in speech also in the conservative group. At the end of 3 months, none of the patients had mastication and speech problem, which was comparable with Shivani *et al.*⁵ The average mouth opening was 41.5 mm in the conservatively treated group and 47 mm in the surgically treated group. This was probably due to the TMJ dysfunction in the conservatively treated group in whom MMF was retained for 4-5 weeks. This was comparable with studies conducted by Amarathunga¹⁸ and Cawood *et al.*¹⁹ This probably due to the muscle disuse atrophy and scarring in the fracture site following tissue disruption and hematoma formation.²⁰ Near normal opening in the surgical group due to MMF removal after surgery and early mobilization. There were weight loss, airway-related problem, difficulty in phonation, and poor oral hygiene in the conservatively treated group. Weight gain and good oral hygiene were seen in the surgically treated patients. This study was similar to that of Brown *et al.*²¹ who demonstrated the advantages of miniplate osteosynthesis over intermaxillary fixation in management of fractured mandible. The post-operative function is improved and there was weight gain. Patients treated with intermaxillary fixation have restricted airway. There was weight loss during the first postoperative week in surgically treated patients. This was probably due to the poor intake of proper diet due to surgical trauma.

A total of 2 patients (13.3%) had malocclusion in the conservative group, which was noticed in the first review and they were subjected to open reduction. There was malocclusion in 4 patients (7.6%) who were treated surgically which was less when compared with the Benjamin *et al.*¹⁵ study. All the 4 patients were subjected to redo and occlusion was achieved. There were 5 cases of infection (9.6%) in the operated group which was treated with higher antibiotics, and the implant was retained till the fracture union. Implant removal was done in all these 5 patients after the fracture union. The infection rate was little higher when compared to Ugboko *et al.*⁷ who had 8.1%. 1 patient who was treated conservatively developed malunion and it was corrected with osteotomy, bone graft, and plate osteosynthesis. The neurological deficit in the operated group was 4 (7.6%) and the conservative group was 2 which was comparable to the study conducted by Benjamin *et al.*,¹⁵ (7.1%) and Cawood¹⁹ (8%) which improved in 6-8 weeks' time. This deficit was not due to the surgical procedure but related to the nature of injury.

CONCLUSION

The treatment of mandible fractures requires adequate fracture reduction and stabilization through a closed or open technique. Success relies on the restoration of normal dental occlusion and bony union. The treatment chosen may differ as there are many factors such as cost of treatment, affordability by the patient, feasibility in the hospital, doctor's decision and skill, and patient's willingness to avail the treatment advised, all of which may vary from one country to another. This study is not comparing the results of closed reduction and open reduction techniques. It is an analysis of the mandibular fracture demographic variables and outcome of the management adopted in patients presented to our department. The results of the patients treated both closed and open methods were same as reported in the literature. In single fracture, the results both in the surgical and conservative groups are equal. Conservative group took longer time for improvement than surgical group since we maintain MMF for 4-6 weeks. In double and segmental fracture, surgical management had good outcome with double-plate fixation. High levels of success can still be achieved using available materials in the form of arch bars, eyelets, and wire osteosynthesis in the treatment of mandibular fractures using either the closed or open reduction technique in resource-poor settings despite the advent of miniplate osteosynthesis.

REFERENCES

1. Passi D, Ram H, Singh G, Malkunje L. Total avulsion of mandible in maxillofacial trauma. *Ann Maxillofac Surg* 2014;4:115-8.
2. Pearl WS. Facial imaging in an urban emergency department. *Am J Emerg Med* 1999;17:235-7.
3. Bruce R, Fonseca RJ. *Oral & Maxillofacial Trauma*. Vol. 1. Toronto: WB Saunders Co.; 1991.
4. Ajmal S, Khan MA, Jadoon H, Malik SA. Management protocol of mandibular fractures at Pakistan Institute of Medical Sciences, Islamabad, Pakistan. *J Ayub Med Coll Abbottabad* 2007;19:51-5.
5. Jain S, Gupta S. Titanium miniplates versus intraosseous wires as methods of fixation of mandibular fractures: A clinical study. *Indian J Stomatol* 2011;2:238-44.
6. Zargar M, Khaji A, Karbakhsh M, Zarei MR. Epidemiology study of facial injuries during a 13 month of trauma registry in Tehran. *Indian J Med Sci* 2004;58:109-14.
7. Oginni FO, Ugboko VI, Ogundipe O, Adegbehingbe BO. Motorcycle-related maxillofacial injuries among Nigerian intracity road users. *J Oral Maxillofac Surg* 2006;64:56-62.
8. Oikarinen VJ, Lindqvist C. The frequency of facial bone fractures in patients with multiple injuries sustained in traffic accidents. *Proc Finn Dent Soc* 1975;71:53-7.
9. Adekeye EO. The pattern of fractures of the facial skeleton in Kaduna, Nigeria. A survey of 1,447 cases. *Oral Surg Oral Med Oral Pathol* 1980;49:491-5.
10. Sirimaharaj W, Pyungtanap K. The epidemiology of mandibular fractures treated at Chiang Mai University Hospital: A review of 198 cases. *J Med Assoc Thai* 2008;91:868-74.
11. Holt GR. Maxillofacial trauma. In: Cummings CW, Krause CJ, editors. *Otolaryngology-Head and Neck Surgery*. St. Louis: C.V. Mosby; 1986. p. 313-44.

12. Mittal G, Mittal S. Mandibular fractures at veer chandra singh garhwali government medical science and research institute, Garhwal region, Uttarakhand, India: A retrospective study. *Ann Med Health Sci Res* 2013;3:161-5.
13. Laurentjoye M, Majoufre-Lefebvre C, Caix P, Siberchicot F, Ricard AS. Mandibular fractures with Michelet technique: Manual fracture reduction without arch bars. *J Oral Maxillofac Surg* 2009;67:2374-9.
14. Ghodke MH, Bhojar SC, Shah SV. Prevalence of mandibular fractures reported at C.S.M.S.S Dental College, Aurangabad from February 2008 to September 2009. *J Int Soc Prev Community Dent* 2013;3:51-8.
15. Benjamin A, Sara KE, Olushola AI. Analysis of complication of mandibular fracture. *Afr J Trauma* 2014;3:24-9.
16. Fonseca RJ, Bruce R, Walker R. Trauma. *Oral and Maxillofacial Surgery*. Vol. 1. Washington, DC: Churchill Livingstone; 2001. p. 19-34.
17. Kamali U, Pohchi A. Mandibular fracture at HUSM: A 5-year retrospective study. *Arch Orofacial Sci* 2009;4:33-5.
18. de Amaratunga NA. Mouth opening after release of maxillomandibular fixation in fracture patients. *J Oral Maxillofac Surg* 1987;45:383-5.
19. Cawood JI. Small plate osteosynthesis of mandibular fractures. *Br J Oral Maxillofac Surg* 1985;23:77-91.
20. Sindet-Pedersen S, Jensen J. Treatment of mandibular fractures with or without intermaxillary fixation - A comparative study. *Oral Surg Oral Diagn* 1992;3:37-44.
21. Brown JS, Trotter M, Cliffe J, Ward-Booth RP, Williams ED. The fate of miniplates in facial trauma and orthognathic surgery: A retrospective study. *Br J Oral Maxillofac Surg* 1989;27:306-15.

How to cite this article: Senthilkumar R, Priya AK, Anandan H. Analysis of the Outcome of Mandible Fracture Management. *Int J Sci Stud* 2017;5(3):179-184.

Source of Support: Nil, **Conflict of Interest:** None declared.