

# Non-Odontogenic Toothache – A Clinical Dilemma

Khushbu Ajmera<sup>1</sup>,  
Sanjot Mulay<sup>2</sup>

<sup>1</sup>MDS 2<sup>nd</sup> Year Post Graduate Student in the Department of Conservative Dentistry and Endodontics, Dr. D.Y. Patil Dental College and Hospital, Pune, Maharashtra, India, <sup>2</sup>MDS & Professor, Department of Conservative Dentistry and Endodontics, Dr. D.Y. Patil Dental College and Hospital, Pune, Maharashtra, India

**Corresponding Author:** Dr. Khushbu Ajmera, Department of Conservative Dentistry and Endodontics, Dr. D.Y. Patil, Vidyapeeth, Sant Tukaram Nagar, Pimpri, Pune - 411018, Mobile: 9619285856, E-mail: khushbu.ajmera9@gmail.com

## Abstract

Toothache is a common complaint in the dental clinic. Generally toothaches have their origin in the pulpal tissues or periodontal structures. These cases of odontogenic pain are managed well and predictably by dental therapies. Nonodontogenic toothache is often difficult to identify and can challenge the diagnostic ability of the clinician. This case report highlights the importance of correct diagnosis and treatment planning.

**Keywords:** Diagnostic aids, Non odontogenic toothache, Orofacial pain, Trigeminal neuralgia

## INTRODUCTION

Oral cavity is a reflection of our body. Diagnosis may be a grey area, even for the most experienced clinician. Pain in orofacial region is both complex and distressing, frequently overlapping various surgical and medical disciplines.<sup>1</sup> The diagnosis of oral pain is a constant challenge to dental practitioner. However, diagnostic procedures are often limited to identifying a suspect tooth rather than considering a non-odontogenic source of pain. Toothache of nonodontogenic origin is not true dental pathology, rather it is the pain referred into the dentition from distant location.<sup>2</sup> A misdiagnosis will lead to unnecessary treatment for the patient and may also exacerbate the symptoms for which the patient sought treatment.<sup>3</sup>

Hence, this case report emphasizes on a multidisciplinary approach, which highlights the importance of correct diagnosis and treatment planning.

## CASE REPORT

A 35 year old man reported to the department of Conservative Dentistry and Endodontics, Dr. D.Y. Patil Dental College and Hospital, Pimpri with a chief complaint of pain in upper front region of the jaw since 2 yrs. On examination no obvious abnormality was detected in the anterior region. The pain was localized with respect to upper

right lateral incisor. Dull continuous pain with exacerbation of sharp, shooting pain, lasting for few seconds. The patient gave a history of trauma in upper front region 2 yrs back. Medical history was non-contributory. Past dental history revealed root canal treatment and surgery in upper front region. He also gave a history of implant placement in lower right and left back region 2 years ago.

On Clinical examination, three unit ceramic bridge on 11, 21 and 22 was present. 12 was sensitive to percussion and palpation, periodontal probing depth ranged from 2-4 mm. Carious lesions with respect to 23, 38 and 47 were noted. Prosthesis with 36 and 46 was seen. Missing teeth were 17, 16, 15 and 21.

Various investigations were carried out - transillumination of 12 revealed enamel crack in incisal 1/3<sup>rd</sup>. pulp vitality test was performed with 13, 12, 11, 21, 22, and 23. all the examined tooth responded to thermal (cold) test and electric pulp test. With respect to 12 the vitality with cold thermal test revealed hyper response. Intraoral periapical radiograph with 12 showed widening of lamina dura (Figure 1). Orthopantomograph (Figure 2) revealed endodontic treatment with 11, 22, 25, 26, 27 and 37. Deep proximal radiolucent area was seen in 38 and 47. Implants in 36 and 46 were noted. Bridge in 11, 21, 22 region as well crowns with respect to 25, 26, 27 and 37 were seen. Provisional diagnosis was chronic irreversible pulpitis with 12.

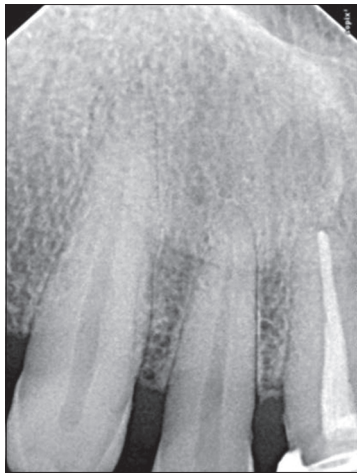

Figure 1: Peroperative IOPA with 12

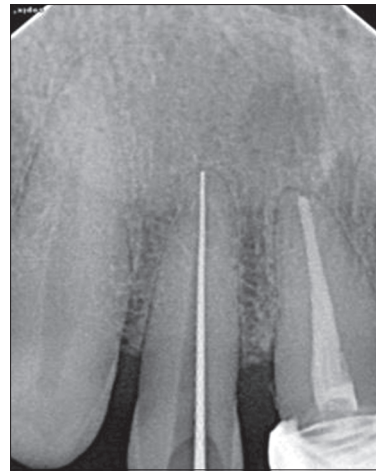

Figure 3: Working length of 12

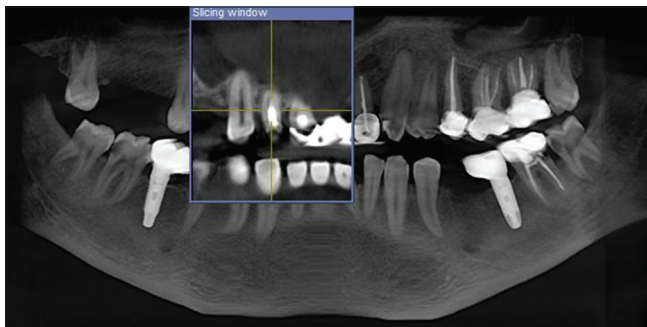


Figure 2: Orthopantomograph

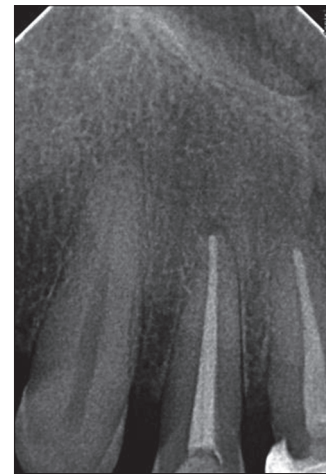

Figure 4: Obturation of 12

Based on the clinical and radiographic findings treatment plan was drawn and carried out as follows:

- Anti-inflammatory and analgesic medication Tab Enzoftam TDS for 3 days.
- In the next visit after five days considering that right lateral was very sensitive to percussion and palpation root canal treatment was initiated with 12 and intracanal medication of calcium hydroxide with iodoform was given (Figure 3). Obturation was completed after 3 weeks (Figure 4).
- All the carious teeth were restored.
- Advanced investigation CBCT was advised, but did not lead to any concrete/definitive diagnosis (Figure 5a-c).

However the pain was still not alleviated and the patient appeared to be in great stress and desperate to seek any relief from pain. The patient was examined further to determine if the pain was of non odontogenic in origin.

Going back to the history of pain, initially the patient could not describe the pain but on asking lead questions and probing he stated “the pain was severe and occurred several times a day and lasted for few minutes”. Palpation of periapical area near the lateral provoked severe pain which was described by the patient as electric shock like

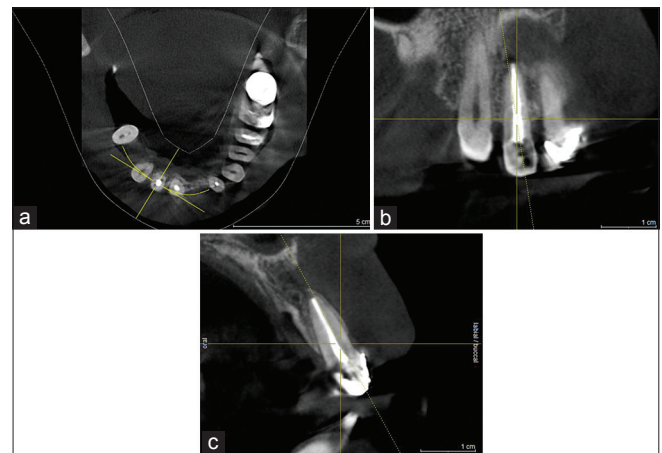


Figure 5: CBCT

pain radiating to the side of the nose near the ala region. The patient was further questioned as to whether the pain could be caused by any other means. He stated “sometimes whenever he stretched or rubbed his upper lip with his fingers, especially during brushing, chewing or talking pain

occurred". Based on these findings, he was then referred to OMDR dept. at Dr. D.Y.Patil College, for consultation regarding non-odontogenic pain. Diagnosis of trigeminal neuralgia was confirmed. The patient was then given tab Tegretol 500 mg in divided doses and he has been partly relieved of acute symptoms for more than 2 months. The patient has been maintained on this regimen, with the pain at a reduced level but not total, pain relief yet.

## DISCUSSION

Tooth ache is the most common pain entity occurring in facial region. All pain entities presenting as tooth ache may not be of odontogenic origin. Pain in the orofacial region is a common affliction, affecting between 10-50% of the population. It is the primary responsibility of a dental practitioner to diagnose pathologic entities associated with oral cavity.<sup>1</sup> While much of endodontic diagnosis can be based on standard diagnostic procedures, an essential component of the diagnostic process is dependent on the patient's history of pain and the description or reaction to diagnostic tests. The patient's medical history, dental history, and psychological state may contribute to the diagnosis. Using various diagnostic aids like thermal testing, percussion, palpation, occlusal sensitivity, electric pulp testing, and radiographs the clinician can frequently isolate the origin of the patient's pain and arrive at a diagnosis. Pain must be considered in terms of quality, duration, temporal pattern, exacerbation, and relief. These characteristics and the perceived origin of the pain may be pathognomonic for specific sites. When patients present with diffuse pain and/or pain radiating to other areas, nonodontogenic sources should be given additional consideration.

Although the overwhelming majority of dental pain is odontogenic in origin, a significant percentage is non-odontogenic.<sup>2</sup> If pain were purely a sensory phenomenon, diagnosis would be fairly straight forward. However, pain has both sensory and emotional components. This complex nature of pain may make it difficult for patients to adequately describe the essential components for diagnosis (e.g. intensity, location, duration). An additional source of confusion is the fact that a practitioner must interpret and co-relate the patient's reaction to diagnostic tests and his/her description of the pain.

When a patient presents to an endodontist, usually the pain is of odontogenic origin. Diagnostic procedures may therefore be limited to identifying a suspect tooth rather than a nonodontogenic source of pain.<sup>3</sup> This case illustrates the complex task of the clinician in determining which factors are important to consider at each stage of the progression of a pain disorder.<sup>4</sup>

In this present case patient's pain condition seemed to be resistant to conservative dental treatment. The symptoms were quite severe which influenced the patient to consent to treatment, though the clinical findings were inconclusive and definitive diagnosis could not be made. Hence, the patient was referred to department of oral diagnosis, wherein the pain was suspected to be of non-odontogenic origin. Temporary Pain relief after therapy with carbamazepine for 3 months. Hence a definitive diagnosis of chronic orofacial pain was made.

"Chronic facial pain" is a more descriptive term than "atypical facial pain" and should be adopted for continuous, dull pain in the face, of greater than 6 months duration, with intermittent severe episodes. (International Association for the Study of Pain's).<sup>5</sup>

There remains an ill-defined and rare group of facial pain, which manifest themselves despite any discernible pathology. They are frequently termed as atypical, idiopathic or non-somatic. The disease can present in its atypical form due to the multitude of possible causes owing to anatomic complexity of the orofacial region. This was until at the end patient described pain to exposure to cold and touch, and the triggering of the attack by habitual oral activities (chewing, talking, tooth brushing). Only then diagnosis of trigeminal neuralgia was made. At the outset, the patient reported idiopathic onset and clinical characteristics with overlapping diagnostic possibilities (sharp pain episodes triggered by tooth stimulation; sharp pain episodes triggered by stimulation to the face), from which nociception sufficient to explain the complaint could be reasonably inferred.<sup>4,6</sup>

Trigeminal neuralgia is defined as "Severe, paroxysmal bursts of pain in one or more branches of the trigeminal nerve; often induced by touching trigger areas in or around the mouth".<sup>7</sup> The mandibular and maxillary divisions are most commonly involved.<sup>5</sup> Typically, the pain occurs as paroxysms of shocking, burning or lightning-like sharp stabs that last from a few seconds to a few minutes.<sup>4,8</sup> It occurs predominantly during middle and old age, and more frequently in women.<sup>4,9</sup> The pain can be provoked by sensory stimulations, such as touching and washing of the face, tooth brushing, shaving, chewing, talking, or by thermal change.<sup>5</sup> It usually is unilateral and remains in the anatomical distribution of the affected nerve regardless of intermission or remissions.<sup>6</sup>

Correct diagnosis and particularly early definitive diagnosis of neuropathic pain is crucial to avoid invasive and potentially more damaging forms of treatment. The overlap of symptom characteristics between some variants of neuropathic trigeminal pain and classic dental

**Table 1: Differences between classic primary trigeminal neuralgia and atypical facial pain<sup>11</sup>**

|                                      | <b>Trigeminal neuralgia</b>  | <b>Atypical facial pain</b>   |
|--------------------------------------|--|---|
| Location of pain                     | Along distribution of branches of the trigeminal nerve; unilateral         | Usually will not follow automatic pathways; unilateral, less likely bilateral |
| Duration of pain                     | Brief : seconds, up to 1 to 2 minutes                                      | Constant  |
| Intensity of pain                    | Severe   | Moderate to severe, may fluctuate   |
| Sensory quality of pain              | Sharp, stabbing, electric shock – like, lancinating, flashing, burning     | Diffuse; burning, aching, dull  |
| Affective quality of pain            | Terrifying, blinding, torturing  | Excruciating, vicious   |
| Trigger                              | Non-painful physical stimulation of trigger points or trigger zones        | Trigger very seldom present   |
| Associated signs and symptoms        | Signs: tic douloureux  | Symptoms: allodynia, dysesthesia, paresthesia                                 |
| Functional impairment                | Considerable to extreme  | Low   |
| Response to treatment                | Good   | Limited   |
| Treatment of choice                  | Carbamazepine  | Tricyclic antidepressants   |
| Sex distribution of patients         | Women-men ~ 2:1 to 3:2   | Predominantly women   |
| Average age at (first) manifestation | Between 50 – 70 years  | Around 40 years   |
| Theories of causation                | Impingement of trigeminal root; central neural disease; vascular causation | Trauma: patho-psychology: vascular causation                                  |

disorders may be responsible for this confusion. Primary care physicians may also lack the training to establish a diagnosis of neuropathic trigeminal pain. More thorough examination of periodontal, alveolar, and gingival tissues for regions of allodynia, hyperpathia, and hyperalgesia will improve detection of less severe and more atypical cases of neuropathic trigeminal pain (Table 1).<sup>10-12</sup>

## CONCLUSION

Severe pain may cause both the patient and the practitioner considerable distress that may complicate the diagnostic process and possibly lead to unnecessary and costly treatment. A multidisciplinary approach is therefore preferable and should be adopted for diagnostic and prognostic assessment.

## ACKNOWLEDGEMENT

Authors would like to thank Dr. L. Beri, Prof. and Dr. R. Shetty, Prof & HOD for constant help and support; Dr. S. Gotecha, MS, MCH Neurosurgery at D Y Patil Medical College for his guidance. Dr. Sarang gotecha, M.S., MCH Neurosurgery at Dr. D.Y. Patil medical college for his constant support and guidance.

## REFERENCES

1. Alberts I. Idiopathic Orofacial Pain: A Review. *The Internet Journal of Pain, Symptom Control and Palliative Care*. 2008;6(2).
2. Philip M, Bruce R. B, Seymour F. Toothache of nonodontogenic origin: A case report. *J Endod* 2003;29(9):608-10.
3. Jeffrey P. Lilly, and Alan S. Law. Atypical odontalgia misdiagnosed as odontogenic pain: A case report and discussion of treatment. *J Endod* 1997;23(5):337-39.
4. Christopher JS, John KN, Henry G, Joanna MZ, and Richard O. Toothache or Trigeminal Neuralgia: Treatment Dilemmas. *J Pain* 2008;9(9):767-70.
5. Madland G, Feinmann C. Chronic facial pain: A multidisciplinary problem. *J Neurol Neurosurg Psychiatry* 2001;71:716-19.
6. Frank F, Josh B, Carmine J and Louis M. Trigeminal Neuralgia and Endodontically Treated Teeth. *J Endod* 1988;14(7):360-62.
7. Regina S, Claudio J, Jacobsen M. Idiopathic trigeminal neuralgia: Clinical aspects and dental procedures. *Oral Surg Oral Med Oral Pathol Oral Radiol Endod* 2004;98:311-5.
8. Alan S, Jeffrey P. L, Iowa C. Trigeminal neuralgia mimicking odontogenic pain – a report of two cases. *Oral Surg Oral Med Oral Pathol Oral Radiol Endod* 1995;80:96-100.
9. Ceena D.E, Jeena P.K.O. Trigeminal neuralgia: Current concepts in medical management. *World journal of dentistry*, April- June 2010;1(1):43-6.
10. Edmond T. Management issues of neuropathic trigeminal pain from a dental perspective. *J Orofacial pain*. 2004;18(4) 374-80.
11. Jens C T. Trigeminal neuralgia versus atypical facial pain. *Oral Surg Oral Med Oral Pathol Oral Radiol Endod* 1996;81:424-32.
12. Lipton JA, Ship JA, Larach-R.D: Estimated prevalence and distribution of reported orofacial pain in the United States. *J Am Dent Assoc* 1993;124:115-21.

**How to cite this article:** Khushbu Ajmera, Sanjyot Mulay. "Non-Odontogenic Toothache – A Clinical Dilemma". *Int J Sci Stud*. 2014;2(3):90-93.

**Source of Support:** Nil, **Conflict of Interest:** None.