

Rapidly Enlarging Swelling of Upper Lip: A Rare Case Report

Neeraj Singh¹, Ishank Singhal², Pradakhshana Vijay³, Amit Gupta⁴, Jinender Jain⁵, Gaurav Bharadwaj⁶

¹Consultant, Department of Oral and Maxillofacial Surgery, Indraprasth Apollo Hospital, New Delhi, India, ²Post-graduate Student, Department of Oral and Maxillofacial Surgery, NIMS Dental College, Jaipur, Rajasthan, India, ³Post-graduate Student, Department of Oral and Maxillofacial Pathology, NIMS Dental College, Jaipur, Rajasthan, India, ⁴Reader, Department of Oral and Maxillofacial Surgery, NIMS Dental College, Jaipur, Rajasthan, India, ⁵Professor and Head, Department of Oral and Maxillofacial Surgery, Kalka Dental College, Meerut, Uttar Pradesh, India, ⁶Senior Lecturer, Department of Oral and Maxillofacial Surgery, NIMS Dental College, Jaipur, Rajasthan, India

Abstract

Squamous cell carcinoma (SCC) is a malignant tumor which arises from the keratinizing cells of the epithelium or epidermis. It grows slowly, shows local invasion with the potential to metastasize other organs of the body. We report an unusual case of a rapidly enlarging swelling on the upper lip of a 56-year-old male patient, which was suspected to be malignant melanoma on the basis of clinical presentation. But, it was histopathologically confirmed as moderately differentiated SCC. Rapidly enlarging skin lesions pose great challenges in the management. As the lesions are rapidly increasing in size, they eliminate the first-line reconstructive options that can compromise aesthetic and functional outcomes. Accurate histological diagnosis prior to surgery is important, as it has an impact on the excision margins. Early referral to a specialist is essential to avoid any need for a more invasive procedure and associated morbidity.

Keywords: Dissection, Lesion, Reconstruction

INTRODUCTION

Lips reveal a heterogeneous group of lesions ranging from developmental, inflammatory, ulcerative and neoplastic conditions. The neoplastic conditions include papilloma, fibroma, lipoma, salivary gland tumors, hemangioma, keratoacanthoma, squamous cell carcinoma (SCC), melanoma and Kaposi's sarcoma etc.,¹ Most common benign tumor of upper lip is canalicular adenoma and lower lip is mucocele. Most common malignant tumor of upper lip is basal cell carcinoma and lower lip is SCC.² We are reporting a case of rapidly enlarging ulcerative swelling of upper lip in a 56-year-old male patient which was thought to be melanoma due to its location and color, but histopathologically was diagnosed as moderately differentiated SCC.

CASE REPORT

A 56-year-old male patient presented to us with a chief complaint of swelling of the upper lip since 2 months. Patient complained of a painless small swelling of the upper lip 2 months back, which gradually increased to present size. The medical history was non-contributory. Patient had the habit of khaini eating with a frequency of 6-7 times a day since 20 years. Now, patient had discontinued the habit.

Local examination showed a solitary, ill-defined swelling, oval in shape, in the center of upper lip measuring 3.5 cm × 3 cm in dimension, extending from midline till the left commissures and intraorally into gingivobuccal sulcus, without involving gingival mucosa. Surface of swelling was covered by a blackish brown slough, which on removal revealed ulcerated mucosa.

The swelling was non-tender and painless, hard in consistency, non-fluctuant, indurated, and fixed to underlying structures. Submandibular and deep cervical lymph nodes were palpable and enlarged, hard in consistency and fixed to underlying structures (Figures 1 and 2).

Access this article online



www.ijss-sn.com

Month of Submission : 12-2014
Month of Peer Review : 02-2015
Month of Acceptance : 02-2015
Month of Publishing : 03-2015

Corresponding Author: Dr. Ishank Singhal, Department of Oral and Maxillofacial Surgery, NIMS Dental College, Jaipur, Rajasthan, India.
Phone: +91-9783956242. E-mail: doc.singhalishank@gmail.com

Radiological findings of computerized tomography (CT) scan revealed an ulcerative ill-defined lesion involving upper lip measuring 3.5 cm × 3.5 cm × 1.8 cm. Lesion extended into gingivobuccal sulcus but did not involve gingival mucosa. No bony erosion of maxillary alveolar arch was noted. Left Level I, II and III nodal lesion with peripheral enhancement and central necrosis seen measuring 2.8 cm × 1.8 cm × 1.6 cm (Figure 3).

Differential diagnosis included keratoacanthoma as it is the most common lesion of upper and lower lip. Canalicular adenoma was also considered as it commonly involves the upper lip. Basal cell carcinoma was also included. But it mostly involves upper 1/3rd of the face. Melanoma is pigmented lesion with rapid growth, and since the present case also had rapid growth, with pigmented appearance. Oral SCC though mostly involves the lower lip was also considered based on the habit of khaini eating and age of the patient. Based on the clinical and radiographic finding, provisional diagnosis of malignant melanoma was made.

An incisional biopsy was initially done, which histopathologically diagnosed it as well differentiated SCC. Later, excision of the lesion along with healthy margins with functional neck dissection followed by lip reconstruction using a double layer flap was done under general anesthesia. The excised specimen was sent to the department of oral pathology (Figure 4).

Gross examination revealed a soft tissue piece measuring 4 cm × 3 cm in diameter, irregular in shape, firm in consistency, grayish black in colour. Histopathologically, H and E stained section showed sheets of highly anaplastic epithelial cells with vesicular and pleomorphic nuclei. Few epithelial and keratin pearls were seen. Ortho-keratinized stratified squamous epithelium with hair follicle and sebaceous gland was also seen. The overall histopathological features were diagnostic of moderately differentiated SCC.

Post-operative findings showed clear margins and the patient recovered well. He maintained oral competence without microstomia and his speech was not affected (Figure 5).

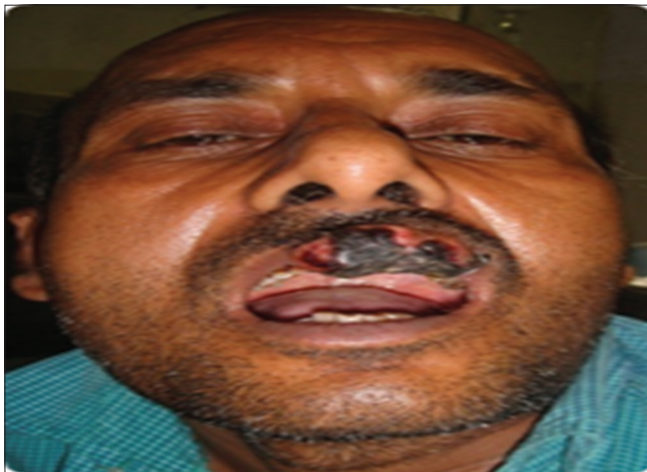

Figure 1: Pre-operative picture of patient

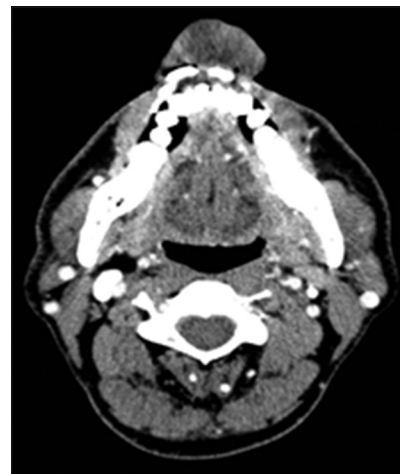


Figure 3: Computed tomography showing an ulcerative lesion involving upper lip measuring 3.5 cm × 3.5 cm × 1.8 cm

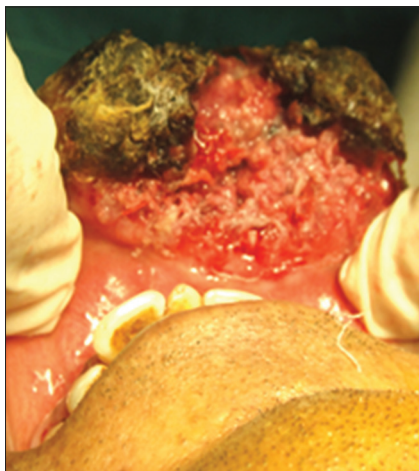

Figure 2: The close-up of lesion

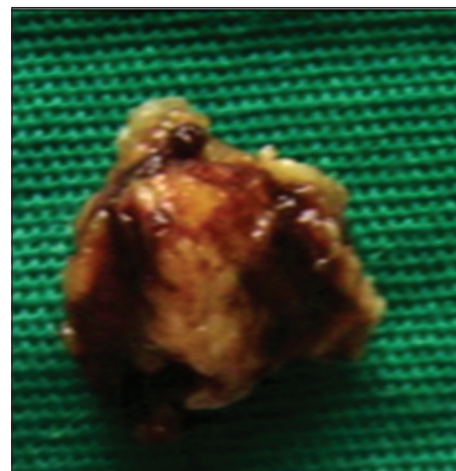


Figure 4: Removed specimen after surgery

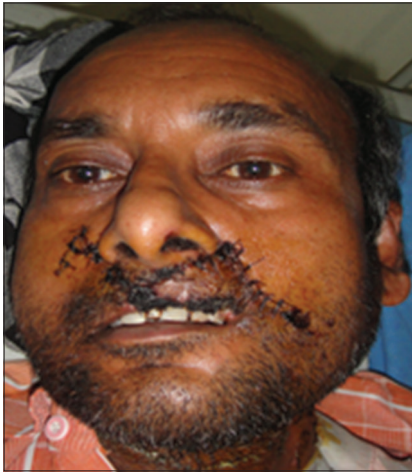

Figure 5: Post-operative picture of patient

DISCUSSION

SCC is defined as a malignant epithelial neoplasm exhibiting squamous differentiation as characterized by the formation of keratin and presence of intercellular bridges as defined by Pindborg (1997). Most common malignant neoplasm of the oral cavity. SCC of the lip is a disease of elderly men.² SCC of upper lip are histologically more undifferentiated and grow more rapidly, and lymphatic metastasis occurs earlier and is more diffuse in carcinoma of upper lip than lower lip.³ Age affected is between 55 and 75 years of age with a mean of 62 years. SCC of lower lip affects 95% males while as in upper lip SCC - females are affected more often compared to males. Upper lip SCC occurs with a frequency of 3.3 %.⁴

Variation in clinical appearance of lip cancer depends on duration of lesion and nature of growth. Begins on the vermillion border of the lip to one side of the midline as a small area of thickening, induration, and ulceration. As the lesion becomes larger, it produces small crater like defect or exophytic, proliferative mass.⁴ Lymphatic drainage through upper lip proceeds from periparotid trunk to pre-auricular, post-auricular, infra parotid and submandibular nodes. Metastasis from carcinoma of upper lip is frequently found in pre-auricular and infraparotid nodes.³ In the present case tumor/node/metastases grading was T2 N1 M0. CT and magnetic resonance imaging supplement the clinical evaluation, staging of the primary tumor and inform about the local extent of the disease and to identify lymph node metastases. But, final diagnosis is made by a histopathological evaluation only.^{5,6}

Histopathologically classified as following according to broder:⁷

Grade I: Well-differentiated tumors - 75-100% of cells are differentiated

Grade II: Moderately differentiated tumors - 50-75% of cells are differentiated

Grade III: Poorly differentiated tumors - 25-50% of cells are differentiated

Grade IV: Anaplastic tumor - 0-25% of cells are differentiated.

Treatment can be surgical excision or X-ray radiation depending on duration and extent of lesion and presence of metastasis.⁸ Early stage lesions can be treated with surgical or radiation therapy with similar 5 years survival rates. Late stage lesions fare poorly with radiation alone. Some drawbacks to radiation therapy, however, include a prolonged treatment course and the potential for whistle deformity of the lips after wound contracture. Osteoradionecrosis is also a potential complication from primary radiotherapy.⁹ Cure rate of patient with lip cancer treated by surgery is 81%. Cases treated with X-ray radiation have 83% cure rate.¹⁰

CONCLUSION

Early diagnosis is the key to optimal management of cancer of the lip. For carcinomas of the lip, surgical resection with adequate margins is the preferred treatment. Any suspicious lesion should be biopsied to establish the diagnosis.

REFERENCES

1. Wood NK, Goaz PW. Textbook of Differential Diagnosis of Oral Lesion. 5th ed. USA: Mosby; 1997. p. 561-78.
2. Rajendran R, Sivapathansundaram B. Shafer's Textbook of Oral Pathology. 5th ed. New Delhi: Elsevier; 2006. p. 143-55.
3. Knabel MR, Koranda FC, Panje WR, Grande DJ Squamous-cell carcinoma of the upper lip. J Dermatol Surg Oncol 1982;8:487-91.
4. Sapp JP, Eversole LR. Sapp Textbook of Oral Pathology. 2nd ed. China: Mosby; 2004. p. 184-96.
5. Regezi JR, Scubba JJ, Jordan CK. Regezi Textbook of Oral Pathology. 4th ed. USA: Saunders; 2003. p. 398.
6. Scully C, Bagan J. Oral squamous cell carcinoma overview. Oral Oncol 2009;45:301-8.
7. Cross JE, Guralnick E, Daland EM. Carcinoma of the lip; A review of 563 case records of carcinoma of the lip at the pondville hospital. Surg Gynecol Obstet 1948;87:153-62.
8. Widman BP. Cancer of lip. Am J Roentgenol Radium Ther Nucl Med 1950;63:13.
9. Lesavoy MA. Lip deformities and their reconstruction. In: Lesavoy MA, editor. Reconstruction of the Head and Neck. Baltimore: William & Wilkins; 1981. p. 95.
10. De Visscher JG, van den Elsaker K, Grond AJ, van der Wal JE, van der Waal I. Surgical treatment of squamous cell carcinoma of the lower lip: Evaluation of long-term results and prognostic factors – a retrospective analysis of 184 patients. J Oral Maxillofac Surg 1998;56:814-20.

How to cite this article: Singh N, Singhal I, Vijay P, Gupta A, Jain J, Bharadwaj G. Rapidly Enlarging Swelling of Upper Lip: A Rare Case Report. Int J Sci Stud 2015;2(12):172-174.

Source of Support: Nil, **Conflict of Interest:** None declared.