

# Gaze Palsy with Diplopia in Hyper Homocysteinemia: A Rare Neuro-ophthalmic Presentation

Sandhya Ramachandra<sup>1</sup>, Shruti Singh<sup>2</sup>, Sahana P Raju<sup>3</sup>

<sup>1</sup>Professor and Head, Department of Ophthalmology, Sri Siddhartha Medical College, Tumkur, Karnataka, India, <sup>2</sup>Resident, Department of Ophthalmology, Sri Siddhartha Medical College, Tumkur, Karnataka, India, <sup>3</sup>Independent Researcher, Karnataka, India

## Abstract

Diagnosis of gaze palsy is indeed a challenging task. This is a masquerade of a serious neurological disorder, probable yet to have full-blown manifestation. It is imperative that only a high index of suspicion can lead to prompt referral and mitigate life-threatening complications. It requires quick ophthalmic evaluation and prompt neurological referral. From the perspective of an ophthalmologist, a high index of suspicion and a thorough knowledge of neuro-ophthalmology are basic prerequisites. The extraocular muscle involvement, if localized based on other associated features, can aid rapid diagnosis. Here, we present a case of 34-year-old male patient presented to ophthalmology Outpatient Department in February 1<sup>st</sup> week, with complaints of diplopia since 1 day.

**Key words:** Cerebrovascular accident, Diplopia, Gaze palsy, Homocysteinemia, Pontine infarct

## INTRODUCTION

Diplopia may be the harbinger of serious neurological pathology. A patient presenting to ophthalmology outpatient with acute diplopia may be on the verge of a life-threatening cerebrovascular accident (CVA). They may be otherwise healthy adults, presenting to ophthalmology outpatient as they are seriously disturbed by the double vision.

## CASE REPORT

A 34-year-old male patient presented to Ophthalmology Outpatient Department in February 1<sup>st</sup> week, with complaints of diplopia since 1 day. No other ocular complaints were reported. Attendant complained of cross-eyed look while staring, on and off in the last couple of days. The patient was not a smoker or alcoholic.

## On Examination

Visual acuity was 6/6 N6 both eyes, with normal color vision. Adnexal and anterior segment examination were normal bilaterally. Hirschberg corneal reflex revealed normal ocular posture. The pupillary reaction was normal - To direct and consensual reflexes, accommodation reflex was present, both eyes. Extraocular movements were full and normal unilaterally, with physiological nystagmus at extremes of gaze, in both eyes. However, the versions were abnormal. Both dextro and levo versions showed variable and inconsistent movements; sometimes, there was a limitation of movement in the abducting eye and sometimes in the adducting eye. Convergence could not be elicited due to diplopia in the primary position. Uncover test revealed esophoria in both eyes, but the disturbing diplopia in primary gaze caused inconsistent findings on repetition. 3<sup>rd</sup>, 4<sup>th</sup>, and 6<sup>th</sup> cranial nerve examinations were essentially normal. Slit lamp examination was essentially normal, with intraocular pressure of 14 mm of Hg in both eyes.

Diplopia charting was done. The result is as follows:

Diplopia charting could not localize the extraocular muscle; it was present even in primary gaze.

### Access this article online



www.ijss-sn.com

Month of Submission : 01-2016  
Month of Peer Review : 02-2016  
Month of Acceptance : 02-2016  
Month of Publishing : 03-2016

**Corresponding Author:** Dr. Shruti Singh, Sri Siddhartha Medical College, Tumkur, Karnataka, India. Phone: +91-9049663100.  
E-mail: dr.singh00@yahoo.co.in



Fundus examination revealed sectoral disc edema; superonasally, in both eyes. Induced venous pulsations were present (Figures 1 and 2).

General physical examination; the patient was lanky with marfanoid features - Arm span greater than height (Figure 3). No arachnodactyly was present. Systemic examination was otherwise normal.

On further questioning, the patient complained of mild dysarthria and ataxia described by the patient as a sensation of “trembling.” The presence of normal

duction with abnormal horizontal and vertical vergences, a clinical diagnosis of GAZE PALSY was made: Multiple sclerosis was the chief suspicion, as the probable cause of the anomaly. The patient was referred to physician and neurologist immediately with a warning of a possible CVA.

Physician and neurologist referral opined a possible cerebrovascular event and opined that a space occupying lesion is to be ruled out. ENT opinion was sought, found normal.

## Management

### Investigations

Routine blood and urine investigations were normal. Serum homocysteine was found to be  $>65 \mu\text{mol/L}$  (accepted adult levels  $>30 \mu\text{mol/L}$ ). Magnetic resonance imaging (MRI) brain revealed infarct in the dorsal pons and midbrain involving the peri-aqueductal region. Hyperintense spot in the right maxillary sinus was opined as “antral cyst” by the ENT specialist (Figures 4 and 5).

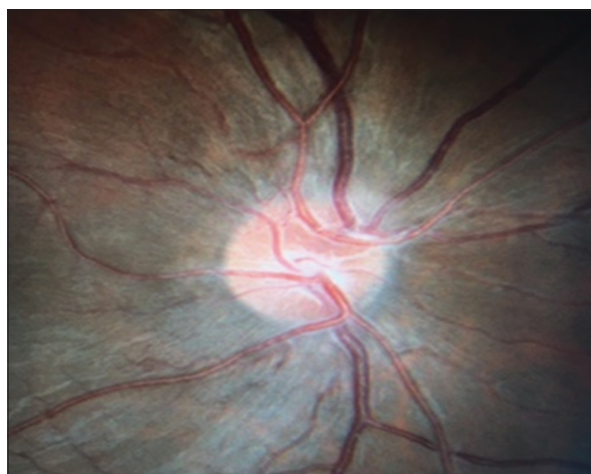


Figure 1: Fundus picture of right eye showing sectoral disc edema, superonasally

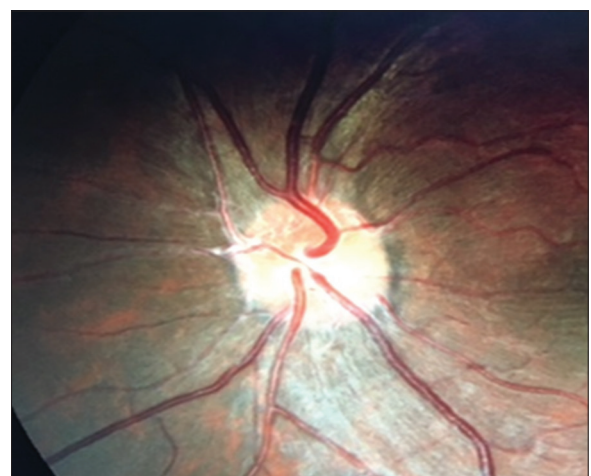

Figure 2: Fundus picture of left eye showing sectoral disc edema, superonasally




Figure 3: Patient showing increased arms span

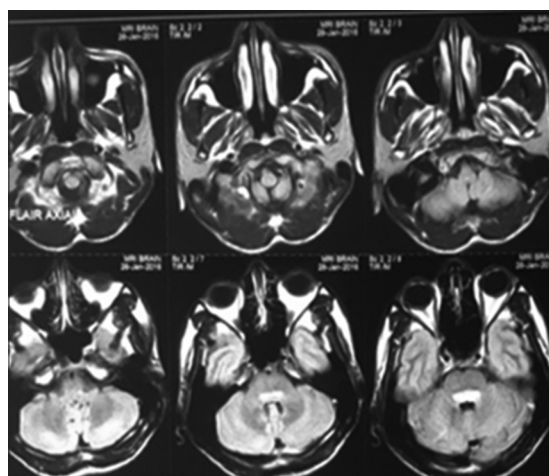
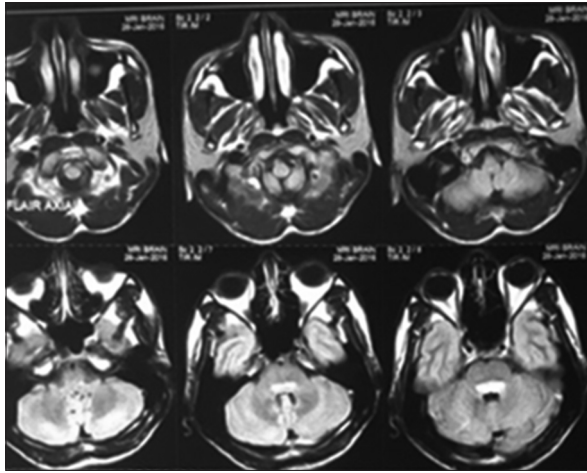


Figure 4: Magnetic resonance imaging brain showing hyperintense spot in right maxillary sinus



**Figure 5: Magnetic resonance imaging brain with infarct in dorsal pons and midbrain**

The patient was put on oral anti-coagulants clopidogrel 75 mg and ecosprin 75 mg, B6, folic acid, Vitamin B12 supplementation by the neurologist. The patient was advised limited physical activity, vegetarian diet with plenty of green leafy vegetables, a low sulfur and low protein diet.

The patient had clinically normal cardiovascular system but was advised echocardiogram.

On follow-up, at 3 weeks, the diplopia had resolved, the patient reported a general sense of well-being.

## DISCUSSION

Diagnosis of gaze palsy is indeed a challenging task. This is a masquerade of a serious neurological disorder, probable yet to have full-blown manifestation. It is imperative that only a high index of suspicion can lead to prompt referral and mitigate life-threatening complications. Less than 10% of the patients with pontine lesions present with negligible motor deficits but predominantly sensory syndrome, disorders of eye movement or vestibular symptoms.<sup>1</sup>

Homocysteinemias are seven biochemically and clinically distinct disorders characterized by abnormally elevated concentrations of sulfur-containing amino acid derivative homocysteine in blood and urine. Classic homocystinuria/homocysteinemia, familiar to the ophthalmologist is the most common form: Caused by the reduced activity of pyridoxal phosphate-dependent enzyme cystathionine  $\beta$  synthetase. The enzyme is required for the formation of cystathionine by condensation of homocysteine with serine. Most cases present between 3 and 5 years of age with ectopia lentis, mental retardation; marfanoid habitus and osteoporosis are some of the associated features. Life-threatening

vascular complications occur during the 1<sup>st</sup> decade of life. Diagnosis is established by elevated methionine and free homocysteine levels.

Type I or classic homocystinuria with autosomal recessive inheritance is an entity well recognized by ophthalmologists and is associated with early degeneration of zonules due to the deficiency of cysteine (present in high quantities in zonules) is the cause of early loss of accommodation and lenticular subluxation. Ectopia lentis is seen in more than 95% of untreated cases. Secondary angle closure due to papillary block may occur. Marfanoid habitus but infrequent arachnodactyly. Neurodevelopmental delay, mental handicap, psychiatric disturbances, and osteoporosis are the usual associations. Thrombosis in any vessel at any age - Post-operative/post-partum. Treatment involves oral pyridoxine, folic acid, and Vitamin B12 to reduce plasma homocysteine and methionine levels. Pathogenesis is attributed to decreased hepatic activity of cystathionine beta-synthetase, resulting in systemic accumulation of homocysteine and methionine.<sup>2</sup> Iris atrophy, optic atrophy, cataract, corneal opacity, myopia, and RD are known to occur in congenital homocystinuria.<sup>3</sup> Furthermore, maculopathy and retinal degeneration have been noted.<sup>4</sup>

Most of the literature emphasizes the inferonasal subluxation of the lens as the major ocular manifestation. Early-onset progressive myopia with ectopia lentis and systemic association - myopia plus are high alert signs of homocysteinemia. Skeletal, vascular and central nervous system (CNS) manifestations are the other well-established associations.<sup>5</sup> Neurodegeneration and epilepsy are known CNS complications.<sup>6</sup> Although in some cases, CNS involvement in the form of mild proprioceptive deficits and sensory neuropathy, extra pyramidal signs, normal acoustic function and central motor system were reported. MRI changes noted were focal white matter gliosis, generalized cortical atrophy, and cortical infarct only in one case.<sup>7</sup> In the present case, the central motor system was involved, in the form of a supranuclear gaze palsy.

The other forms of homocystinuria, including adult onset types, may be due to the (1) Defective Methionine synthase enzyme, (2) reduced availability of 2 co-factors 5- methyl tetrahydrofolate and methycobalamin.<sup>8</sup> Hyper homocysteinemia or increased free homocysteine levels in seen in heterozygotes for the genetic defects results coronary, cerebrovascular, peripheral arterial disease and deep vein thrombosis in adult life, such as this case. Vitamin supplements are helpful in reducing the plasma homocysteine levels.<sup>9</sup> Increased risk of coronary artery disease, stroke, and thromboembolism, Alzheimer's disease, schizophrenia, cognitive deficiency, osteoporosis,



venous thrombosis, pregnancy-related complications are associated with hyper homocysteinemia. Vitamin B6 supplementation is found effective in such cases. Patient was given supplementation of B6.<sup>10</sup>

Vascular occlusions in young adults may be associated with systemic genetic, biochemical disorders. However, there are no specific Indian studies to understand the association between cerebrovascular occlusions and disorders with biochemical abnormalities as a part of a genetic syndrome or otherwise. An interesting fact is that, in contrast to the west, a much higher incidence of 52-84% prevalence of homocysteinemia has been reported in Indian studies, among the general population.<sup>11</sup>

Others are more common and are treated with folate, Vitamin B12 and in selected cases as in methionine synthase deficiency, methionine, avoiding excess plasma accumulation of homocysteine.<sup>12</sup> Furthermore, elevated plasma levels of homocysteine are strong, graded, independent risk factor for stroke, myocardial infarction, and other vascular events.<sup>2</sup>

## CONCLUSION

This case presented a unique challenge because of its unusual presentation and incidental detection of homocysteinemia. It is atypical because of the adult onset and the absence of other features of congenital homocysteinemia (except for marfanoid habitus) on one hand; the CNS manifestations and presentation almost a decade earlier for classical adult onset type, on the other

hand. The patient is on regular follow-up: Advised more investigations, once he is able to afford them. The high risk of cardiovascular disease was explained to the patient. A karyotyping, examination of family members may give a better insight to the understanding of this biochemical abnormality.

## REFERENCES

1. Kumral E, Bayülkem G, Evyapan D. Clinical spectrum of pontine infarction. Clinical-MRI correlations. *J Neurol* 2002;249:1659-70.
2. Spence JD, Bang H, Chambless LE, Stampfer MJ. Vitamin Intervention For Stroke Prevention trial: An efficacy analysis. *Stroke* 2005;36:2404-9.
3. Kanski J, Bowling B. Synopsis of Clinical Ophthalmology. St. Louis, Mo: Saunders; 2013.
4. Tsina EK, Marsden DL, Hansen RM, Fulton AB. Maculopathy and retinal degeneration in cobalamin C methylmalonic aciduria and homocystinuria. *Arch Ophthalmol* 2005;123:1143-6.
5. Cruysberg JR, Boers GH, Trijbels JM, Deutman AF. Delay in diagnosis of homocystinuria: Retrospective study of consecutive patients. *BMJ* 1996 26;313:1037-40.
6. Available from: <http://www.European Journal of Pediatrics March 1998, Volume 157, Supplement.> [Last accessed 2016 Feb 23].
7. Valk J, Barkhof F, Scheltens P. Magnetic Resonance in Dementia. Berlin: Springer; 2002.
8. Harrison T, Wiener C, Brown C, Hemnes A. Harrison's Principles of Internal Medicine. New York: McGraw-Hill Medical; 2012.
9. Ramakrishnan S, Sulochana KN, Lakshmi S, Selvi R, Angayarkanni N. Biochemistry of homocysteine in health and diseases. *Indian J Biochem Biophys* 2006;43:275-83.
10. Available from: <http://www.douglaslabs.ca/pdf/nutrinenews/The%20Homocysteine%20Threat.pdf>. [Last accessed on 2016 Feb 24].
11. Refsum H, Yajnik CS, Gadkari M, Schneede J, Vollset SE, Orning L, *et al.* Hyper homocysteinemia and elevated methylmalonic acid indicate a high prevalence of cobalamin deficiency in Asian Indians. *Am J Clin Nutr* 2001;74:233-41.
12. Sainani GS, Talwalkar PG, Wadia RS, Keshvani AA. Hyperhomocysteinemia and its implications in atherosclerosis the Indian scenario. *Med Update* 2007;17:11-20.

**How to cite this article:** Ramachandra S, Singh S, Raju SP. Gaze Palsy with Diplopia in Hyper Homocysteinemia: A Rare Neuro-ophthalmic Presentation. *Int J Sci Stud* 2016;3(12):316-319.

**Source of Support:** Nil, **Conflict of Interest:** None declared.