

Midgut Carcinoid Tumor in an Elderly Female: A Rare Case Report

M R Shanker¹, Geetha Avadhani², V Edwine³, K Arun³, S Prajwal⁴

¹Associate Professor, Department of Surgery, Adichunchanagiri Institute of Medical Sciences, Mandya, Karnataka, India, ²Professor, Department of Surgery, Adichunchanagiri Institute of Medical Sciences, Mandya, Karnataka, India, ³Post-graduate, Department of Surgery, Adichunchanagiri Institute of Medical Sciences, Mandya, Karnataka, India, ⁴Under-graduate, Department of Surgery, Shyamnur Shivshankarappa Institute of Medical Sciences and Research Centre, Davangere, Karnataka, India.

Abstract

Neuroendocrine tumors arise from diffuse endocrine system of the gastrointestinal system. They arise from amine precursor uptake decarboxylation cells, which can be found distributed throughout the gastrointestinal system. They show differential growth pattern varying from benign and well differentiated (tumors) to poorly differentiated malignant (carcinomas). Those arising from the gut have been collectively termed as carcinoid tumors. They are mostly asymptomatic. They may be detected incidentally or present as mass abdomen. The secreting tumors present with symptoms of hormone they secrete. They are rare (1.9/1,00,000 population) and overall form <2% of gastrointestinal tumors. We present one such rare case of midgut carcinoid in an elderly female who presented with mass abdomen.

Keywords: Carcinoid tumor, Elderly female, Midgut, Neuroendocrine tumor

INTRODUCTION

Carcinoids are usually slow-growing neuroendocrine tumors arising in the gastrointestinal tract, respiratory tract, thymus, testis or ovary. They are APUDomas with cells of origin in argentaffin cells (dark stain with silver stain) or enterochromaffin cells (yellowish brown stain with chromate salts), which are found in a small intestine. They are mostly asymptomatic. Initial presentation may be in the form of mass or secretory symptoms of carcinoid syndrome due to secretion of serotonin (5-hydroxytryptamine) mainly, which is metabolized in liver, lung and brain to 5-hydroxyindoleacetic acid (5-HIAA), and excreted in urine. The measurement of 24 h urinary 5-HIAA and chromogranin (Cg A) are important tools for initial diagnosis and later follow-up of carcinoid tumor. Unusual manifestations of gastrointestinal carcinoids may be excessive gastrointestinal bleeding or cardiac

manifestations.¹ Surgical excision forms the cornerstone of therapy, curative in early stages, and cytoreductive in later stages. Endoscopic resection of the tumor may be done in selected cases.² Radio-active ablation and chemotherapy have some role in controlling metastatic disease. Somatostatin analogues (Octreotide and lanreotide) are used to control symptoms of carcinoid syndrome.³ Hepatic artery embolization has been used to control hepatic metastasis.^{4,5} With increasing diagnosis, newer modalities of treatment have come into practice with better control of the disease.⁶

CASE REPORT

A 72-year-old female presented with frequent episodes of loose stools and pain abdomen of about 2 years duration and mass abdomen of 1-year duration. She had no other symptoms attributable to cardio-respiratory system or history of flushing. General physical examination was unremarkable. A 12 cm × 10 cm size globular freely mobile non-tender, cystic intra-abdominal mass with a nodular surface was found occupying umbilical region mainly and extending to epigastric and left hypochondriac regions. Liver and spleen were not palpable and no ascites was found. Abdominal ultrasonography (USG) and computed tomography (CT) scan revealed a well-defined

Access this article online



www.ijss-sn.com

Month of Submission : 01-2015
Month of Peer Review : 01-2015
Month of Acceptance : 02-2015
Month of Publishing : 03-2015

Corresponding Author: Dr. M R Shanker, 4544, 16th Main, Vijayanagar - 2nd stage, Mysore - 570 017, Karnataka, India.
 Phone: +91-9449044110. E-mail: coldmrshanker@yahoo.com

thick walled predominantly cystic intraperitoneal mass of 10 cm × 09 cm size in close proximity to jejunum and its mesentery, extending into root of small intestinal mesentery (Figure 1).

Exploratory laparotomy revealed a large mass in small intestinal mesentery and another smaller mass in close proximity to intestine. There were no metastatic deposits in the liver. Complete excision of mass along with about 70 cm of a small intestinal coil and its mesentery was carried out (Figure 2). Abdomen was closed after peritoneal toilet. Post-operative recovery was uneventful. Cut surface of the intestine showed a well-circumscribed grey-white soft to firm tumor mass. Cut surface was grey-white to grey brown. Section studied showed a tumor composed of cells arranged in an organoid, trabecular, and ribbon-like pattern separated by thin fibrovascular septatae. Tumor cells were round and uniform with a moderate amount of eosinophilic granular cytoplasm, which was vacuolated at

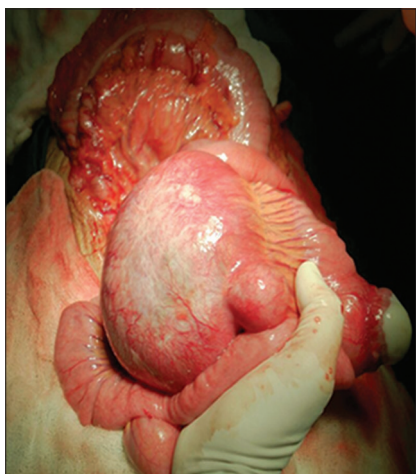


Figure 1: Per-operative appearance of the tumor arising from the jejunum with mesenteric lymph node metastasis

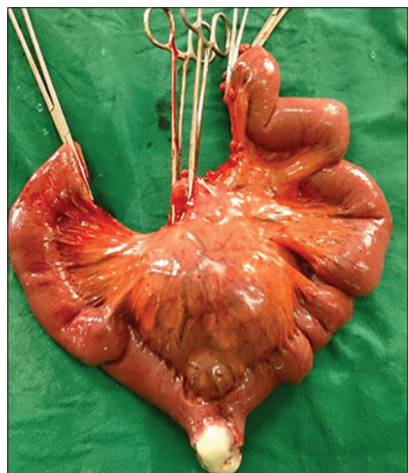


Figure 2: Specimen of the tumor along with coil of small gut after resection

places. The tumor cells were seen to form pseudorosettes at places. Sections from adjoining mass showed a tumor with similar features.⁷ Section studied from mesenteric lymph nodes showed hemorrhagic areas extensively infiltrated by tumor cells with similar morphology. Also seen were areas of lymphovascular invasion.

Patient is planned for further follow-up with biological markers with the help of higher centers.

DISCUSSION

Siegfried Oberndorfer, a German pathologist (1907) coined the term “Karizinoide” (carcinoma like), unique benign growing tumors, for their benign growth in spite of their malignant appearance microscopically.⁸ Incidence reported is 1.9/1,00,000 and form 0.25% of total oncology load. They are found in 1 in 300 autopsies. They usually have a benign course, but some become aggressive and resistant to treatment. 40% of carcinoids occur in a small intestine, 96% of these in jejunum.^{9,10} In 2006 and 2010, Canadian consensus guidelines were published by a Canadian net expert group.^{11,12} Furthermore, in recent years, a number of European and North American groups have developed consensus guidelines for the diagnosis and management of well-differentiated gastroenterohepatic nets.^{13,14} Improvement in diagnostic modalities and management has improved the survival (67% - 5 years survival). They may be functioning (hormone secreting) or non-functioning. Functioning tumors produce carcinoid syndrome characterized by flushing, diarrhea, wheezing and peripheral edema due to secretion of serotonin.^{15,16} Our patient did not have classical symptoms of carcinoid syndrome except attacks of diarrhea. Associated attacks of pain abdomen in our patient may have been due to the fibrotic changes producing gut ischemia, (abdominal cramps) that are known to be caused as a result of desmoplastic reaction in mesentery due to excess of serotonin secretion.¹⁷ They may also give rise to intestinal obstruction, intussusceptions.¹⁸ or even distant fibrotic changes in the form of endomyocardial fibrosis, tricuspid insufficiency and pulmonary valvular disease giving rise to carcinoid heart failure which may be fatal. In addition to serotonin several other biologically active substances such as kallikrein, histamine, prostaglandins, adrenocorticotrophic hormone, gastrin, calcitonin, and growth hormone among others are secreted. As compared to carcinoids elsewhere, midgut carcinoids tend to produce carcinoid syndrome more often than others. Severity of symptoms depends on the size of tumor and extent of metastasis especially access of hormone to the systemic circulation bypassing portal circulation. Non-functioning tumors are asymptomatic and detected incidentally. Our patient did not have liver metastasis.

Biochemical markers are important tools in the diagnosis and follow-up of these patients. 5-HIAA, serotonin metabolite and Cg A are the two biochemical markers used for diagnosis and follow-up of these patients.^{19,20} 24 h urinary 5-HIAA is normally 3-15 mg and up to 45 mg is taken as normal by some laboratories. It has 73% sensitivity and 100% specificity. Cg found in the walls of vesicles containing serotonin and glucagon is elevated in 85-100% of patients with carcinoid tumors with a specificity of 98% and sensitivity of 62%.²¹ Ki 67 antigen protein present in the nucleus of proliferating cells is used as a prognostic marker along with mitotic index. Tumors with high value >2% of Ki 67 are likely to respond than those with low values (<2%). Antibodies to Ki 67 are reliable markers of cell proliferation. In our patient, biological markers could not be assessed due lack of facilities in our center. However, these studies are planned to be undertaken with the help of higher centers during follow-up of the patient.

Conventional imaging (USG, CT and magnetic resonance imaging) can be used to locate site and extent of tumor. Abdominal USG and CT scanning revealed the location and extent of tumor in our case. ¹¹¹In pentetreotide scintigraphy and ¹²³I or ¹³¹I Meta iodobenzylguanidine (MIBG) scintigraphy are used for identifying and staging.²² MIBG scans may be positive in 10% of cases with negative pentetreotide scan. Somatostatin analogue scans for tumor detection, are also used to control symptoms of carcinoid syndrome.

As per the recommendation, a basal octreoscan should be done before treatment and thereafter yearly, after curative resection. 03 monthly urinary 5-HIAA during 1st year and 6 monthly in 2nd year with yearly Cg A levels is also recommended along with imaging studies for follow-up.

WHO has classified gastrohepatic neuroendocrine tumors as:²³

- Well-differentiated NETs
 - Benign
 - Uncertain malignant potential
- Well differentiated neuroendocrine carcinomas
- Poorly differentiated neuroendocrine carcinomas.

Well-differentiated nets are often considered the “classical carcinoid” NETs and demonstrate a trabecular, insular, or ribbon-like architecture, minimal cellular pleomorphism and sparse mitotic activity. Well-differentiated neuroendocrine carcinomas (sometimes called “malignant carcinoids”) have increased cellular pleomorphism and mitotic activity and may have punctate necrosis. Poorly differentiated neuroendocrine carcinomas show marked cellular pleomorphism, fields of necrosis, and brisk mitotic activity. These can be histopathologically similar to small-cell lung

carcinoma.

Surgical treatment is curative for loco-regional disease. Tumor debulking provides good palliation in control of large tumors and metastatic disease. Prophylactic cholecystectomy should be considered in every patient undergoing surgery for NETs of the digestive tract. Our patient had already undergone cholecystectomy. This procedure mitigates the biliary toxicity of sulfosalicylic acid therapy and avoids chemical cholecystitis if transcatheter arterial chemoembolization is required to be performed in the future.²⁴

Medical management consists of administration of somatostatin analogues (octreotide) for functioning tumors. Interferon alfa helps in control of angiogenesis and improves immunity. Chemotherapy consisting of streptozocin with doxorubicin or fluorouracil have been used with limited effect in poorly differentiated carcinomas.²⁵

CONCLUSION

A rare case of midgut carcinoid in an elderly female with lump abdomen is reported. Whereas symptoms of diarrhea and abdominal cramps were only symptoms in addition to lump abdomen. Complete classical carcinoid syndrome was not noted in our patient. Hence, the possibility of carcinoid was not considered in our patient. The diagnosis was clear only after the histopathological examination. Studies of hormonal markers could have given more information about the functional status of the tumor. Since the tumor has been completely resected, further follow-up with imaging studies and biological markers need to be done to detect any recurrence or metastasis.

ACKNOWLEDGMENT

Authors would like to acknowledge the following:

- Dr A L Hemalatha, Professor and Head, Department of Pathology, Adichunchanagiri Institute of Medical Sciences, Mandya, Karnataka, India
- Dr B S Sathish Prasad, Professor and Head, Department of Pathology, Adichunchanagiri Institute of Medical Sciences, Mandya, Karnataka, India.

REFERENCES

1. Flaherty AM. Carcinoid heart disease. *Oncol Nurs Forum* 2014;41:687-91.
2. Longcroft-Wheaton G, Bhandari P. Endoscopic resection of submucosal tumors. *Expert Rev Gastroenterol Hepatol* 2015;1-11.
3. Strosberg JR, Benson AB, Huynh L, Duh MS, Goldman J, Sahai V, et al. Clinical benefits of above-standard dose of octreotide LAR in patients with neuroendocrine tumors for control of carcinoid syndrome symptoms: A

- multicenter retrospective chart review study. *Oncologist* 2014;19:930-6.
4. Swärd C, Johanson V, Nieveen van Dijkum E, Jansson S, Nilsson O, Wängberg B, *et al.* Prolonged survival after hepatic artery embolization in patients with midgut carcinoid syndrome. *Br J Surg* 2009;96:517-21.
 5. Sakamoto I, Aso N, Nagaoki K, Matsuoka Y, Uetani M, Ashizawa K, *et al.* Complications associated with transcatheter arterial embolization for hepatic tumors. *Radiographics* 1998;18:605-19.
 6. Rindi G, Petrone G, Inzani F 25 Years of neuroendocrine neoplasms of the gastrointestinal tract. *Endocr Pathol* 2014;25:59-64.
 7. Hirabayashi K, Zamboni G, Nishi T, Tanaka A, Kajiwara H, Nakamura N. Histopathology of gastrointestinal neuroendocrine neoplasms. *Front Oncol* 2013;3:2.
 8. Oberndorfer S. Karzinoide Tumoren des Dünndarms. *Frankfurt Zeitschrift für Pathologie* 1907;1:425-9.
 9. Schnirer II, Yao JC, Ajani JA. Carcinoid – a comprehensive review. *Acta Oncol* 2003;42:672-92.
 10. Modlin IM, Lye KD, Kidd M. A 5-decade analysis of 13,715 carcinoid tumors. *Cancer* 2003 15;97:934-59.
 11. Maroun J, Kocha W, Kvols L, Bjarnason G, Chen E, Germond C, *et al.* Guidelines for the diagnosis and management of carcinoid tumours. Part 1: The gastrointestinal tract. A statement from a Canadian National Carcinoid Expert Group. *Curr Oncol* 2006;13:67-76.
 12. Kocha W, Maroun J, Kennecke H, Law C, Metrakos P, Ouellet JF, *et al.* Consensus recommendations for the diagnosis and management of well-differentiated gastroenterohepatic neuroendocrine tumours: A revised statement from a Canadian National Expert Group. *Curr Oncol* 2010;17:49-64.
 13. Oberg K, Astrup L, Eriksson B, Falkmer SE, Falkmer UG, Gustafsen J, *et al.* Guidelines for the management of gastroenteropancreatic neuroendocrine tumours (including bronchopulmonary and thymic neoplasms). Part II-specific NE tumour types. *Acta Oncol* 2004;43:626-36.
 14. Plöckinger U, Rindi G, Arnold R, Eriksson B, Krenning EP, de Herder WW, *et al.* Guidelines for the diagnosis and treatment of neuroendocrine gastrointestinal tumours. A consensus statement on behalf of the European Neuroendocrine Tumour Society (ENETS). *Neuroendocrinology* 2004;80:394-424.
 15. National Comprehensive Cancer Network (NCCN). Clinical Practice Guidelines in Oncology. Neuroendocrine Tumours. Vol. 1. Jenkintown, PA: NCCN; 2010.
 16. Ramage JK, Davies AH, Ardill J, Bax N, Caplin M, Grossman A, *et al.* Guidelines for the management of gastroenteropancreatic neuroendocrine (including carcinoid) tumours. *Gut* 2005;54 Suppl 4:iv1-16.
 17. DeVita VT Jr, Hellman S, Rosenberg SA, editors. *Cancer: Principles and Practice of Oncology*. 6th ed. Philadelphia, PA: Lippincott Williams and Wilkins; 2001. p. 1813-33.
 18. Wiener-Carrillo I, González-Alvarado C, Cervantes-Valladolid M, Echaverry-Navarrete D, Zubieta-O’Farrill G, Gudiño-Chávez A. Intussusception secondary to a carcinoid tumor in an adult patient. *Int J Surg Case Rep* 2014;5:265-7.
 19. Bajetta E, Öberg K, Janson ET, Eriksson B. Tumour markers in neuroendocrine tumours. *Ital J Gastroenterol Hepatol* 1999;31 Suppl 2:S160-2.
 20. Eriksson B, Oberg K, Stridsberg M. Tumor markers in neuroendocrine tumors. *Digestion* 2000;62 Suppl 1:33-8.
 21. Bajetta E, Ferrari L, Martinetti A, Celio L, Procopio G, Artale S, *et al.* Chromogranin A, neuron specific enolase, carcinoembryonic antigen, and hydroxyindole acetic acid evaluation in patients with neuroendocrine tumors. *Cancer* 1999;86:858-65.
 22. Ganeshan D, Bhosale P, Yang T, Kundra V. Imaging features of carcinoid tumors of the gastrointestinal tract. *AJR Am J Roentgenol* 2013;201:773-86.
 23. Klöppel G, Perren A, Heitz PU. The gastroenteropancreatic neuroendocrine cell system and its tumors: The WHO classification. *Ann N Y Acad Sci* 2004;1014:13-27.
 24. Trendle MC, Moertel CG, Kvols LK. Incidence and morbidity of cholelithiasis in patients receiving chronic octreotide for metastatic carcinoid and malignant islet cell tumors. *Cancer* 1997;79:830-4.
 25. Kaltsas GA, Besser GM, Grossman AB. The diagnosis and medical management of advanced neuroendocrine tumors. *Endocr Rev* 2004;25:458-511.

How to cite this article: Shanker MR, Avadhani G, Edwine V, Arun K, Prajwal S. Midgut Carcinoid Tumor in an Elderly Female: A Rare Case Report. *Int J Sci Stud* 2015;2(12):197-200.

Source of Support: Nil, **Conflict of Interest:** None declared.