Print ISSN: 2321-6379
Online ISSN: 2321-595X
DOI: 10.17354/ijss/2018/75

Original Article

Functional Outcome of Primary Total Elbow Arthroplasty for Intra-articular Distal Humerus Fractures in Elderly Patients: A Prospective Study

Sudarsan Behera[1], Prasanta Kumar Saha[2], Sagnik Ray[3], Ananda Kisor Pal[4]

[1]Senior Resident, Department of Orthopaedics, All India Institute of Medical Sciences, Bhubaneswar, Odisha, India, [2]Associate Professor, Malda Medical College and Hospital, West Bengal, India, [3]Senior Resident, Department of Orthopaedics, Institute of Post Graduate and Medical Research and Seth Sukhlal Karmani Memorial Hospital, Kolkata, West Bengal, India, [4]Professor and Head, Department of Orthopaedics, Institute of Post Graduate and Medical Research and Seth Sukhlal Karmani Memorial Hospital, Kolkata, West Bengal, India

Abstract

Introduction: Treatment of fractures of distal humerus after the age of 50 years is challenging due to osteoporotic bone and comminution of the articular surface. Distal humerus has complex anatomy with limited options for internal fixation. Open reduction and internal fixation carry risks of loss of fixation, stiffness, infection, and non-union. Arthroplasty carries the risk of loosening, infection, and periprosthetic fractures. The aim is to study the functional outcome of primary total elbow arthroplasty (TEA) for intra-articular distal humerus fractures.

Design: This was an institution-based prospective study.

Patients: A total of 15 patients in the age group more than 50 years having distal humerus fractures that required surgical treatment with minimal clinical follow-up of 1 year were selected. All fractures were OTA classification 13.C2 or 13.C3. No patient lost the follow-up.

Intervention: We used Bakshi's sloppy hinge elbow prosthesis (3rd generation) as the intervention procedure.

Main Outcome Measurement: Mayo Elbow Performance Score was used.

Results: Among total elbow replacement group after 1 year, all the patients satisfied (14 excellent and 1 good result). No patients treated with TEA require revision surgery.

Conclusion: We recommend TEA which may be a viable option for intra-articular distal humerus fracture in the patients with age more than 50 years. Our study population is small and also the follow-up period is short. Further study with large population with longer duration follow-up is needed.

Key words: Distal humerus fracture, Old age patient, Total elbow arthroplasty

INTRODUCTION

Distal humerus are approximately one-third of all elbow injury (7%) which comprises around 2% of all adult fractures, 5% of osteoporotic stress fractures in subjects over the age of 60 with bimodal age of distribution[1-4] with peak incidences occurring between age 12 and 19 years usually in males, and those elderly 80 or elderly mainly in females. In the elderly, more than 60% of distal humerus fractures in elderly are due to low energy injuries like fall from standing height.[2,4]

The overall incidence of distal humerus is increasing mimicking the increasing incidence of hip, proximal humerus, and wrist fractures.[5-7] An aging population with increasing life expectancy combined with the fact that most of the fractures require surgical treatment which is likely to increase the health expenditure. Now, mainstay is to prevent fractures by screening for osteopenia and osteoporosis with bone mineral density and then to treat with medication.[6]

Access this article online

IJSS
www.ijss-sn.com

Month of Submission : 01-2018
Month of Peer Review : 02-2018
Month of Acceptance : 02-2018
Month of Publishing : 03-2018

Corresponding Author: Dr. Sudarsan Behera, Room No 201, Type IV Quarters, AIIMS Housing Complex, All India Institute of Medical Sciences, Bhubaneswar, Patrapara, Bhubaneswar, Odisha, India. Phone: +91-9692296970. E-mail: sudarsanctc@gmail.com

During old age, if any patient having comorbidity like immunological disease and chronic obstructive pulmonary disease which require steroid regularly further increase in the risk of osteopenia. Distal humerus fractures remain the most challenging injuries to manage due to multi fragmented and commonly seen in osteoporotic bone with complex anatomy of the elbow with limited options for internal fixation.

The treatment options for distal humerus fracture range from conservative management to operative management such as open or closed reduction with internal or external fixation and elbow arthroplasty surgery. Evans[8] in 1953 termed the mode of treatment "bag of bones" and thought appropriate for elderly patients but not ideal for young active patients. In last quarter of century, improved outcome surgery for distal humerus headed toward surgical management. The principles set out by AO association for the study of internal fixation group including anatomical articular reduction and rigid internal fixation which allows for healing and early post-operative motion after understanding anatomy, improved surgical approaches, new innovative fixation devices, and post-operative rehabilitation protocols, and the result of surgical management is increased.[9-11] However, in the elderly, restoration of anatomy and obtain rigid fixation may be difficult because of poor bone quality and comminution of articular surface and metaphysis. Hence, when rigid fixation not achieved to allow early range of motion, prolonged immobilization required leads to poor outcomes like stiffness. The failure of fixation may lead to non-union or implant failure leads to increased reoperation rate associated with open reduction and internal fixation (ORIF) may convert previously independent individual into a dependent. Total elbow arthroplasty (TEA) has been shown to offer a solution for post-traumatic deformities of the elbow, particularly for selected elder patients with articular fragmentation, comminution, and osteopenia.

To evaluate better the role of TEA as a definitive treatment solution for comminuted distal humeral fractures in older age group, we study the functional outcome of TEA. In developing country like India where physiological age is more than actual age, we have taken the age of more than 50 years for the study in contrast to the elder (age more than 65 years).

MATERIALS AND METHODS

This was an institution-based, prospective longitudinal study. The study was conducted in our institution after getting ethical permission. All the patients were counseled about the advantages, disadvantages, and complications of the procedure. After otaining written consent from patients, we performed total elbow arthroplasty (TEA) procedure. The study period was from December 2013 to November 2015 (24 months' duration).

Inclusion criteria of our study were patients above age 50 years of both sexes with isolated fresh or <90 days traumatic close comminuted distal humerus fracture with articular involvement or displaced or involving fracture with elbow dislocation. Exclusion criteria were age below 50 years, open fracture around elbow, previous history of sepsis, excessive use of elbow, neurotropic joint, poor functioning of flexor and extensor mechanism of elbow joint, and extensive loss on either side of elbow joint or severe comorbidity patients.

The surgical technique described by Baksi[12] was principally followed but with addition of an insertion technique of the humeral stem flanges of the new version of the sloppy hinge into the shaft of the humerus.[13,14] Patients were operated with supine position with the arm, forearm supported in the side table under general anesthesia/ brachial block, and full thickness flap developed medially and laterally, and then, the ulnar nerve was isolation done. Soft tissues around the medial epicondyle and the muscles from the fractured fragments of the anterior and posterior surfaces of the lower humerus were detached. The medial articular capsule was detached from the upper articular margin of the ulna. Further dissection was done laterally over the triceps posterior surface to reveal the lateral epicondyle and fractured lateral supracondylar ridge while soft tissue around them was separated. The distal humerus was sectioned transversely just proximal to the olecranon fossa and upper limit of fracture, and a subarticular L-shaped cut was made over the upper end of the ulna to explore its medullary canal, preserving triceps insertion over the olecranon process and brachialis in front of the coronoid process. Reaming of the ulnar and reaming of the ulnar and humeral medullary canals were done with a harpoon-shaped reamer and rasp for humerus triangular-shaped rasp and ulna quadrangular-shaped rasp to provide snug fitting of the prosthetic stems. A longitudinal groove of 13 mm was cut on each side of the lower end of the humerus [Figure 1] in its coronal plane, extending from its transverse cut end for seating of the humeral stem flanges. Trial implants were used to finalize actual implant size. Cementing was done manually with the help of a bladder wash syringe and tube. Elbow kept in flexed position, assembled sloppy hinge elbow prosthesis inserted both in humerus and ulna simultaneously is such a that both the humeral stem and ulnar stem was then snugly fitted within the medullary canal with the help of bone cement and humeral stem flanges seated in the corresponding longitudinal slots already

created over the sides of the humerus. Elbow kept in extension till cement sets [Figure 2]. Full range of elbow flexion and extension was tested. Triceps muscle repaired at insertion by drilling hole over the proximal ulna through which suture passed [Figure 3]. The wound was closed in layers, over a suction drain, around the prosthesis, and a well-padded compression bandage placed around the elbow. Splinting was done with a plaster slab in 30° flexion.

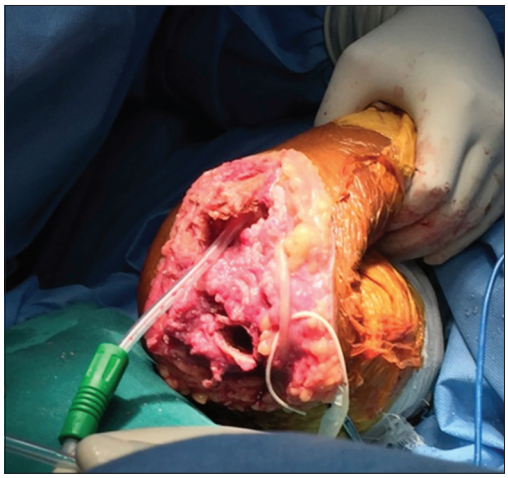

Figure 1: Ulnar and humerus after cut

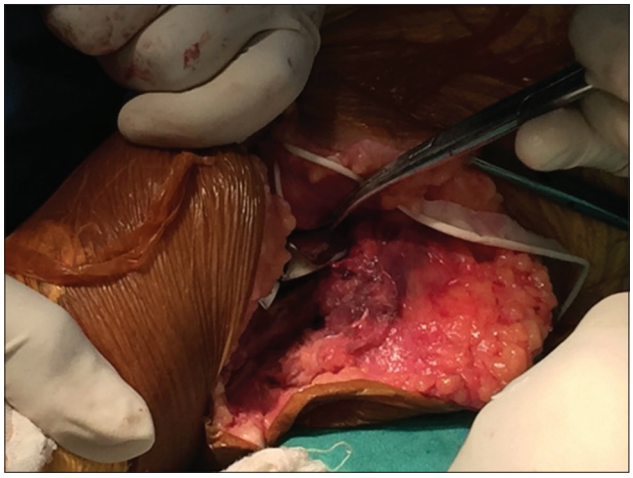

Figure 2: After inserting the Baksi slope hinge prosthesis

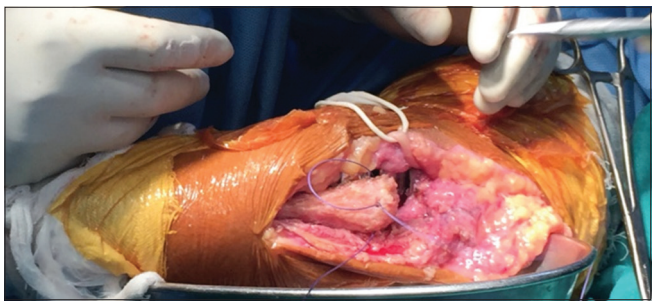

Figure 3: Triceps repair using drill hole in the proximal ulna

During the post-operative period, suction removed after 48 h, plaster slab removed after 5 days kept in turnbuckle splinting maximum flexion and extension 4 h in a day during 1st week, 3 h in next week, and then 2 h a day. Intermittent active and passive elbow movements were promoted out of the splint till satisfactory recovery of elbow motion. Removal of stitch done after 2 weeks and an elbow splint was used for 1 week, and if active elbow movements were free and painless, the splint was discarded. Weightlifting over 2½ kg and physically strenuous work with the replaced elbow were banned permanently.

All patients were evaluated at 4 weeks, then 2, 4, 8, 12, and 24 months, and periodically thereafter. However, if any patient complained of pain and increased local temperature around the elbow and limited post-operative elbow motion, he or she was instructed to see us at our follow-up clinic without delay. At each visit, we recorded Mayo Elbow Performance Score (MEPS), elbow and forearm range of motion, elbow stability, presence of any local pain, ability to carry out routine daily activities, overall subjective assessment of the outcome, and radiographic study of replaced elbow.

RESULTS

About 15 patients in the age group of more than 50 years were included in the group with mean age 61.5 years with 9 females and 6 males. Of 15 patients, 11 patients had left elbow affected and 4 patients right elbow affected with majority of right handed (14 right handed and 1 left handed). Out of 15 patients, two were diabetic, two were hypertensive, one was with both diabetes and hypertension while one had both hypertension and osteoporosis Table 1.

All the patients with distal humerus comminuted fracture humerus were treated with third-generation Baksi sloppy hinge elbow prosthesis. The mean interval between the injuries and the operation was 25 days (10–90 days). Among all the patients operated, 1 patient had superficial skin infection which was treated by oral antibiotics,1 patient ulnar neuropraxia which recovers within few days, 2 patients had post-operative hematoma treated by drain, and 1 patient had triceps weakness (IV/V) seen.

The mean post-operative arc of elbow motion (F/E) was 110 and 107 after 3 and 12 months' post-operative period, respectively. The mean range of elbow motion (F/E) at 3 month post operative period was 20 to 130° which was nearly equal to 12 month follow up period. The mean range of motion after 3 months and 12 months was 60% more than 100° and 40% between 50 and 100°. All the patients had >50 supination and pronation after 3 and 12 months.

Table 1: Patient, comorbidity, complications and follow up information including Mayo elbow performance scores at 3 and 12 months post-operative period

S no.	1	2	3	4	5	6	7	8	9	10	11	12	13	14	15
Age	53	60	65	70	60	56	58	71	63	59	53	60	56	65	73
Sex	M	F	M	F	F	M	F	F	M	F	F	M	M	F	F
Affected elbow	L	L	L	L	R	L	R	L	L	R	L	L	L	R	L
Dominant Hand	R	R	L	R	R	R	R	R	R	R	R	R	R	R	R
Duration of trauma in days	15	20	10	90	14	14	15	90	22	11	16	18	12	14	16
Comorbidity	HTN	DM	NIL	HTN+Osteo penia	NIL	NIL	NIL	DM+HTN	DM	NIL	NIL	NIL	NIL	NIL	HTN
Complications	NIL	Ulnar N.praxia	Hematoma	Hematoma	NIL	NIL	NIL	Infection	NIL	NIL	NIL	NIL	NIL	NIL	NIL
Post of power of biceps	5	5	5	5	5	5	5	5	5	5	5	5	5	5	5
Post of power of triceps	5	5	5	4	5	5	5	5	5	5	5	5	5	5	5
Post-operative of arc of elbow motion (F/E)[3]	100	120	100	95	110	120	100	90	120	120	120	125	110	120	100
Range of flexion- extension[3]	30–130	15–135	30–130	10–105	10–120	15–135	30–130	20–110	20–140	20–140	10–130	15–140	10–120	20–140	10–110
Post-operative of arc of forearmmotion (P/S)[3]	60/65	60/60	60/65	55/60	60/65	60/65	60/65	55/60	60/65	60/65	60/65	60/65	60/65	60/60	60/60
Pain[3]	No	No	No	Mild	No	No	No	Mild	No	No	No	No	No	No	No
Stability[3]	Stable	Stable	Stable	Stable	Stable	Stable	Stable	Stable	Stable	Stable	Stable	Stable	Stable	Stable	Stable
ADL[12]	5	5	5	3	5	5	5	3	5	5	5	5	5	4	4
MEPS[12]	100	100	100	85	100	100	100	85	100	100	100	100	100	95	95
Post-operative of arc of elbow motion (F/E)[12]	100	120	100	90	110	120	100	90	110	120	100	120	120	110	100
Range of flexion extension[12]	30–130	15–135	30–130	20–110	20–130	20–140	30–130	20–110	20–130	20–140	30–130	20–140	20–140	20–130	20–120
Pain[12]	No	No	No	No	No	No	No	No	No	No	No	No	No	No	No
Stability[12]	Stable	Stable	Stable	Stable	Stable	Stable	Stable	Stable	Stable	Stable	Stable	Stable	Stable	Stable	Stable
ADL[9]	5	5	5	3	5	5	5	3	5	5	5	5	5	4	4
MEPS[9]	100	100	100	80	100	100	100	90	100	100	100	100	100	95	95

MEPS: Mayo Elbow Performance Score, ADL: Adjusted disability living

Among all the patient operated, 2 patients after 3 months had pain due to hematoma which improved after drainage, and during 12 months, all are pain free.

Mean MEPS was 95.333 and 97.333 after 3 and 12 months, respectively. After 3 months of post operative period, out of 15 patients 13 showed excellent results and rest two patients showed good results. This improved after 12 months, 14 showing excellent results and one good result [Figure 4]. All the patients were satisfied (excellent and good result) after 3 months and 12 months.

DISCUSSION

Distal intra-articular humerus fractures among old age patients remain the most challenging injuries to manage as these fractures are usually multi fragmented with osteoporotic bone and complex anatomy. Treatment outcomes often associated with stiffness, pain, and weakness. To perform daily activity, we require a painless, stable, and mobile elbow joint. Hence, there is a decreased functional outcome managed by fixation as published by numerous authors.

In our study, 15 patients with distal humerus fractures were operated female predominance (60% female and 40% male). Average age of our study population was 61.27 years. Among operated patients, maximum patients were in the age group 51–60 years (15 patients), 12 patients were between 60 and 70 years, and 3 patients were above 70 years. Hence, in our study, there was female predominance which is comparable with other studies such as John *et al.*[15] and Frankle *et al.*,[16] and the average age is less probably due to the fact that in other western countries people are physiologically more active at older.

In our study, of 15 patients, 2 patients were only diabetic, 2 patients hypertensive, 1 patient with both diabetes and hypertension, and 1 patient with both hypertensive and osteoporosis.

In our study, 1 patient had superficial skin infection which was treated by oral antibiotics, 1 patient had ulnar neuropraxia, and 2 patients had post-operative hematoma treated by drain.

In our series, ulnar apraxia and infection rate are comparable with the studies of Cobb and Morrey,[17] Ray *et al.*,[18] Frankle *et al.*,[16] and Tian *et al.*, [19] but in our series, there was no loosening of any component or heterotropic calcification. It was may be due to short-term follow-up. We found that fixation problem occurs on patient with osteoporosis.

In contrast, Gambirasio *et al.*[20] reported the functional outcome of primary total elbow replacement (TER) in the treatment of the distal humerus fractures in ten elderly patients and concluded that the treatment of multifragmentary, intra-articular fractures of the distal humerus are difficult and found no complications in regard to the soft tissues, bone, or prosthesis. Garcia *et al.*[21] studied 19 patients and found that 1 patient had loosening of a component of prosthesis and no other complication.

In our series, we found that, among TEA group, 1 patient had triceps weakness (IV/V), mean post-operative arc of elbow motion (F/E) of TER group was 110 and 107 after 3 and 12 months' post-operative period, respectively, and 2 patients after 3 months had pain due to hematoma which improved after drainage, and during 12 months, all are pain free.

All the patients were stable and arc of pronation and supination normal functional range. In our study, the mean arc of elbow flexion-extension, stability, pain, and pronation–supination of elbow are comparable with the result of the studies by Cobb and Morrey,[17] Ray *et al.*,[18]

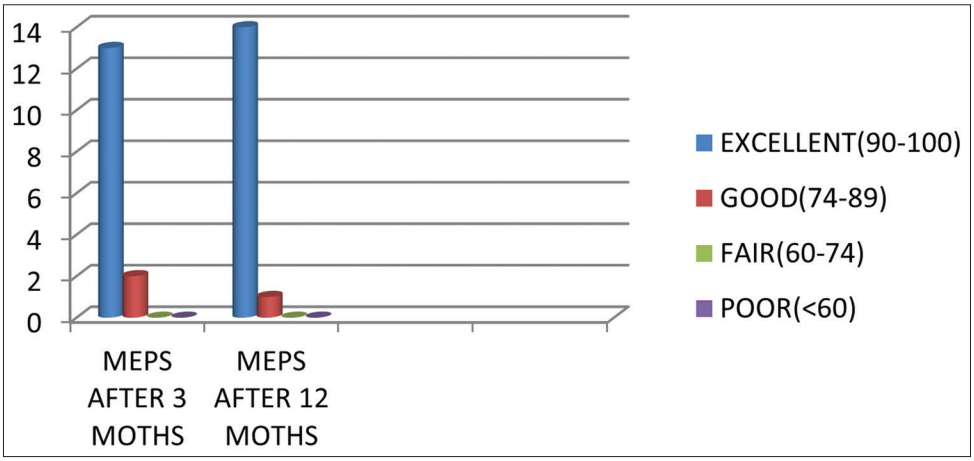

Figure 4: Mayo Elbow Performance Score after 3 months and 12 months of follow-up

McKee *et al.*,[22] and Tian *et al.*,[19] but flexion-extension arc is less than few studies which may be due to late start of physiotherapy following fixation due to fixation problems in a osteoporotic bone and intra-articular incongruity.

In our study, we found triceps muscle weakness in 1 patient among TER groups which is comparable to the result of Cobb and Morrey[17] and Tian *et al.*[19] study which may be due to late start of physiotherapy following fixation due to fixation problems in a osteoporotic bone and intra-articular incongruity.

In our series, the mean MEPS after 12 months was 97 (minimum 80 to 100), and of 15 patients, 14 excellent and 1 good with no fair or poor results.

Gambirasio *et al.*[20] reported the MEPS Score was 94 points (80 to 100) and the patient satisfaction was high. Garcia *et al.*[21] conducted a study of 16 patients (TER) after 3-year follow-up found that mean MEPS was 93 (80–100). Of the 16 patients, 15 were satisfied. Frankle *et al.*[16] conducted a retrospective study taking a total of 24 patients to compare ORIF with TEA using the MEPS, and the outcomes of the 12 patients treated with ORIF were as follows: 4 excellent, 4 good, 1 fair, and 3 poor with mean MEPS score 95. Outcomes of the 12 patients treated with TEA were as follows: 11 excellent and 1 good. There were no fair or poor outcomes in the TEA group with mean MEPS of 81. Kamineni and Morre[y][23] retrospectively reviewed 49 acute distal humeral fractures in 48 patients who were treated with TEA, and as the primary option, the MEPS averaged 93 of a possible 100 points. Sørensen *et al.*[24] evaluated short- to medium-term outcome of TEA in complex fractures of the distal humerus and after 6-year follow-up of 24 cases found that mean MEPS was 94 (range 65–100) with 15 excellent, 4 good, and 1 fair result. Tian *et al.*[19] analyzed the outcomes of TEA in the treatment of 8 cases of elderly Type C distal humeral fractures and found that the average Mayo elbow score was 85.2 ± 3.4 (75–95), four cases of excellent and four cases of good. In our series, MEPS score was comparable to these studies[16,20,21,23]. It was relatively better as compared to other studies[19,25] which may be due to the short follow up period in our series. In contrast, Ducrot *et al.*[25]studied 20 patients undergone TER and found that the average MEPS was 83 (range 60–100, median 80) which was due to 4 patients died and 1 lost follow-up.

In our study, we did not found component loosening, periprosthetic fracture, or revision surgery. It may be due to the limitation of our study that we do not have a long-term follow-up and a large patients number. If we use disabilities of the arm, shoulder, and hand score, then the study would be more effective and informative. Most of the studies done on this topic had used MEPS to assess the result like we did.

CONCLUSION

Distal comminuted intra-articular fracture humerus can be managed by ORIF or with primary TEA. Our study shows good results using TER. Primary TEA may be a viable option for elderly patient with comminuted intra-articular distal humerus fracture with osteoporosis expecting failure of fixation but not to the manual laborer or heavy weight lifter.

REFERENCES

1. Palvanen M, Kannus P, Niemi S, Parkkari J. Secular trends in the osteoporotic fractures of the distal humerus in elderly women. Eur J Epidemiol 1998;14:159-64.
2. Palvanen M, Kannus P, Parkkari J, Pitkäjärvi T, Pasanen M, Vuori I, *et al.* The injury mechanisms of osteoporotic upper extremity fractures among older adults: A controlled study of 287 consecutive patients and their 108 controls. Osteoporos Int 2000;11:822-31.
3. Robinson CM. Fractures of the distal humerus. In: Bucholz RW, Court-Brown C, Tornetta P, Heckman JD, editors. Rockwood and Green's Fractures in Adults. 6th ed. Philadelphia, PA: Lippincott Williams and Wilkins; 2005. p. 1051-116.
4. Robinson CM, Hill RM, Jacobs N, Dall G, Court-Brown CM. Adult distal humeral metaphyseal fractures: Epidemiology and results of treatment. J Orthop Trauma 2003;17:38-47.
5. Järvinen TL, Sievänen H, Khan KM, Heinonen A, Kannus P. Shifting the focus in fracture prevention from osteoporosis to falls. BMJ 2008;336:124-6.
6. Kannus P. Preventing osteoporosis, falls, and fractures among elderly people. Promotion of lifelong physical activity is essential. BMJ 1999;318:205-6.
7. Kannus P, Niemi S, Parkkari J, Palvanen M, Heinonen A, Sievänen H, *et al.* Why is the age-standardized incidence of low-trauma fractures rising in many elderly populations? J Bone Miner Res 2002;17:1363-7.
8. Evans EM. Supracondylar-Y fractures of the humerus. J Bone Joint Surg Br 1953;35-B:371-5.
9. Gofton WT, Macdermid JC, Patterson SD, Faber KJ, King GJ. Functional outcome of AO type C distal humeral fractures. J Hand Surg Am 2003;28:294-308.
10. Kundel K, Braun W, Wieberneit J, Rüter A. Intraarticular distal humerus fractures. Factors affecting functional outcome. Clin Orthop Relat Res 1996;332:200-8.
11. McKee M, Jupiter J, Toh CL, Wilson L, Colton C, Karras KK, *et al.* Reconstruction after malunion and nonunion of intra-articular fractures of the distal humerus. Methods and results in 13 adults. J Bone Joint Surg Br 1994;76:614-21.
12. Baksi DP. Sloppy hinge prosthetic elbow replacement for post-traumatic Ankylosis or instability. J Bone Joint Surg Br 1998;80:614-9.
13. Baksi DP. Modification of Baksi sloppy hinge elbow to minimize the stress at the humeral bone cement interface-an early experience. Indian J Orthop 2005;39:240-3.
14. Baksi DP. Evaluation of physical properties of author's elbow prosthesis with the help of a newly designed elbow. Joint simulator. Indian J Orthop 1989;23:61-9.
15. John H, Rosso R, Neff U, Bodoky A, Regazzoni P, Harder F. Operative treatment of distal humerus fractures in the elderly. J Bone Joint Surg Br 1994;76:793-6.
16. Frankle MA, Herscovici D Jr., DiPasquale TG, Vasey MW, Sanders RW. A comparison of open reduction and internal fixation and primary total elbow arthroplasty in the treatment of intraarticular distal humerus fractures in women older thanage 65. J Orthop Trauma 2003;17:473-80.
17. Cobb TK, Morrey BF. Total elbow arthroplasty as primary treatment

for distal humerus fractures in elderly patients. J Bone Joint Surg Am 1997;79:826-32.
18. Ray PS, Kakarlapudi K, Rajsekhar C, Bhamra MS. Total elbow arthroplasty as a primary treatment for distal humeral fractures in elderly patients. Injury 2000;31:687-92.
19. Tian W, He C, Jia J. Total elbow joint replacement for the treatment of distal humerus fracture of type c in eight elderly patients. Int J Clin Exp Med 2015;8:10066-73.
20. Gambirasio R, Riand N, Stern R, Hoffmeyer P. Total elbow replacement for Complex fractures of the distal humerus: An option for the elderly patient. J Bone Joint Surg Br 2001;83:974-8.
21. Garcia JA, Mykula R, Stanley D. Complex fractures of the distal humerus in the elderly. The role of total elbow replacement as primary treatment. J Bone Joint Surg Br 2002;84:812-6.
22. McKee MD, Veillette CJ, Hall JA, Schemitsch EH, Wild LM, McCormack R, *et al.* A multicenter, prospective, randomized, controlled trial of open reduction-internal fixation versus total elbow arthroplasty for displaced intra-articular distal humeral fractures in elderly patients. J Shoulder Elbow Surg 2009;18:3-12.
23. Kamineni S, Morrey BF. Distal humeral fractures treated with non-custom total elbow replacement. Surgical technique. J Bone Joint Surg 2005;87:41-50.
24. Sørensen BW, Brorson S, Olsen BS. Primary total elbow arthroplasty in complex fractures of the distal humerus. World J Orthop 2014;5:368-72.
25. Ducrot G, Ehlinger M, Adam P, Di Marco A, Clavert P, Bonnomet F, *et al.* Complex fractures of the distal humerus in the elderly: Is primary total elbow arthroplasty a valid treatment alternative? A series of 20 cases. Orthop Traumatol Surg Res 2013;99:10-20.

How to cite this article: Behera S, Saha PK, Ray S, Pal AK. Functional Outcome of Primary Total Elbow Arthroplasty for Intra-articular Distal Humerus Fractures in Elderly Patients: A Prospective Study. Int J Sci Stud 2018;5(12):19-25.

Source of Support: Nil, **Conflict of Interest:** None declared.