Original Article

DOI: 10.17354/ijss/2016/119

Surgical Fibrolysis and Skin Grafts in the Management of Oral Submucous Fibrosis

Subodh Nanavati[1], Pallavi Nanavati[2], Maulik Nanavati[3]

[1]Oral & Maxillo-Facial Surgeon and Consultant in Healthcare Management, Department of Oral and Maxillo-Facial Surgery, Oral and Maxillo-Facial Surgical Hospital, Rajkot, Gujarat, India, [2]General Dental Practitioner, Oral and Maxillo-Facial Surgical Hospital, Rajkot, Gujarat, India, [3]General Dental Practitioner, Happy Sapiens Dental, Houston, Texas, USA

Abstract

Introduction: Oral submucous fibrosis (OSMF) is a chronic, insidious, irreversible disease characterized mainly by two symptoms, burning sensation in the mouth while eating spicy hot food in early stages of the disease and trismus in the late stages of the disease.

Materials and Methods: This is retrospective hospital-based study of 25 patients, selected from 170 patients of OSMF, who attended OPD of Oral and Maxillofacial Surgical Hospital, Rajkot, Gujarat, India. Patients were selected for surgery based on their inter-incisal distance (IID) (Between 0.00 cm [Complete Trismus] and 2.5 cm). Patients having IID >2.5 cm were not subjected to surgical treatment. Complete records of the patients were maintained, and patients were followed postoperatively for the period of at least 3 Years.

Results: An average pre-operative IID of 25 patients who underwent surgery was found to be 1.49 cm, intra-operative IID was 2.86 cm while immediate post-operative IID was found to be 3.40 cm. All patients were recalled for check-up after 6 months, 1, 2, and 3 years in the post-operative period. The average IIDs recorded at the time of post-operative check-up were found to be as 6 months = 3.51 cm, 1-year IID = 3.45 cm, 2 years IID = 3.43 cm and 3 years IID was 3.44 cm. Thus, improvement in IID at pre-operative period (1.49 cm) was recorded to be (3.44 cm) at the end of 3-year period.

Conclusions: Surgical excision of fibrous bands followed by application of split skin graft covering the raw area in buccal mucosa gives good long-term results without any complications and satisfactory long-term results.

Key words: Oral submucous fibrosis, Skin grafts, Surgery, Trismus

INTRODUCTION

Oral submucous fibrosis (OSMF) is a chronic, progressive, irreversible or incurable, scarring disease, that predominantly affects the people of South-East Asian origin. This condition was described first by Schwartz (1952)[1] while examining five Indian women from Kenya, to which he ascribed the descriptive term "atrophiaidiopathica (tropica) mucosae oris." Later in 1953, Joshi[2] from Mumbai, redesignated the condition as OSMF, implying predominantly its histological nature. The WHO definition for an oral precancerous condition – "a generalized pathological state of the oral mucosa associated with a significantly increased risk of' cancer," accords well with the characteristics of OSMF.[3]

Access this article online

IJSS

www.ijss-sn.com

Month of Submission : 01-2015
Month of Peer Review : 02-2016
Month of Acceptance : 02-2016
Month of Publishing : 03-2016

Described for the first time in detail in the year 1966 by Pindborg and Sirsat,[4] OSMF is now definitely being recognized as a disease of Indian subcontinent occurring more commonly in countries such as India, Pakistan, Shri Lanka, Nepal, China and few countries where Indians have migrated like Europe and North America.

Patients present themselves to the clinician treating OSMF with two major complaints: Burning sensation in the mouth, particularly while eating spicy food and progressive inability to open mouth fully (Trismus). The clinical examination invariably reveals multiple oral ulcerations, white blanched oral mucosa, particularly mucosa of cheek and palate, partial or complete trismus and submucosal fibrous bands running in either vertical directions in cheek

Corresponding Author: Dr. Subodh Nanavati, Happy Sapiens Dental, 27631, Decker Prairie Road, Pinehurst, Huston, TX 77362, USA. E-mail: drnanavati1@hotmail.com

mucosa or horizontally across in palatal mucosa. Diagnosis of OSMF is mainly clinical, however, biopsy of the oral mucosa is mandatory to rule out malignant changes. The fibrosis observed during the clinical examination in oral mucosa involves the lamina propria and the submucosa and may often extend into the underlying musculature resulting in the deposition of dense fibrous bands giving rise to the limited mouth opening which is a hallmark of this disorder.

OSMF is associated with significant morbidity, with restricted mouth opening causing eating difficulties so a range of surgical modalities has been attempted, from moderate to significantly invasive. The most common initial surgical intervention includes the release of intraoral fibrous bands, coronoidotomies, muscle of mastication myotomies, and soft-tissue reconstruction with split thickness skin graft or allograft.[5] Aggressive physical therapy post-surgery is essential: Without physical therapy compliance, the risk of recurrent trismus is possible. Patients should be made aware that, although the trismus has resolved post-surgery, their OSMF has not been cured. As such, continued physical therapy for the rest of their life is the best way to prevent recurrence of trismus. In addition, cessation of betel nut and tobacco use is essential to minimize disease progression. Finally, oral cancer surveillance is necessary for the rest of the patient's life.

For cases in which initial surgical intervention is unsuccessful (recurrent trismus; usually secondary to lack of compliance with physical therapy), the more aggressive surgical therapy is indicated. Again, excision of any fibrous bands intraorally and repeat masticatory muscle myotomy is required. Often, in this situation, a larger soft tissue buccal defect is created, needing large soft tissue reconstruction. This can include a temporalis pedicled flap, pedicled superficial temporalis fascial flap or a radial forearm free flap combined with split thickness skin graft coverage.[6]

The various local or distant tissues used for covering raw areas after surgical excision of the fibrous bands are either extra-oral tissue flaps or intraoral tissue flaps and include split skin grafts, nasolabial grafts, forehead flaps, palatal flaps, buccal fat pad tissue, lateral tongue flaps, absorbable collagen membrane, use of lasers, radial forearm free flaps, anterolateral thigh (ALT) flaps, vascularized temporal myofascial flaps, and collagen/silicone bilayer membrane. Each of these techniques has their own advantages and disadvantages and works best under the hands of those who advocate it (Table 1).

Table 1: Surgical procedures described in the literature for OSMF

Surgical procedures
Buccal fat pad
Lateral tongue flaps
Palatal flaps
Nasolabial flaps
Forehead flaps
Split skin grafts
Absorbable collagen membrane
Laser surgery
KTP laser
CO_2 laser
Radial forearm free flaps
Platysma myocutaneous flap
ADG
Amniotic membrane graft
Fibrn glue and absorbable atelocollagen membrane
Free flap reconstruction
Fibrotomy with coronoidectomy
Vascularised temporal myofascial pedicled flap
ALT thigh flaps
Collagen/silicone bilayer membrane

ADG: Artficial dermis graft, ALT: Anterolateral thigh, OSMF: Oral submucous fibrosis

MATERIALS AND METHODS

In this retrospective hospital-based study, 170 patients attending OPD of Oral and Maxillofacial Surgery Hospital, Rajkot, Gujrat State, India[7] and who were diagnosed for the presence of OSMF based on pre-determined clinical criteria mainly, burning sensation in the mouth particularly while eating spicy hot food and progressively increasing inability to open mouth (Trismus) were included in this study. Diagnosis of OSMF was confirmed by biopsy. Complete records were maintained including records about areca nut and tobacco chewing habits, and oral hygiene. Inter-incisal distance (IID) (Mouth opening) was measured with calipers. Radiological examinations were carried out whenever found necessary. Whenever possible, considering the presence of trismus, existing dental pathologies such as dental caries and periodontal pathologies like gingivitis were eliminated preoperatively to eliminate source of infection.

Patients exhibiting marked trismus (IID < 2.5 cm) were offered surgical treatment in the form of "Surgical fibrolysis and skin grafts" to relieve them of their trismus. Complete details of surgery were explained to the patients and informed consent was obtained from each patient. A total of 25 patients consented for surgical treatment.

All patients were males and their ages ranged from 21 to 40 years (Groups 3 and 4)[7] average being 30.5 years. All patients had marked trismus with IID being <2.5 cm.

Inclusion Criteria's

1. Established case of OSMF by clinical and histopathological examination
2. IID < 2.5 cm
3. Patient has fully understood the surgical procedure he is about to undergo and has signed informed consent

4. Patient willing to leave tobacco habit and willing to continue to do so during post-operative period and signs document regarding his cooperation
5. Patients with good general health with no systemic comorbidity like diabetes or hypertension.

Exclusion Criteria's

1. IID > 2.5 cm
2. Patients with chief complaint of burning sensation in the mouth while eating spicy food
3. Patients not fully understanding the surgical procedure and not signing the informed consent
4. Patient expecting high results
5. Patients showing signs of non-cooperation before surgery like not ready to leave tobacco habits or not ready to carry out oral physiotherapy in the post-operative period
6. Patient having poor general health.

Surgical Procedure

Essentially, surgical procedure involved surgical removal of fibrous bands and resurfacing the raw area thus created in the buccal mucosa, bilaterally, by thick split skin graft. All surgeries were performed under general anesthesia. Pre-operative IID is measured and recorded.

A step-wise surgical procedure is described for better understanding of the surgical procedure.

1. Step No. 1 (Induction of anesthesia): General anesthesia was induced by either direct naso-endotracheal intubation or by use of fiber optic bronchoscope. Emergency tracheostomy set was always kept ready.
2. Step No. 2 (Incision): Horizontal incision was taken into both buccal mucosa beginning from a point just behind the oral commissure, going posteriorly to a point just in front of palato-lingual fold, avoiding injury to opening of parotid gland. This incision runs between occlusal surfaces of upper and lower teeth and its depth is limited to oral mucosa only.
3. Step No. 3 (Exposing fibrous bands): After primary incision in both the buccal mucosa, its depth being restricted only to mucosa, mouth is forcefully open, with the help of mouth prop taking care of the teeth. This opens up incisions in both the buccal mucosa in a triangular fashion, with tip positioned posteriorly and exposing underlying fibrous bands and musculature. IID is measured and recorded (intraoperative IID).
4. Step No. 4 (Fibrolysis): After fibrous bands are exposed, they are removed (fibrolysis) by palpating fibrous bands with fingers, till normal tissue without fibrous bands, is felt under palpating fingers. At this stage, surgical myotomies may have to be performed to get desired results. Excessive tissue at the posterior end of the incision is excised to give raw area a rectangular shape. Bleeding points are checked and bleeding controlled.
5. Step No. 5 (Obtaining skin graft): Thick split skin graft is obtained using suitable skin-grafting knife from hair-less areas of the skin. The most suitable area is the medial surface of the forearm. Donor area is covered with dressings. A skin graft is divided into two parts for each buccal mucosa and cut into proper shape. Any fat globules and other tissues attached on the raw area of the graft are excised, and grafts are made ready to place on recipient sites.
6. Step No. 6 (Skin grafting): Skin grafts are placed on the raw areas created in the buccal mucosa bilaterally, their edges matched and skin grafts are sutured into position using absorbable suture material. One end of the suture is kept long so that it can be used to put tie-over bolster dressing on the skin graft. To create pressure on skin grafts and stabilize them, softened dental compound is pressed onto the skin grafts and between teeth on both the sides. IID is measured (immediate post-operative IID).
7. Step No. 7 (End of surgery): After securing grafts in position Ryle's tube is passed through nose and patient is extubated.

Post-operative Course

Patient is kept in the ward for the period of one week. Feeding is carried out through Ryle's tube. On 7th post-operative day, Ryle's tube, intraoral pressure dressings, including tie-over bolster dressings are removed. Excessive suture material is removed. The patient is advised to start post-operative oral physiotherapy until further advice. Patient is recalled after 6 months, 1, 2 and 3 years for post-operative checkup.

For oral physiotherapy, wooden stents of various lengths were provided.

Measurement of IID

IID is measured at regular intervals.

1. Preoperatively
2. Intra-operative after opening the mouth forcefully
3. Postoperatively after surgery is over and pressure dressings are given
4. Postoperatively, after 6 months, 1, 2 and 3 years during recall checkup (Charts 1-10).

Data Analysis

Data were analyzed using two systems:

1. ANOVA Single Factor 6.521E-38 ($P < 0.05$)
2. IBM Watson Analytics: High-quality Results with 93 points. Various IID were compared and recorded (Chart 11).

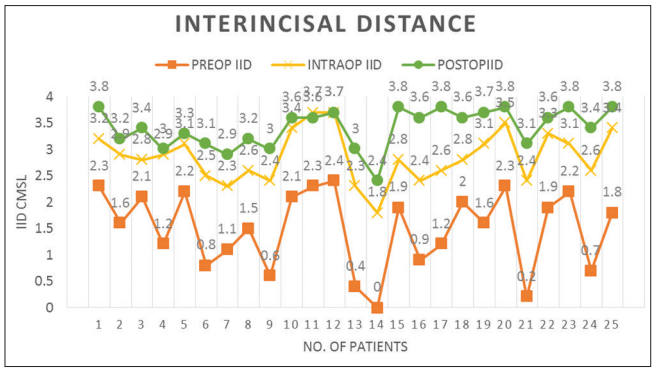

Chart 1: Inter-incisal distance (IID) pre-operative, intra-operative, and immediate post-operative

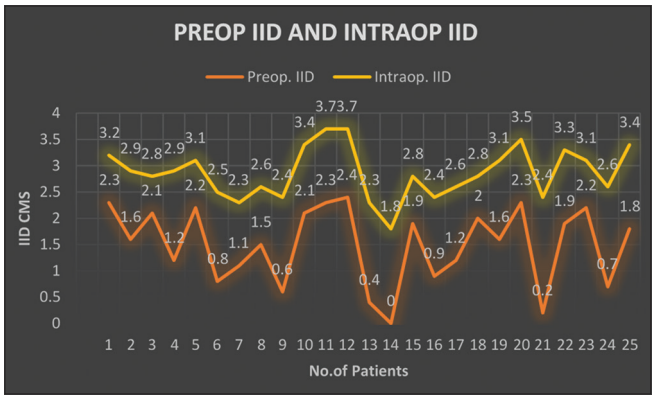

Chart 2: Pre-operative inter-incisal distance (IID) and intra-operative IID

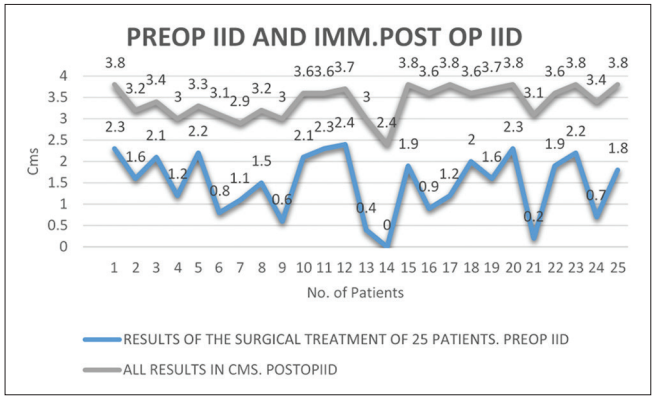

Chart 3: Pre-operative inter-incisal distance (IID) and immediate post-operative IID

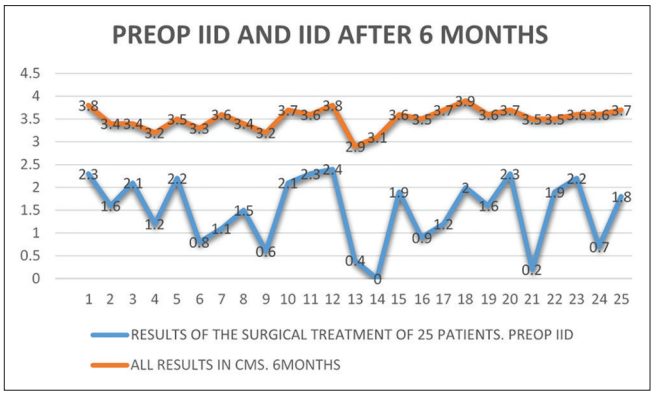

Chart 4: Pre-operative inter-incisal distance (IID) and post-operative IID after 6 months

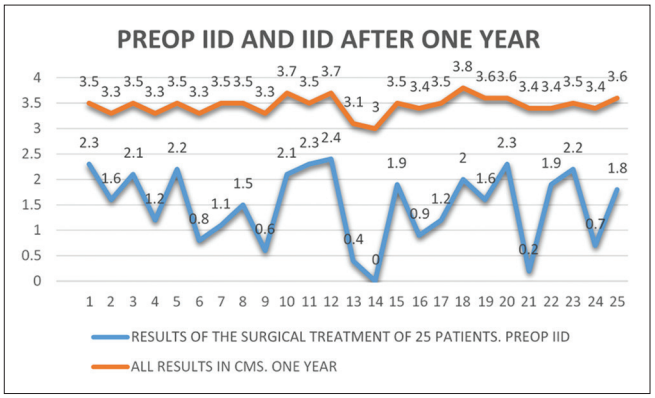

Chart 5: Pre-operative inter-incisal distance (IID) and IID after 1-year

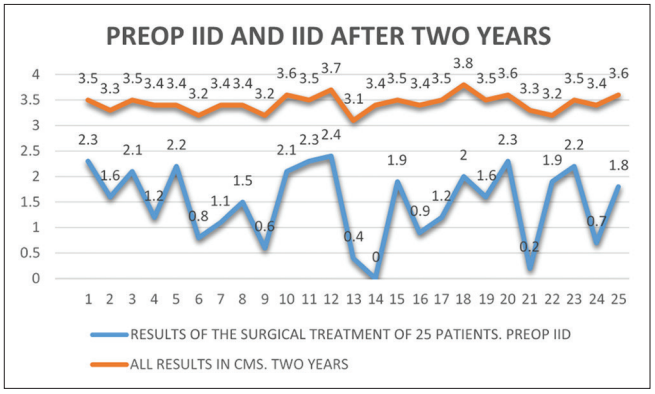

Chart 6: Pre-operative inter-incisal distance (IID) and IID after 2 years

RESULTS

In total, 25 patients underwent surgical fibrolysis followed by skin graft for the treatment of trismus associated with OSMF. Results of IID measured at various stages of treatment protocol was considered as a benchmark for the success of this surgical treatment.

Average pre-operative IID in all patients was found to be 1.49 cm, while Average intraoperative IID was 2.86 cm. Average immediate post-operative IID was 3.4 cm. At the end of 6-month period average post-operative IID in all 25 patients was 3.51 cm, while at the end of 1, 2 and 3 years post-operative periods average IIDs were found to be 3.45, 3.43 and 3.44 cm, respectively. On average pre-operative IID increased from 1.49 cm to 3.44 cm at the end of 3 years post-operative period (Table 2).

Table 2: Results of surgical treatment of 25 patients

Serial number	Pre-operative IID	Intra-operative IID	Post-operative IID	6 Months IID	1 year IID	2 years IID	3 years IID
1	2.3	3.2	3.8	3.8	3.5	3.5	3.4
2	1.6	2.9	3.2	3.4	3.3	3.3	3.3
3	2.1	2.8	3.4	3.4	3.5	3.5	3.5
4	1.2	2.9	3	3.2	3.3	3.4	3.9
5	2.2	3.1	3.3	3.5	3.5	3.4	3.4
6	0.8	2.5	3.1	3.3	3.3	3.2	3.2
7	1.1	2.3	2.9	3.6	3.5	3.4	3.4
8	1.5	2.6	3.2	3.4	3.5	3.4	3.4
9	0.6	2.4	3	3.2	3.3	3.2	3.2
10	2.1	3.4	3.6	3.7	3.7	3.6	3.6
11	2.3	3.7	3.6	3.6	3.5	3.5	3.5
12	2.4	3.7	3.7	3.8	3.7	3.7	3.6
13	0.4	2.3	3	2.9	3.1	3.1	3.1
14	0	1.8	2.4	3.1	3	3.4	3.4
15	1.9	2.8	3.8	3.6	3.5	3.5	3.5
16	0.9	2.4	3.6	3.5	3.4	3.4	3.4
17	1.2	2.6	3.8	3.7	3.5	3.5	3.5
18	2	2.8	3.6	3.9	3.8	3.8	3.8
19	1.6	3.1	3.7	3.6	3.6	3.5	3.5
20	2.3	3.5	3.8	3.7	3.6	3.6	3.6
21	0.2	2.4	3.1	3.5	3.4	3.3	3.2
22	1.9	3.3	3.6	3.5	3.4	3.2	3.2
23	2.2	3.1	3.8	3.6	3.5	3.5	3.5
24	0.7	2.6	3.4	3.6	3.4	3.4	3.4
25	1.8	3.4	3.8	3.7	3.6	3.6	3.6
Averages (cm)	1.49	2.86	3.40	3.51	3.45	3.43	3.44

All results are in cm. IID: Inter-incisal distance

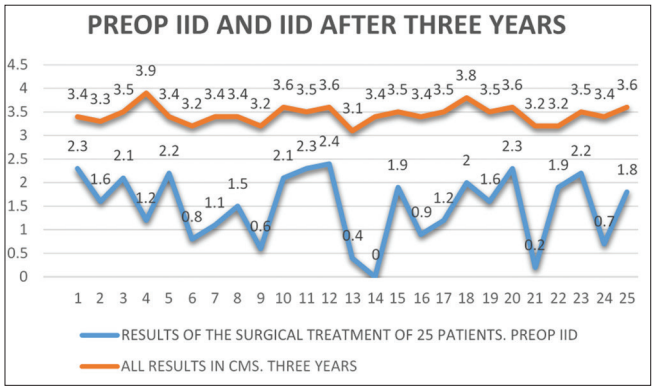

Chart 7: Pre-operative inter-incisal distance (IID) and IID after 3 years

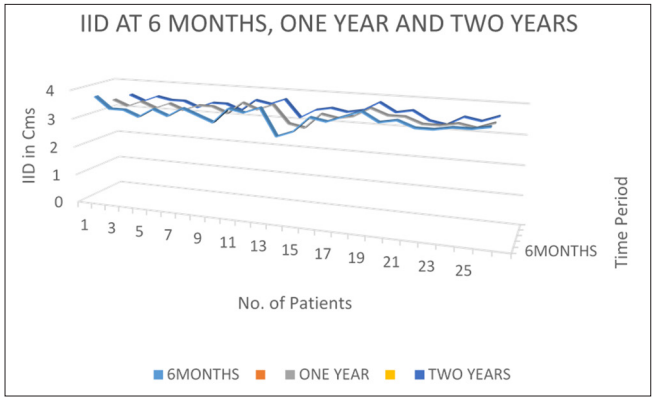

Chart 8: Inter-incisal distance after 6 months, 1 and 2 years

DISCUSSION

Plethora of literature is published on the treatment of OSMF each clinician claiming better success than the other. But in reality, most clinicians attempt to relieve symptoms associated with OSMF, primarily burning sensation in the mouth while eating spicy food in the early stage of the disease when inflammation, ulcerations and vesiculations dominate the clinical picture. At this stage dizzying array of treatment modalities have been administered by various clinicians which are mainly conservative non-invasive treatments. Success has been claimed using intralesional steroids. lycopene, micronutrients, milk from immunized cows, pentoxifilline, interferon gamma, placental extracts, turmeric (curcumin-diferuloymethane), chymotrypsin, hyaluronidase, dexamethasone, levamesole, vitamin A, and stem cell therapy. The conservative non-invasive treatment of OSMF consists mainly of intraoral submucosal injections of various drugs suggested or it may consists of ingestion of oral medications. Conservative treatment of OSMF is mainly effective during first two stages of disease when chief complaint of the patient is burning sensation in the mouth (Table 3).

When disease advances to late stage of OSMF when trismus predominates the clinical picture, surgical treatment is attempted. Essentially surgical treatment consists of excision of fibrous bands and covering the raw area thus

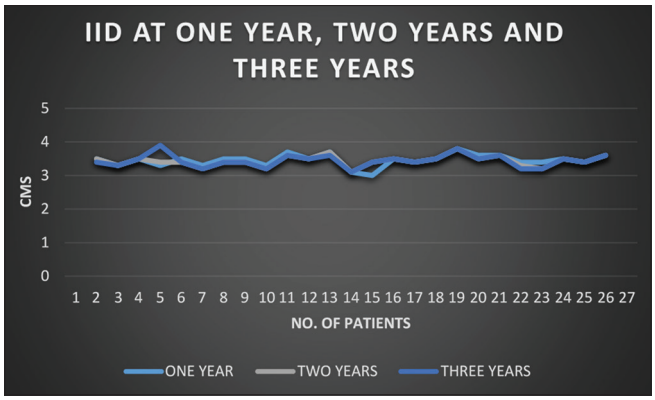

Chart 9: Inter-incisal distance at the end of 1, 2, and 3 years period

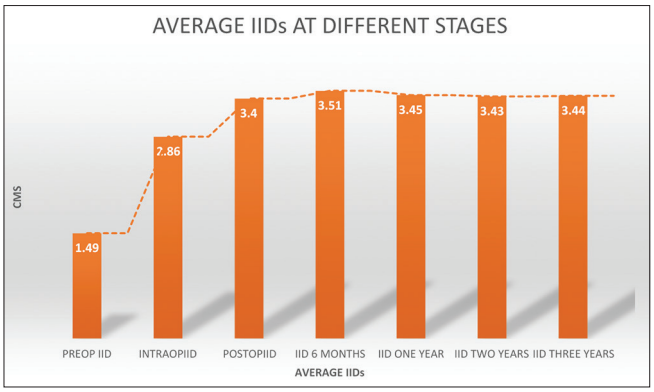

Chart 10: Average inter-incisal distances (IIDs) at different stages

created by various local or distant tissues, and hope for trismus to be relieved. The various local or distant tissues used for covering raw areas after surgical excision of the fibrous bands are split skin grafts, nasolabial pedicled grafts, forehead flaps, palatal island flaps, buccal fat pad tissue, lateral tongue flaps, absorbable collagen membrane, radial forearm free flaps, ALT thigh flaps, vascularized temporal myofascial flaps, and collagen/silicone bilayer membrane[6,8-26] (Table 1). Lasers have also been advocated by few clinicians.[27] Each of these techniques have their own advantages and disadvantages and works best under the hands of those who advocate it.

None of the interventions reported so far, both, conservative non-invasive medical interventions or invasive surgical interventions, have reported any improvement in oral health-related quality of life among patients treated for OSMF. Both, main clinical symptoms, burning sensation in the mouth while eating spicy hot food and progressive inability to open mouth fully (Trismus) can affect oral functions, oro-facial appearance (sunken cheeks), and social interactions (difficulty in speech and deglutition).[28]

Few reviewers like Ramesh Ram[29] are of the opinion that appropriate line of treatment whether conservative or invasive, can be decided only after studying individual mechanisms operating at various stages of OSMF – initial, intermediate and advanced stages of OSMF.

Table 3: Non-invasive treatment for OSMF described in the literature

Non-invasive treatment
Micronutrients and minerals
Milk from immunized cows
Lycopene
Pentoxyfilline
Interferon gamma
Steroids
Placental extracts
Turmeric
Chymotrypsin, hyaluronidase, dexamethasone
Levamisole and vitamin A
Stem cell therapy

OSMF: Oral submucous fibrosis

In the year 2015, Kamath[30] carried out review of articles published on surgical treatment of OSMF. In total, 56 articles have been published on this subject and 995 surgically treated cases are included in the analysis. According to Kamath[30] very few controlled trials are conducted, most being randomized surgical trials on few patients with a short follow-up. The surgical procedure depends on preference of the clinicians and no definite protocols for treatment of OSMF exist. Adequate documentation and follow up need to be established to statistically analyze the results and proclaimed successes of various treatment modalities.

Fedorowicz *et al.*[31] found no reliable RCT evidence for medical or surgical problems caused by restricted mouth opening and according to him more robust trials are required to identify the most effective treatment approaches to this debilitating condition.

There have been conflicting views about use of skin grafts in the treatment of OSMF, some clinicians favoring its use while others outright rejecting skin grafts. When used for excision of intraoral lesions, small defects are often resurfaced by skin grafts Use of split skin grafts have certain advantages in covering intraoral mucosal defects like ease of harvest with minimal additional operating time and post-operative hospital stay, an acceptable functional cosmetic result, and the ability to survive post-operative radiation[32] when radiation is part of the treatment. Furthermore, the use of split-thickness skin grafts (STSG) increases the practicability of a wider removal of abnormal mucous membranes surrounding the primary lesions.[33]

Yen was the first to succeed in covering the buccal defect with a STSG in treating a case of OSMF.[34]

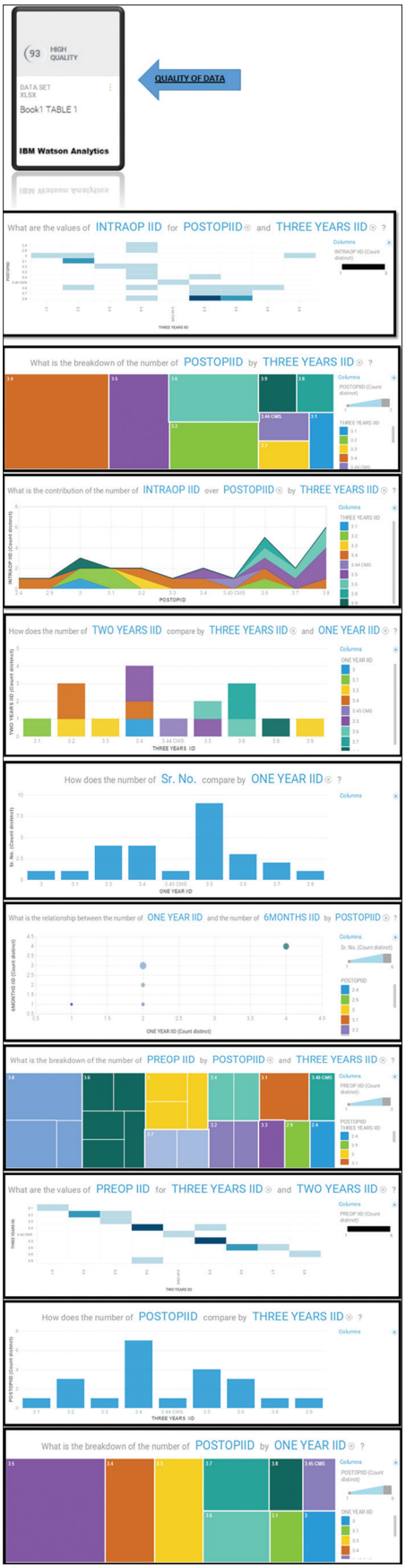

Chart 11: IBM WATSON data analytics

Yeh carried out a surgical procedure of incising the mucosa down to the muscles from the angle of mouth to the anterior tonsillar pillar, taking care to prevent damage to the stoma of the parotid duct, followed by split skin grafting into the defect, with acceptable results.[11]

Soh and Muthusekhar[35] reported in the year 2015 use split skin grafts and polyethylene stent in 15 patients with OSMF. They concluded that fibrotomy followed by split skin graft along with a polyethylene sheet stent and sufficient post-operative physiotherapy is a simple, cost-effective and viable treatment modality for OSMF.

Canniff *et al.*[12] described the procedure of split thickness skin grafting after bilateral temporalis myotomy or coronoidectomy along with daily opening exercise and nocturnal props for a further 4 weeks.

Intraoral skin grafting in the buccal mucosa needs meticulous planning and execution so far as immobilization and adherence of the skin graft to the recipient bed is concerned.

Graft failure can be prevented by immobilizing the graft and closing up any potential dead space that might lead to separation. Multiple approaches for immobilizing skin grafts intraorally have been described in the literature. In 1975, Goshgarian and Miller[36] described a parachute stent technique that secures intraoral skin grafts via transcutaneous sutures. In 1981, Friedlander and Miller[37] described a technique using eye patches and a denture soft liner, securing the STSG to the cheek using transbuccal bolster sutures. Since then, many materials have been used, including foam, gauze, sutures, silicone, foam rubber pads, and eye patches, in addition to a myriad of different bolstering techniques.[38]

The traditional tie over bolster technique described by Schramm and Myers involves fixation of the skin graft to the raw area, followed by placement of non-absorbable silk sutures from the adjacent mucosa, which are then tied over the bolster. However, the placement of this tie over sutures requires adjacent normal mucosa for anchorage, which may not be sufficient especially in the gingivobuccal sulcus. Although external fixation of the stents to the cheek has been described, this results in ugly scarring of the cheek.[32]

In our surgical technique, these problems were overcome by giving proper rectangular shape to the recipient site with adequate tissue surrounding it, using multiple interrupted absorbable sutures, tie-over bolster dressings and using softened dental compound on the graft between teeth so that adequate pressure is created on the graft and oral movements are restricted.

Improved oral opening is an important objective of OSMF treatment. The treatment of severe trismus requires a combination of surgical release and post-surgical physiotherapy; the latter is essential for preventing a relapse due to post-operative inactivity and scarring.[14,39-44] Mouth exercising is the well-established method to improve mouth opening and also to prevent post-surgical relapse. Various devices that help patients improve the mouth opening have been described in the literature. A majority of the appliances are tooth-borne, where opening force can be applied with the help of the devices or stents placed between the maxillary and mandibular arches or teeth. Previous literature described many mouth opening devices.[41-43] Cox and Zoellner[41] tested the hypothesis that physiotherapy alone can modify tissue remodeling in OSMF to increase oral opening. Mouth-opening devices for this purpose are fixed to the teeth to keep the dental arches apart.[41,42] Partially or totally edentulous arches, decayed teeth, or periodontitis, do not allow for the use of such devices, and often patients suffering from severe trismus present with these conditions. A non-tooth-borne mouth-opening device applying force to two intraoral screws placed in the vestibule of the maxillary and mandibular bones is described in such a situation. Patient noncompliance prevents surgical intervention for placement of the screws and limits the use of such devices. Patil and Patil[44] describe the fabrication and use of a new mouth-exercising device that helps patients to squeeze or stretch the cheek, resulting in local tissue remodeling to increase the elasticity of the mucosa for improvement in mouth opening.

In spite of tremendous advances in the oral physiotherapy devices,[44] a simple and cost effective device which even patient himself can fabricate at home is a wooden stent. We gave patients wooden oral stents (Props) of increasing lengths like 2.5, 2.8 and 3.00 cm and more, and advised them to insert them between their teeth as long as possible till it falls off and does not stay between their teeth because of increased mouth opening. Patient will then start using longer stent till he reaches longest possible stent.

In general, IID are considered as parameters of success in the surgical treatment of trismus associated with OSMF. Accordingly, we measured IID at the end of 6 months period and 1, 2, and 3 years periods. All patients were recalled accordingly, IID measured and clinical examination carried out to notice any change. Patients were encouraged to continue with oral physiotherapy.

A study of first two charts reveal the fact that forceful opening of the mouth improves the IID considerably, however, surgical fibrolysis and myotomies are necessary to achieve desired and further acceptable mouth opening. Average Preop IID improved from 1.49 to 2.86 cm after forcefully opening the mouth while after fibrolysis and myotomies the average IID showed significant improvement from 2.86 cm to 3.40 cm.

Intraoral split thickness grafts may show some contracture and patients show reduced IID for first 1-year. However at the end of 1-year period, most grafts do not show any further contraction and remains stable as evident by stability in IID measured and compared at the end of 1, 2, and 3 years period (Charts 1-10).

Though use of skin grafts in the management of trismus associated with OSMF has not given expected, or satisfactory results to some clinicians and as a matter of fact few clinicians have outright rejected skin grafts as a suitable replacement tissue for large buccal defects created after fibrous band excision, we believe with proper surgical technique and meticulous follow-up of the patients for long periods gives good results, as it has given in our patients. When split-skin grafts are used for treatment of OSMF patients undergo three phases of healing:

1. Phase of Expansion (Increased in IID): In this phase, patient experiences increased mouth opening postoperatively because of surgical fibrolysis and myotomies followed by intense oral physiotherapy by patient. This phase last from immediate post-operative period until 6 months postoperatively.
2. Phase of Contractility (Reduction in IID): In this phase, patient shows reduction in mouth opening due to normal contracture of the wound and skin graft during healing phase. Another possibility is of non-cooperation of the patient regarding tobacco-habits or oral physiotherapy. This phase lasts from 6 months to 1-year of post-operative period.
3. Phase of Stability (Stable IID): This is final phase in which the wound and skin grafts stabilizes without further contracture. IID remains constant and patient shows signs of cooperation. This period usually starts after 1-year of post-operative period till final follow-up in our case 3 years.

We were able to get good results by using split skin grafts in OSMF. Statistically results were significant with $P < 0.05$ (ANOVA Single Factor 6.3521E-38). IBM Watson Analytics showed High-quality Results with 93 points (Chart 11).

Most importantly, we believe that choice of surgical interventions while treating trismus in OSMF clinicians should bear in mind necessity of repeat surgery in case of surgical failure or refibrosis and trismus following failure of patient compliance as regards to stoppage of tobacco habit and oral physiotherapy. Unfortunately, most surgeries advocated by various clinicians fail on these both accounts.

Repeat surgeries are not possible using same local or distant tissue flaps, and therefore, more radical surgery needs to be undertaken for which patient may not agree and may not be possible on technical grounds. When refibrosis takes place, intraoral local flaps like Palatal island flaps or tongue flaps themselves are known to get fibrosed. Use of skin grafts give opportunity for repeat surgery in case of surgical failure or refibrosis.

How split skin graft prevents or minimizes re-fibrosis is a question of debate.

Wound healing and scar formation is highly complex process and involves Actin and myosin and tethring movements of fibroblasts and myofibroblasts.

Based on above theory of scar contracture as suggested by Zhang Q, Qian YL, Cui L.[45] we propose a hypothesis that skin graft , prevents or minimizes re-fibrosis by following three mechanisms:

1. Reduction of levels of Actin and Myosin in myofibrils.
2. Reduction in the levels of Propyl Hydroxylase.
3. Mechanical interference by skin graft.

However, further studies are necessary to arrive at any definite conclusions

CONCLUSIONS

Surgical treatment of trismus associated with OSMF is a challenging task and needs meticulous planning and its execution. Proper choice of surgical intervention is necessary considering likelihood of surgical failure or refibrosis. Use of Intraoral tissue flaps may not be possible because of the presence of fibrosis preoperatively or these flaps themselves may get fibrosed in the event of non-compliance by the patient and make their re-use obsolete. Extra-oral tissue flaps are technically difficult, may need additional training or skilled surgeons and leaves behind large facial or extra-facial tissue scars which may not be acceptable to the patient and again in the event of refibrosis their use becomes obsolete.

REFERENCES

1. Schwartz J. Atrophicaidiopathica Mucosae Oris. London: Demonstrated at The Eleventh International Dental Congress; 1952.
2. Joshi SG. Fibrosis of the palate and pillars. Indian J Otolaryngol 1953;4:1-4.
3. Kramer IR, Pindborg JJ, Bezroukov V, Infirri JS. Guide to epidemiology and diagnosis of oral mucosal diseases and conditions. World Health Organization. Community Dent Oral Epidemiol 1980;8:1-26.
4. Pindborg JJ, Sirsat SM. Oral submucous fibrosis. Oral Surg Oral Med Oral Pathol 1966;22:764-79.
5. Chang YM, Tsai CY, Kildal M, Wei FC. Importance of coronoidotomy and masticatory muscle myotomy in surgical release of trismus caused by submucous fibrosis. Plast Reconstr Surg 2004;113:1949-54.
6. Lee JT, Cheng LF, Chen PR, Wang CH, Hsu H, Chien SH, *et al.* Bipaddled radial forearm flap for the reconstruction of bilateral buccal defects in oral submucous fibrosis. Int J Oral Maxillofac Surg 2007;36:615-9.
7. Nanavati S, Nanavati P, Nanavati M. Clinico-pathological study of 170 cases of oral sub-mucous fibrosis. Int J Sci Stud 2015;3:1-8.
8. Mehrotra D, Pradhan R, Gupta S. Retrospective comparison of surgical treatment modalities in 100 patients with oral submucous fibrosis. Oral Surg Oral Med Oral Pathol Oral Radiol Endod 2009;107:e1-10.
9. Borle RM, Nimonkar PV, Rajan R. Extended nasolabial flaps in the management of oral submucous fibrosis. Br J Oral Maxillofac Surg 2009;47:382-5.
10. Amin MA, Bailey BM, Swinson B, Witherow H. Use of the buccal fat pad in the reconstruction and prosthetic rehabilitation of oncological maxillary defects. Br J Oral Maxillofac Surg 2005;43:148-54.
11. Yeh CJ. Application of the buccal fat pad to the surgical treatment of oral submucous fibrosis. Int J Oral Maxillofac Surg 1996;25:130-3.
12. Canniff JP, Harvey W, Harris M. Oral submucous fibrosis: Its pathogenesis and management. Br Dent J 1986;160:429-34.
13. Khanna JN, Andrade NN. Oral submucous fibrosis: A new concept in surgical management. Report of 100 cases. Int J Oral Maxillofac Surg 1995;24:433-9.
14. Lai DR, Chen HR, Lin LM, Huang YL, Tsai CC. Clinical evaluation of different treatment methods for oral submucous fibrosis. A 10-year experience with 150 cases. J Oral Pathol Med 1995;24:402-6.
15. Zhang HM, Yan YP, Qi KM, Wang JQ, Liu ZF. Anatomical structure of the buccal fat pad and its clinical adaptations. Plast Reconstr Surg 2002;109:2509-18.
16. Nataraj S, Guruprasad Y, Shetty JN. A comparative clinical evaluation of buccal fat pad and collagen in surgical management of oral sub mucous fibrosis. Arch Dent Sci 2011;2:15-22.
17. Gupta RL. Fate of collagen sheet cover for artificially created raw areas (exptal study). Int J Surg 1978;40:641-5.
18. Mitchell R. A new biological dressing for areas denuded of mucous membrane. A preliminary report. Br Dent J 1983;155:346-8.
19. Rapidis AD, Alexandridis CA, Eleftheriadis E, Angelopoulos AP. The use of the buccal fat pad for reconstruction of oral defects: Review of the literature and report of 15 cases. J Oral Maxillofac Surg 2000;58:158-63.
20. Mokal NJ, Raje RS, Ranade SV, Prasad JS, Thatte RL. Release of oral submucous fibrosis and reconstruction using superficial temporal fascia flap and split skin graft – A new technique. Br J Plast Surg 2005;58:1055-60.
21. Kavarana NM, Bhathena HM. Surgery for severe trismus in submucous fibrosis. Br J Plast Surg 1987;40:407-9.
22. Maria A, Sharma Y, Kaur P. Use of nasolabial flap in the management of oral submucous fibrosis - A clinical study people's. J Sci Res 2011;4:28-30.
23. Martín-Granizo R, Naval L, Costas A, Goizueta C, Rodriguez F, Monje F, *et al.* Use of buccal fat pad to repair intraoral defects: Review of 30 cases. Br J Oral Maxillofac Surg 1997;35:81-4.
24. Wei FC, Chang YM, Kildal M, Tsang WS, Chen HC. Bilateral small radial forearm flaps for the reconstruction of buccal mucosa after surgical release of submucosal fibrosis: A new, reliable approach. Plast Reconstr Surg 2001;107:1679-83.
25. Huang JJ, Wallace C, Lin JY, Tsao CK, Kao HK, Huang WC, *et al*. Two small flaps from one anterolateral thigh donor site for bilateral buccal mucosa reconstruction after release of submucous fibrosis and/or contracture. J Plast Reconstr Aesthet Surg 2010;63:440-5.
26. Omura S, Mizuki N, Horimoto S, Kawabe R, Fujita K. A newly developed collagen/silicone bilayer membrane as a mucosal substitute: A preliminary report. Br J Oral Maxillofac Surg 1997;35:85-91.
27. Nayak DR, Mahesh SG, Aggarwal D, Pavithran P, Pujary K, Pillai S. Role of KTP-532 laser in management of oral submucous fibrosis. J Laryngol Otol 2009;123:418-21.
28. Kerr AR, Warnakulasuriya S, Mighell AJ, Dietrich T, Nasser M, Rimal J, *et al.* A systematic review of medical interventions for oral submucous fibrosis and future research opportunities. Oral Dis 2011;17 Suppl 1:42-57.
29. Ram R, Goyal S, Pandher PK, Singh Chawla JP. An approach to management of oral submucous fibrosis: Current status and review of literature. Int J Curr Res 2014;6:10598-604.
30. Kamath VV. Surgical interventions in oral submucous fibrosis: A systematic

analysis of the literature. J Maxillofac Oral Surg 2015;14:521-31.
31. Fedorowicz Z, Chan Shih-Yen E, Dorri M, Nasser M, Newton T, Shi L. Interventions for the management of oral submucous fibrosis. Cochrane Database Syst Rev 2008:CD007156.
32. Qureshi SS, Chaukar D, Dcruz AK. Simple technique of securing intraoral skin grafts. J Surg Oncol 2005;89:102-3.
33. Sharp GS, Helsper JT. Intra-oral cancer. The use of skin grafts in the management of the condition. Calif Med 1964;100:332-5.
34. Yen DJ. Surgical treatment of submucous fibrosis. Oral Surg Oral Med Oral Pathol 1982;54:269-72.
35. Soh CL, Muthusekhar MR. Treatment of oral submucous fibrosis using split skin graft and a polyethylene stent: a prospective study. J Maxillofac Oral Surg 2015;14:370-3.
36. Goshgarian G, Miller TA. The "parachute" stent. Am J Surg 1975;130:370.
37. Friedlander AH, Miller J. Stabilization of intraoral skin grafts to the cheek. J Oral Surg 1981;39:63.
38. Jundt JS, Odom KW, Wilson JW. Intraoral split-thickness skin grafts: A new approach using vinyl polysiloxane. J Oral Maxillofac Surg 2011;69:1255-7.
39. Patil PG, Patil SP. Novel mouth-exercising device for oral submucous fibrosis. J Prosthodont 2012;21:556-60.
40. Angadi PV, Rao S. Management of oral submucous fibrosis: An overview. Oral Maxillofac Surg 2010;14:133-42.
41. Cox S, Zoellner H. Physiotherapeutic treatment improves oral opening in oral submucous fibrosis. J Oral Pathol Med 2009;38:220-6.
42. Le PV, Gornitsky M, Domanowski G. Oral stent as treatment adjunct for oral submucous fibrosis. Oral Surg Oral Med Oral Pathol Oral Radiol Endod 1996;81:148-50.
43. Heller F, Wei FC, Chang YM, Tsai CY, Liao HT, Lin CL, *et al.* A non-tooth-borne mouth-opening device for postoperative rehabilitation after surgical release of trismus. Plast Reconstr Surg 2005;116:1856-9.
44. Patil PG, Parkhedkar RD. New graft-stabilizing clip as a treatment adjunct for oral submucous fibrosis. J Prosthet Dent 2009;102:191-2.
45. Zhang Q, Qian YL, Cui L. Experimental study of actin and myosin in the scar tissue. Zhongguo Xiu Fu Chong Jian Wai Ke Za Zhi 2001;15:32-5.

How to cite this article: Nanavati S, Nanavati P, Nanavati M. Surgical Fibrolysis and Skin Grafts in the Management of Oral Submucous Fibrosis. Int J Stud Sci 2016;3(12):43-52.

Source of Support: Nil, **Conflict of Interest:** None declared.