

Significance of Silver Binding Nucleolar Organizer Regions in Oral Squamous Cell Carcinomas

Ritu Sharma¹, Gaurav Kumar²

¹Assistant Professor, Department of Pathology, Hind Institute of Medical Sciences, Dr. RML Avadh University, Lucknow, Uttar Pradesh, India,

²Assistant Professor, Department of ENT, TSM Hospital & Medical College, Lucknow, Uttar Pradesh, India

Abstract

Background: Cell proliferation is an important factor in the prognosis of malignant neoplasia. The number of argyrophilic nucleolar organizer regions (AgNORs) per cell has been considered as an indicator of the cellular proliferative activity. A study is carried out to examine whether AgNOR numbers relate to the growth rate in squamous cell carcinoma (SCC) of the oral cavity.

Aim: To verify the relationship between total AgNORs mean value (mAgNOR) and/or the percentage of cells exhibiting five or more AgNOR dots/nucleus/100 cells AgNORs (proliferative index [pAgNOR]) with histopathologic grading of oral SCC according to Broder's grading.

Materials and Methods: This was a prospective study done over a period of 3 years from May 2012 to June 2015. A total of 50 cases of oral SCC were graded into three groups according to Broder's grading, namely well-differentiated, moderately differentiated, and poorly differentiated. For NOR study, 3-5 μ m-thick sections were stained with 50% aqueous silver nitrate solution. The predominant microscopic pattern of NORs was determined. Quantitative and qualitative analyses of NORs were obtained of all cells present on each histological field. AgNORs were stained by a one-step silver method and examined in representative paraffin sections from 50 cases of oral SCC.

Results: The mAgNORs per nucleus was 3.3057 ± 0.11 for the well-differentiated group, 5.324 ± 0.43 for the moderately differentiated, and 8.167 ± 0.22 for the poorly differentiated. The proliferative index in well-differentiated pAgNOR count is 25%, in moderately differentiated count it is 49.7%, and in poorly differentiated count it is 65.4%.

Conclusions: AgNOR staining technique seems to be a useful diagnostic tool since differences in AgNOR numeric values can be identified in the different types of oral SCC. This technique is easy to handle and inexpensive, thus justifying its large use in histopathology.

Key words: Argyrophilic nucleolar organizer regions, Nucleolar organizer regions, Oral squamous cell carcinoma

INTRODUCTION

In 1941, Broders¹ related the extent of malignancy in neoplasms and emphasized the correlation between histological tumor differentiation, their treatment, and prognosis. The majority of oral and pharyngeal cancers were squamous cell carcinoma (SCC). Out of which, 91.6% occurred in the oral cavity.² Oral SCC represents the third most common form of malignancy in the developing

countries whereas in the developed countries, it is the eighth most common malignancy.^{3,4} The most widespread is the chewing of betel quid with tobacco that have been demonstrated as an increased risk for cancers of the oral cavity.

Quantification of argyrophilic nucleolar organizer regions (AgNORs) is a valuable parameter in tumor pathology. Studies have shown the higher number of AgNORs in malignant lesions such as SCC, which are associated with poor prognosis. NORs are the loop of DNA that encode ribosomal RNA and are considered important in the synthesis of protein. They are located on the short arm of acrocentric chromosomes - 13, 14, 15, 21, and 22. Many of them bind silver, a property attributed to proteins associated with these sites, particularly the acidic

Access this article online



www.ijss-sn.com

Month of Submission : 01-2015
Month of Peer Review : 02-2016
Month of Acceptance : 02-2016
Month of Publishing : 03-2016

Corresponding Author: Dr. Ritu Sharma, 1404 HIG, Sector-I, LDA Colony, Kanpur Road, Lucknow - 226 012, Uttar Pradesh, India.
 Phone: +91-9455149391. E-mail: drritzsharma@gmail.com

nonhistone components. NOR staining thus represents actively transcribing NORs (thus rDNA) and the frequency of NORs per nucleus may prove to be useful as replication markers.^{5,6} AgNORs reflect the state of activation and the proliferation activity of the cell and degree of malignant transformation of certain tissues. The amount of AgNOR is proportional to the proliferative activity of neoplastic cells into the cell cycle, which progressively increase from G₀ to S phase.⁷ A rapidly dividing tumor population had a greater proportion of cells in the early stages of G₁. Conversely, tumors with a low rate of cell proliferation display a single NOR.⁷ The silver staining technique is not able to recognize rDNA and rRNA, but the acidic proteins associated with these sites of rRNA transcription are designated as B23, C23, “AgNOR” proteins, and RNA polymerase I.⁸ NORs have got importance nowadays more because the frequency within the nuclei is much higher in malignant cells than in normal cells, reactive, or benign neoplastic cells.⁸

Morphological Characteristics - Qualitative Assessment

Morphological variations of AgNORs were assessed regarding the size and shape of the individual AgNOR dots and their pattern of distribution, as defined by Khan *et al.*, 2006,⁹ who identified different patterns of AgNOR size and distribution:

The grading of size variation was performed according to Khan *et al.*⁹ and scores of distribution were given as following:

- 0 - More or less uniform in size;
- 1+ - Two different sizes;
- 2+ - More than two different sizes (but not those of 3+);
- 3+ - Including all grades and sizes.

The dots dispersion grading was performed according to Khan *et al.*⁹ and scores of AgNOR dots were given as following:

- 0 - Limited to nucleoli;
- 1+ - Occasional dispersion outside nucleoli;
- 2+ - Moderate dispersion outside nucleoli;
- 3+ - Widely dispersed throughout nucleus.

MATERIALS AND METHODS

The present study is undertaken in the Pathology Department of Mahatma Gandhi Medical College and Hospital, Jaipur. A total of 50 cases were studied from May 2012 to June 2015. The cases are referred from ENT Department having growth in the oral cavity (Figure 1a and b) biopsy taken, and sent for histopathological examination. These are broadly classified into three groups according to Broder’s¹ grading of histopathological reports as well differentiated (Figure 2a and b), moderately differentiated (Figure 3a

and b), and poorly differentiated (Figure 4a and b), SCC (Table 1).

The biopsy specimens which were received subjected to proper fixation in 10% formal saline after that followed by

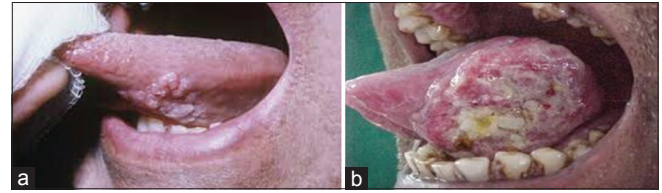


Figure 1: (a) Carcinoma of base of tongue, (b) carcinoma of lateral border of tongue

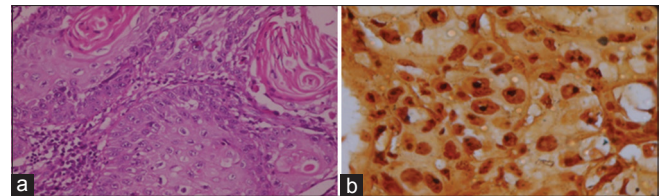


Figure 2: (a) Well- differentiated squamous cell carcinoma (H and E, x40), (b) more or less uniform size argyrophilic nucleolar organizer regions (AgNORs) dots/nucleus (AgNOR stain, x100)

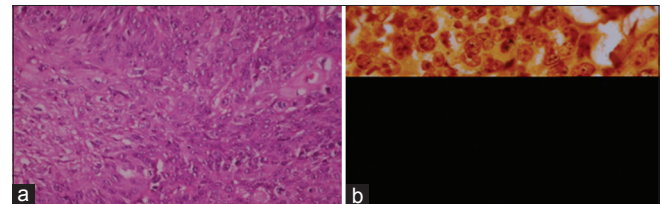


Figure 3: (a) Moderately- differentiated squamous cell carcinoma (H and E, x40), (b) grade “1+” score argyrophilic nucleolar organizer regions (AgNOR) size (AgNOR stain, x100)

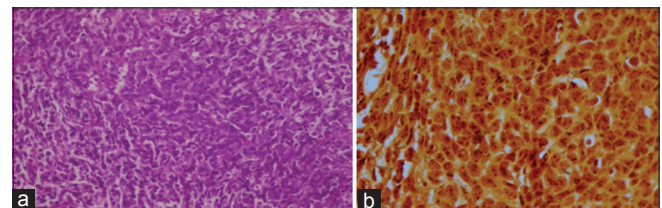


Figure 4: (a) Poorly- differentiated oral squamous cell carcinoma (H and E, x40), (b) great amount and highly stained argyrophilic nucleolar organizer regions (AgNOR) dots (AgNOR stain, x100)

Table 1: Classification of patients according to Broder’s grading

Groups	Number of cases
Group I (WDSCC)	19
Group II (MDSCC)	22
Group III (PDSCC)	9

WDSCC: Well-differentiated squamous cell carcinoma, MDSCC: Moderately-differentiated squamous cell carcinoma, PDSCC: Poorly-differentiated squamous cell carcinoma

routine paraffin sectioning at 3-4 μm thickness. AgNOR staining was performed as described by Ploton *et al.*^{6,10} First, the samples were de-waxed in xylene and then rehydrated through graded ethanols to distilled water. The silver nitrate solution was prepared by mixing two parts of 50% silver nitrate solution with 2 g of gelatin in 100 ml of 1% formic acid in distilled water. The sections are incubated in this solution in dark at room temperature for 60 min and then washed with de-ionized water. This is followed by pair dehydration in graded alcohol solutions, cleared in xylene, and mounted in Canada balsam. AgNORs are seen as distinct intranuclear black dots and are randomly counted manually in 100 nuclei under ×1000 magnification with oil immersion in the three groups. Finally, the mean value and standard deviation of an each case are determined.

AgNORs are seen as distinct intranuclear black dots and were counted manually in 100 epithelial nuclei under ×100 magnifications with oil immersion in different groups. Finally, the mean value and standard deviation of each group are determined and tabulated. One-way ANOVA was used to compare these groups. The mean of AgNOR (mAgNOR) is compared in each group separately using unpaired *t*-test. The data obtained are tabulated in the master charts of the various histological grades/groups in oral SCC. The qualitative assessment of AgNORs based on their size, shape, and the pattern of distribution was processed using frequencies, percentages, and Chi-square test.

The mAgNORs in a different grade of oral SCC per nucleus was 3.3057 ± 0.11 for the well-differentiated group, 5.324 ± 0.43 for the moderately differentiated, and 8.167 ± 0.22 for the poorly differentiated group (Figure 5). According to one-way ANOVA, a significant difference was seen in the number of AgNOR dots between the groups ($P < 0.001$) (Table 2). The second count was the proliferative index (pAgNOR) which is defined as the percentage of nuclei exhibiting five or more AgNOR granules/nucleus/100 cells (Figure 6). This count represents the proliferative activity of tumors cells. High proliferative activity in tumors is considered when there is pAgNOR count of 8% or more (Table 3).¹¹

RESULTS

Clinical data obtained from medical records are compiled according to the tumor site such as 23 cases of the lateral border of tongue, 14 of the base of tongue, 6 of retromolar trigone, and 7 of buccal mucosa. The age of the patients ranged from 31 to 80 years at the time of diagnosis of neoplasm. Regarding the gender, 36 were male and 14 were female. AgNORs were seen through light microscope

Table 2: Distribution based on AgNOR counts (mean and range) in different grades/groups

Broder's grade of oral SCC	Number of subject	mAgNOR count	Standard deviation
WDSCC	19	3.3057	0.11
MDSCC	22	5.3241	0.43
PDSCC	9	8.1677	0.22

SCC: Squamous cell carcinoma, WDSCC: Well-differentiated squamous cell carcinoma, MDSCC: Moderately-differentiated squamous cell carcinoma, PDSCC: Poorly-differentiated squamous cell carcinoma, AgNORs: Argyrophilic nucleolar organizer regions

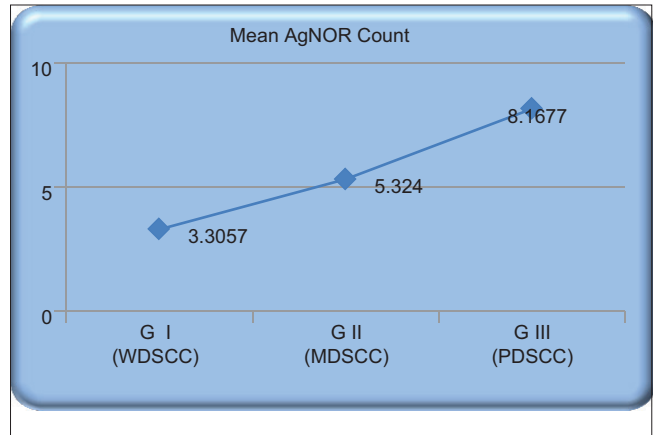


Figure 5: Distribution based on mean argyrophilic nucleolar organizer regions count in different grades of oral squamous cell carcinoma

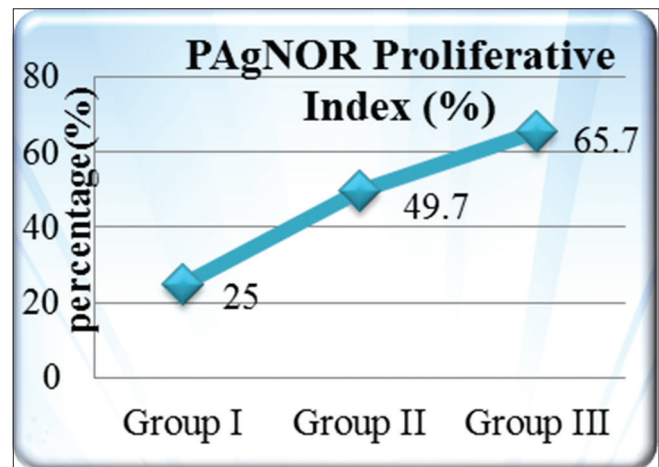


Figure 6: Proliferative index of argyrophilic nucleolar organizer regions count in different grades/groups of oral squamous cell carcinoma

inside the cell nuclei as black to brownish dots as the yellow staining allowed easy visualization of individual NORs. The number and diameter of the NORs, usually round, were variable and either diffusely distributed all over the nuclear area or grouped in a wide, round, and less intensely stained structure. Qualitative assessment was done according to Khan *et al.*⁹ and scores of dot distribution were given

Table 3: Comparison of mAgNOR count, pAgNOR, size, and distribution per cell between different grades/groups of oral squamous cell carcinoma

Grades	Number of cases	mAgNOR count per cell	pAgNOR (percentage of nuclear with >5 AgNOR dots/nuclear)	AgNOR variation in size per cell	AgNOR dispersion per cell
WDSCC	19	3.306	25	0.263	0.263
MDSCC	22	5.324	49.7	0.454	0.41
PDSCC	9	8.167	65.4	1.22	0.88

SCC: Squamous cell carcinoma, WDSCC: Well-differentiated squamous cell carcinoma, MDSCC: Moderately-differentiated squamous cell carcinoma, PDSCC: Poorly-differentiated squamous cell carcinoma, pAgNORs: Proliferative index argyrophilic nucleolar organizer regions, mAgNORs: Mean argyrophilic nucleolar organizer regions

as: 0 - more or less uniform in size; 1+ - two different sizes; 2+ - more than two different sizes (but not those of 3+); 3+ - including all grades and sizes. The grading dots dispersion was performed according to Khan *et al.*⁹ and scores of dispersion of AgNOR dots were given as following: 0 - limited to nucleoli; 1+ - occasional outside nucleoli; 2+ - moderate outside nucleoli; and 3+ - widely throughout the nucleus.

DISCUSSION

Although conventional histological staining with hematoxylin and eosin may be useful in the determination of dysplastic changes in precancerous lesions and grading of SCC, sometimes it is difficult to differentiate these lesions with this staining technique. In such cases, AgNORs staining seems to be useful. The AgNOR counts increase with increased cell ploidy and with increased transcriptional activity in the stages of active cell proliferation.¹² Variations in the size and number of the AgNOR dots may depend on the stage of the cell cycle, the number of NOR-bearing chromosomes in the karyotype, or the transcriptional and metabolic activity of the cell. In a rapidly proliferating cell, AgNOR distribution and the chromosomal remain disorganized with the resultant formation of small, multiple, and dispersed nucleoli. Actively proliferating cells have impaired nucleolar association, and therefore, they exhibit a higher AgNOR count, regardless of the ploidy state of the cell.

In the present study, results of 50 cases were compared according to age, sex, sites of lesions, evaluated quantitative, and qualitative AgNOR counts in the different grades of oral SCC with the study done by other workers, and it was suggested that AgNOR staining can be used to differentiate different grades of oral SCC.

CONCLUSION

The present study shows the importance of AgNORs in the various grades of oral SCC. Although conventional histological staining with hematoxylin and eosin may be useful in the grading of SCC and determination of dysplastic changes in precancerous lesions, sometimes it is

difficult to differentiate these lesions with this conventional staining technique. In such cases, AgNORs staining seems to be beneficial and useful. It has been established that quantification of interphase AgNORs can actually represent a valuable tool for cell kinetics evaluation. The AgNOR counts increase with increased cell ploidy and with increased transcriptional activity in the stages of active cell proliferation.

Of the various newer techniques which were used for assessing the tumor tissue based on nuclear studies, the staining of AgNORs by a silver compound has become popular for its:

- Simplicity than other various techniques
- Ease of use and to carry out
- Low cost of staining
- Good correlation with other proliferative markers of tumors.

Finally, AgNORs (mAgNOR and pAgNOR) counting have a direct relationship with Broder's histopathologic grading, leading us to suggest that AgNOR technique can be used as a biological marker of oral SCC tumor progression.

REFERENCES

1. Broders AC. The microscopic grading of cancer. *Surg Clin North Am* 1941;21:947-61.
2. Chamani G, Zarei MR, Rad M, Hashemipour M, Haghdoost AA. Epidemiological aspects of oral and pharyngeal cancer in Kerman Province, South Eastern Iran. *Iran J Publ Health* 2009;38:90-7.
3. Johnson NW. How great is the risk? In: John NW, editor. *Risk Markers for Oral Diseases. Oral Cancer. Detection for Patients and Lesions at Risk. Vol. 2.* Cambridge: University Press; 1991. p. 3-27.
4. Bhosle RB, Murti PR, Gupta PC. Tobacco habits in India. In: *Control of Tobacco Related Cancers and Other Diseases. Proceedings of an International Symposium, 5-19 January. Bombay: Oxford University Press; 1990. p. 25-46.*
5. Chattopadhyay A. AgNORs in tumoral pathology. Review of literature and observations on the technic and reaction in normal oral epithelium. *Indian J Dent Res* 1993;4:47-53.
6. Crocker J, Boldy DA, Egan MJ. How should we count AgNORS? Proposals for a standardized approach. *J Pathol* 1989;158:185-8.
7. Cabrini RL, Schwint AE, Mendez A, Femopase F, Lanfranchi H, Itoiz ME. Morphometric study of nucleolar organizer regions in human oral normal mucosa, papilloma and squamous cell carcinoma. *J Oral Pathol Med* 1992;21:275-9.
8. Underwood JC, Giri DD. Nucleolar organizer regions as diagnostic

- discriminants for malignancy. *J Pathol* 1988;155:95-6.
9. Khan SA, Chaudhry NA, Khalid AW, Akhtar GN, Ibne-Rasa SN. Patterns of argyrophilic nucleolar organiser regions in pleural and peritoneal effusions. *J Coll Physicians Surg Pak* 2006;16:412-5.
 10. Orrell JM, Evans AT, Grant A. A critical evaluation of AgNOR counting in benign naevi and malignant melanoma. *J Pathol* 1991;163:239-44.
 11. Mourad WA, Vallieres E, Chuen J, Alrobaish A. Cell kinetics analysis of surgically resected non-small cell carcinoma of the lung using the AgNOR silver stain. *Ann Saudi Med* 1997;17:161-6.
 12. Abbas NF, Abbas EA, Aal WE. Image cytometric analysis of mean nuclear area and nucleolar organizer regions (AgNORs) in oral squamous cell carcinoma. *Egypt Med J NRC* 2002;1:141-57.

How to cite this article: Sharma R, Kumar G. Significance of Silver Binding Nucleolar Organizer Regions in Oral Squamous Cell Carcinomas. *Int J Sci Stud* 2016;3(12):193-197.

Source of Support: Nil, **Conflict of Interest:** None declared.