

Ophthalmological Manifestations of Dengue Fever During an Epidemic in a Tertiary Care Hospital of West Bengal

M Nazarul Islam¹, Pampa Halder², Sushmita Mukherji³, Begam Sabiha Masuda Khanam³

¹Associate Professor, Department of Ophthalmology, R. G. Kar Medical College, Kolkata, West Bengal, India, ²Assistant Professor, Department of Ophthalmology, R. G. Kar Medical College, Kolkata, West Bengal, India, ³Post Graduate Trainee, Department of Ophthalmology, R. G. Kar Medical College, Kolkata, West Bengal, India

Abstract

Introduction: Dengue is a fast resurging arthropod-borne viral infection causing ocular complications which has not been classically described in literature. Here, ocular findings in patient suffering from were studied.

Materials and Methods: This study was conducted on 90 cases diagnosed with dengue fever (DF) from the 1st May to the 30th September, 2015 at R. G. Kar Medical College and Hospital during an epidemic. All the patients were evaluated with regard to thorough systemic and ophthalmological examination.

Results: Out of the 90 patients diagnosed with DF, 54 (60%) were males and 36 (40%) were females. Mean age group was 34 years (Range: 10-70 years). 73 (81.11%) patients were having bilateral visual symptoms; 17 (18.88%) noted unilateral symptoms. 38(42.22%) had a vision 6/60 or worse. 74 (82.22%) patients were presented with defective central vision (relative scotoma). The anterior segment findings were subconjunctival hemorrhage in 73 (81.11%) and anterior uveitis in 3 (6%) cases, respectively. The posterior segment changes were macular edema in 74 (82.22%), retinal vasculitis in 24 case; among this, there were involvement of macular vasculature in 6 cases and pan retinal vasculitis in 18 patients, respectively. All the ocular changes resolved on 8-12 weeks follow-up along with a normal platelet count.

Conclusion: With the rise in the frequency of varied and serious ocular complications, each and every case of DF requires an immediate thorough ophthalmological assessment and follow-up for prevention of sight-threatening dreaded consequences.

Key words: Dengue fever, Ophthalmologic manifestations, Retrobulbar pain, Subconjunctival hemorrhage

INTRODUCTION

Dengue virus is the fastest reemerging flavivirus infection in humans today. It is transmitted to human arises by bite of *Aedes aegypti* mosquito. It has become a worldwide public health problem, especially affecting the Southeast Asia and its illness exceeds approximately 100 million/year.¹⁻³ The clinical symptoms of dengue are sudden onset of fever along with symptoms of malaise, headache, rhinitis, sore throat, cough, generalized body ache, retroorbital

and lumbosacral pain, and rash. The clinical signs ranging from subconjunctival hemorrhage to vision-threatening complications such as optic neuropathy and panophthalmitis have been reported in literature.^{1,3-6} The classical descriptions of ophthalmic manifestations have not yet been reported except a few isolated case reports.⁷⁻¹⁴ However, the ocular involvement in patients with dengue has been observed in recent times. Owing to the warm and temperate climate in Kolkata of West Bengal, there is an increased surge of dengue cases every year; thus, our attention was attracted to study the ocular findings associated with dengue fever (DF).

MATERIALS AND METHODS

This was a prospective, observational study comprising 90 patients with DF during an epidemic between the 1st May and the 30th December, 2015 at R. G. Kar Medical

Access this article online



www.ijss-sn.com

Month of Submission : 01-2016
Month of Peer Review : 02-2017
Month of Acceptance : 02-2017
Month of Publishing : 03-2017

Corresponding Author: Dr. M Nazarul Islam, 75, Dr. Biresh Guha Street, Kolkata - 700 017, West Bengal, India. Phone: +91-9433114913.
E-mail: nazarul_islam24@yahoo.cpm

College and Hospital in Kolkata, West Bengal, a state from Eastern India.

The DF and dengue hemorrhagic fever was made on the basis of WHO guidelines, i.e., fever with thrombocytopenia ($<100 \times 10^9$ cells/L and hemoconcentration (hematocrit $>20\%$ above baseline).¹⁵ Further confirmation was done by serological assay, i.e., immunoglobulin (IgM) and IgG antibody assay and markedly reduced platelet counts. A detailed and meticulous clinical history with emphasis on visual symptoms was taken in all patients. Recording of unaided and aided visual acuity was measured with Snellen charts. Following this, a detailed anterior and posterior segment evaluation with the help of Slit-lamp biomicroscopy and direct and indirect ophthalmoscopy, respectively, was carried out for significant ocular changes. The fundus photograph was taken using the fundus camera. All the patients underwent testing of visual fields by Humphrey automated visual field analyzer (HVF) and ocular coherence tomography (OCT), Amsler charting, and fundus fluorescein angiography. Recruited cases were followed up for 12 weeks. Prior informed consents were taken from all the patients.

RESULTS

Out of the 90 patients diagnosed with DF, 54 (60%) were males and 36 (40%) were females with a mean age of 35 years (10-70 years) as mentioned in Table 1 and Figure 1. All of the patients presented with fever.

Symptoms

Defective vision was the most common presentation, 73 (81.11%) patients were having bilateral visual symptoms; 17 (18.88%) noted unilateral symptoms. Visual acuity ranged from 6/9 to fingers counting only. 38 (42.22%) had vision 6/60 or worse. 74 (82.22%) patients, who presented with reduced central vision (relative scotoma) confirmed by Amsler charting and automated HVF testing.

Signs

In majority of cases, the most common anterior segment findings among the patients with DHF were subconjunctival hemorrhages in 37 (81.11%) patients depicting in Table 2 and Figure 1. Anterior uveitis was found in 3(6%) patient as showing in Table 2 and Figure 2. The most common posterior segment findings were macular edema in 74 (82.22%) patients. There was retinal vasculitis in 24 cases; among these patients, 6 (6.66%) involved the macular vasculature and 18 patients had pan retinal vasculitis. Other findings with lesser importance were perifoveal telangiectasia and cotton wool spots at the peripheral retina. Two patients were lost to follow-up, may be due to restoration of vision to premorbidity level. In all the above-mentioned cases, the ocular features resolved over the next 8-12 weeks.

Table 1: Sex distribution of study population

Total number of patients	Male (%)	Female (%)
90	54 (60)	36 (40)

Table 2: Various ocular features in dengue patients (n=90)

Ocular features	Number of patients (%)
Anterior segment	
Subconjunctival haemorrhage	73 (81.11)
Anterior uveitis	3 (6)
Posterior segment findings	
Macular edema	74 (82.22)
Retinal vasculitis	24
Macular vasculature	6
Panretinal vasculitis	18

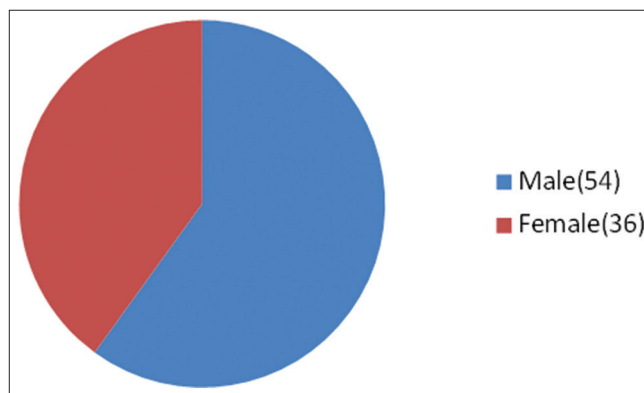


Figure 1: Sex distribution in study population

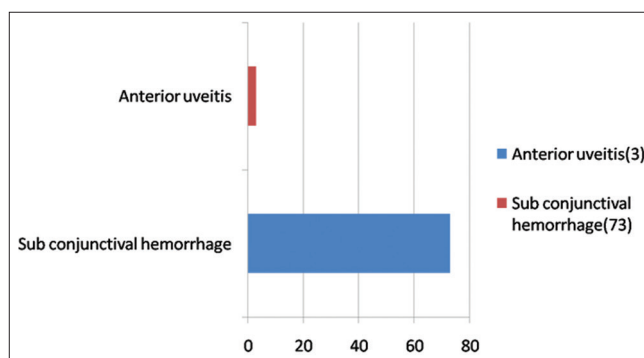


Figure 2: Anterior segment features in dengue patients (n=90)

DISCUSSION

The mechanism of the wide spectrum of ocular findings in DF is not well known. However, it clearly depicts immune-mediated process and possibly infective etiology.¹⁶ The possible causes of hemorrhage could be reduced platelet count, i.e., thrombocytopenia with coagulation defects, capillary fragility, consumptive coagulopathy, and platelet dysfunction.⁶ In this study, we assumed that the increased incidence of visual morbidity was due to the complications

located in macula leading to visual impairment resulting from poor central vision. However, increased number of dengue-related complications was seen, including changes in the retinal periphery without any associated significant visual impairment. Macular edema with subtle microangiopathy with minimal functional disturbance may also be unreported by the patient. OCT and FFA would be helpful to detect these subtle findings. The chemical mediators causing capillary leakage may form the basis for resulting macular edema and breakdown of the aqueous blood barrier, resulting in anterior uveitis and periphlebitis.⁷

There was a male preponderance which is similar to the earlier study by Kapoor *et al.*⁵ and Hussain *et al.*¹⁷ The mean age group of patients included in our study was found to be 35 years which is corroborative with the study of Halstead³ and Haritoglou *et al.*⁸ The most notable finding was subconjunctival hemorrhage followed by retinal hemorrhages which were similar to studies of Kapoor *et al.*⁵ and Hussain *et al.*¹⁷

In the present study, ophthalmic findings varied involving both anterior segment and posterior segment in contrast to the study of Lim *et al.*⁷ whose study depicted features mainly confined to the macula.

In our study, subconjunctival hemorrhage was in 73 (81.11%) patients which is corroborative with the earlier findings noted by Kapoor *et al.*⁵ In another study, it has been reported that subconjunctival hemorrhage was in 3 eyes of 50 patients (65 eyes) suffering from DF.¹⁸

However, Kapoor *et al.*⁵ and Hussain *et al.*¹⁷ reported bilateral periorbital ecchymosis or unilateral ptosis and proptosis secondary to anterior orbital and retrobulbar hemorrhage, respectively, which was not found in any case among our sample of study population with dengue.

All our patients with ocular complications had platelet count <50,000/ μ l. The association of such thrombocytopenia with the development of ocular features has been supported previously by several other studies.^{19,17,19} It was also noted that ocular morbidity was in close to the day of the lowest serum platelet level.

CONCLUSION

Dengue is an old disease and is endemic in tropical countries. Dengue virus results in a spectrum of ocular

manifestations, ranging from non-specific symptoms to severe vision-threatening complications. Although most common manifestation is subconjunctival hemorrhage, retinal hemorrhages can also occur. With increasing epidemicity and cocirculation of multiple dengue serotypes, an increase in the occurrence of DF and dengue-related ophthalmic morbidity can be expected. An awareness for ocular complications and hence, prompt referral for ophthalmologic assessment and management is required. Increased awareness regarding early treatment of ocular complications and institutionalization is of utmost importance.

REFERENCES

1. Chan DP, Teoh SC, Tan CS, Nah GK, Rajgopalan R, Prabhakaragupta MK, *et al.* The eye institute dengue-related ophthalmic complications workgroup: Ophthalmic complications of dengue. *Emerg Infect Dis* 2006;12:285-9.
2. Halstead SB. Mosquito-borne haemorrhagic fevers of South and South-East Asia. *Bull World Health Organ* 1966;35:3-15.
3. Halstead SB. Global epidemiology of dengue hemorrhagic fever. *Southeast Asian J Trop Med Public Health* 1990;21:636-41.
4. Yip VC, Sanjay S, Koh YT. Ophthalmic complications of dengue fever: A systematic review. *Ophthalmol Ther* 2012;1:2.
5. Kapoor HK, Bhai S, John M, Xavier J. Ocular manifestations of dengue fever in an East Indian epidemic. *Can J Ophthalmol* 2006;41:741-6.
6. Teoh SC, Chan DP, Nah GK, Rajagopalan R, Laude A, Ang BS, *et al.* A re-look at ocular complications in dengue fever and DHF. *Dengue Bull* 2006;30:184-93.
7. Lim WK, Mathur R, Koh A, Yeoh R, Chee SP. Ocular manifestations of dengue fever. *Ophthalmology* 2004;111:2057-64.
8. Haritoglou C, Scholz F, Bialasiewicz A, Klaus V. Ocular manifestation in dengue fever. *Ophthalmologie* 2000;97:433-6.
9. Wen KH, Sheu MM, Chung CB, Wang HZ, Chen CW. The ocular fundus findings in dengue fever. *Gaoxiong Yi Xue Ke Xue Za Zhi* 1989;5:24-30.
10. Deutman AF, Bos PJ. Macular bleeding in dengue fever. *Klin Monbl Augenheilkd* 1979;175:429.
11. Spitznas M. Macular haemorrhage in dengue fever. *Klin Monbl Augenheilkd* 1989;175:429.
12. Nainiwal S, Garg SP, Prakash G, Nainiwal N. Bilateral vitreous haemorrhage associated with dengue fever. *Eye (Lond)* 2005;19:1012-3.
13. Haritoglou C, Dotse SD, Rudolph G, Stephan CM, Thureau SR, Klaus V. A tourist with dengue fever and visual loss. *Lancet* 2002;360:1070.
14. Siqueira RC, Vitral NP, Campos WR, Oréfice F, de Moraes Figueiredo LT. Ocular manifestations in dengue fever. *Ocul Immunol Inflamm* 2004;12:323-7.
15. *Emerging Infectious Diseases*. Vol. 12. No. 2. February; 2006. Available from: www.cdc.gov/eid.
16. Chhina DK, Goyal O, Goyal P, Kumar R, Puri S, Chhina RS. Haemorrhagic manifestations of dengue fever and their management in a tertiary care hospital in North India. *Indian J Med Res* 2009;129:718-20.
17. Hussain I, Afzal F, Shabbir A, Adil A, Zahid A, Tayyib M. Ophthalmic manifestation of dengue fever. *Ophthalmol Update* 2012;10:93-6.
18. Mehta S. Ocular lesions in severe dengue hemorrhagic fever (DHF). *J Assoc Physicians India* 2005;53:656-7.
19. Nagaraj KB, Jayadev C, Yajmaan S, Prakash S. An unusual ocular emergency in severe dengue. *Middle East Afr J Ophthalmol* 2014;21:347-9.

How to cite this article: Islam MN, Halder P, Mukherji S, Khanam BSM. Ophthalmological Manifestations of Dengue Fever During an Epidemic in a Tertiary Care Hospital of West Bengal. *Int J Sci Stud* 2017;4(12):204-206.

Source of Support: Nil, **Conflict of Interest:** None declared.