

LASER Assisted Excision of Pyogenic Granuloma Associated with Localized Alveolar Bone Loss: A Case Report

Sidharth Shankar¹,
Shankar T Gokhale²,
Ashish Agarwal³,
R G Shiva Manjunath⁴

¹Post Graduate Student in the Department of Periodontology, Institute of Dental Sciences, Bareilly,
²Professor in the Department of Periodontology, Institute of Dental Sciences, Bareilly, ³Senior Lecturer
in the Department of Periodontology, Institute of Dental Sciences, Bareilly, ⁴Professor & HOD,
Department of Periodontology, Institute of Dental Sciences, Bareilly

Corresponding Author: Dr. Sidharth Shankar, Institute of Dental Sciences, Bareilly,
Mobile: 7499527108, E-mail: sidharth.shankar7@gmail.com

Abstract

Pyogenic granuloma is a primarily reactive hyperplasia which appears in the oral cavity as an overgrowth of tissue due to physical trauma or hormonal factors & irritation. Pyogenic granuloma is a non specific gingival overgrowth seen as a response to underlying irritating factors. The growth is mainly seen in young but it may occur in any age group especially in individuals with poor oral hygiene. Females are far more susceptible than males because of the hormonal changes that occur in women during pregnancy, puberty and menopause. The peak prevalence is in teenagers and young adults, the treatment is excision of the lesion in toto.

Keywords: Granuloma, Gravidarum, Hamartoma, Pyogenic Granuloma, Reactive hyperplasia, Trauma

INTRODUCTION

Pyogenic granuloma was first originally described in 1897 by two French surgeons, Poncet and Dor, who named this lesion botryomycosis hominis. The name for Pyogenic Granuloma is misleading because it is not a true granuloma. In actuality, it is a capillary hemangioma.^{1,2} According to Vilmann et al, majority of the pyogenic granulomas are found on the marginal gingiva with only 15 % of the tumors on the alveolar part. It is reported many times pyogenic granulomas cause significant bone loss.³ Females are far more susceptible than males because of the hormonal changes that occur in women during puberty, pregnancy, and menopause. In many cases, mastication on the lesion causes bleeding and pain and requires surgical intervention before parturition. Some pyogenic granulomas regress after child birth without surgical intervention. Treatment of pyogenic granuloma involves a complete surgical excision. Recurrence of pyogenic granuloma after excision is a known complication but can be prevented. Recurrence rate for pyogenic granuloma is said to be 16 % of the treated lesions and so re excision of such lesions might be necessary. Being a non-neoplastic growth, excisional therapy is the treatment of

choice but some alternative approaches such as cryosurgery, excision by Nd:YAG Laser, flash lamp pulsed dye Laser, injection of corticosteroid or ethanol, and sodium tetradecyl sulphate sclera therapy have been reported to be effective.⁴

So, this case report explains the use of Diode Laser (unilase) for the management of pyogenic granuloma.

CASE REPORT

A 24 years old female patient reported to the department of periodontics, Institute of Dental Sciences Bareilly, with a chief complaint of painless growth of gum in the lower front teeth regionsince 1 year. She also complained of the lesion being associated with bleeding while brushing. The patient was apparently all right when she first noticed the lesion in relation to lingual aspect of lower front teeth region one year back. To start with the lesion was peanut in size and slowly progressed to attain the present size (Figure 1). The patient also noticed loss of contact & presence of spacing between central incisors owing to pressure from this lesion. There was no history of swelling in any other part of the body and had no relevant medical history.

Clinical examination

Extraoral examination

No abnormality detected.

Intraoral examination

Inspection: A solitary discrete gingival over growth was visible between mandibular central incisors on lingual aspect measuring 4×3 mm in size. The growth was roughly oval in shape, colour is varying from pinkish red, and surface was smooth. The growth covered approximately whole of the crown on lingual aspect of mandibular central incisors. The oral hygiene status was found to be poor (Figure 1). Pathologic migration was seen wrt.31,41.

Palpation: The inspectory findings regarding number, site, shape and size were confirmed & the lesion was found to be pedunculated with stalk. The lesion was bleeding on probing.

Radiographic findings: Radiovisiography (RVG) of the involved region demonstrated localized alveolar bone loss suggestive of pressure resorption⁵ (Figure 2).

Blood examination

Revealed normal values.

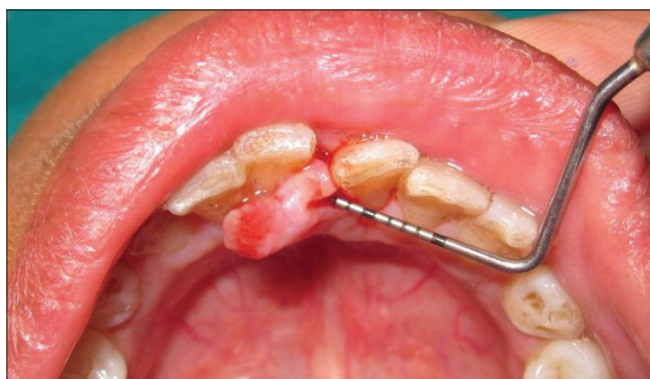

Figure 1: Preoperative photograph

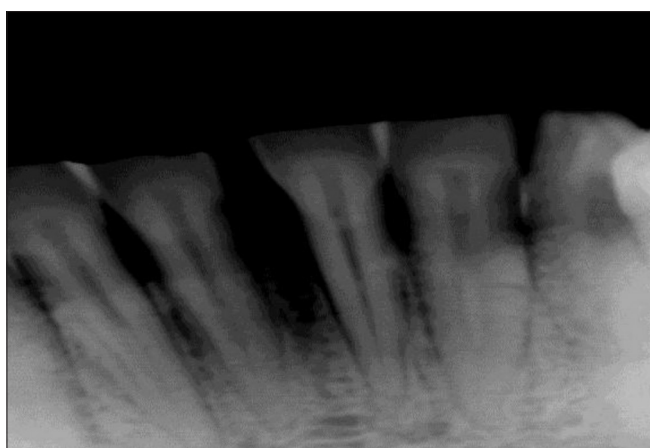


Figure 2: Radiographic picture

HISTOPATHOLOGICAL EXAMINATION

The Hematoxylin & Eosin stained section showed: under scanner view two bits of tissue showed overlying inflamed vascular connective tissue stroma. Low power and high power view showed parakeratinized stratified squamous epithelium with pseudoepitheliomatous hyperplasia in few areas. Stroma also showed plump to spindle shaped fibroblast, with loose to dense collagen fibre bundles suggestive of pyogenic granuloma (Figures 3 and 4).

TREATMENT

The treatment comprised of oral prophylaxis and excisional biopsy of the growth with diode Laser (unilase) 4 Watts. To start with thorough scaling & root planning was carried out & the response to the same was evaluated after 3-4 weeks of time. Then the excisional biopsy of the lesion was done by using diode LASER (unilase-unicorn[®]) 4 watts in toto in the absence of local anaesthesia (Figures 5-7). Following

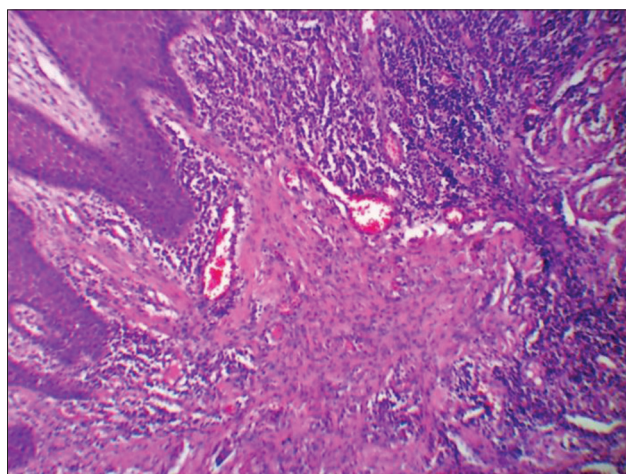


Figure 3: Pyogenic Granuloma 10X Low Power

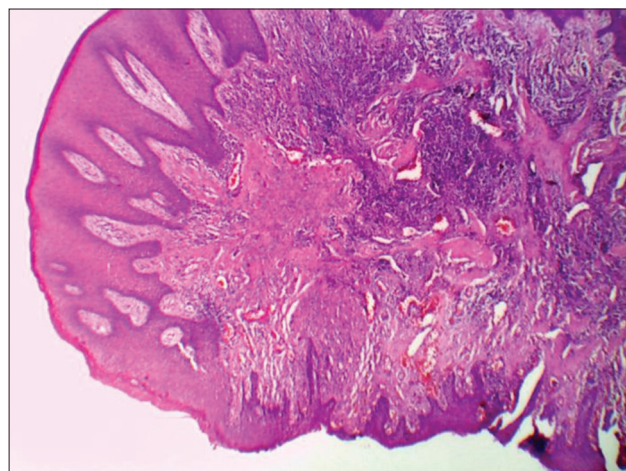


Figure 4: Pyogenic Granuloma 4X Scanner

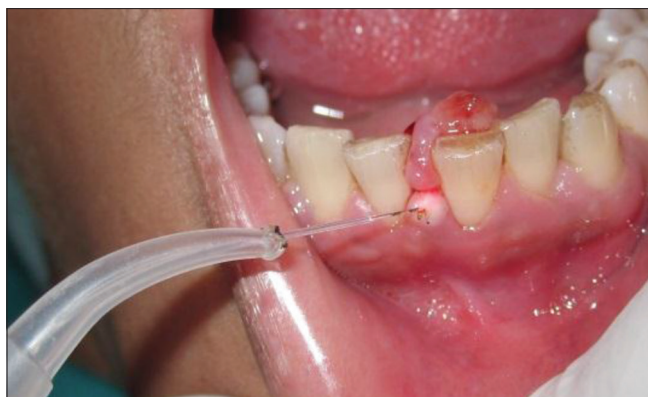

Figure 5: Local excision with laser

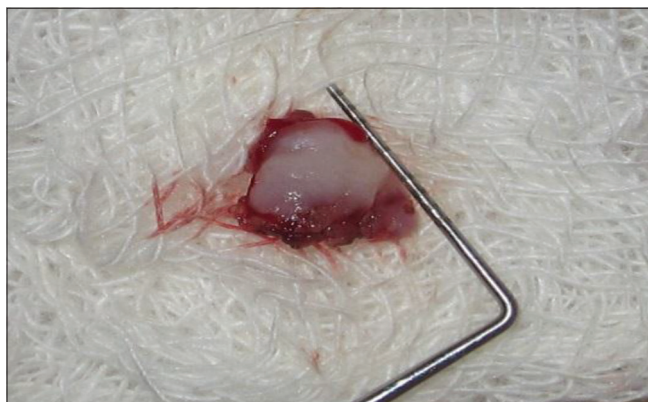

Figure 6: Excised tissue

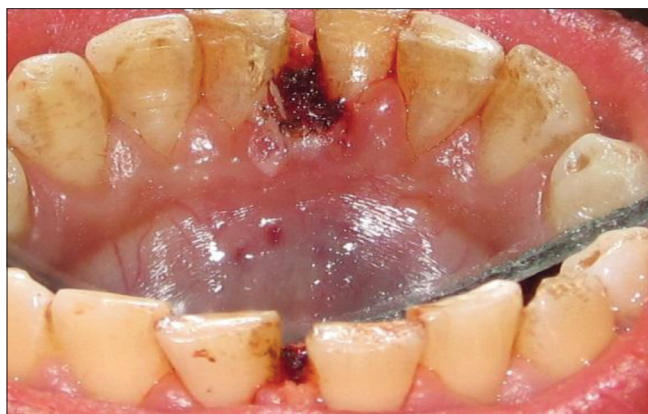

Figure 7: After excision

excision the surgical site was irrigated with normal saline & covered with periodontal dressing (Coe-Pak[®]). Post-operative instruction were given to the patient along with prescription of amoxicillin 500 mg TID, analgesics 500 mg SOS, chlorhexidine mouth wash, 10 ml twice a day for 10 days is given. The patient was recalled after 1 week, the healing of the lingual site was uneventful & the patient was kept under long term maintenance (Figure 8). After 6 month again the patient was recalled for follow up, the healing was focus to be uneventful & satisfactory without any sign of recurrence (Figure 9).

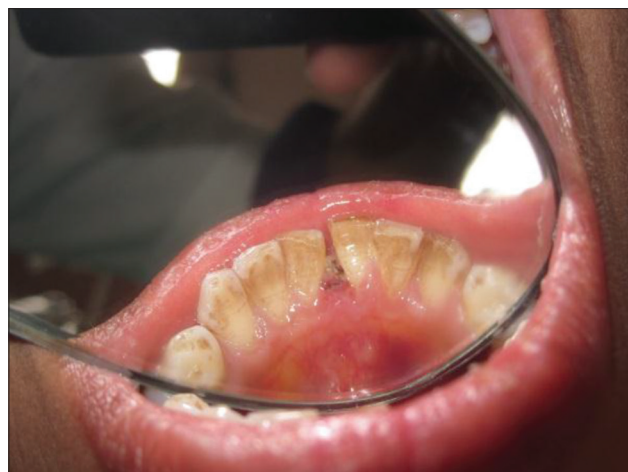

Figure 8: After 1 week

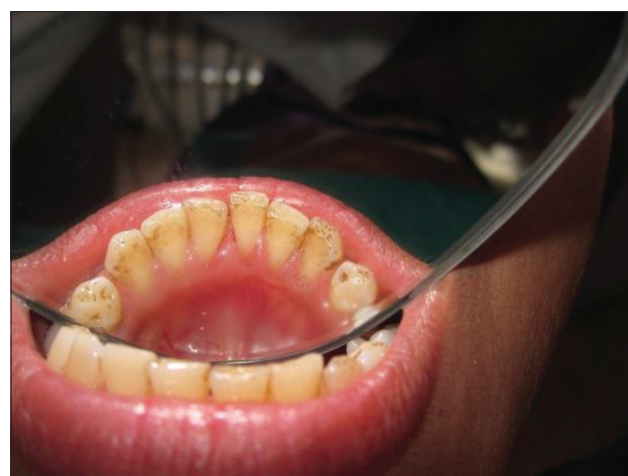

Figure 9: After 6 months

DISCUSSION

The pyogenic granuloma is a relatively common, tumor like, exuberant tissue response to localized irritation or trauma. Pyogenic granulomas occur at any age, but they most frequently affect young adults. The maxillary gingiva (especially in the anterior region) is involved more frequently than the mandibular gingiva; the facial gingiva is involved more than the lingual gingiva. Three quarters of all oral pyogenic granulomas occur on the gingiva, with the lips, tongue (especially the dorsal surface), and buccal mucosa also affected. A history of trauma is common in extragingival sites, whereas most lesions of the gingiva are response to irritation. Individual's with poor oral hygiene and chronic oral irritants most frequently are affected.^{6,7} Early lesions bleed easily due to extreme vascularity. Pyogenic granulomas can have a rapid growth pattern that can cause alarm. If left alone, a number of pyogenic granulomas undergo fibrous maturation and resemble and/or become fibromas. A number of lesions affect both the facial and lingual gingivae. Pyogenic granulomas usually present as smooth or lobulated

red-to-purple masses that may be either pedunculated or sessile. As lesions mature, the vascularity decreases and the clinical appearance is more collagenous and pink.⁴ Pyogenic granulomas vary in size from a few millimetres to several centimetres and are painless.⁶ These tumors are soft to palpation. A history of trauma is common in extragingival sites, whereas most lesions of the gingiva are a response to irritation. Individuals with poor oral hygiene and chronic oral irritants (eg, over-hanging restorations, calculus) most frequently are affected.

Histologic examination reveals sectioned soft tissue consisting of a lesion composed of ulcerated mucosa covering a core of cellular fibrous connective tissue admixed with proliferating vascular channels and a mixed inflammatory infiltrate. This lesion is a reactive/inflammatory process. Differential diagnosis for PG is fibroma, peripheral ossifying fibroma, irritation fibroma, peripheral giant cell granuloma.

The treatment of choice is conservative surgical excision. For gingival lesions, excising the lesion down to the periosteum and scaling adjacent teeth to remove any calculus and plaque that may be a source of continuing irritation is recommended⁵. Pyogenic granuloma occasionally recurs, and a re-excision is necessary. There recurrence rate is higher for pyogenic granulomas removed during pregnancy. The only outpatient care is observation of the surgical healing 1 week after removal. Prevention consists of routine scaling and home care, especially during pregnancy. No complications are anticipated with removal of this lesion other than the chance of a cosmetic gingival defect. The prognosis is excellent, and the lesion usually does not recur unless inadequately removed. Lesions removed during pregnancy may have a higher recurrence rate.

Focus patient education on better oral hygiene, and consider recommending pulsating mechanical toothbrushes with timers. These tooth brushes encourage better hygiene.¹

Laser therapy using continuous and pulsed CO₂ and Nd:YAG systems have been used for a variety of intraoral soft tissue

lesions such as haemangioma, lymphangioma, squamous papilloma, lichen planus, focal melanosis, and pyogenic granuloma, because they carry the advantage of being less invasive and sutureless procedures that produce only minimal postoperative pain. Rapid healing can be observed within a few days of treatment, and as blood vessels are sealed, there are both a reduced need for post-surgical dressings and improved haemostasis and coagulation. It also depolarizes nerves, thus reducing post-operative pain and also destroys many bacterial and viral colonies that may potentially cause infection. Reduced post-operative discomfort, oedema, scarring and shrinkage have all been associated with its use.⁸

CONCLUSION

Pyogenic granuloma is a reactive hyperplasia/non-specific conditional gingival over growth. Diagnosis should be made with clinical and histopathological findings. Excision by Laser is a successful treatment option for this kind of lesion with no recurrence.

REFERENCES

1. Sheiba R Gomes, Quaid J. Shakir, Prarthana V Thaker, Jamshed K Tavadia. Pyogenic granuloma of the gingiva: A misnomer - A case report and review of literature. *Journal of Indian Society of Periodontology* 2013;17:514-519.
2. Sanjay, Venugopal, Shobha KS, Netravathi TD. Pyogenic granuloma – A case report, *Journal of Dental Sciences & Research*. 1:1:Pages 80-85.
3. Goodman-Topper E, Bimstein E. Pyogenic granuloma as a cause of bone loss in a twelve-year-old child: report of case. *ASDC Journal of Dentistry for Children*. 1994;61:65-67.
4. Jafarzadeh H, Sanatkhan M, Mohtasham N. Oral pyogenic granuloma: A Review. *J Oral Sci*. 2006;48:167-175.
5. Saikhedkar R, Shrivastava S, Melkundi M, Viswanathan V. Pyogenic granuloma – A Case Report. *International Journal Of Dental Clinics* 2011;3:87-88.
6. Ramirez. K, Bruce G, Carpenter W. Pyogenic granuloma: case report in a 9-year-old girl. *General Dentistry* 2002;50:280-281.
7. A Maryam, Farnaz F, Nooshin M, Pegah Mosannen M. Extragingival pyogenic granuloma: A Case Report. *Cases Journal* 2008; 1:371.
8. Angelopoulos AP. Pyogenic granuloma of the oral cavity: Statistical analysis of its clinical features. *Journal Oral Surgery* 1971; 29:840-7.

How to cite this article: Sidharth Shankar, Shankar T Gokhale, Ashish Agarwal, RG Shiva Manjunath. "LASER Assisted Excision of Pyogenic Granuloma Associated With Localized Alveolar Bone Loss: A Case Report". *Int J Sci Stud*. 2014;2(2):87-90.

Source of Support: Nil, **Conflict of Interest:** None declared.