International Journal of Scientific Study

General Information

About The Journal

International Journal of Scientific Study (IJSS) is a monthly journal publishing research articles after full peer review and aims to publish scientifically sound research articles in across all science like Medicine, Dentistry, Genetics, Pharmacy, etc.

Each article submitted to us would be undergoing review in three stages: Initial Review, Peer Review & Final Review.

Abstracting & Indexing Information

Index Medicus (IMSEAR), Global Index Medicus, Index Copernicus, Directory of Open Access Journals(DOAJ), Google Scholar, WorldCat, SafetyLit, WHO Hinari, Genamics Journal Seek Ulrichsweb Serials Solutions , International Committee of Medical Journal Editors(ICJME) Geneva Foundation for Medical Education & Research(GFMER), Socolar, Bielefeld Academic Search Engine(BASE) , Research Bible , Academic Journals Database, J-Gate, Jour Informatics, Directory of Research Journal Indexing(DRJI), Scientific Indexing Services(SIS) Rubriq-Beta, SHERPA RoMEO, New Jour, EIJASR), IndianScience.in, CiteFactor, Scientific Journal Impact Factor (SJIF), Journal Index.net, ROAD, Global Impact Factor(GIF) , International Society for Research Activity (ISRA), Advanced Science Index, OpenAccessArticles.com, etc

Information for Authors

The authors should follow "Instructions to Authors" which is available on website http://www.ijss-sn.com/instructions-to-authors.html. Authors should fill the Copyright Transfer form & Conflict of Interest form. Manuscripts should be submitted directly to: editor@ijss-sn.com.

Publication Charges

International Journal of Scientific Study aims to encourage research among all the students, professionals, etc. But due to costs towards article processing, maintenance of paper in secured data storage system, databases and other financial constraints, authors are required to pay. However discount will be provided for the non-funding quality research work upon request. Details about publication charges are mentioned on journal website at: http://www.ijss-sn.com/publication-charges.html.

Advertising Policy

The journal accepts display and classified advertising Frequency discounts and special positions are available. Inquiries about advertising should be sent to editor@ijss-sn.com.

Publishing Details

Publisher Name: International Research Organization for Life & Health Sciences (IROLHS)

Registered Office: L 214, Mega Center, Magarpatta, Pune - Solapur Road, Pune, Maharashtra, India – 411028. Contact Number: +919759370871.

Designed by: Tulyasys Technologies (www.tulyasys.com)

Disclaimer

International Journal of Scientific Study

Editorial Board

International Journal of Scientific Study
May 2020 • Vol 8 • Issue 2

Contents

International Journal of Scientific Study

May 2020 • Vol 8 • Issue 2

Print ISSN: 2321-6379
Online ISSN: 2321-595X

Case Report

Reinforced Polymethyl Methacrylate Resin Using Grapheme Derivative For an "All-On-4" Implant- Supported Definitive Mandibular Prosthesis – A Case Report

Sachin Gupta[1], Lalith Vivekananda[2], Tejal Mavinkurve[3]

[1]Bds Mum, PGDI, DWCOI, PGCOI, [2]Professor, Dental Science Masters Programme, Universitat Jaume I, Castelló de la Plana, Castellón, Spain, [3]Bds Mum, Fellowship in Implantology (MUHS), Nashik, Maharashtra, India

Abstract

Since the inception of implant dentistry, implant-supported metal-acrylic resin hybrid prostheses are the major prosthetic devices given to restore physiological and esthetic functions of oral tissues of edentulous or partially edentulous patients. The clinical performance of the most commonly used acrylic resin in the fabrication of dentures, namely, polymethyl methacrylate (PMMA) resin determines its long-term deformation and wear resistance. However, its poor mechanical resistance to wear and tear poses a major setback. An attempt to incorporate graphene derivative with PMMA resin in prosthesis fabrication has demonstrated significant improvement in the mechanical strength as per literature. This case report presents rehabilitation of edentulous mandibular jaw and also briefly states the properties of graphene and the polymerization process of the resin with the graphene derivative.

Key words: Computer-aided design EXOCAD, Graphene derivative, Mandibular prosthodontic rehabilitation, Mechanical resistance, Polymethyl methacrylate resin

INTRODUCTION

Implant-supported metal-acrylic resin hybrid dentures primarily having polymeric compositions, i.e., polymethyl methacrylate (PMMA) with a metallic framework is the most commonly used, cost-effective material for this purpose. Its qualities of biocompatibility, reliability, relative ease of manipulation, low modulus of elasticity, and low toxicity[1] have made it a definitive material in prosthodontic rehabilitation. However, poor mechanical properties, volume shrinkage after polymerization, and poor antimicrobial (anti-adhesion) effects have posed to be major drawbacks lately.[2] Hence, in this case, PMMA resin reinforced with graphene derivative aided by EXOCAD for prosthetic planning has been tried as it essentially enhances mechanical properties of PMMA according to literature.[3] Since limited data have been published regarding inclusion of a graphene compound in a PMMA resin for improving the mechanical properties, further evidence-based studies are needed to ensure rigorous scientific support of this technique and materials.[4]

Access this article online

www.ijss-sn.com

Month of Submission : 03-2020
Month of Peer Review : 04-2020
Month of Acceptance : 05-2020
Month of Publishing : 05-2020

MATERIALS AND METHODS

Properties of Graphene

Graphene is an atomically thin, two-dimensional sheet of sp2 carbon atoms in a honeycomb structure. It has been shown to have many desirable properties such as high mechanical strength, electrical conductivity, molecular barrier abilities, and other remarkable properties. However, the use of pristine graphene has proved challenging due to poor solubility and agglomeration in solution due to van der Waals interactions. As an alternative, compounds similar in structure to graphene are synthesized from graphite in an effort to achieve many of the advantages of pristine graphene while also imbuing the surface with

Corresponding Author: Lalith Vivekananda, Dental Science Masters Programme, Universitat Jaume I, Castelló de la Plana, Castellón, Spain.

functionalized oxygen groups. Graphene's principal properties are its high thermal and electrical conductivity, high traction resistance, low density, and low coefficient of thermal expansion. Furthermore, since it is carbon, graphene is ecological and recyclable.[5]

The incorporation of graphene into PMMA resin is an innovative strategy to improve its mechanical properties, simultaneously increasing the elastic modulus as well as the tenacity, reducing the appearance of cracks and their spread as well as decreasing the shrinkage rate during polymerization. It is an ideal candidate to improve the performance of autopolymerizing acrylic resins for dental use not only due to its high traction resistance, coefficient of thermal expansion, high capacity for absorption and lubrication, flexibility, and high surface area but also for its high weight to resistance ratio.[6]

Resin Polymerization with Graphene

One of the principal advantages of graphene is that even in small quantities, its inclusion can cause big changes in the mechanical and physicochemical properties of the material to which it is added. Given that, graphene is a good thermal conductor and that the process of post-polymerization of the acrylic resin requires heat to complete it, its addition allows a higher polymerization conversion rate.

Compared to conventional polymer materials, PMMA resin nano reinforced with graphene has a higher modulus and specific resistance due to the distribution of tension between the structures, as they are capable of withstanding tensions practically without suffering deformations. The union between the nano reinforcements and the original polymer is one of the main aspects that explain the increase in mechanical resistance.[5]

This case report hereby presents mandibular implant rehabilitation by an "All-on-4" technique highlighting delivery of graphene derivative reinforced PMMA resin implant-supported hybrid prosthesis to enhance mechanical resistance of the prosthesis.

CASE REPORT

A 67-year-old female patient of Indian origin visited our clinic in Mumbai with a chief complaint of missing teeth in her lower jaw requesting replacement of fixed teeth.

Diagnosis

Diagnostic criteria involved thorough medical history, dental history including intraoral and extraoral examination, intraoral and extraoral pictures, blood investigations, full volume radiographic investigation cone-beam computed tomography (CBCT), and diagnostic cast assessment for a comprehensive treatment plan.[6]

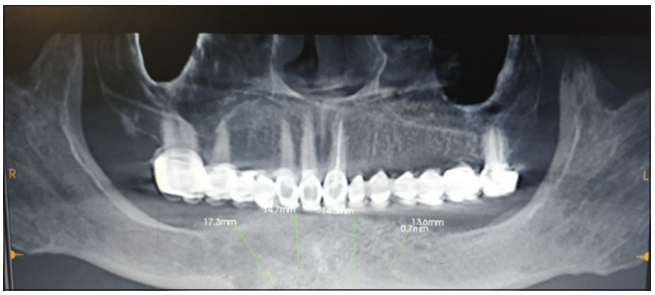

Figure 1: Pre-operative panoramic radiograph.

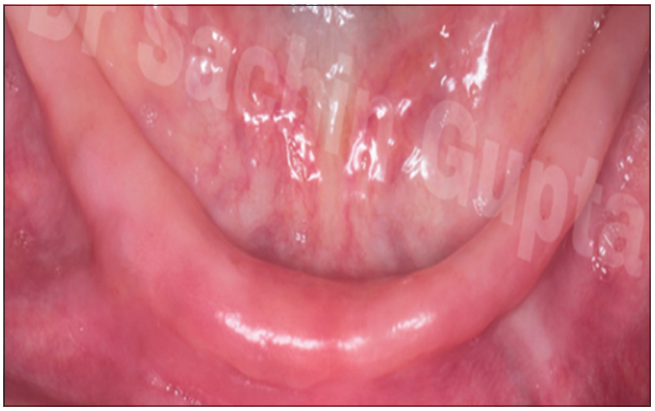

Figure 2: Pre-operative, intraoral view of the residual mandibular ridge

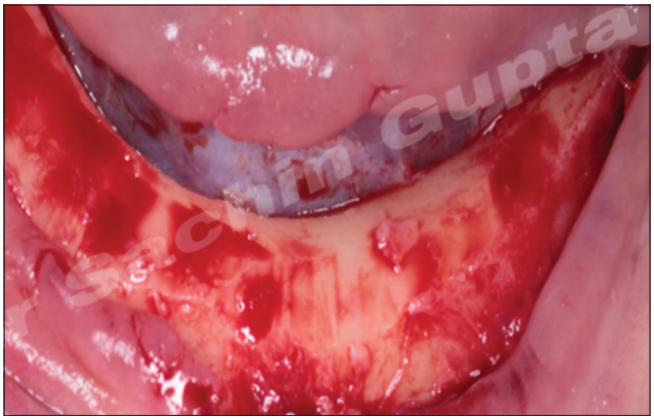

Figure 3: Full-thickness incision with ridge tabling

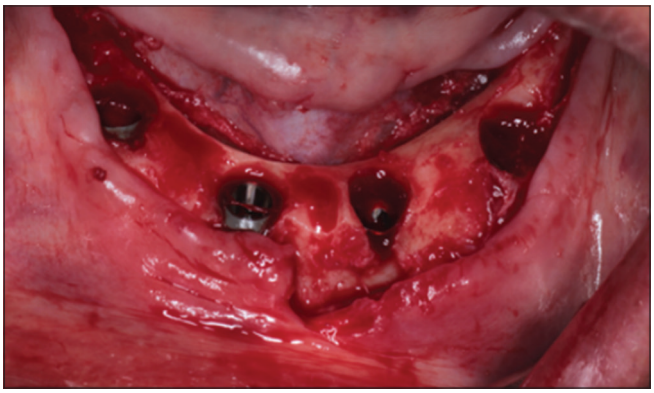

Figure 4: Surgical placement of two straight and two tilted implants

The patient had a medical history of controlled hypertension and intraoral examination revealed dental history of a 5-year-old PFM FPD in upper jaw, edentulous mandibular jaw, and xerostomia (dry mouth condition).

Blood investigation revealed all parameters within normal range and suggested that the patient was fit enough to undergo surgical procedures in implant replacement therapy.

Radiographic data evaluation of CBCT revealed no pathology with severe atrophy in the mandibular residual ridge, indicating an "All-On-4" concept for implant placement to be appropriate for FPD in mandible [Figure 1].

The panoramic radiograph revealed an advanced alveolar bone resorption in the mandible.

Treatment Plan

Given the intraoral condition of the residual mandibular ridge [Figure 2], the "All-on-4" concept of placement of four implants in the anterior region (combining two tilted and two axial implants) and loading a graphene derivative reinforced PMMA resin-based, screw-retained definitive hybrid prosthesis with prosthetic planning on EXOCAD was considered a less time consuming, viable economic treatment modality of choice in this case.

The "All-on-4" technique was scheduled to rehabilitate the lower jaw.

Under local anesthesia, a full-thickness crestal incision from the right molar region to the left molar region was performed [Figure 3]. Because there was a vertical dimension collapse, significant alveoplasty by means of tabling the residual ridge was done to achieve adequate prosthetic space of desired 15 mm [Figure 4].

The two anterior implants were axially placed in the incisive area, whereas the two posterior implants were placed at an angle of 30° to the mental foramina.

After soft-tissue management and closure, straight and angulated abutments were placed onto the implants [Figures 5 and 6] and multiunit impression copings were attached to the prosthetic abutments for an open tray impression [Figures 7 and 8].

A jig trial was taken, splinting the impression copings with a low shrinkage autopolymerizing resin to ensure that the interimplant relationship is preserved and an accurate transfer without accidental displacement is achieved for an accurate master cast, a passive fit, and a decrease in potentially destructive forces that may lead to bone loss or prosthetic failure [Figure 9].

An open tray impression, jig trial and jaw relation with two wax rims were taken [Figures 8-10].

With the information provided by the intraoral scan (EXOCAD), Figure 11, a new wax try-in denture was

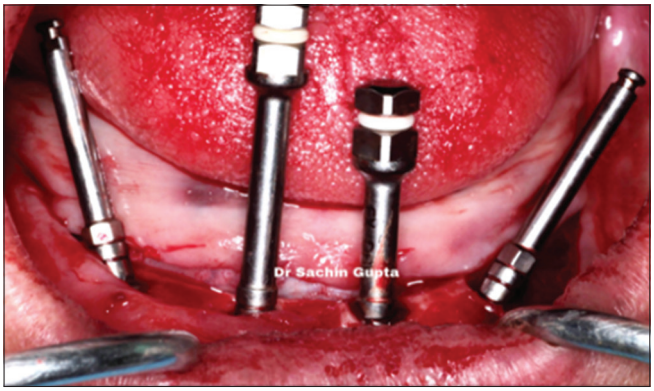

Figure 5: Straight and angled abutments placement on the four implants

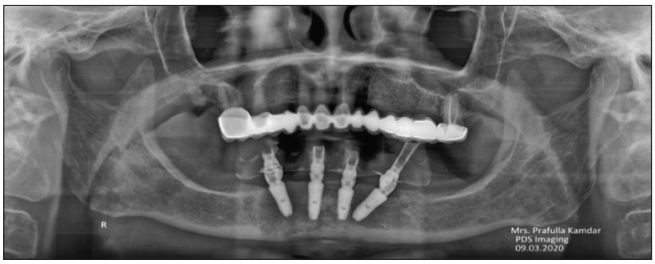

Figure 6: Post-surgical panoramic view

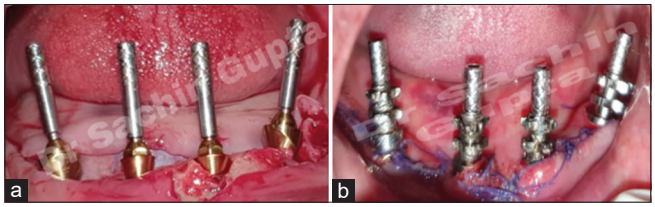

Figure 7: (a and b) Multiunit impression copings attached to prosthetic abutments

Figure 8: Open tray impression

designed [Figure 12] and 3D-printed working cast was created to evaluate the esthetic parameters, prospective tooth positions, and vertical dimension. A new cast was then 3D printed to fabricate a screw-retained, hybrid prosthesis made of PMMA resin reinforced with graphene derivative.

A definitive prosthesis made from PMMA resin reinforced with graphene derivative was designed based on biologic and functional parameters of the interim prosthesis with the help of EXOCAD software and milled [Figures 13 and 14].

Passive fit and occlusion were checked by equilibrating the occlusal forces with the help of OccluSense device in the patient's mouth [Figure 15].

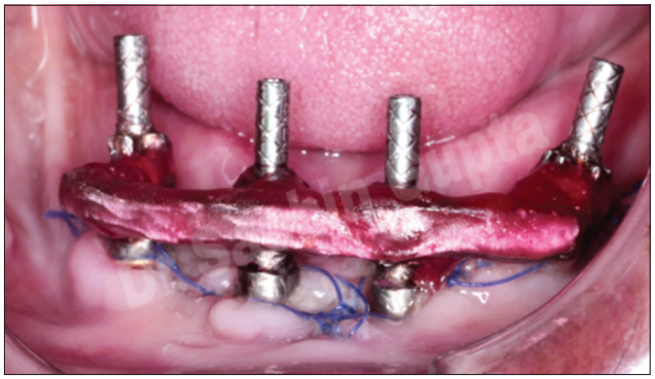

Figure 9: Jig trial

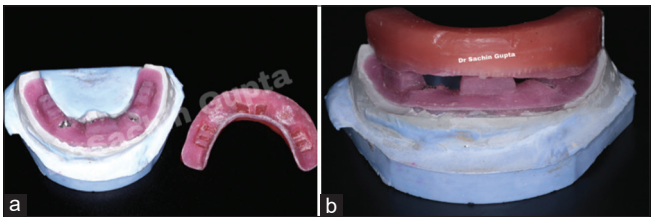

Figure 10: (a and b) Jaw relation with two-step wax rims

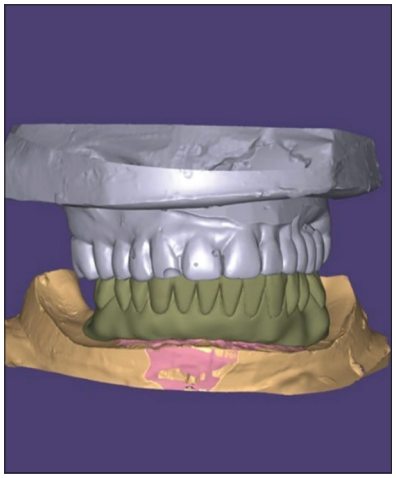

Figure 11: 3D-printed working cast planned on EXOCAD

After all the parameters were verified, the prosthesis was delivered [Figure 16] and oral hygiene instructions with information on how to take care of the new prosthesis were provided.

After 1 year of placement of the definitive prosthesis, no biomechanical or biological complications were reported in the follow-up check-up, thus concluding, incorporation

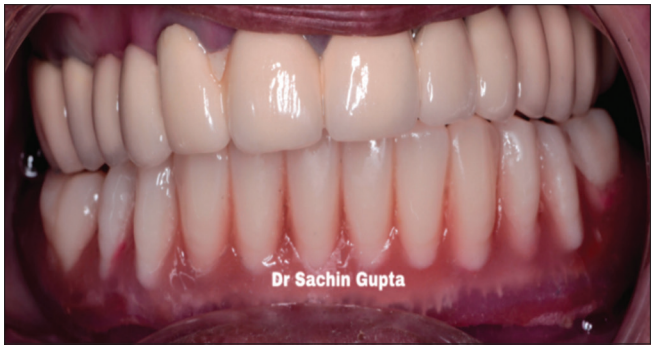

Figure 12: Wax try-in

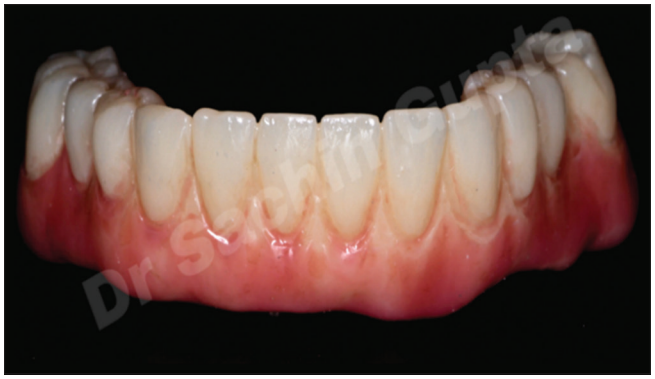

Figure 13: Graphene derivative reinforced polymethyl methacrylate resin-based hybrid prosthesis

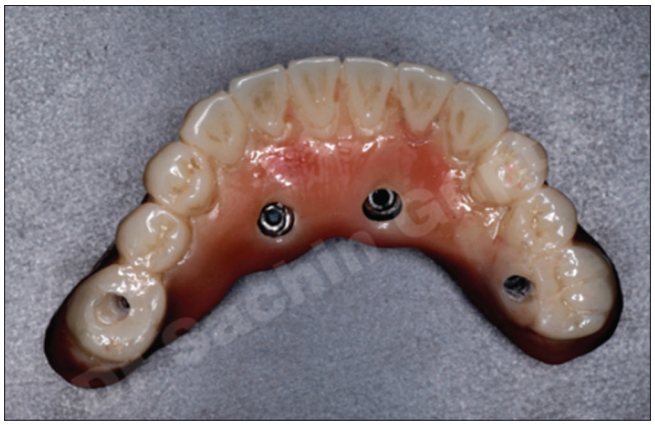

Figure 14: Occlusal view of the hybrid prosthesis

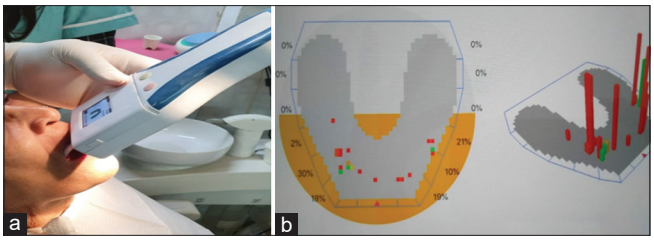

Figure 15: (a and b) Occlusal forces equilibrated by OccluSense device

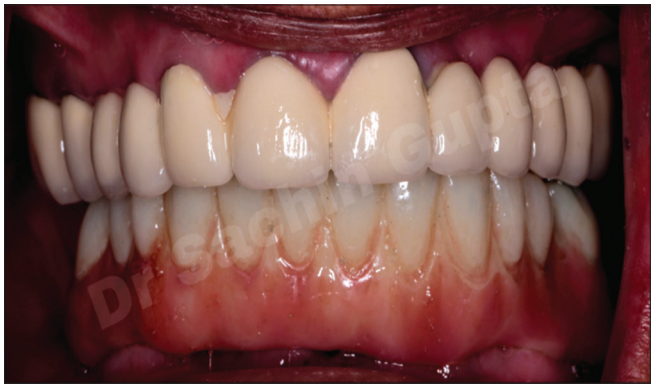

Figure 16: Frontal view of the graphene derivative reinforced polymethyl methacrylate resin-based hybrid prosthesis delivery on the 5th day

of Graphene derivative in PMMA resins to be a suitable option for prosthetic rehabilitation.

DISCUSSION

The present case report used graphene derivative to PMMA resins to overcome the compromised mechanical properties in PMMA resin material. Many authors claim that this incorporation in acrylic resins may enhance the resin's mechanical properties and antimicrobial adhesion effects and decrease the degree of contraction during polymerization.[4]

However, much more evidence-based study is needed to establish that this new strategy produces consistent successful outcome.

The patient informed consent was obtained for the publication of this case report.

ACKNOWLEDGMENTS

The authors are grateful to their dental technician and the axillary team in private practice for their support in this work.

REFERENCES

1. Azevedo L, Antonaya-Martin JL, Molinero-Mourelle P, Del Rio-Highsmith J. Improving PMMA resin using graphene oxide for a definitive prosthodontic rehabilitation-a clinical report. J Clin Exp Dent 2019;11:e670-4.
2. Jagger DC, Harrison A, Jandt KD. The reinforcement of dentures. J Oral Rehabil 1999;26:185-94.
3. Ruse ND, Sadoun MJ. Resin-composite blocks for dental CAD/CAM applications. J Dent Res 2014;93:1232-4.
4. Wong DM, Cheng LY, Chow TW, Clark RK. Effect of processing method on the dimensional accuracy and water sorption of acrylic resin dentures. J Prosthet Dent 1999;81:300-4.
5. Haselton DR, Diaz-Arnold AM, Vargas MA. Flexural strength of provisional crown and fixed partial denture resins. J Prosthet Dent 2002;87:225-8.
6. Matsuo H, Suenaga H, Takahashi M, Suzuki O, Sasaki K, Takahashi N. Deterioration of polymethyl methacrylate dentures in the oral cavity. Dent Mater J 2015;34:234-9.

How to cite this article: Gupta S, Vivekananda L, Mavinkurve T. Reinforced Polymethyl Methacrylate Resin Using Grapheme Derivative For an "All-On-4" Implant-Supported Definitive Mandibular Prosthesis – A Case Report. Int J Sci Stud 2020;8(2):1-5.

Source of Support: Nil, **Conflicts of Interest:** None declared.

Print ISSN: 2321-6379
Online ISSN: 2321-595X

Case Report

Case of Pelviureteric Obstruction and Renal Stones with Transitional Cell Carcinoma: Beware of Tumor in Gross Hematuria

Kabilan Saminathan

Consultant Urologist, Department of Urology, Dr. Mehta's Hospital, Chennai, Tamil Nadu, India

Abstract

Presenting an interesting case report of a patient with gross hematuria. On contrast CT evaluation was found to have pelvic-ureteric obstruction with multiple secondary calculi. Since he was on anticoagulants and antiplatelets, these were thought to be the cause of hematuria. On the table when laparoscopic pyeloplasty and stone removal procedure was on, incidental tumor in lower calyx was detected. Pyeloplasty was converted to laparoscopic nephrectomy after discussing with patients' kin. This highlights the importance of suspecting tumor in patients presenting with gross hematuria.

Key words: Kidney calculi, Laparoscopic nephrectomy, Pelvic-ureteric junction obstruction, Pyeloplasty, Renal cell carcinoma, Transitional cell carcinoma

INTRODUCTION

Common causes of gross hematuria are benign (stones, infection, and benign prostatic enlargement). The incidence of tumors will be 3–6%.[1,2] The common tumors are renal cell carcinoma and transitional cell carcinoma. In hematuria evaluation, we routinely do CT-urogram for all patients, MRI in patients with elevated Sr. creatinine values.[3] Urine cytology is done once hematuria has cleared. In patients over 35 years or any aged patient who is a smoker, with exposure to benzene and aniline dyes or have received radiation therapy/chemotherapy (high-risk group), cystoscopy is done to rule out flat lesions.[3] In recurrent and persistent hematuria, ureterorenoscopy may be done if no abnormalities are seen in imaging.[4-6] It is a way to rule out urothelial tumors of the upper tract as well as to treat bleeding sites with LASER coagulation (benign essential hematuria). If the hematuria does not recur, then repeat imaging done in 3–5 years.[3] In any patient with whom the predominant complaint is hematuria, a urothelial tumor must be suspected even if other causes such as stone, anticoagulant therapy, and infection are present. Rarely a tumor may coexist and missed.

Access this article online

www.ijss-sn.com

Month of Submission : 03-2020
Month of Peer Review : 04-2020
Month of Acceptance : 05-2020
Month of Publishing : 05-2020

CASE PRESENTATION

A 73-year-old male presented to the clinic with complaints of gross hematuria, on and off for 2 weeks. Left flank pain was present. He was having urinary incontinence for the past 2 days. He had clot retention: urinary bladder was palpable. His medications were antihypertensives, statins, clopidogrel 75 mg, and aspirin 150 mg. Urethral catheterization done and obstruction relieved, bladder wash done with clot evacuation. His labs: Hemoglobin 8 g/dl, serum platelets 1.2 lakhs/dl, INR 2.2, and serum creatinine 1.3 mg/dl. He does not have any coronary heart conditions. Cardiac ECHO was not suggestive of ischemic heart disease.

After cardiologist consult, aspirin, and clopidogrel were stopped. Two units of packed RBC were transfused. Urine cleared after 3 days, repeated bladder washes were given. A contrast CT KUB with CT urogram taken[Figures 1 and 2]. There was contrast hold up in the left kidney, suggestive of pelvic-ureteric junction obstruction. Soft tissue densities were seen within the dilated pelvis, suggestive of clots. There was a good amount of renal parenchyma in

Corresponding Author: Dr. Kabilan Saminathan, 6/7 Second Street, Kilpauk Garden, Chennai - 600 010, Tamil Nadu, India.

the upper and inter-polar region with normal enhancement. Cortex thinned out in the lower pole, without notable enhancement. Multiple 20–30 small secondary calculi were seen sedimenting in the lower pole. The right kidney was normal. After 3 weeks split, renal function done using DTPA. The left renal function was 30%. Laparoscopic pyeloplasty was planned. After removing the larger stones by grasper, the smaller stones were planned to be sucked out with a large cannula. Under general anesthesia and left kidney up position, with 70° tilt, three ports were used. The left colon was dropped, the renal pelvis was dissected.

Adhesions were seen at the pelvic-ureteric junction. No vessel crossing. Ureter was spatulated and pelvis transected above the pelvic-ureteric junction. Larger stones were removed with bowel grasper. In the lower pole, proliferative growth was noticed [Figure 3].

The condition explained to relatives on table and laparoscopic left radical nephrectomy was done [Figure 4]. The pathology report was transitional cell carcinoma, high grade from the lower calyx. The pelvic-ureteric junction showed fibrosis and epithelial atrophy. The patient was not willing for removal of left ureteric stump and cuff of bladder. He is on follow-up for 2 years. Six monthly cystoscopies with left ureteroscopy, urine cytology, and ultrasound were done.

DISCUSSION

Long-standing kidney stones are associated with increased risk of papillary type renal cell carcinoma and upper tract urothelial carcinoma. Especially if stone diagnosis was made in people who are <40 years old. Tumor formation may be due to chronic inflammation and infection.[7,8] The diagnosis of tumor in the scenario of dilated kidneys will also difficult. Main criteria for tumor diagnosis are the presence of contrast enhancement. In thinned parenchyma, in this patient the lower pole cortex, there may not be contrast enhancement because of poor vascularity.[8] Small tumors may be missed as in this case. Another important fact, as in this patient, is anticoagulants and antiplatelets therapy.

Many patients presenting with hematuria are on anticoagulants. The hematuria may be attributed to anticoagulant therapy. However, it is rare for patients on therapeutic doses of

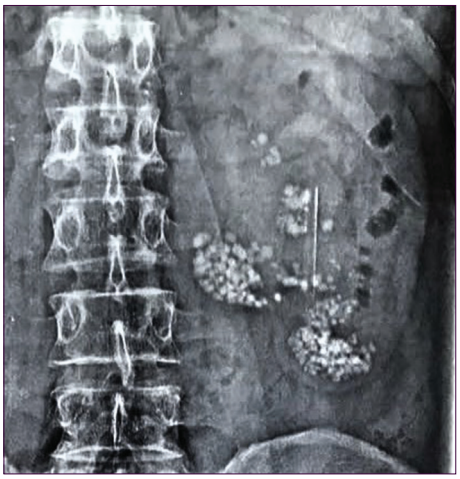

Figure 1: X ray KUB

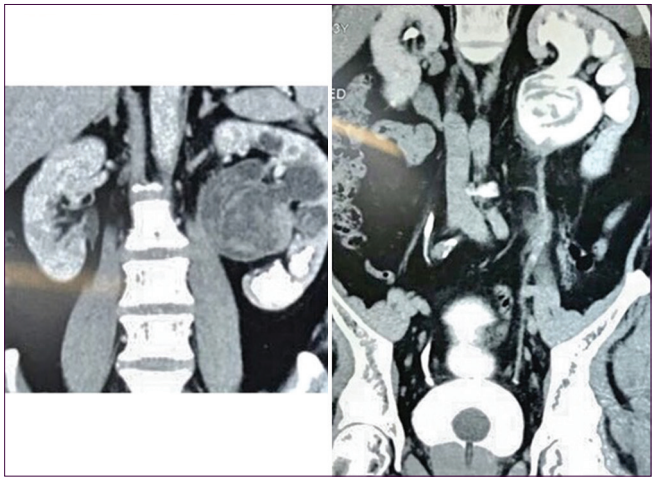

Figure 2: Contrast CT

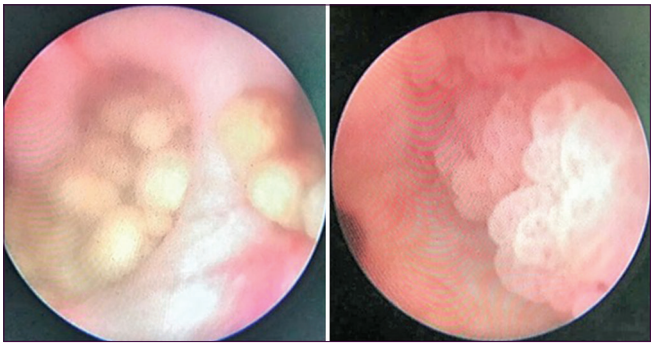

Figure 3: Stones and tumor

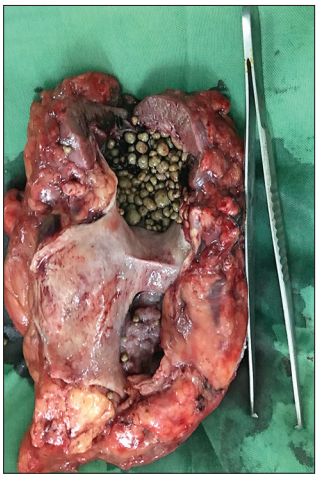

Figure 4: Nephrectomy specimen

anticoagulant/antiplatelets to present with gross hematuria.[9] Renal/urothelial tumor must be suspected. CT urogram may be normal in 50% of patients presenting to hematuria clinics.

Ureterorenoscopy findings in these kinds of patients will reveal a ruptured venous bleed or a small papilloma at the apex of calyx. This entity is named as benign essential hematuria.[3]

This could be due to vigorous physical exercise/sexual intercourse.[2] A 1.8% of asymptomatic microscopic hematuria patients who did not show any lesion at the time of first evaluation develop a tumor in the kidney when imaged at 3 years (Mohr *et al*., 1986). The incidence may be more in patients presenting with gross hematuria. These may be because of missed early lesions, as in this patient. Problems in patients with pelvic-ureteric junction obstruction presenting with gross hematuria may be unique. A hydronephrotic variant of TCC must be suspected. The bulged out pelvis and calyx (oncocalyx) may be due to tumor filling and bulging the system.[10] Solid elements within hydronephrotic kidneys may be a clot or fungal ball, other than tumor. Due to poor vascularity (poor contrast enhancement) will be difficult to differentiate.[11]

CONCLUSION

In patients with stones and/or pelvic-ureteric junction obstruction presenting with gross hematuria, it is better to inspect the pelvicalyceal system during surgery so that a coexisting early tumor is not missed.

REFERENCES

1. O'Connor OJ, Fitzgerald E, Maher MM. Imaging of hematuria. AJR Am J Roentgenol 2010;195:W263-7.
2. Yeoh M, Lai NK, Anderson D, Appadurai V. Macroscopic haematuria--a urological approach. Aust Fam Physician 2013;42:123-6.
3. Davis R, Jones JS, Barocas DA, Castle EP, Lang EK, Leveillee RJ. Diagnosis, evaluation and follow-up of asymptomatic microhematuria (AMH) in adults: AUA guideline. J Urol 2012;188:2473-81.
4. Mugiya S, Ozono S, Nagata M, Takayama T, Furuse H, Ushiyama T. Ureteroscopic evaluation and laser treatment of chronic unilateral hematuria. J Urol 2007;178:517-20.
5. Dooley RE, Pietrow PK. Ureteroscopy for benign hematuria. Urol Clin North Am 2004;31:137-43.
6. Grasso M. Ureteroscopic management of upper urinary tract urothelial malignancies. Rev Urol 2000;2:116-21.
7. Van De Pol JAA, Van Den Brandt PA, Schouten LJ. Kidney stones and the risk of renal cell carcinoma and upper tract urothelial carcinoma: The Netherlands cohort study. Br J Cancer 2019;120:368-74.
8. Zengin K, Tanik S, Sener NC, Albayrak S, Ekici M, Bozkurt IH, *et al*. Incidence of renal carcinoma in non-functioning kidney due to renal pelvic stone disease. Mol Clin Oncol 2015;550:941-3.
9. Bukhari S, Amodu A, Akinyemi M, Wallach S. Persistent hematuria caused by renal cell carcinoma after aortic valve replacement and warfarin therapy. Proc (Bayl Univ Med Cent) 2017;30:327-9.
10. Jain KA. Transitional cell carcinoma of the renal pelvis presenting as pyonephrosis. J Ultrasound Med 2007;26:971-5.
11. Vasudev P, Kumar N, Kumar A. Transitional cell carcinoma: A rare development in congenital ureteropelvic junction obstruction kidney. Indian J Urol 2016;32:79-80.

How to cite this article: Saminathan K. Case of Pelviureteric Obstruction and Renal Stones with Transitional Cell Carcinoma: Beware of Tumor in Gross Hematuria. Int J Sci Stud 2020;8(2):6-8.

Source of Support: Nil, **Conflicts of Interest:** None declared.

Print ISSN: 2321-6379
Online ISSN: 2321-595X

Case Report

Management of Early Failed Implant – A Case Report

Amit C Daiv[1], Lalith Vivekananda[2,3]

[1]PG Student, Dental Science Master, Department of Periodontology and Oral Implantology, Universitat Jaume I, Castelló de la Plana, Castellón, Spain, [2]Assistant Professor, Department of Periodontics, Mathrusri Ramabai Ambedkar Dental College, Bengaluru, Karnataka, India, [3]Professor, Dental Science Masters Programme, Universitat Jaume I, Castelló de la Plana, Castellón, Spain

Abstract

Success cannot be guaranteed, what one can guarantee is to care, to do one's best, and to be there to help in the rare instance if something goes wrong. Dental implants are most commonly used for the replacement of missing teeth. Lack of osseointegration and peri-implantitis are considered as major contributory factors of implant failure. This case report presents a procedure and treatment option for immediate implant placement into previously early failed dental implant osteotomy.

Key words: Dental implants, Novabone putty, Teeth

INTRODUCTION

The single-tooth implant procedure is a predictable procedure with good survival rates.[1] Biologic, esthetic, and technical complications can occur in a certain percentage of patients. We should have a better understanding of the role of the factors that may indicate or cause implant failures such as immunological, inflammatory, microbial, systemic, anatomic, occlusal, procedural, and genetic factors. Clinicians may select appropriate cases or interventions that may enhance treatment outcomes for complete or partially edentulous patients.[2] The scientific literature on differential diagnosis and treatment of biologic complications and failing implants is limited, lacks systematic scientific validation, and is based mainly on empirical considerations from *in vitro* findings of case reports carried out on a trial and error basis.[3] Early implant failures occur before functional loading.[4] Lack of osseointegration is one of the worst complications since it inevitably results in loss of the implant diagnosed at Phase II surgery or when the implant is loaded. Epithelial downgrowth was occasionally observed histopathologically for asymptomatic submerged implants.

Access this article online

www.ijss-sn.com

Month of Submission : 03-2020
Month of Peer Review : 04-2020
Month of Acceptance : 05-2020
Month of Publishing : 05-2020

The etiologies that might implicate early implant failure are weak bone to implant interface, the healing ability of the host bone site, and infection.[5] After a failed implant is removed, the patient is left with a difficult decision regarding replacement options. Most of the time, the patient will choose to replace the failed dental implant with the placement of another implant.[6] Replacement of a failed implant presents a challenge to achieve osseointegration and may result in a decline in the survival rates.[7] The survival rate of implant replacement after early failure was accounted for 94.6%. After an adequate soft and hard tissue healing period, early implant failure was not an obstacle for implant replacement at the same site.[8] Replacement of implant at the same site with a wider diameter of the implant increases the risk of buccal bone dehiscence.[9] Bioactive materials can be used to stimulate a biological response from the body. They also elicit a positive bone response by creating bonding along with implant-bone interface.[10,11] To improve osseointegration, removal of fibrous soft tissue by thorough debridement of osteotomy, promote fresh blood to increase the angiogenesis, and use of bioactive material should be considered at failed implant osteotomy.

CASE REPORT

A 24-year-old systemically healthy female patient reported to our private dental practice with the complaint of missing teeth in the lower right posterior region for 3 years. A comprehensive clinical examination revealed

Corresponding Author: Dr. Lalith Vivekananda, Professor, Dental Science Masters Programme, Universitat Jaume I, Castelló de la Plana, Castellón, Spain.

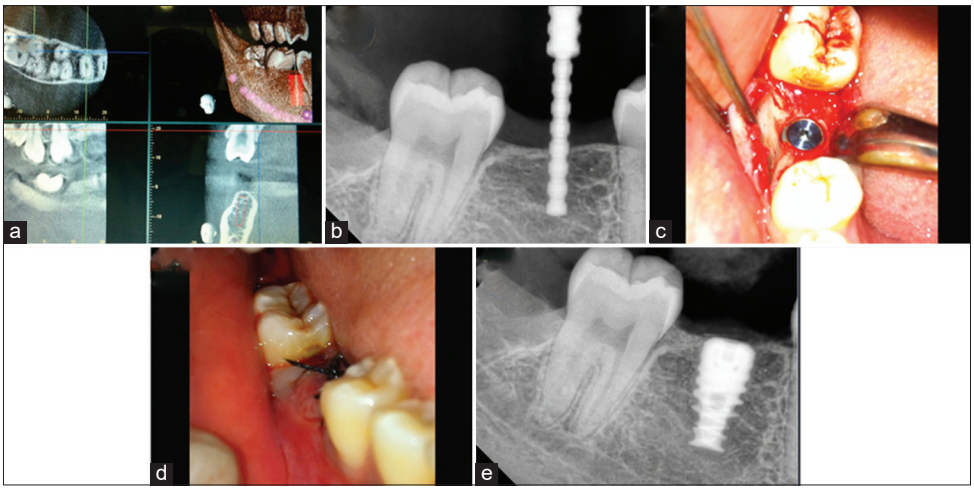

Figure 1: Initial implant placement procedure. (a) Pre-operativecone-beam computed tomography,(b) osteotomy angulation verification, (c) implant placement followed by cover screw placement, (d) suturing,(e) immediate post-operativeintraoral periapical

that adequate space is available to replace teeth. Adjacent teeth were free from caries, vital and have suitable crown volume and height. The general periodontal condition was healthy. Multiple treatment options with their advantages and disadvantages were discussed with patient, however, the patient agreed for dental implant for missing teeth. The patient was advised cone-beam computed tomography (CBCT) as radiographic investigation [Figure 1a]. The CBCT showed the possibility of implant placement in the edentulous mandibular right first molar region. On CBCT, ridge was measured and the length and diameter of the implant to be placed were decided. An endosseous implant of 4.25 mm × 11.5 mm diameter (SPI Implant, Alpha-BioTech) was planned. After the administration of adequate local anesthesia, midcrestal incision was given in the region of 46 and full-thickness mucoperiosteal flap was reflected. The osteotomy was carried to the desired depth. The angulation was checked once again with the paralleling pin [Figure 1b], both clinically and radiographically. Any discrepancy found can be corrected subsequently. The osteotomy was then diametrically enlarged to the desired diameter. Constant external irrigation with normal saline was used during drilling. After complete osteotomy, the implant was then screwed in and tightened using the manual torque ratchet provided in the surgical kit. It is made sure that optimal torque is obtained while placing in the implant, which is ascertained by the "slip of the Ratchet," adjusted at 45Ncm, to ensure optimal primary stability of the implant. A cover screw was placed on top of the implant [Figure 1c]. The flap was closed with the help of interrupted 3.0 silk sutures [Figure 1d]. Immediate post operative IOPA was taken [Figure 1e]. Post-operative antibiotic (amoxicillin 500 mg, 3 times daily for 5 days) and analgesic (diclofenac and paracetamol combination) for 3 days were prescribed. Post-operative instructions were given. Follow-up taken on the 3rd day to check the healing

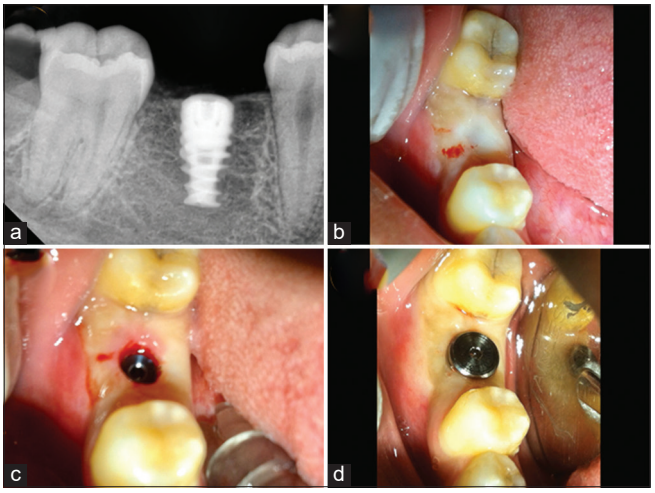

Figure 2: Second-stage surgery (a)intraoral periapical after 3 months of healing, (b) after local anesthesia, (c) implant exposure using tissue punch, (d) healing screw placement

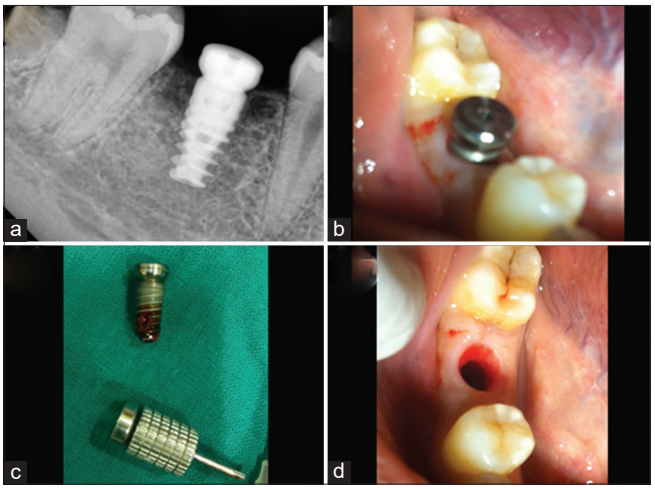

Figure 3: (a) IOPA to ascertain proper fit of Healing Screw, (b) implant came out with coverscrew, (c) implant retrieved using hex driver, (d) osteotomy after implant removal

of site and suture removal was done on the 7th day after the procedure.

The patient was recalled at 3 months. An intraoral periapical (IOPA), radiograph [Figure 2a] was taken to evaluate the implant. After local anesthesia [Figure 2b], implant was uncovered using soft-tissue punch [Figure 2c] and the healing screw was placed [Figure 2d], proper fit of which was ascertained by taking IOPA [Figure 3a].

The patient was recalled after 15 days. During the appointment, while unscrewing healing screw with hand hex driver implant got unscrewed [Figure 3b]. The patient was then appointed for replacement with a new implant on the next day. A samesized implant in wider osteotomy was planned. After the local anesthesia, unscrewed implant was removed with the healing screw attached to the implant [Figure 3c and d].

It was decided to enlarge the osteotomy by one size larger drill [Figure 4a] previously last used drill to ensure complete cleaning of osteotomy wall till apex and to promote angiogenesis of site. The enlarged osteotomy was filled with bioactive synthetic calcium phosphate putty (NovaBone, Florida, USA)[Figure 4b]. The bone graft material is adapted to walls of the enlarged osteotomy. A new implant of the same diameter (4.25 mm × 11.5 mm) was placed inside the well of bone graft created [Figure 4c]. The final placement of the implant was carried out using hand ratchet. Healing screw was placed on the top of the implant. Antibiotics and analgesics were advised postoperatively.

The patient was recalled after 3 months. No pain or sign of infection and absence of clinical mobility detected during the clinical examination after 3 months. On radiographic evaluation using IOPA, no sign of peri-implant pathology was seen [Figure 5a and b]. The impression of the implant was taken using an open tray technique [Figure 5c], which was then verified using verification jig[Figure 5d]. A cement and screw-retained PFM crown was received from the laboratory. IOPA was taken to check the proper fit of the abutment [Figure 5e]. Crown was then cemented extraorally and fixed onto the implant by utilizing an access hole in the crown, which was filled with composite resin and cured [Figure 5f].

Long-term follow-up of 4 years showed no clinical sign of inflammation and radiographic examination showed a close contact of bone to implant and absence of bone loss[Figure 6a and b].

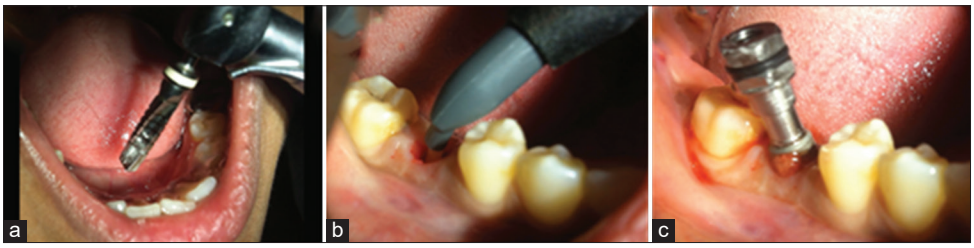

Figure 4: (a) Wider drill to enlarge osteotomy, (b) placement of NovaBone putty, (c) placement of implant into well of NovaBone putty

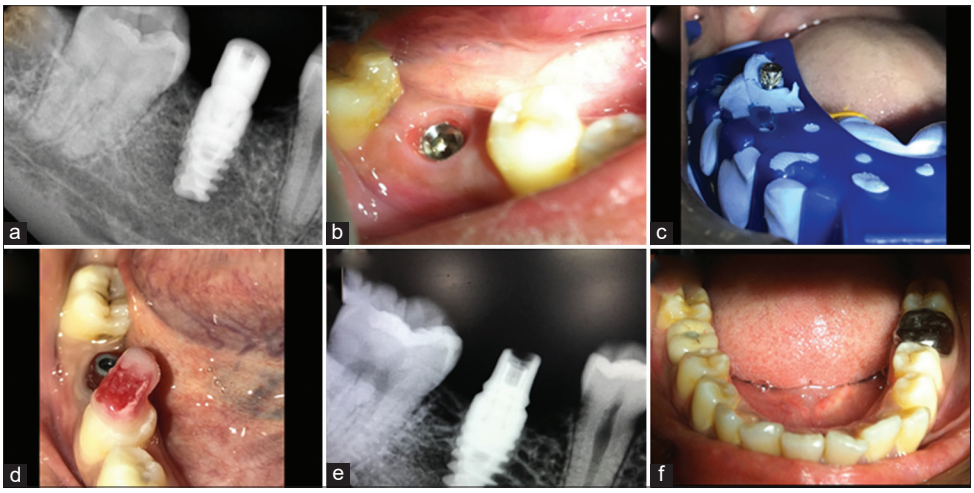

Figure 5: Threemonths post-reimplantation (a) intraoral periapical (IOPA), (b) soft-tissue healing, (c) open tray impression, (d) verification jig, (e) IOPA to check sitting of abutment, (f) placement ofcement and screw-retained final crown

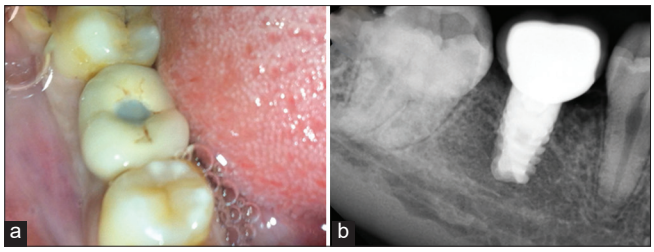

Figure 6:Fouryears post-operative of reimplantation (a) intraoral image, (b) intraoral periapical

DISCUSSION

An implant that has failed to integrate can suffer fibrous downgrowth, which acts as a barrier to the osseointegration of the replacement implant. It is important to thoroughly debride the implant socket to meticulously remove all soft tissue, promote angiogenesis, and enhance bone-to-implant contact before reimplantation. Proper instrumentation was necessary to perform thorough curettage on the osseous walls of the old osteotomy and to reach the apex, which was achieved by preparing larger osteotomy using a wider drill. Well of bioactive calcium phosphate putty (NovaBone, USA) helped to build faster and stronger bone by accelerating the regeneration of bone (osteostimulation).

CONCLUSION

Same sized implant into a well of bioactive calcium phosphate putty created in wider osteotomy can be a viable option to treat early failed implant. It remains a potion for the management of such failures and further studies involving a significant number of cases are suggested.

ACKNOWLEDGMENTS

The authors are grateful to their dental technician and the auxiliary team in private practice for their support in this work.

REFERENCES

1. Levin L, Sadet P, Grossmann Y. A retrospective evaluation of 1,387 single-tooth implants: A 6-year follow-up. J Periodontol 2006;77:2080-3.
2. Paquette D, Nadine B, Williams R. Risk factors for endosseous dental implant failure. Dent Clin North Am 2006;5:361-74.
3. Esposito M, Hirsch J, Lekholm U, Thomsen P. Differential diagnosis and treatment strategies for biologic complications and failing oral implants: A review of the literature. Int Oral Maxillofac Implants 1999;14:473-90.
4. Esposito M, Hirsch J, Lekholm U, Thomsen P. Biological factors contributing to failures of osseointegrated oral implants. (II). Etiopathogenesis. Our J oral Sci 1998;106:721-64.
5. Esposito M, Thomsen P, Ericson L, Lekholm U. Histopathologic observations on early oral implant failures. Int J Oral Maxillof Implants 1999;14:798-810.
6. Duyck J, Naert I. Failure of oral implants: Aetiology, symptoms and influencing factors. Clin Oral Investig 1998;2:102-14.
7. Grossmann Y, Levin L. Success and survival of single dental implants placed in sites of previously failed implants. J Periodontol 2007;78:1670-4.
8. Wang F, Zhang Z, Monje A, Huang W, Wu Y, Wang G. Intermediate long-term clinical performance of dental implants placed in sites with a previous early implant failure: A retrospective analysis. Clin Oral Implants Res 2015;26:1443-9.
9. Urban T, Kostopoulos L, Wenzel A. Immediate implant placement in molar regions: Risk factors for early failure. Clin Oral Implants Res 2012;23:220-7.
10. Kokubo T, Kim HM, Kawashita M, Nakamura T. Bioactive metals: Preparation and properties. J Mater Sci Mater Med 2004;15:99-107.
11. Osborn JF, Newesely H. Dynamic aspects of the implant-bone-interface. In: Heimke G, editor. Dental implants: Materials and Systems. Munich, Germany: Carl HanserVerlag; 1979. p. 111-23.

How to cite this article: Daiv AC, Vivekananda L. Management of Early Failed Implant – A Case Report. Int J Sci Stud 2020;8(2):9-12.

Source of Support: Nil, **Conflicts of Interest:** None declared.

Print ISSN: 2321-6379
Online ISSN: 2321-595X

Case Report

A Rare Case of Urothelial Carcinoma with Divergent Differentiation Showing Multiple Varied Histomorphology with Review of Literature

Mary Anelia Correya[1], Sandhya Sundaram[2], Lawrence D Cruze[3], K Natarajan[4]

[1]Post Graduate, Department of Pathology, Sri Ramachandra Institute of Higher Education and Research, Chennai, Tamil Nadu, India,
[2]Professor and Head, Department of Pathology, Sri Ramachandra Institute of Higher Education and Research, Chennai, Tamil Nadu, India,
[3]Associate Professor, Department of Pathology, Sri Ramachandra Institute of Higher Education and Research, Chennai, Tamil Nadu, India,
[4]Professor and Head, Department of Urology, Sri Ramachandra Institute of Higher Education and Research, Chennai, Tamil Nadu, India

Abstract

Urothelial carcinoma with divergent differentiation is a variant of urothelial carcinoma and it is being increasingly recognized with the increase in awareness and advancement of immunohistochemistry. It is important to quantify the degrees of each differentiation for the prognosis and treatment of the patient. Here, we present a unique case of urothelial carcinoma of urinary bladder with divergent differentiation showing urothelial, squamous, papillary, and glandular differentiation.

Key words: Divergent differentiation, Mixed histology, Urothelial carcinoma

INTRODUCTION

Bladder cancer is the most common malignancy arising in the urinary tract. It is a heterogeneous group of cancers and it arises from the epithelial lining of the bladder called the urothelium. It is the seventh most common cancer in the world. A variant of urothelial carcinoma called urothelial carcinomas with variant histology also known as urothelial carcinoma with divergent differentiation has been noted. These patients were seen to be associated with an increased chance of locally advanced disease and metastasis. Therefore, early diagnosis and treatment of these patients are essential.

CASE REPORT

A 42-year-old male came to the urology outpatient department with complaints of macrohematuria for the past 2 months. The patient did not have history of pain, difficulty in micturition, loss of weight, loss of appetite and was not on any antiplatelet drugs. History revealed that the patient is a known case of chronic kidney disease on hemodialysis. The patient belonged to a socioeconomic class 2 and did not have any adverse social habits. On examination, the patient was pale and vitals were stable. Systemic examination was normal and examination of external genitalia showed penoscrotal edema. The patient was advised a transabdominal ultrasonogram, which revealed increase in renal cortical echoes, mild hydroureteronephrosis, and ill-defined heteroechoic lesion in the urinary bladder measuring 6.0 cm × 3.2 cm, with minimal ascites [Figure 1]. He underwent a computed tomography whole abdomen showing an ill-defined endophytic lesion with papillary projections arising in the dome of the bladder. The patient then underwent a transurethral resection of bladder tumor (TURBT) and the specimen was subjected for histopathological examination. The specimen was processed and it revealed an urothelial carcinoma with divergent differentiation showing a high grade papillary urothelial carcinoma with divergent differentiation showing papillary areas (30%), urothelial areas (30%), squamous areas (30%), and glandular areas (10%) [Figure 2]. Extensive areas of necrosis and brisk mitosis were noted. Immunohistochemistry for p63 and

Access this article online

IJSS
www.ijss-sn.com

Month of Submission : 03-2020
Month of Peer Review : 04-2020
Month of Acceptance : 05-2020
Month of Publishing : 05-2020

Corresponding Author: Dr. Sandhya Sundaram, Department of Pathology, Sri Ramachandra Institute of Higher Education and Research, Porur, Chennai - 600 116, Tamil Nadu, India.

GATA3 was done. p63 was positive in the squamous areas and urothelial areas. GATA3 was positive in the papillary and urothelial areas [Figure 3].

DISCUSSION

Urothelial carcinoma is one of the most common cancers worldwide. It is more common in older age males. It can arise anywhere within the urinary tract, but most commonly from the urinary bladder and the other sites include ureter, renal pelvis, and proximal urethra. Many risk factors have been identified for urothelial carcinomas, some of them are tobacco smoking, occupational exposures, chemicals, urinary tract infection, genetic factors, chronic inflammation, and irradiation.

Almost 90% of the urothelial carcinomas are conventional urothelial carcinomas, the rest of the urothelial carcinomas are urothelial carcinoma with divergent differentiation or non-urothelial carcinomas. Based on the recent WHO 2016 classification of bladder tumors, about 11 histologic variants of urothelial carcinoma are recognized such as the urothelial carcinoma with divergent differentiation, nested variant, microcystic, micropapillary, lymphoepithelioma like carcinoma, plasmacytoid, sarcomatoid, giant cell variant, lipid rich variant, clear cell, and poorly differentiated variant.[1]

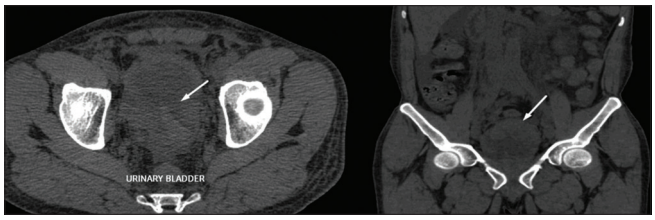

Figure 1: Ultrasonogram of pelvis showing a heteroechoic lesion in the urinary bladder

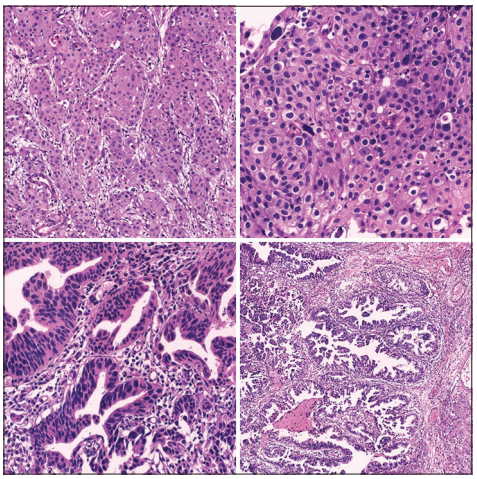

Figure 2: (a) H&E, ×40, urothelial differentiation; (b) H&E, ×40, squamous differentiation; (c) H&E, ×40, glandular differentiation; (d) H&E, ×40, papillary areas

Urothelial carcinoma with divergent differentiation is associated with squamous cell differentiation, glandular differentiation, with trophoblastic differentiation, and small cell differentiation. The squamous differentiation was found to be the most common type accounting for about 20–40%, the glandular differentiation was seen in 6–18% and syncytiotrophoblastic giant cells are seen in 28–35% of urothelial carcinomas with divergent differentiation.[1] Makise *et al.* report a case of urothelial carcinoma with squamous, glandular, and plasmacytoid differentiation confirmed by immunohistochemistry.[2]

Charlise *et al.* studied the impact of urothelial carcinomas with divergent differentiation on tumor stage and report that squamous differentiation was most common. These tumors are associated with higher stage, lymphovascular and perineural invasion and associated with a worse outcome even in T1 high grade urothelial carcinomas.[3] These tumors were seen to be associated with a higher chance of lymph node metastasis.

Our case of urothelial carcinoma was diagnosed by TURBT. Billis *et al.* report a series of 165 cases of urothelial carcinomas with divergent differentiation diagnosed on TURBT. They suggest that these tumors are associated with a higher stage at clinical presentation.[4] Wasco *et al.* also report a series of 448 cases of urothelial carcinoma with divergent differentiation diagnosed on TURBT and these patients were found to have a locally aggressive disease.[5] Genetic studies have indicated that the variants of urothelial carcinomas arise from a common clonal precursor. Thus, extensive search for divergent differentiation in urothelial carcinomas must be done by the pathologist.

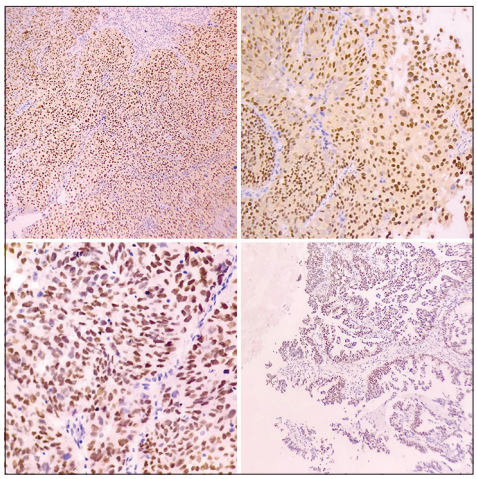

Figure 3: (a) Immunohistochemistry, ×40, p63 positive in urothelial areas, (b) immunohistochemistry, ×40, p63 positive in squamoid areas, (C) immunohistochemistry, ×40, GATA3 positive in urothelial areas, (d) immunohistochemistry, ×40, GATA3 positive in papillary areas

CONCLUSION

Urothelial carcinomas with divergent differentiation have an impact on the local aggressiveness, tumor stage, and lymph node metastasis. An early cystectomy and strict follow-up of these patients will help to improve the oncological outcome.

REFERENCES

1. Lopez-Beltran A, Henriques V, Montironi R, Cimadamore A, Raspollini MR, Cheng L. Variants and new entities of bladder cancer. Histopathology 2019;74:77-96.
2. Makise N, Morikawa T, Takeshima Y, Homma Y, Fukayama M. A case of urinary bladder urothelial carcinoma with squamous, glandular, and plasmacytoid differentiation. Case Rep Oncol 2014;7:362-8.
3. Fujii N, Hoshii Y, Hirata H, Mori J, Shimizu K, Kobayashi K, *et al*. Impact of divergent differentiation in urothelial carcinoma on oncological outcome in patients with T1 high-grade bladder cancer. Jpn J Clin Oncol 2017;47:560-7.
4. Billis A, Schenka AA, Ramos CC, Carneiro LT, Araújo V. Squamous and/or glandular differentiation in urothelial carcinoma: Prevalence and significance in transurethral resections of the bladder. Int Urol Nephrol 2001;33:631-3.
5. Wasco MJ, Daignault S, Zhang Y, Kunju LP, Kinnaman M, Braun T, *et al*. Urothelial carcinoma with divergent histologic differentiation (mixed histologic features) predicts the presence of locally advanced bladder cancer when detected at transurethral resection. Urology 2007;70:69-74.

How to cite this article: Correya MA, Sundaram S, Cruze LD, Natarajan K. A Rare Case of Urothelial Carcinoma with Divergent Differentiation Showing Multiple Varied Histomorphology with Review of Literature. Int J Sci Stud 2020;8(2):13-15.

Source of Support: Nil, **Conflicts of Interest:** It is the policy of "International Journal of Scientific Study" that individuals who submit or review manuscripts for publication disclose any proprietary, financial, professional, or other personal interest that may influence positions presented in, or the review of, the manuscript.

Print ISSN: 2321-6379
Online ISSN: 2321-595X

Case Report

A Very Rare Case of Pancreatic Acinar Variant of Gastric Adenocarcinoma with Review of the Literature

T R Praveen Paul[1], Sandhya Sundaram[2], Lawrence D'Cruze[3], Subalakshmi Balasubramanian[4], Shanmugasundaram Gouthaman[5]

[1]Post graduate, Department of Pathology, Sri Ramachandra Institute of Higher Education and Research, Chennai, Tamil Nadu, India,
[2]Professor and Head, Department of Pathology, Sri Ramachandra Institute of Higher Education and Research, Chennai, Tamil Nadu, India,
[3]Associate Professor, Department of Pathology, Sri Ramachandra Institute of Higher Education and Research, Chennai, Tamil Nadu, India,
[4]Assistant Professor, Department of Pathology, Sri Ramachandra Institute of Higher Education and Research, Chennai, Tamil Nadu, India,
[5]Professor, Department of Surgical Oncology, Sri Ramachandra Institute of Higher Education and Research, Chennai, Tamil Nadu, India

Abstract

A pancreatic acinar variant of gastric adenocarcinoma is a very rare presentation, and only six cases have been reported worldwide. A 55-year-old male came with complaints of vomiting and weight loss. By PET-CT, a growth was found in the gastric antrum. Distal gastrectomy was done and a histopathology report of a pancreatic acinar variant of gastric adenocarcinoma was done.

Key words: Biopsy, Gastric adenocarcinoma, Pancreatic acinar variant

INTRODUCTION

Adenocarcinoma of the stomach is a malignant epithelial neoplasm of the gastric mucosa, with glandular differentiation. It is a common malignancy of the stomach. There are seven different subtypes mentioned in the WHO, and new subtypes are being studied in various institutes. A pancreatic acinar variant of gastric adenocarcinoma is a rare new variant with classic histopathological features. These patients are associated with poor prognosis.

CASE REPORT

A 55-year-old male patient of Northeast Indian origin presented with complaints of vomiting after intake of food and subsequent significant loss of around 9 kg weight. An upper GI endoscopy revealed an ulceroproliferative growth in the antrum. A biopsy was taken, which showed a poorly differentiated adenocarcinoma.

Access this article online

www.ijss-sn.com

Month of Submission : 03-2020
Month of Peer Review : 04-2020
Month of Acceptance : 05-2020
Month of Publishing : 05-2020

The patient was subjected to a PET-CT, and a hypermetabolic malignant mass was found in the antrum which was seen extending into the first part of the duodenum. Radiologically, the pancreas showed no abnormalities, and the laboratory tests were normal. The patient underwent distal gastrectomy with D2 dissection, and the specimen was sent for histopathological evaluation.

On gross examination, an ulceroinfiltrative gray-white firm to the hard lesion was present in the antral region measuring 5.5 × 5 × 1.7 cm, extending up to the muscularis propria. Multiple lymph nodes from Level I to Level XII were sent separately. The specimen was adequately sampled according to standard guidelines.

The microscopy was reported according to the College of American Pathologists protocol. The lesional site showed neoplastic cells invading into the muscularis propria. The neoplastic cells showed three growth patterns: Acinar (50%), glandular (30%), and solid (20%). The acinar areas showed a moderate to abundant eosinophilic cytoplasm, and the nuclei were round to oval with finely dispersed chromatin and indistinct nucleoli. The glandular element

Corresponding Author: Dr. Lawrence D'Cruze, Department of Pathology, Sri Ramachandra Institute of Higher Education and Research, Porur, Chennai - 600 116, Tamil Nadu, India.

consisted of columnar to cuboidal cells with scant eosinophilic cytoplasm and pleomorphic nuclei, increased nuclear-cytoplasmic ratio, and prominent nucleoli. Brisk mitosis (6/10 HPF) was noted. The adjacent gastric mucosa showed no dysplastic changes. The resected margins and serosa were free of tumor. Regional lymph nodes examined to show no involvement by tumor. Perineural and lymphovascular invasion was not identified.

The possible H&E differentials were hepatoid variant of poorly differentiated adenocarcinoma, parietal cell carcinoma, and pancreatic acinar variant of poorly differentiated adenocarcinoma. Immunohistochemistry for alpha-fetoprotein was negative which ruled out hepatoid adenocarcinoma. EMA was positive which ruled out parietal cell carcinoma. Hence, a final diagnosis of Grade 3 poorly differentiated pancreatic acinar variant of gastric adenocarcinoma pT2 pN0 was given, and margins were free of tumor [Figures 1-4].

DISCUSSION

Gastric carcinoma is a common cancer worldwide. Usually, four common variants are recognized: Tubular adenocarcinoma, papillary adenocarcinoma, mucinous adenocarcinoma, and signet ring cells carcinoma. Other rare variants include adenosquamous cell carcinoma, squamous cell carcinoma, mixed adenocarcinoma-carcinoid, small cell carcinoma, choriocarcinoma, endodermal sinus tumor, embryonal carcinoma, and hepatoid adenocarcinoma.[1] The case mentioned above, a pancreatic acinar variant of adenocarcinoma is rarer variant with only six cases being reported worldwide.[2]

The tumor cells which are arranged in acini may be cuboidal to columnar cells with a moderate amount of

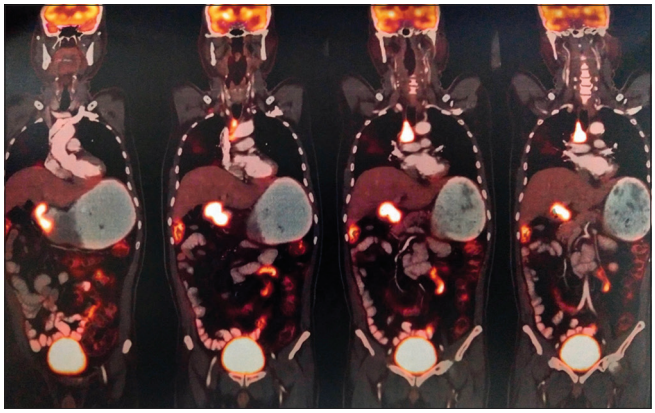

Figure 1: PET-CT shows a hypermetabolic malignant mass in the antrum of the stomach extending into the first part of the duodenum

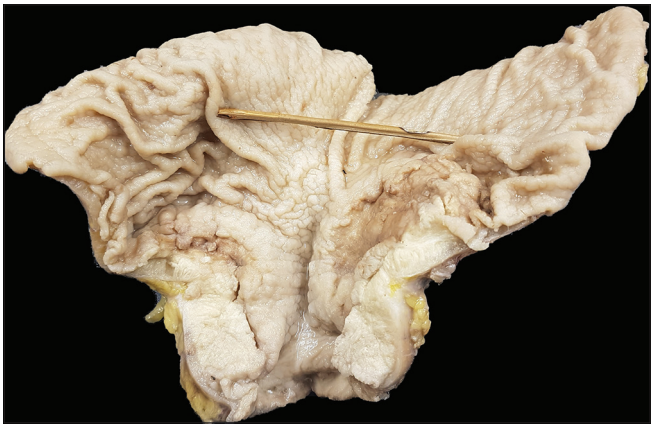

Figure 2: Gross of a distal gastrectomy with D2 dissection specimen showing a gray-white, solid, firm, ulcerative, and infiltrative lesion measuring 5.5 × 5 × 1.5 cm

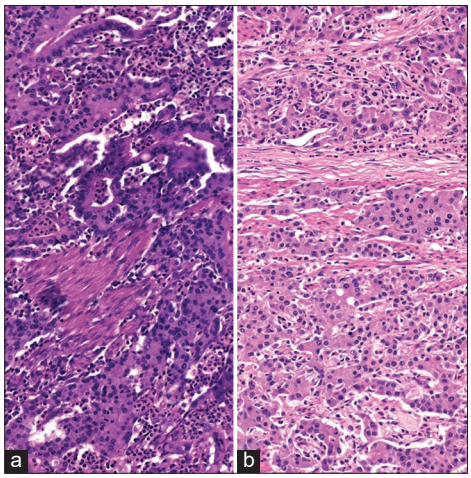

Figure 3: (a) Poorly differentiated neoplastic cells showing vague glandular patter ×40. (b) Neoplastic cells with abundant eosinophilic cytoplasm arranged in the form of acini ×40

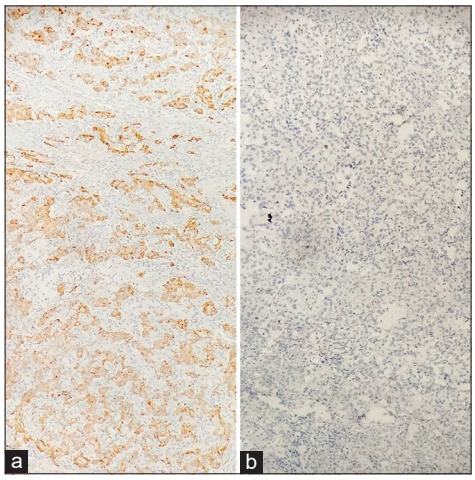

Figure 4: (a) Immunohistochemistry, ×10, EMA shows membrane positivity in the neoplastic cells. (b) Immunohistochemistry, ×10, AFP is negative in the neoplastic cells

eosinophilic cytoplasm, round to oval nuclei showing pleomorphism. Few of them showing prominent nucleoli.[3] The adjacent gastric mucosa can show intestinal metaplasia or features of chronic gastritis. The tumor cells may arise from pancreatic heterotrophy in the gastric mucosa, but it is questionable.[4] The extra-pancreatic acinar cell carcinoma is very rare.[2] There can be congenital acinar metaplasia of the gastric mucosa which can differentiate into pancreatic acinar cells and can later turn malignant.[2]

The tumor cells express pancreatic exocrine enzymes and can be detected by immunohistochemistry. They express predominantly trypsin and other enzymes such as chymotrypsin, alpha-1-antichymotrypsin, and lipase may also be expressed.[3,5] Another diagnostic feature is the presence of zymogen granules which are homogeneous dense granules seen electron microscopy.[3] The prognosis of this case is not known due to the limited number of cases studied.[2,5]

CONCLUSION

A pancreatic acinar variant of adenocarcinoma is a rare variant which can be diagnosed by H&E and immunohistochemistry features. The prognosis of this variant is not known due to the scarcity of published cases. However, most of the cases are associated with early metastasis; thus, it can have a poor prognosis.

REFERENCES

1. Lee SM, Kim KM, Ro YJ. Variants of gastric carcinoma: Morphologic and theranostic importance. In: Gastric Carcinoma-New Insights into Current Management. London: InTech; 2013.
2. Kim KM, Kim CY, Hong SM, Jang KY. A primary pure pancreatic-type acinar cell carcinoma of the stomach: A case report. Diagn Pathol 2017;12:10.
3. Yonenaga Y, Kurosawa M, Mise M, Yamagishi M, Higashide S. Pancreatic-type acinar cell carcinoma of the stomach included in multiple primary carcinomas. Anticancer Res 2016;36:2855-64.
4. Mizuno Y, Sumi Y, Nachi S, Ito Y, Marui T, Saji S, *et al*. Acinar cell carcinoma arising from an ectopic pancreas. Surg Today 2007;37:704-7.
5. Fukunaga M. Gastric carcinoma resembling pancreatic mixed acinar-endocrine carcinoma. Hum Pathol 2002;33:569-73.

How to cite this article: Paul TRP, Sundaram S, D'Cruze L, Balasubramanian S, Gouthaman S. A Very Rare Case of Pancreatic Acinar Variant of Gastric Adenocarcinoma with Review of the Literature. Int J Sci Stud 2020;8(2):16-18.

Source of Support: Nil, **Conflicts of Interest:** None declared.

Print ISSN: 2321-6379
Online ISSN: 2321-595X

Case Report

Case Report: A Case of Addison's Disease

V Pavithra[1], Arun Tyagi[2]

[1]Classified Specialist, Department of Pediatrics, Military Hospital, Agra, Uttar Pradesh, India, [2]Professor and Head, Department of Medicine, Dr. Vithalrao Vikhe Patil Foundation's Medical College, Ahmednagar, Maharashtra, India

Abstract

Addison's disease is chronic adrenocortical insufficiency. Adrenocortical insufficiency (AI) could be due to congenital or acquired causes. Congenital causes include inborn defects of steroidogenesis, adrenal hypoplasia congenita, adrenoleukodystrophy, and familial glucocorticoid deficiency. Acquired causes include autoimmunity (Type 1 and 2 autoimmune polyendocrinopathy), infections such as tuberculosis and meningococcemia, drugs such as ketoconazole, rifampicin, phenytoin, and phenobarbitone, and hemorrhage into adrenals as a consequence of difficult labor, metastasis, amyloidosis, and surgical excision. Although autoimmunity is the major cause of AI in developed countries, infections like tuberculosis still remain an important cause in developing countries like India. Addison's disease can be easily missed due to its presentation with non-specific symptoms. Serum cortisol levels can also be misleading due to variations in circadian rhythm and increase during stressful situations. Hence, strong clinical suspicion is the key to early diagnosis and treatment. We report here a case Addison's disease secondary to tuberculosis.

Key words: Adrenocortical insufficiency, Autoimmunity, Hyperpigmentation, Tuberculosis

INTRODUCTION

Adrenocortical insufficiency (AI), popularly known as Addison's disease, is rare endocrine disease. Addison's disease has an incidence of 0.8/million and a prevalence of 40–60/million in the USA and European countries. It affects males and females in equal numbers and can potentially affect individuals of any age.[1] In India, the prevalence of Addison's disease is estimated around 12/million.[2] Addison's disease was first described by Thomas Addison of University of Edinburgh Medical School in 1855 as a syndrome of weakness and hyperpigmentation. Interestingly, all the 11 cases of adrenocortical insufficiency described by Thomas Addison in his initial report had tuberculosis of adrenals.[3] Famous Addisonian includes President John F Kennedy, Jane Austen, and Osama bin-Laden.

Although Addison's disease is a rare disorder, it is seen in all the social and economic strata of the society in all the countries. Since the presentation is vague, not only the diagnosis is delayed leading to increased morbidity and mortality but it also leaves a number of undiagnosed cases in the society. A survey of patients with Addison's disease revealed that 60% had sought medical attention from two or more physicians before the correct diagnosis was made and there are a number of undiagnosed patients.[4] Acute adrenocortical insufficiency (Addisonian crisis), a potentially catastrophic condition, is seen in nearly 6–8% of cases of AI and if not managed promptly and aggressively, can be life threatening.[5] Awareness about this condition and high index of suspicion is required for timely diagnosis and intervention. We present the case report of a child whose non-specific manifestations resulted in 2 years' delay in reaching proper diagnosis.

Access this article online

www.ijss-sn.com

Month of Submission : 03-2020
Month of Peer Review : 04-2020
Month of Acceptance : 05-2020
Month of Publishing : 05-2020

CASE REPORT

A Three and half-year-old female child presented with fever and cough of 1-month duration. This child had been suffering from recurrent upper respiratory tract symptoms along with generalized weakness, malaise, loss of appetite, and poor weight gain for previous 2 years. There was no history of pain abdomen or vomiting. On examination, her height (92 cm) and weight (13 kg) were below the 10th percentile. Her body mass index was 14.4 kg/m^2. Her pulse was 92 beats/min, respiratory rate 18 cycles/min, and blood pressure was 80/50 mmHg. There was no orthostatic hypotension. The child had generalized hyperpigmentation

Corresponding Author: Arun Tyagi, Dr. Vithalrao Vikhe Patil Foundation's Medical College, Ahmednagar - 414 111, Maharashtra, India

of the skin, buccal mucosa, hard palate, gums, and over palms and soles [Figure 1] which the parents first noticed around 2 years back and had been gradually increasing. Rest of the general examination was non-contributory. The sexual maturity rating (Tanner stage) was pre-pubertal. Respiratory system examination revealed crackles over the right inframammary and infra-axillary areas. Rest of the systemic examination was unremarkable. Possibility of chronic adrenocortical insufficiency was considered in view of hyperpigmentation and growth retardation and history of recurrent respiratory tract infections pointed to tuberculosis as the cause.

Laboratory work-up revealed hemoglobin 10.2 g/dl, total leukocyte count (TLC) 10,200/μl, differential leukocyte count-P42 L48 M06 E04, and ESR 32 mm in the 1st h. Biochemical parameters including serum glucose, renal and liver function tests, and serum electrolytes were normal. X-ray chest posteroanterior revealed non-homogenous opacities over right lower zone [Figure 2] and Mantoux test showed a wheal and induration of 12 mm diameter (normal <10 mm). Gastric aspirate for acid-fast bacilli (three early morning samples) was negative. Serum cortisol level was low; 4.2 μg/dl (normal <18 μg/dl). Plasma adrenocorticotropic hormone (ACTH) level was 978 pg/ml (normal <46 pg/ml). On ACTH stimulation test, there was no increase in cortisol levels at 30 min and 60 min following administration of cosyntropin 250 μg. Non-contrast computed tomography (CT) abdomen revealed bilateral enlarged adrenal glands [Figure 3]. Taking into consideration, the clinical profile and investigation results, the diagnosis of Addison's disease secondary to pulmonary tuberculosis was made. Adrenal biopsy was not done as it is an invasive procedure and would have added little to the patient management.

Child was managed with anti-tubercular treatment (ATT-2EHRZ +4HR) along with intravenous hydrocortisone at 100 mg/m^2/day initially for 1 week and subsequently discharge on replacement dose of oral hydrocortisone at 10 mg/m^2/day in three divided doses.

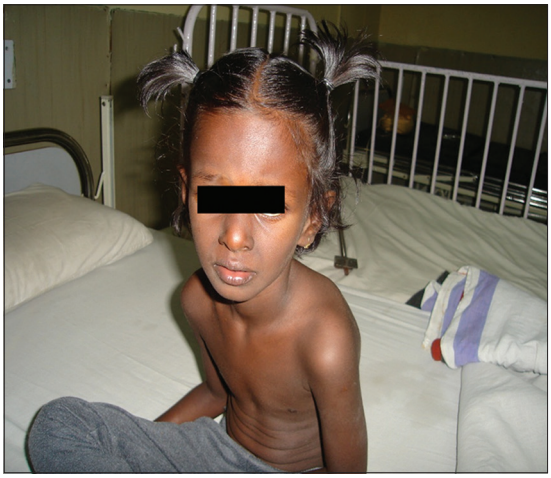

Figure 1: Hyperpigmentation of the skin

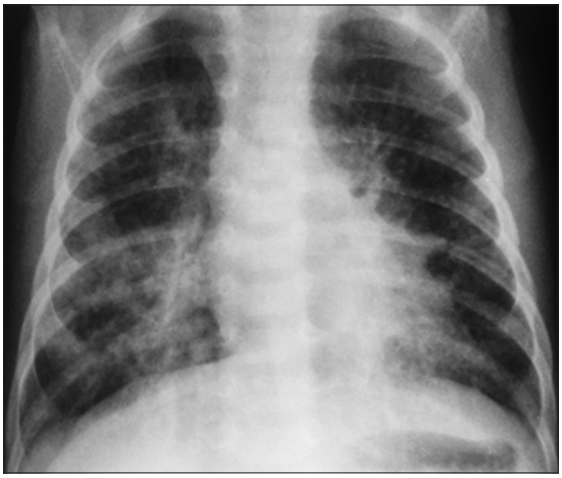

Figure 2: Non-homogenous opacities right lower lobe

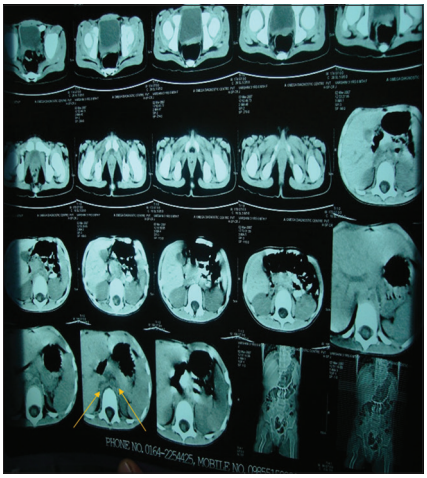

Figure 3: Non-contrast computed tomography abdomen – bilateral enlarged adrenal glands

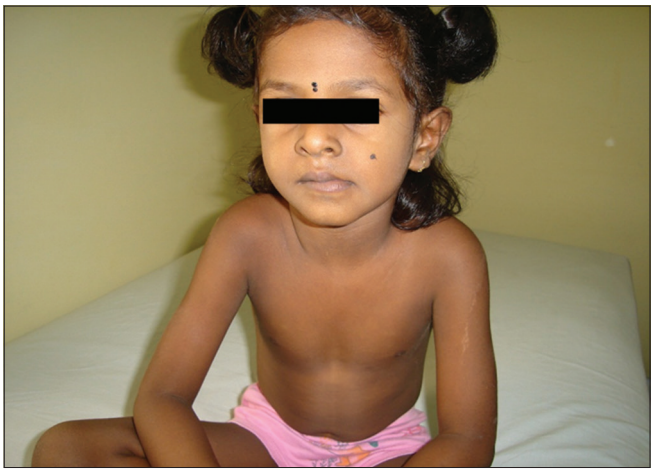

Figure 4: After 3 months – fading hyperpigmentation and weight gain

On follow-up after 3 months, the child had gained 2 kg weight and the hyperpigmentation disappeared [Figure 4]. Plasma ACTH level at 6 months was 202 pg/dl.

The parents were counseled regarding the nature of the disease and the need for lifelong replacement therapy and periodic follow-up with the pediatrician/physician.

Parents were also explained about the need to carry a disease identity card/bracelet and the need for stress dose steroids before dental/surgical procedures.

DISCUSSION

Addison's disease is a rare disorder. AI may be caused by destruction or dysfunction of adrenal gland (primary AI, Addison's disease), deficient pituitary ACTH secretion (secondary AI), or deficient hypothalamic secretion of corticotropin-releasing hormone (Tertiary AI).

The most common cause of primary AI in children is congenital adrenal hyperplasia (CAH) which accounts for 70% of pediatric patients with AI, whereas autoimmune adrenalitis accounts for 15% of cases.[4] The most common cause of CAH is 21-hydroxylase deficiency, accounting for ~ 90% of all CAH cases, with an incidence of 1 in 14,000 live births.[6] Autoimmune Addison's disease may be associated with other autoimmune diseases such as autoimmune polyendocrine syndromes types 1 and 2. Iatrogenic tertiary AI caused by suppression of the hypothalamic-pituitary adrenal axis secondary to glucocorticoid administration is the most common cause of central AI, with an estimated prevalence of 150–280 per 1,000,000. In developed countries, only about 10% of cases of Addison's disease have infectious etiology. In developing countries like India, the infectious etiology is more common. Tuberculosis accounts for about 20–30% of cases of Addison's disease in developing world. Adrenal tuberculosis is one of the five most common sites of extra-pulmonary tuberculosis. Lam and Lo reported 6% incidence of adrenal tuberculosis in the patients with active tuberculosis at autopsy.[7] Other infections include HIV, opportunistic infections like cytomegalovirus, and fungi such as Cryptococcus, Histoplasma, and Coccidioides.[8] It is possible that infections play a role in the development of AAD.[9]

Presentation is usually insidious but can be acute during an adrenal crisis. The clinical features of AI are manifested only after more than 90% of the adrenal gland has been destroyed. The most common symptoms such as lethargy, weakness, anorexia, nausea, and vomiting are vague, usually delaying the diagnosis. Hyperpigmentation is the most frequent feature seen in 90% of the cases of AI. Other clinical signs include failure to thrive, orthostatic hypotension, hyponatremia, hyperkalemia, and hypoglycemia. Hyponatremia is the most commonly found metabolic abnormality. A high index of suspicion is needed to diagnose AI.[10] Diagnosis is based on clinical presentation, electrolyte changes (hyponatremia and hyperkalemia), low cortisol levels, abnormal ACTH stimulation test, and CT abdomen findings. CT abdomen can also help correlate the clinical duration of Addison's disease.[11] In cases where etiology of AI remains uncertain, percutaneous biopsy is a safe, accurate procedure for the diagnosis of pathologic conditions of the adrenal glands.[12] Percutaneous biopsy is largely indicated in cases where malignancy needs to be ruled out.

Differential diagnosis includes other causes of hyperpigmentation such as melasma, malignant melanoma, and anorexia nervosa. AI should be kept as a possibility in the patients presenting with hyponatremia. In cases presenting in Addison's crisis, sepsis, gastroenteritis, acute abdomen, and hypovolemic shock need to be ruled out.

Treatment includes intravenous hydrocortisone during the acute episode followed by chronic replacement with oral hydrocortisone and if needed, fludrocortisone. Usually, the patients require lifelong replacement therapy with steroids. Since plasma cortisol levels and ACTH stimulation test does not usually return to normal after completion of antitubercular therapy.[13] Prognosis is good with proper control and special attention to drug interactions. One of the most important aspects of the management of AI is patient and family education. The reason for lifelong replacement therapy, the need to increase the dose of glucocorticoid during stress, and shift to injectable steroids in emergencies cannot be overemphasized.[14] Starting doses of glucocorticoids should be 15–20 mg for hydrocortisone or equivalent, preferably weight adjusted, with one half to two-thirds of the total daily dose being given in the morning. The long-acting synthetic glucocorticoids should be avoided because their longer duration of action may produce manifestations of chronic glucocorticoid excess. Timed release hydrocortisone tablets and continuous subcutaneous hydrocortisone infusion are promising new treatment modalities.[15]

Adrenal crisis, also termed acute AI, is the most dreaded and acute life-threatening complication. Even with proper recognition and treatment, the adrenal crisis may result in death. Other complications of Addison's disease include arrhythmias, seizures and coma etc due to electrolyte abnormalities such as hyponatremia, hyperkalemia and hypoglycemia. Hypotension may lead to hypoperfusion and organ failure as well.

CONCLUSION

Addison's disease is a rare disorder that has vague and non-specific presentation often leading to delay in diagnosis and requires high index of suspicion for timely management. Failure to identify the disorder in time may result in life-threatening emergency of adrenal crisis. Education of the patients and the parents is the key to successful management. All patients must be counseled regarding need for lifelong treatment and need to carry a medical alert identification card.

REFERENCES

1. NORD: Rare Diseases Database, Addison's Disease; 2018. Available from: https://www.rarediseases.org/rare-diseases/addisons-disease. [Last accessed on 2020 Apr 15].
2. Mokta J, Mokta K, Ranjan A, Joshi I. Tubercular Addison' disease-an under-diagnosed entity. J Assoc Physicians India 2016;64:101. Available from: https://www.japi.org/september_2016/26_corr.html. [Last accessed on 2020 Apr 18].
3. Pearce JM. Thomas Addison (1793-1860). J Royal Soc Med 2004;97:297-300. Available from: https://www.journals.sagepub.com/doi/pdf/10.1177/014107680409700615. [Last accessed on 2020 Apr 19].
4. Ten S, New M, Maclaren N. Clinical review 130: Addison's disease 2001. J Clin Endocrinol Metab 2001;86:2909-22.
5. Hahner S, Loeffler M, Bleicken B, Drechsler C, Milovanovic D, Fassnacht M, *et al*. Epidemiology of adrenal crisis in chronic adrenal insufficiency: The need for new prevention strategies. Eur J Endocrinol 2010;162:597-602.
6. Arlt W, Allolio B. Adrenal insufficiency. Lancet 2003;361:1881-93.
7. Lam KY, Lo CY. A critical examination of adrenal tuberculosis and a 28-year autopsy experience of active tuberculosis. Clin Endocrinol (Oxf) 2001;54:633-9.
8. Hellesen A, Bratland E. The potential role for infections in the pathogenesis of autoimmune Addison's disease. Clin Exp Immunol 2018;195:52-63.
9. Vinnard C, Blumberg EA. Endocrine and metabolic aspects of tuberculosis. Microbiol Spectr 2017;5:10.
10. Auron M, Raissouni N. Adrenal insufficiency. Pediatr Rev 2015;36:92-102.
11. Guo YK, Yang ZG, Li Y, Ma ES, Deng YP, Min PQ, *et al*. Addison's disease due to adrenal tuberculosis: Contrast-enhanced CT features and clinical duration correlation. Eur J Radiol 2007;62:126-31.
12. Welch TJ, Sheedy PF 2nd, Stephens DH, Johnson CM, Swensen SJ. Percutaneous adrenal biopsy: Review of a 10-year experience. Radiology 1994;193:341-4.
13. Bhatia E, Jain SK, Gupta RK, Pandey R. Tuberculous Addison's disease: Lack of normalization of adrenocortical function after anti-tuberculous chemotherapy. Clin Endocrinol (Oxf) 1998;48:355-9.
14. Nicolaides NC, Chrousos GP, Charmandari E. Adrenal insufficiency. In: Feingold KR, Anawalt B, Boyce A, Chrousos G, Dungan K, Grossman A, editors. Endotext. South Dartmouth (MA): MDText.com., Inc.; 2017.
15. Løvås K, Husebye ES. Replacement therapy for Addison's disease: Recent developments. Expert Opin Investig Drugs 2008;17:497-509.

How to cite this article: V Pavithra, Tyagi A. Case Report: A Case of Addison's Disease. Int J Sci Stud 2020;8(2):19-22.

Source of Support: Nil, **Conflicts of Interest:** None declared.

Print ISSN: 2321-6379
Online ISSN: 2321-595X

Review Article

Relation of Biological Factors with Failure of Osseointegration of Dental Implants

Pravin R Bonde[1], Seda Ozturan[2]

[1]2nd Year Post Graduate, [2]Professor, Dental Science Masters Programme, Universitat Jaume I, Castello de la Plana Castellon, Spain

Abstract

Osseointegration, a term explained by Branemark and co-workers in the early 1960s, represents a direct connection between bone and implant without interposed soft tissue layers. The purpose of the present topic is to discuss various factors responsible for the loss of implants. The factors influencing the failure of osseointegration have been identified as the medical status of the patient, smoking, bone quality, bone grafting, irradiation of bone, bacterial contamination, lack of pre-operative antibiotics, degree of surgical trauma, and operator experience. Furthermore, it appears that implant surface properties, roughness, and premature loading influence the failure rate. Dental implantology is the science associated with the diagnosis, design, insertion, restoration, and/or management of alloplastic or autogenous oral structure to restore the loss of contour, comfort, function, esthetic, speech, and/or health of the partially or completely edentulous patient.

Key words: Alloplast, Failure, Implants, Osseointegration

INTRODUCTION

The implants have become an important therapeutic modality in the last decade, mainly after the works developed by Brånemark, in which the direct contact between the bone functional tissues and the biomaterial titanium which was termed osseointegration.

Dental implants are inert, alloplastic materials embedded in the maxilla and/or mandible for replacing lost tooth/teeth and lost orofacial structures as a result of trauma, neoplasia, and congenital defects. The most common type of dental implant is endosseous, comprising a discrete, single implant unit placed within a drilled space within dentoalveolar or basal bone.

SUCCESS AND FAILURE

Adell (1981) reported the success rate of 895 implants over an observation period of 5 years after placement. Eighty-one percent of maxillary and 91% of mandibular implants remained stable.

Access this article online

www.ijss-sn.com

Month of Submission : 03-2020
Month of Peer Review : 04-2020
Month of Acceptance : 05-2020
Month of Publishing : 05-2020

Albrektsson (1986) proposed the formula for successful integration of dental implants have been. Of these, a lack of mobility is of prime importance as "loosening" is the most often cited reason for implant body removal.

Despite high success rates, implant failure may occur and is defined as the inadequacy of the host tissue to establish or maintain osseointegration. One review (Adell, 1990) suggested that 2% of implant fixtures failed to achieve osseointegration following placement. Using this meta-analysis, failure rates for Branemark dental implants were 7.7% (excluding bone grafts) over 5 years. Interestingly, failure rates in edentulous patients were almost double than those for partially dentate patients (7.6% vs. 3.8%).

IMPLANT COMPLICATIONS AND FAILURE

Factors associated for implant complication and failure have been extensively reviewed by Esposito *et al.* (1998). Factors affecting early failure of dental implants may be briefly classified as:

- Implant
- Patient and
- Surgical technique/environment related.

Corresponding Author: Seda Ozturan, Dental Science Masters Programme, Universitat Jaume I, Castello de la Plana Castellon, Spain

Esposito *et al.* (1999) defined biological failure related to biological process and mechanical failures related to fractures of components and prostheses. Koutsonikos (1998) added the categories of iatrogenic failure and failure due to patient adaptation. El Askary *et al.* (1999) further defined failure as ailing, failing, and failed implants. This article gives an overview of the important biological factors that affect osseointegration and thus lead to loss of implant [Table 1]. Three major etiologic factors have been suggested as follows:

Infection

Infections caused due to bacteria occurs any time after implant placement. Many terms are currently used, indicating failing implants or complications. They are peri-implant disease, peri-implant mucositis, and peri-implantitis.

Peri-implant disease is a collective term for inflammatory reactions in the soft tissues which surround implants.

Peri-implant mucositis is a term that describes reversible inflammatory reactions in the soft tissue surrounding implants.

Other soft-tissue complications (hyperplastic mucositis, fistulas, and mucosal abscesses) seem mainly to have an infectious etiology. Fistulations and hyperplastic mucositis are often found in association to lose prosthetic components. Abscesses can occasionally be seen in relation to food particles trapped in the peri-implant crevice.

Impaired Healing

It is believed that the amount of surgical trauma (lack of irrigation and overheating), micromotion, and some local and systemic characteristics of the host play a major role in implant failures related to impair healing.

Overload

When the load applied to dental implants beyond the withstanding capacity of the bone, overload occurs, causing implant to failure. Failures that happen between abutment connection and delivery of the prosthesis, probably caused by unfavorable loading conditions or induced by the prosthetic procedure, considered to have an overload etiology. Other attributes to implant failure are poor surgical technique, poor bone quality, and poor prosthesis design in addition to the traumatic loading conditions.

FACTORS RELATED TO PATIENT

The patient factor is an important determinant of implant failure. Ekfeldt *et al.* (2001) identified the patient risk factors leading to multiple implant failures and concluded that a combination of several medical situations could be a contraindication to implant treatment. Hutton *et al.* (1995) showed that people with one implant failure would be likely to have others, and Weyant (1994) stated that a positive medical history is associated with an increase in implant failure. Weyant and Burt (1993) observed a 30% increase in the chances of removal of a second implant in patients with multiple implants presenting with one failure. This evidence indicates that implant failures are not randomly distributed in the population, but seems to occur in a small subset of individuals.

Table 1: Factors associated to failure of dental implants

Factor	Comments
Implant fixture	Previous failure Surface characteristics Surface purity and sterility Fit discrepancies Intra-oral exposure time
Mechanical overloading (overload)	Premature loading of implant Traumatic occlusion due to inadequate Restorations
Patient or local factors	Bone quantity/quality Adjacent infection/inflammation Oral hygiene Gingivitis Presence of natural teeth Periodontal condition of natural teeth Lodging of foreign bodies (including Debris from surgical procedure) in the implant pocket Soft tissue viability
Patient (systemic factors)	Vascular integrity smoking alcoholism Predisposition to infection, e.g., age, obesity, steroid therapy, malnutrition, metabolic disease (diabetes) systemic illness chemotherapy/ radiotherapy hypersensitivity to implant components
Surgical techniques/ environment	Surgical trauma Overheating (use of handpiece) Perioperative bacterial contamination, e.g., through saliva, perioral skin, gloves, armamentarium, operating room air, or air expired by the patient

MEDICAL STATUS

Diabetes

Diabetic patients experience delayed wound healing, which logically affects the osseointegration process. Uncontrolled diabetes has been proven to inhibit osseointegration and leads to implant failure. Fiorellini *et al.* (2001) demonstrated a low success rate of only 85% in diabetic patients, while Olson *et al.* (2000) found that the duration of diabetes had effects on implant success: More failures occurred in patients who had diabetes for a longer period. Fiorellini *et al.* (2001) observed that most failures in diabetic patients occurred in the 1st year after implant is loaded. Special

review programs and contingency plans are prudent commitments in the treatment planning for this category of patients.

Cigarettes Smoking

The ill effects of cigarette smoking on implant treatment are well documented. A longitudinal study by Lambert *et al.* (2000) found more failures in patients who smoked, and Bain and Moy (1993) observed that a significantly greater percentage of failures occurred in smokers (11.3%) than in non-smokers (4.8%). This difference was highly significant for implants placed in all regions of the jaws, with the exception of the posterior mandible. Several retrospective short-term studies in different populations and with different implant systems have been published and they demonstrate similar results. Kan *et al.* (1999) reported that smoking also creates problems in implants in the grafted maxillary sinuses.

Cigarette smoking is associated with significantly higher levels of marginal bone loss around implants, and the effect of smoking status on the hard and soft peri-implant tissues has been clearly shown. Lemons *et al.* (1997) again showed that smoking reduced bone density in the femur and vertebrae as well as in the jawbone.

The short-term advantage of a smoking cessation protocol suggested by Bain (1993) further explained the causal relationship between smoking and implant failure. The protocol specifically states that complete smoking cessation for 1 week before and 8 weeks after surgery. The results indicated that the smokers who undergone the cessation protocol displayed short-term implant failure rates similar to non- smokers, and significantly lower than smokers who did not follow the protocol. Although the meta-analysis published by Bain *et al.* in 1993 suggested that patients who smoked <12 cigarettes per day did not significantly affect the osseointegration of implant, the adverse effects mentioned by the previous mentioned studies should not be ignored.

Age

In young patients, implants such as "ankylosed (osseointegrated)" devices can introduce problems in growing jaws. Op Heij *et al.* (2003) reported that jaw bone growth can compromise oral implants and questioned the minimum age of a patient for implant treatment. Other studies have also discussed complications in similar situations, including submerging the implants in the jaw, changing position of the implants, potential for interference with normal jaw growth, and occlusal problems.

Theoretically, patients with more age will have more systemic health problems, but there is no scientific proof correlating old age with implant failure. Although Salonen *et al.* (1993) stated that advanced age was a possible contributing factor to implant treatment failure, other reports have shown no relationship between old age and implant failure.

IATROGENIC FACTORS

a. Overheating of bone during surgery
   The most widely suspected reason for failures occurring within 3 months of insertion is tissue overheating during the surgery. Salonen *et al.* (1993) found that 5.8% of implants were lost due to failures in osseointegration. Bone necrosis can occur if bone is heated to a temperature of 47°C for 1 min. The use of proper irrigation and sharp drills at low rotation speed can be employed to reduce heat generation. Moreover, Brisman (1996) recommended increasing both to allow speed and the load of the handpiece more efficient cutting and less frictional heat.
b. Lack of communication
   Most implant treatments involve multidisciplinary cooperation, and a lot of complications are related to communication errors. Starting from patient assessment with radiographs to the completion of treatment in which the laboratory processes the prosthesis, accurate communication among various team members plays a very important role in therapy. Watanabe *et al.* (2002) have emphasized the importance of thorough communication within the implant team. Tolman and Laney (2002) stressed that many failures are the result of wrong diagnosis, poor treatment techniques, and a lack of communication between members of the treatment team.

LOCAL FACTORS

a. Peri-implantitis

Peri-implantitis is a chronic, progressive, marginal, and inflammatory process affecting the tissues surrounding osseointegrated implants that result in the loss of supporting bone. It accounts for 10–50% of all implant failures occurring after the 1st year of loading of implant. The exact pathogenesis of peri-implantitis is still not clearly known. Plaque accumulation on natural teeth may play a role in the bacterial composition of the peri-implant sulcus. Apse *et al.* (1989) found raised levels of Gram-negative bacteria in the peri-implantitis sulcus of dentate patients. Studies by Mombelli *et al.* (1987) and Rosenberg *et al.* (1991) showed that there is a presence of periodontal microorganisms around failing implants.

Haanaes (1990) stated that peri-implantitis is similar to periodontitis occurring in natural teeth. Lang *et al.* (2000) suggested a cumulative interceptive supportive therapy protocol to treat peri-implantitis, which includes mechanical debridement, antiseptic treatment, antibiotic treatment, and regenerative or resective therapy.

b. Position of the implant site

Due to the poor quality of bone in the maxillary bone, the results of implant treatment anywhere in the maxillae are generally poorer than those in the mandible. Adell *et al.* (1990) found a failure rate of about 20% for upper jaw implants. A retrospective multicenter evaluation study by van Steenberghe (1989) found that 1 in 6 (17%) implants placed in the maxillary molar region were lost as compared with 2 of 45 (4%) placed in the mandibular molar region. Jaffin and Berman (1991) reported the loss of 8.3% of 444 implants placed in the maxillae in their 15-year experience. In general, mandibular implants survive longer than maxillary implants.

c. Bone quality and quantity

The most important local patient factor for successful implant treatment is the quality and quantity of bone available for implant placement. Patients with low quality and low density of bone were at the highest risk for implant loss. Jaffin and Berman (1991), in their 5-year analysis, reported that as many as 35% of all implant failures occurred in type IV bone due to its thinner cortex, poor medullary strength, and low trabecular density. Unfortunately, the diagnosis of type IV bone is usually made during implant drilling for insertion. Although periapical X-rays offer some diagnostic help in identifying type IV bone, they may be deceiving because a thick buccal or lingual plate may hide the soft medullary nature of the internal bone.

Systemic osteoporosis has also been mentioned as a possible risk factor for failure of osseointegration of implants. Although the prevalence of osteoporosis increases among the elderly persons and after menopause, it appears that osteoporosis, as diagnosed at one particular site of the skeletal bone, is not necessarily seen at another distant site. In the study conducted by Roberts *et al.* (1992) and Dao *et al.* (1993), local rather than systemic bone density seemed to be the predominant factor.

d. Irradiated bone

Implants can be used to provide support for craniofacial prostheses. Radiotherapy in combination with surgical excision is the treatment generally given for malignant tumors in that region, and osteoradionecrosis is one of the oral effects of radiation therapy. Although radiation therapy is not an absolute contraindication for implant treatment, the reported success rate is only about 70%. Long-term studies are limited, but Jacobsson *et al.* (1988) showed increasing implant failure/loss over time.

Adjunctive hyperbaric oxygen (HBO) therapy has been also proposed for previously irradiated implant patients, especially for the region of the maxilla, zygoma, and frontal bones. For implants in the maxillary bone and orbit, Granstrom *et al.* (1992) demonstrated a failure rate of 58% without HBO (1983–1990) and of only 2.6% after HBO pre-treatment (1988–1990). In a later case-controlled study, Granstrom *et al.* (1999) further made a conclusion that HBO treatment reduced the implant failure rate in irradiated bone.

CONCLUSION

There is high success rate with endosseous implants but failures unavoidably occur. At an early stage, lack of primary stability of implant, surgical trauma, perioperative contamination, and occlusal overload seem to be the most important causes of implant failure.

REFERENCES

Adell R, Lekholm U, Rockler B, Branemark PI. A 15-year study of osseointegrated implants in the treatment of the edentulous jaw. Int J Oral Surg 1981;10:387-416.

Adell R, Eriksson B, Lekholm U, Branemark PI, Jemt T. A long-term follow-up study of osseointegrated implants in the treatment of totally edentulous jaws. Int J Oral Maxillofac Implants 1990;5:347-59.

Albrektsson T, Zarb GA, Worthington P, Eriksson AR. The long-term efficacy of currently used dental implants: A review and proposed criteria of success. Int J Oral Maxillofac Implants 1986;1:11-25.

Apse P, Ellen RP, Overall CM, Zarb GA. Microbiota and crevicular fluid collagenase activity in the osseointegrateddental implant sulcus: A comparison of sites in edentulous and partially edentulous patients. J Periodontal Res 1989;24:96-105.

Bain CA, Moy PK. The association between the failure of dental implants and cigarette smoking. Int J Oral Maxillofac Implants 1993;8:609-15.

Bain CA. Smoking and implant failure-benefits of a smoking cessation protocol. Int J Oral Maxillofac Implants 1996;11:756-9.

Bain CA, Weng D, Meltzer A, Kohles SS, Stach RM. A meta-analysis evaluating the risk for implant failure in patients who smoke. Compend Contin Educ Dent 2002;23:695-9.

Brisman DL. The effect of speed, pressure, and time on bone temperature during the drilling of implant sites. Int J Oral Maxillofac Implants 1996;11:35-7.

Dao TT, Anderson JD, Zarb GA. Is osteoporosis a risk factor for osseointegration of dental implants? Int J Oral Maxillofac Implants 1993;8:137-44.

De Bruyn H, Collaert B. The effect of smoking on early implant failure. Clin Oral Implants Res 1994;5:260-4.

Ekfeldt A, Christiansson U, Eriksson T, Lindén U, Lundqvist S, Rundcrantz T, *et al*. A retrospective analysis offactors associated with multiple implant failures in maxillae. Clin Oral Implants Res 2001;12:462-7.

El Askary AS, Meffert RM, Griffin T. Why do dental implants fail? Part I. Implant Dent 1999;8:173-85.

Esposito M, Hirsch JM, Lekholm U, Thomsen P. Biological factors contributing to failures of osseointegrated implants (I). Success criteria and epidemiology. Eur J Oral Sci 1998;106:527-51.

Esposito M, Hirsch J, Lekholm U, Thomsen P. Differential diagnosis and treatment strategies for biologic complications and failing oral implants:

A review of the literature. Int J Oral Maxillofac Implants 1999;14:473-90.
Esposito M, Thomsen P, Ericson LE, Lekholm U. Histopathologic observations on early oral implant failures. Int J Oral Maxillofac Implants 1999;14:798-810.
Eriksson A, Albrektsson T, Grane B, McQueen D. Thermal injury to bone. A vital microscopic description of heat effects. Int J Oral Surg 1982;11:115-21.
Eriksson AR, Albrektsson T. Temperature threshold levels for heat-induced bone tissue injury: A vital-microscopic study in the rabbit. J Prosthet Dent 1983;50:101-7.
Fiorellini JP, Chen PK, Nevins M, Nevins ML. A retrospective study of dental implants in diabetic patients. Int J Periodontics Restorative Dent 2000;20:366-73.
Friberg B, Jemt T, Lekholm U. Early failures in 4,641 consecutively placed Branemark dental implants: A study from stage 1 surgery to the connection of completed prostheses. Int J Oral Maxillofac Implants 1991;6:142-6.
Granstrom G, Jacobsson M, Tjellstrom A. Titanium implants in irradiated tissue: Benefits from hyperbaric oxygen. Int J Oral Maxillofac Implants 1992;7:15-25.
Granstrom G, Tjellstrom A, Branemark PI. Osseointegrated implants in irradiated bone: A case-controlled study using adjunctive hyperbaric oxygen therapy. J Oral Maxillofac Surg 1999;57:493-9.
Gorman LM, Lambert PM, Morris HF, Ochi S, Winkler S. The effect of smoking on implant survival at second-stage surgery: DICRG interim Report No. 5. Dental implant clinical research group. Implant Dent 1994;3:165-8.
Haas R, Haimbock W, Mailath G, Watzek G. The relationship of smoking on Peri-implant tissue: A retrospective study. J Prosthet Dent 1996;76:592-6.
Haanaes HR. Implants and infections with special reference to oral bacteria. J Clin Periodontol 1990;17:516-24.
Hutton JE, Heath MR, Chai JY, Harnett J, Jemt T, Johns RB, *et al*. Factors related to the success and failure rates at 3-year follow-up in a multicenter study of overdentures supported by Branemark implants. Int J Oral Maxillofac Implants 1995;10:33-42.
Ibbott CG, Kovach RJ, Carlsson-Mann LD. Acute Periodontal abscess associated with an immediate implant site in the maintenance phase: A case report. Int J Oral Maxillofac Implants 1993;8:699-702.
Jacobsson M, Tjellstrom A, Thomsen P, Albrektsson T, Turesson I. Integration of titanium implants in irradiated bone. Histologic and clinical study. Ann Otol Rhinol Laryngol 1988;97:377-40.
Jaffin RA, Berman CL. The excessive loss of Branemark fixtures in Type IV bone: A 5-year analysis. J Periodontol 1991;62:2-4.
Kan JY, Rungcharassaeng K, Lozada JL, Goodacre CJ. Effects of smoking on implant success in grafted maxillary sinuses. J Prosthet Dent 1999;82:307-11.
Koutsonikos A. Implants: Success and failure a literature review. Ann R Australas Coll Dent Surg 1998;14:75-80.
Lambert PM, Morris HF, Ochi S. The influence of smoking on 3-year clinical success of osseointegrated dental implants. Ann Periodontol 2000;5:79-89.
Lang NP, Wilson TG, Corbet EF. Biological complications with dental implants: Their prevention, diagnosis and treatment. Clin Oral Implants Res 2000;11 Suppl 1:S146-55.
Lemons JE, Laskin DM, Roberts WE. Changes in patient screening for a clinical study of dental implants after increased awareness of tobacco use as a risk factor. J Oral Maxillofac Surg 1997;55 Suppl 5:S72-5.
Lindquist LW, Carlsson GE, Jemt T. Association between marginal bone loss around osseointegrated mandibular implants and smoking habits: A 10-year follow-up study. J Dent Res 1997;76:1667-74.
Linden R, PihakariA, Perala A, Makela A. The 2002 dental implant yearbook. In: The Finnish Dental Implant Register. Helsinki: National Agency for Medicines; 2003.
Mombelli A, van Oosten MA, Schurch E, Land N. The microbiota associated with successful or failing osseointegrated titanium implants. Oral Microbiol Immunol 1987;2:145-51.
Mombelli A, Lang NP. The diagnosis and treatment of peri-implantitis. Periodontology 2000 1998;17:63-76.
Olson JW, Shernoff AF, Tarlow JL, Colwell JA, Scheetz JP, Bingham SF. Dental endosseous implant assessments in a Type 2 diabetic population: A prospective study. Int J Oral Maxillofac Implants 2000;15:811-8.
O'Mahony A, Spencer P. Osseointegrated implant failures. J Ir Dent Assoc 1999;45:44-51.
Op Heij DG, Opdebeeck H, van Steenberghe D, Quirynen M. Age as compromising factor for implant insertion. Periodontology 2000 2003;33:172-84.
Salonen MA, Oikarinen K, Virtanen K, Pernu H. Failures in the osseointegration of endosseous implants. Int J Oral Maxillofac Implants 1993;8:92-7.
Sánchez-Garcés MA, Gay-Escoda C. Periimplantitis. Med Oral Patol Oral Cir Bucal 2004;9:S63-74.
Santos MC, Campos MI, Line SR. Early dental implant failure: A review of the literature. Braz J Oral Sci 2002;1:103-11.
Shernoff AF, Colwell JA, Bingham SF. Implants for Type II diabetic patients: Interim report. VA implants in diabetes study group. Implant Dent 1994;3:183-5.
Smith GC. Surgical principles of the Branemark osseointegration implant system. Aust Prosthodont Soc Bull 1985;15:37-40.
Smith RA, Berger R, Dodson TB. Risk factors associated with dental implants in healthy and medically compromised patients. Int J Oral Maxillofac Implants 1992;7:367-72.
Roberts WE, Simmons KE, Garetto LP, DeCastro RA. Bone physiology and metabolism in dental implantology: Risk factors for osteoporosis and other metabolic diseases. Implant Dent 1992;1:11-21.
Rosenberg ES, Torosian JP, Slots J. Microbial differences in 2 clinically distinct Types of failures of osseointegrated implants. Clin Oral Implants Res 1991;2:135-44.
Tolman DE, Laney WR. Tissue-integrated prosthesis complications. Int J Oral Maxillofac Implants 2002;7:477-84.
Tonetti MS, Schmid J. Pathogenesis of implant failures. Periodontology 2000 1994;4:127-38.
Van Steenberghe D. A retrospective multicenter evaluation of the survival rate of osseointegrated fixtures supporting fixed partial prostheses in the treatment of partial edentulism. J Prosthet Dent 1989;61:217-23.
Watanabe F, Hata Y, Mataga I, Yoshie S. Retrieval and replacement of a malpositioned dental implant: A clinical report. J Prosthet Dent 2002;88:255-8.
Weyant RJ. Characteristics associated with the loss and peri-implant tissue health of endosseous dental implants. Int J Oral Maxillofac Implants 1994;9:95-102.
Weyant RJ, Burt BA. An assessment of survival rates and within-patient clustering of failures for endosseous oral implants. J Dent Res 1993;72:2-8.
Zarb GA, Schmitt A. The longitudinal clinical effectiveness of osseointegrated dental implants: The Toronto study. Part III: Problems and complications encountered. J Prosthet Dent 1990;64:185-94.

How to cite this article: Bonde PR and Ozturan S. Relation of Biological Factors with Failure of Osseointegration of Dental Implants. Int J Sci Stud 2020;8(2):23-27.

Source of Support: Nil, **Conflicts of Interest:** None declared.

Print ISSN: 2321-6379
Online ISSN: 2321-595X

Original Article

The Acidity of Non-alcoholic Beverages in Australia: Risk of Dental Erosion

Jeremiah Schmidt[1], Boyen Huang[2]

[1]BSc (Honours), BDSc, School of Dentistry and Health Science, Charles Sturt University, Orange, New South Wales, Australia, [2]PhD, MHA, DDS, School of Dentistry and Health Science, Charles Sturt University, Orange, New South Wales, Australia

Abstract

Introduction: Extrinsic acids play a key role in the etiology of dental erosion (DE), particularly acidic beverages. Of the factors considered, pH appears to be the most significant influencing a beverage's ability to cause DE. This study tested the pH and subsequent erosive potential of non-alcoholic beverages commercially available in Australia.

Purpose: Internationally, the consumption of non-alcoholic beverages is increasing. Regional differences in beverage availability and manufacturing processes may alter beverage pH. To date, little research outside of the United States has been conducted investigating the erosive potential of non-alcoholic beverages. This information should serve as a resource to professionals to facilitate dietary counseling and identify potentially acidic beverages that have not been previously identified in the literature.

Methods: A total of 177 commercially available non-alcoholic beverages were purchased from a supermarket in Orange, Australia, and their pH tested in triplicate at room temperature, using a temperature calibrated benchtop pH meter and probe. Beverages were classified by beverage type and subsequent erosive potential. The mean and median pH of beverage types was taken where appropriate.

Results: As high as, 93.8% of the beverages had a potential to cause DE. These included 34 (19.2%) extremely erosive (pH < 3), 114 (64.4%) erosive (3 ≤ pH < 4), and 18 (10.2%) minimally erosive beverages (4 ≤ pH ≤ 5.5). Only 11 beverages (6.2%) were unlikely to be erosive (pH > 5.5).

Conclusions: Of the beverages tested, most beverages (93.8%) had the potential to cause some degree of DE. The results provided could serve as a resource to health professionals to facilitate dietary counseling and healthy dietary decisions among consumers.

Key words: Acidic, Australia, Beverages, Erosive potential, pH, Tooth erosion

INTRODUCTION

The consumption of commercial beverages is increasing.[1] Australia saw a 14% decrease in the consumption of sugar-sweetened carbonated throughout Australia between 2009 and 2017, yet 37% increase in "diet" or "low sugar" beverages and 18% increase in the consumption of packaged water.[2] Aggressive marketing tactics by companies to highlight "zero sugar" beverages act to shift negative attention from the sugar-sweetened beverages they also sell. To date, little attention has been given to the role that non-sweetened beverages play on an individual's general and dental health.[3] One concern that remains is due to acid content of these beverages capable of causing dental erosion (DE).[4] DE is the irreversible loss of tooth structure due to acids, through a chemical dissolution process, without the involvement of microorganisms.[5] DE is caused by hydrogen ions from extrinsic and intrinsic acid sources contacting the tooth surface, resulting in the dissolution of the inorganic calcium hydroxyapatite.[6] Sources of intrinsic acids include stomach acids (due to gastroesophageal reflux disease and other purging behaviors related to pregnancy), alcoholism, and psychological disorders.[7] Sources of extrinsic acids include the previously mentioned commercially and non-commercially available beverages, foods (e.g., citrus fruits

Access this article online

www.ijss-sn.com

Month of Submission : 04-2020
Month of Peer Review : 05-2020
Month of Acceptance : 05-2020
Month of Publishing : 05-2020

Corresponding Author: Dr. Jeremiah Schmidt, A: 9 Darling Street, Tamworth, New South Wales 2340, Australia.

and vinegar), acidic drugs (e.g., aspirin and Vitamin C), acidic vapors in battery factories, and chlorinated swimming pool water.[4] The chemical dissolution process can be simplified to the following equation: $Ca_{10}(PO_4)_6OH_{2(s)}+H^+_{(aq)}\rightarrow Ca^{2+}_{(aq)}+H_3PO_{4(aq)}+OH^-_{(aq)}$.[8] The consequences of these acid exposures can be quite severe in terms of function, esthetics,[9] psychologically,[10] and holistically.[11] The prevalence of DE ranged from 20%[12] to 90%[13] in developed countries in recent years.

The capacity for acidic beverages to cause DE is termed erosive potential[14,15] and plays a key role in its etiology.[15] Factors shown to influence a beverage's erosive potential include pH,[16-21] titratable acidity,[17,21,22] buffering capacity,[5,23] calcium,[24,25] phosphate,[24] fluoride,[26] and casein phosphopeptide-amorphous calcium phosphate content.[27] Of these factors, the pH of beverages appears to be the most critical factor in determining its erosive potential (therefore, its ability to cause DE), with several studies identifying it as the only statistically significant factor.[18-21] It has also been shown that the dissolution of enamel increased inversely logarithmically with the pH of beverages [Figure 1].[16] Surprisingly, information relating to the beverages final pH is often not published by manufacturers nor is it available on the container of the beverage. The aim of this study was to address this gap in the literature and information available to consumers. It is hoped that by determining commercially available beverages erosive potential and making this information available will empower professionals and individuals to make healthy dietary choices.

METHODS

From a range of non-alcoholic, non-dairy beverages, a total of 177 were purchased from a supermarket in Orange, Australia. Beverage types purchased were soft drink, energy drink, juice, still and sparkling bottled water, flavored water, iced tea, coconut water, and *Aloe vera* water. A temperature calibrated benchtop pH meter and probe (Eutech pH 700, Thermo Scientific) was calibrated using CertiPUR buffer solutions (pH 10, 7, and 4 buffer solutions, CertiPUR®) and operated according to the manufacturer's instructions. The pH of different beverages was tested in triplicate at room temperature (22°C) immediately after opening. The mean pH, standard deviation, acids added, and manufacturer information from the products label were recorded. The mean pH of the beverage was used to determine the beverage's relative erosive potential based on the solubility of enamel at a given pH,[16] similar to the method of the previous studies.[28] Erosive potential was classified as extremely erosive (pH < 3), erosive (3 ≤ pH < 4), minimally erosive (4 ≤ pH ≤ 5.5), and unlikely to be erosive (pH > 5.5).[28]

RESULTS

Of the 177 beverages tested, Pepsi® original (pH = 2.56) was most acidic, while Alka Power water (pH = 10.29) was the most basic beverage in Australia. Individual beverage pH is summarized in Table 1. The results of the different beverage types are summarized in Table 2. The pH levels recorded for sports drinks and "other" beverages failed

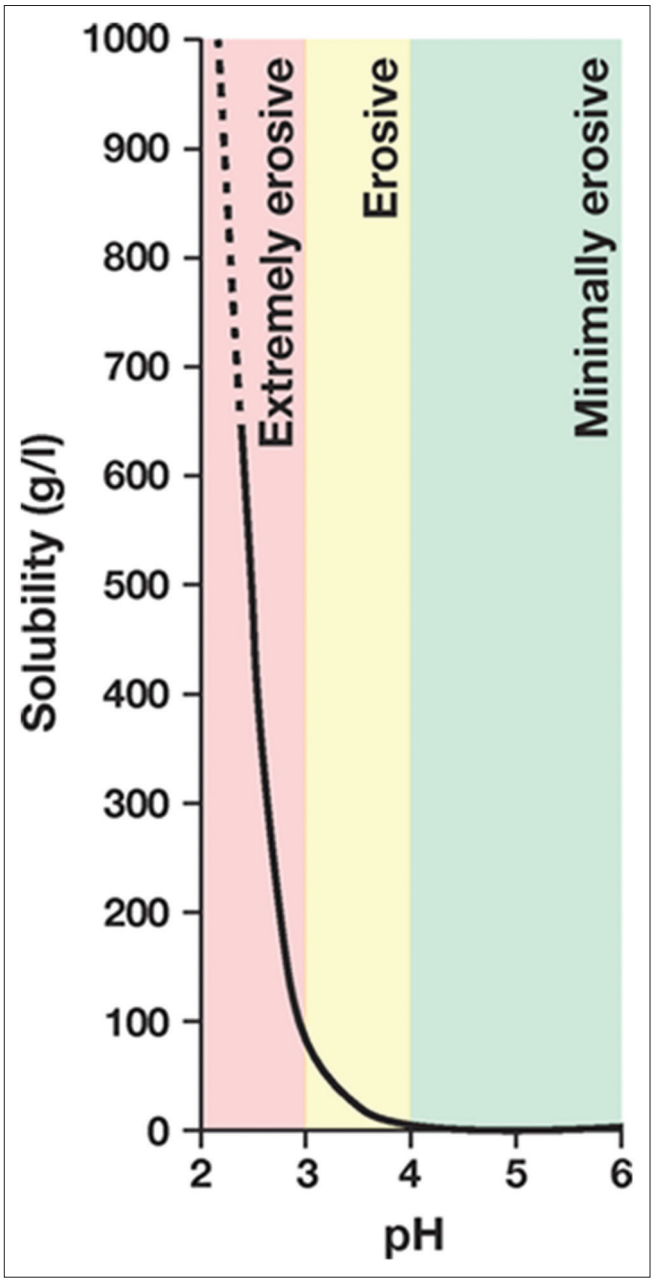

Figure 1: Solubility of enamel by pH and subsequent erosive potential28; Elsevier Reuse Licence Number: 4463380957145

Table 1: Beverage measured pH and subsequent erosive potential

Beverage type	Beverage name	x̄ pH (s)	Erosive potential
Soft drink	Pepsi® – original	2.56 (0.00)	Extremely erosive
Soft drink	Coca-Cola® – classic	2.61 (0.01)	Extremely erosive
Sparkling water	Schweppes® – raspberry sparkling	2.62 (0.00)	Extremely erosive
Sparkling water	Schweppes® – Indian tonic	2.63 (0.01)	Extremely erosive
Soft drink	Woolworths® – cola	2.64 (0.00)	Extremely erosive
Sparkling water	Woolworths® – tonic	2.68 (0.00)	Extremely erosive
Sports drink	Lucozade® – original	2.70 (0.01)	Extremely erosive
Juice	Ocean Spray® – cranberry classic	2.70 (0.01)	Extremely erosive
Soft drink	LA Ice® – cola	2.71 (0.01)	Extremely erosive
Juice	Ocean Spray® – light cranberry classic	2.71 (0.01)	Extremely erosive
Sparkling water	Woolworths® – diet tonic	2.71 (0.01)	Extremely erosive
Soft drink	Coca-Cola® – stevia	2.73 (0.01)	Extremely erosive
Energy drink	28 Black® – pink grapefruit and mint	2.73 (0.02)	Extremely erosive
Soft drink	Schweppes® – agrum blood orange	2.75 (0.00)	Extremely erosive
Energy drink	28 Black® – acai	2.75 (0.01)	Extremely erosive
Soft drink	Woolworths® – ginger beer	2.78 (0.01)	Extremely erosive
Soft drink	Coca-Cola® – vanilla	2.80 (0.01)	Extremely erosive
Juice	Golden Circle® – pine orange	2.84 (0.01)	Extremely erosive
Juice	Ocean Spray® – low sugar cranberry	2.87 (0.01)	Extremely erosive
Iced tea	Arizona® – lemon-flavored iced tea	2.88 (0.01)	Extremely erosive
Soft drink	Kirks® – lemonade	2.89 (0.01)	Extremely erosive
Soft drink	Pepsi® – max vanilla	2.89 (0.01)	Extremely erosive
Soft drink	Woolworths® – passion fruit	2.90 (0.01)	Extremely erosive
Energy drink	Bunderim® – ginger fresh	2.91 (0.01)	Extremely erosive
Iced tea	Arizona® – pomegranate iced green tea	2.93 (0.01)	Extremely Erosive
Soft drink	Kirks® – Pasito	2.94 (0.00)	Extremely erosive
Energy drink	Rockstar® – tropical guava (SF)	2.95 (0.00)	Extremely erosive
Energy drink	Rockstar® – tropical guava	2.95 (0.01)	Extremely erosive
Soft drink	Woolworths® – lemonade	2.96 (0.01)	Extremely erosive
Sparkling water	Schweppes® – lime sparkling (SF)	2.97 (0.01)	Extremely erosive
Soft drink	Sunkist® – original	2.98 (0.01)	Extremely erosive
Soft drink	Woolworths® – orange flavor	2.98 (0.01)	Extremely erosive
Soft drink	Bundaberg® – diet ginger beer	2.99 (0.00)	Extremely erosive
Soft drink	Pepsi® – lite (caffeine free)	2.99 (0.01)	Extremely erosive
Soft drink	Solo® – original	3.00 (0.01)	Erosive
Sports drink	Lucozade® – orange	3.01 (0.01)	Erosive
Soft drink	Crush® – orange flavor	3.03 (0.00)	Erosive
Juice	Golden Circle® – Golden Pash	3.03 (0.00)	Erosive
Flavored water	Schweppes® – lemon water	3.03 (0.00)	Erosive
Soft drink	LA Max® – ice (SF)	3.04 (0.01)	Erosive
Soft drink	Solo® – zero (SF)	3.05 (0.01)	Erosive
Soft drink	Kirks® – lemon squash	3.05 (0.01)	Erosive
Soft drink	Woolworths® – cola zero (SF)	3.06 (0.00)	Erosive
Soft drink	Lido® – lemonade	3.08 (0.00)	Erosive
Energy drink	Mother® – kicked apple	3.08(0.01)	Erosive
Soft drink	Kirks® – ginger beer	3.09 (0.01)	Erosive
Sparkling water	Waterfords® – lite and fruity sparkling lemon-lime-bitters	3.10 (0.00)	Erosive
Soft drink	Woolworths® – lemon	3.10 (0.01)	Erosive
Soft drink	Coca-Cola® – zero (SF)	3.12 (0.00)	Erosive
Energy drink	Red Bull® – zero (SF)	3.12 (0.01)	Erosive
Energy drink	Mother® (SF)	3.12(0.02)	Erosive
Soft drink	Schweppes® – sarsaparilla	3.13 (0.00)	Erosive
Soft drink	Schweppes® – agrum citrus blend (SF)	3.14 (0.01)	Erosive
Energy drink	Red Bull® – coconut and berry	3.15 (0.01)	Erosive
Energy drink	V® – blue	3.15 (0.01)	Erosive
Soft drink	Bundaberg® – ginger beer	3.16 (0.00)	Erosive
Juice	Golden Circle® – pine mango	3.16 (0.01)	Erosive
Iced tea	Lipton® – peach ice tea	3.16 (0.02)	Erosive
Soft drink	Diet Rite® – Portello	3.17 (0.00)	Erosive
Iced tea	Lipton® – ice green tea jasmine and lychee	3.17 (0.00)	Erosive
Iced tea	Lipton® – lemon ice tea	3.17 (0.01)	Erosive

(*Contd...*)

Table 1: (*Continued*)

Soft drink	Sprite® – zero (SF)	3.18 (0.01)	Erosive
Soft drink	Sprite® – original	3.19 (0.01)	Erosive
Sparkling water	Schweppes® – diet Indian tonic	3.19 (0.01)	Erosive
Soft drink	Schweppes® – raspberry	3.21 (0.00)	Erosive
Soft drink	Fanta® – raspberry	3.21 (0.00)	Erosive
Soft drink	Schweppes® – lemonade zero (SF)	3.21 (0.01)	Erosive
Sports drink	Gatorade® – blue bolt	3.21 (0.01)	Erosive
Flavored water	Gatorade® – active electrolyte lemon (SF)	3.21 (0.01)	Erosive
Soft drink	Coca-Cola® – diet	3.22 (0.01)	Erosive
Soft drink	Schweppes® – lemonade	3.22 (0.01)	Erosive
Energy drink	Mother® – passion	3.25 (0.01)	Erosive
Flavored water	Gatorade® – active electrolyte orange (SF)	3.25 (0.01)	Erosive
Iced tea	Arizona® – peach flavor ice tea	3.25 (0.01)	Erosive
Sports drink	Gatorade® – orange (SF)	3.25(0.01)	Erosive
Iced tea	Lipton® – ice green tea original	3.26 (0.00)	Erosive
Iced tea	Lipton® – raspberry ice tea	3.26 (0.00)	Erosive
Sports drink	Gatorade® – orange ice	3.26 (0.01)	Erosive
Sparkling water	Waterfords® – lite and fruity sparkling apple berry	3.26 (0.01)	Erosive
Soft drink	Mountain Dew® – energized	3.27 (0.00)	Erosive
Sports drink	Gatorade® – lemon-lime	3.27 (0.01)	Erosive
Soft drink	Schweppes® – dry ginger ale	3.28 (0.01)	Erosive
Soft drink	Woolworths® – dry ginger ale	3.28 (0.01)	Erosive
Soft drink	Coca-Cola® – diet caffeine free	3.29 (0.00)	Erosive
Soft drink	Woolworths® – creaming soda	3.29 (0.01)	Erosive
Iced tea	Arizona® – green tea with honey	3.29 (0.01)	Erosive
Sports drink	Gatorade® – pineapple	3.29 (0.02)	Erosive
Flavored water	Cool Ridge® – restore raspberry and blueberry flavor	3.30 (0.01)	Erosive
Soft drink	Ceda® – creaming soda	3.32 (0.00)	Erosive
Soft drink	Diet Rite® – ginger beer	3.33 (0.00)	Erosive
Sports drink	Gatorade® – tropical	3.33 (0.01)	Erosive
Juice	Golden Circle® – tropical punch	3.33 (0.01)	Erosive
Sports drink	Gatorade® – grape	3.35 (0.01)	Erosive
Energy drink	V® – original	3.36 (0.01)	Erosive
Soft drink	Kirks® – creaming soda	3.37 (0.01)	Erosive
Juice	Golden Circle® – sunshine punch	3.38 (0.01)	Erosive
Energy drink	V® (SF)	3.39 (0.01)	Erosive
Sparkling water	Waterfords® – lite and fruity sparkling Tahitian Lime	3.39 (0.01)	Erosive
Sports drink	Powerade® – mountain blast	3.39 (0.02)	Erosive
Sports drink	Powerade® – gold rush	3.40 (0.01)	Erosive
Juice	Golden Circle® – pine coconut	3.40 (0.01)	Erosive
Energy drink	Red Bull® (SF)	3.41 (0.00)	Erosive
Sports drink	Powerade® – lemon-lime	3.41 (0.00)	Erosive
Flavored water	Cool Ridge® – immunity blood orange and lemon flavor	3.41 (0.01)	Erosive
Energy drink	Monster® – 44	3.42 (0.01)	Erosive
Energy drink	Red Bull® – original	3.42 (0.01)	Erosive
Energy drink	Mother® – frosty berry	3.43 (0.01)	Erosive
Sports drink	Gatorade® – watermelon chill	3.43 (0.01)	Erosive
Flavored water	Cool Ridge® – revitalize green tea and peach	3.44 (0.00)	Erosive
Flavored water	Gatorade® – active berry water	3.44 (0.01)	Erosive
Sports drink	Powerade® – berry ice	3.45 (0.01)	Erosive
Sports drink	Powerade® – zero mountain blast (SF)	3.45 (0.01)	Erosive
Energy drink	Monster® – original	3.46 (0.01)	Erosive
Energy drink	Monster® – VR46	3.46 (0.01)	Erosive
Sports drink	Powerade® – zero berry ice (SF)	3.47 (0.01)	Erosive
Juice	Berri® – apple and blackcurrant	3.50 (0.01)	Erosive
Juice	Just Juice® – apple	3.53 (0.00)	Erosive
Soft drink	Kirks® – lemonade (SF)	3.53 (0.01)	Erosive
Juice	Berri® – apple, celery, coconut water, and lemon juice	3.53 (0.01)	Erosive
Soft drink	Schweppes® – diet dry ginger ale	3.56 (0.00)	Erosive
Energy drink	Monster® – zero ultra (SF)	3.57 (0.01)	Erosive
Sports drink	Maximus® – green	3.59 (0.01)	Erosive
Juice	Just Juice® – apple blackcurrant	3.59 (0.01)	Erosive
Sports drink	Maximus® – red	3.61 (0.01)	Erosive

(*Contd...*)

Table 1: (*Continued*)

Sports drink	Powerade® – pineapple storm	3.61 (0.01)	Erosive
Juice	Berri® – grape	3.61 (0.01)	Erosive
Sports drink	Maximus® – blue	3.62 (0.01)	Erosive
Sports drink	Maximus® – the big O	3.64 (0.00)	Erosive
Juice	Woolworths® – apple	3.69 (0.00)	Erosive
Juice	Berri® – apple, carrot, pear, and ginger	3.70 (0.01)	Erosive
Aloe vera drink	Ya-Coya Aloe Crush® – original	3.70 (0.01)	Erosive
Juice	Woolworths® – apple and blackcurrant	3.71 (0.01)	Erosive
Aloe-Vera drink	Ya-Coya Aloe Crush® –(SF)	3.74 (0.00)	Erosive
Juice	Golden Circle® – pineapple	3.75 (0.01)	Erosive
Juice	Berri® – apple and pear juice	3.75 (0.01)	Erosive
Juice	Berri® – apricot	3.76 (0.00)	Erosive
Juice	Berri® – Multi V Juice	3.76 (0.00)	Erosive
Juice	Berri® – apricot	3.76 (0.00)	Erosive
Juice	Berri® – Multi V Juice	3.76 (0.00)	Erosive
Sparkling water	Mount Franklin® – sparkling wild berry	3.76 (0.01)	Erosive
Soft drink	Kirks® – creaming soda (SF)	3.81 (0.01)	Erosive
Juice	V8® – breakfast fusion	3.83 (0.00)	Erosive
Juice	Berri® – apple, mango, and banana	3.88 (0.02)	Erosive
Juice	Woolworths® – orange juice	3.94 (0.01)	Erosive
Sparkling water	Mount Franklin® – sparkling raspberry and lemon	3.95 (0.01)	Erosive
Juice	V8® – tropical fusion	3.96 (0.01)	Erosive
Juice	Just Juice® – orange	3.98 (0.01)	Erosive
Juice	Berri® – orange juice	3.99 (0.00)	Erosive
Sparkling water	Mount Franklin® – lightly sparkling	4.00 (0.01)	Minimally erosive
Sparkling water	Mount Franklin® – lightly sparkling lime	4.03 (0.01)	Minimally erosive
Juice	Berri® – Tomato	4.06 (0.00)	Minimally erosive
Sparkling Water	Mount Franklin® – lightly sparkling lemon	4.12 (0.01)	Minimally erosive
Juice	V8® – vegetable juice	4.21 (0.00)	Minimally erosive
Sparkling water	Woolworths® – soda water	4.24 (0.01)	Minimally erosive
Bottled water	Pump®	4.28 (0.01)	Minimally erosive
Sparkling water	Icelandic® – glacial sparkling	4.33 (0.01)	Minimally erosive
Sparkling water	Woolworths® – lightly sparkling lemon (SF)	4.38 (0.01)	Minimally erosive
Bottled water	Mount Franklin®	4.38 (0.01)	Minimally erosive
Bottled water	Balance® – cleanse	4.39 (0.01)	Minimally erosive
Bottled water	Balance® – with flower essence	4.40 (0.01)	Minimally erosive
Sparkling water	Woolworths® – lightly sparkling	4.48 (0.01)	Minimally erosive
Sparkling water	Schweppes® – soda water	5.14 (0.01)	Minimally erosive
Bottled water	Cool Ridge®	5.17 (0.00)	Minimally erosive
Coconut water	Rawsome® – coconut water	5.27 (0.00)	Minimally erosive
Coconut water	Woolworths® – coconut water	5.31 (0.00)	Minimally erosive
Coconut water	H2COCO® – coconut water	5.48 (0.01)	Minimally erosive
Bottled water	Aroona® – water	5.56 (0.01)	Not erosive
Bottled water	Voss® – water	6.02 (0.02)	Not erosive
Bottled water	Frantelle® – water	6.28 (0.02)	Not erosive
Bottled water	Woolworths® – spring water	6.90 (0.01)	Not erosive
Bottled water	Thank You® – water	6.92 (0.02)	Not erosive
Bottled water	Fiji® – water	7.15 (0.01)	Not erosive
Bottled water	Evian® – water	7.41(0.02)	Not erosive
Bottled water	Acqua Panna® – Toscana water	8.13 (0.00)	Not erosive
Bottled water	Icelandic Glacial® – water	8.47 (0.02)	Not erosive
Bottled water	Aqua Love® – water	9.18 (0.01)	Not erosive
Bottled water	Alka Power® – water	10.29 (0.02)	Not erosive

normality testing; thus, the median pH was determined and reported in Table 2. For all other beverage types, the pH measurements were normally distributed; thus, the mean and standard deviation was calculated. Of the beverages tested, 166 (93.8%) beverages had the potential to cause some degree of DE. These included 34 (19.2%) extremely erosive (pH < 3), 114 (64.4%) erosive (3 ≤ pH < 4), and 18 (10.2%) minimally erosive beverages (4 ≤ pH ≤ 5.5). Only 11 beverages (6.2%) were unlikely to be erosive (pH > 5.5).

DISCUSSION

Understanding and identifying the factors contributing to the etiology of DE in patients are an essential step before delivering restorative treatment. Furthermore,

it has been well established that there is a significant relationship between low oral health literacy and poorer health outcomes.[29] It is alarming to note that until this study, the most comprehensive Australian study to date tested 39 commercially available beverages.[30] Our study looked at 177 Australian beverages categorized by type and their pH at room temperature (22°C). This was because studies have indicated that of all factors to be considered of beverages, pH is likely the most important in determining the beverage's erosive potential.[19,21] From the measured pH, the erosive potential of the beverages was determined using the established inverse logarithmic relationship by Larsen and Nyvad [Figure 1].[16] This is similar to the method used by the most comprehensive international study to date of 379 commercially available beverages in the United States.[28] This study was repeated in Australia as the pH measurements of beverages are not routinely published by manufacturing companies; therefore, this study and previously conducted studies provide a valuable resource to health professionals and, subsequently, the general population. While the pH and subsequent erosive potential of beverages have been investigated previously by numerous authors,[17-19,28,30] extrapolations of international data to Australian beverages have its limitations. This is due to regional variations in the fabrication process of beverages and beverage availability. Some examples of similarities and differences between this study and others are noted in Table 3. Variations in laboratory methodologies, including the temperature the beverage was tested at and equipment accuracy may also be attributed to minor variations in pH measurements among comparable beverages. This is because those beverages tested at higher temperatures are likely to have a lower pH reading.[31]

Table 2: Beverage type descriptive statistics

Beverage type	*n* (*n* = 177)	pH range	x̄ pH (s)	x̃ pH
Soft drink	51	2.56–3.81	3.07 (0.25)	
Iced tea	9	2.88–3.39	3.17 (0.17)	
Energy drink	21	2.73–3.57	3.20 (0.25)	
Flavored water	7	3.03–3.44	3.30 (0.15)	
Sports drinks	20	2.70–3.64		3.41
Juice	29	2.70–3.64	3.56 (0.41)	
Sparkling water	19	2.62–5.14	3.63 (0.74)	
Bottled water	16	4.28–10.29	6.56 (1.84)	
Other	6	5.27–5.53		5.29

The most common acids found in the beverages tested were carbonic, citric, ascorbic, phosphoric, and malic acid. Acidic beverage types included soft drinks, iced tea, energy drinks, flavored water, sports drinks, juice, and sparkling water. From this study, it was determined that 93.8% of commercially available, non-alcoholic beverages in Australia have the potential to cause DE. In contrast, the pH of gastric acid is 3.0,[32] of the tested beverages, 19.2% of beverages available are extremely erosion (pH < 3) and are, therefore, more acidic than human gastric juice. With the increase in consumption of these beverages, this highlights a potentially serious oral and general health risk. Given the decline in sales of sugar-sweetened beverages yet increase in sales of "zero sugar" alternatives,[1,2] attention should be given to the impact, these beverages have on individuals dental and holistic health beyond sugar content, particularly in terms of their erosive potential. In addition to the already acidic nature of these beverages, the consumption of sugar-sweetened acidic beverages

Table 3: Comparison of beverage pH measurements between published studies

Beverage	Study	Year	Location	°C	pH
Coca-Cola®	This study	2018	Australia	22	2.61
	Reddy *et al*.[28]	2016	United States	25	2.37
	Cochrane *et al*.[19]	2012	Australia	*	2.46
	Cochrane *et al*.[18]	2009	Australia	**	2.39
	Hara *et al*.[17]	2008	United States	23	2.45
	Seow and Thong[30]	2005	Australia	22	2.6
	Larsen and Nyvad[16]	1999	Denmark	**	2.4
Red Bull®	This study	2018	Australia	22	3.42
	Reddy *et al*.[28]	2016	United States	25	3.43
	Seow and Thong[30]	2005	Australia	22	3.1
Pepsi®	This study	2018	Australia	22	2.56
	Reddy *et al*.[28]	2016	United States	25	2.39
	Cochrane *et al*.[18]	2009	Australia	**	2.36
	Seow and Thong[30]	2005	Australia	22	2.3
	Larsen and Nyvad[16]	1999	Denmark	**	2.53
Schweppes Tonic Water®	This study	2018	Australia	22	2.63
	Reddy *et al*.[28]	2016	United States	25	2.54
	Larsen and Nyvad[16]	1999	Denmark	*	2.48
Mount Franklin Water®	This study	2018	Australia	22	4.38
	Cochrane *et al*.[18]	2012	Australia	*	7.56
	Cochrane *et al*[19]	2009	Australia	**	4.65

*Room temperature, **Not stated

has been found to be associated with the occurrence of laryngopharyngeal reflux.[33] This may result in a synergistic acid attack on the teeth prolonging their exposure. Unexpectedly, several types of bottled water measured were also acidic. This is of concern given the established 18% increase in consumption of bottled water.[2] While not being acidic enough to cause significant DE, their pH would be low enough to cause demineralization to tooth enamel.[7] This is likely due to the reverse osmosis filtration process that is carried out, increasing the water's uptake of CO_2 and subsequently leading to the waters acidification.[34] Some of the identified acidic bottled waters include Mount Franklin® Water, Balance Cleanse® Water, Pump® Water, and Cool Ridge® Water. Further research into the effects these bottled waters may have on dental health is indicated.

Using the method in this and previous studies is impractical, expensive and time consuming. Further consideration should be undertaken to establish inexpensive and predictable models of determining beverage's erosive potential. While pH may currently be the best predictor to determine erosive potential of beverages, there are several other factors influencing it.[6] These factors, coupled with the complex, multifactorial process of DE, play key roles in influencing an individual's susceptibility.[20] This data should serve as a reference for future investigations and an immediate resource to health practitioners and individuals to facilitate dietary counseling and healthy dietary decisions among consumers.

CONCLUSIONS

This study identified that a high percentage of non-alcoholic commercially available beverages in Australia has the potential to cause DE. Most non-alcoholic beverages, including some bottled water, have been found acidic. The risk of DE by the consumption of the tested beverages poses an oral and general health risk for the public. Further investigation is indicated.

ACKNOWLEDGMENTS

The study was supported with an Australian Dental Research Foundation Colin Cormie Grant. Thank you to Dr. Stephanie Momeni and her team for their guidance and supporting this research. In addition, the paper is indebted to Dr. Erica Yates for her guidance and input into this project.

REFERENCES

1. Global Industry Analysts Inc. Non-Alcoholic Beverages: A Global Outlook; 2012. Available from: https://www.bit.ly/2LDiJjH. [Last accessed on 2019 Nov 02].
2. Coca-Cola Amatil. Submission 84: Coca-Cola Amatil Submission to the Select Committee into the Obesity Epidemic in Australia; 2018. Available from: https://www.bit.ly/2qEAFTO. [Last accessed on 2019 Oct 10].
3. Demaio A, Jones A. The true price of sugar-sweetened disease: Political inertia requires renewed, strategic action. Med J Aust 2018;209:60-1.
4. Dawes C. What is the critical pH and why does a tooth dissolve in acid? J Can Dent Assoc 2003;69:722-4.
5. Cairns A, Watson M, Creanor S, Foye R. The pH and titratable acidity of a range of diluting drinks and their potential effect on dental erosion. J Dent 2002;30:313-7.
6. Shellis R, Featherstone J, Lussi A. Understanding the chemistry of dental erosion. In: Monographs in Oral Science. Basel: Karger Publishers; 2014. p. 163-79.
7. Kanzow P, Wegehaupt FJ, Attin T, Wiegand A. Etiology and pathogenesis of dental erosion. Quintessence Int 2016;47:275-8.
8. Bartlett D. Intrinsic causes of erosion. Monogr Oral Sci 2006;20:119-39.
9. Ganss C, Lussi A. Diagnosis of erosive tooth wear. In: Monographs in Oral Science. Basel: Karger; 2014. p. 22-31.
10. Ahmed K. The psychology of tooth wear. Spec Care Dent 2013;33:28-34.
11. Li X, Kolltveit KM, Tronstad L, Olsen I. Systemic diseases caused by oral infection. Clin Microbiol Rev 2000;13:547-58.
12. Marqués Martínez L, Leyda Menéndez AM, Ribelles Llop M, Segarra Ortells C, Aiuto R, Garcovich D. Dental erosion. Etiologic factors in a sample of Valencian children and adolescents. Cross-sectional study. Eur J Paediatr Dent 2019;20:189-93.
13. Vainionpää R, Tuulaniemi K, Pesonen P, Laitala ML, Anttonen V. Erosive tooth wear and use of psychoactive substances among Finnish prisoners. BMC Oral Health 2019;19:97.
14. Stefański T, Postek-Stefańska L. Possible ways of reducing dental erosive potential of acidic beverages. Aust Dent J 2014;59:280-8.
15. Marshall TA. Dietary assessment and counseling for dental erosion. J Am Dent Assoc 2018;149:148-52.
16. Larsen M, Nyvad B. Enamel erosion by some soft drinks and orange juices relative to their pH, buffering effect and contents of calcium phosphate. Caries Res 1999;33:81-7.
17. Hara AT, Carvalho JC, Zero DT. Causes of dental erosion: Extrinsic factors. In: Dental Erosion and Its Clinical Management. Berlin: Springer International Publishing; 2015. p. 69-96.
18. Cochrane N, Cai F, Yuan Y, Reynolds E. Erosive potential of beverages sold in Australian schools. Aust Dent J 2009;54:238-44.
19. Cochrane N, Yuan Y, Walker G, Shen P, Chang C, Reynolds C. Erosive potential of sports beverages. Aust Dent J 2012;57:359-64.
20. Lussi A, Jäggi T, Schärer S. The influence of different factors on *in vitro* enamel erosion. Caries Res 1993;27:387-93.
21. Jensdottir T, Holbrook P, Nauntofte B, Buchwald C, Bardow A. Immediate erosive potential of cola drinks and orange juices. J Dent Res 2006;85:226-30.
22. Rugg-Gunn AJ, Maguire A, Gordon PH, McCabe JF, Stephenson G. Comparison of erosion of dental enamel by four drinks using an intra-oral applicance. Caries Res 1998;32:337-43.
23. Edwards M, Creanor SL, Foye RH, Gilmour WH. Buffering capacities of soft drinks: The potential influence on dental erosion. J Oral Rehabil 2001;26:923-7.
24. Magalhães A, Moraes S, Rios D, Buzalaf M. Effect of ion supplementation of a commercial soft drink on tooth enamel erosion. Food Addit Contam Part A Chem Anal Control Expo Risk Assess 2009;26:152-6.
25. Mita H, Kitasako Y, Takagaki T, Sadr A, Tagami J. Development and evaluation of a low-erosive apple juice drink with phosphoryl-oligosaccharides of calcium. Dent Mater J 2013;32:212-8.
26. Mahoney E, Beattie J, Swain M, Kilpatrick N. Preliminary *in vitro* assessment of erosive potential using the ultra-micro-indentation system. Caries Res 2003;37:218-24.
27. Manton DJ, Cai F, Yuan Y, Walker GD, Cochrane NJ, Reynolds C, *et al*. Effect of casein phosphopeptide-amorphous calcium phosphate added to acidic beverages on enamel erosion *in vitro*. Aust Dent J 2010;55:275-9.
28. Reddy A, Norris DF, Momeni SS, Waldo B, Ruby JD. The pH of beverages in the United States. J Am Dent Assoc 2013;147:255-63.
29. Chesser AK, Woods NK, Smothers K, Rogers N. Health literacy and older adults: A systematic review. Gerontol Geriatr Med 2016;2:1-13.
30. Seow W, Thong K. Erosive effects of common beverages on extracted

premolar teeth. Aust Dent J 2005;50:173-8.
31. Wang X, Lussi A. Assessment and management of dental erosion. Dent Clin North Am 2010;54:565-78.
32. Hsu P, Chen C, Hsieh C, Chang W, Lai K, Lo G, *et al*. Alpha1-antitrypsin precursor in gastric juice is a novel biomarker for gastric cancer and ulcer. Clin Cancer Res 2007;13:876-83.
33. Lechien JR, Bobin F, Muls V, Horoi M, Thill M, Dequanter D, *et al*. Patients with acid, high-fat and low-protein diet have higher laryngopharyngeal reflux episodes at the impedance-pH monitoring. Eur Arch Otorhinolaryngol 2020;277:511-20.
34. Nir O, Bishop NF, Lahav O, Freger V. Modeling pH variation in reverse osmosis. Water Res 2015;87:328-35.

How to cite this article: Schmidt J, Huang B. The Acidity of Non-alcoholic Beverages in Australia: Risk of Dental Erosion. Int J Sci Stud 2020;8(2):28-35.

Source of Support: Nil, **Conflicts of Interest:** None declared.

Print ISSN: 2321-6379
Online ISSN: 2321-595X

Original Article

Clinical Assessment of Itraconazole in Dermatophytosis (CLEAR Study): A Retrospective Evaluation

Harshal Mahajan[1], Dhiraj Dhoot[2], Hanmant Barkate[3]

[1]Assistant Manager, Medical Services, Glenmark Pharmaceuticals Ltd., Mumbai, Maharashtra, India, [2]Senior Manager, Medical Services, Glenmark Pharmaceuticals Ltd., Mumbai, Maharashtra, India, [3]Vice President, Medical Services, Glenmark Pharmaceuticals Ltd., Mumbai, Maharashtra, India

Abstract

Introduction: The recent prevalence of dermatophytosis in India ranges from 36.6 to 78.4%. Itraconazole is commonly used systemic antifungal to treat dermatophytosis.

Objective: The objective of the present study was to evaluate the effectiveness and safety of itraconazole given 100 mg twice daily for the treatment of dermatophytosis.

Materials and Methods: The present retrospective questionnaire-based survey was done, wherein dermatologists and general physicians were given survey questionnaire. Data analysis up to 4 weeks of treatment with itraconazole was considered for this study. Efficacy evaluation was considered as percentage of patients achieving clinical cure.

Results: A total of 150 doctors completed the survey involving 1100 patients. Out of 1100 patients, 341 patients (31%) responded well to topical therapy alone and were considered as clinically cured as per medical records. In remaining patients who did not respond well to topical monotherapy, itraconazole was found to be added in 652 patients as 100 mg twice daily for 4 weeks. Of these, 456 patients (70%) responded well to therapy in 4 weeks and were considered as clinically cured. Among the topical antifungals coprescribed with itraconazole, luliconazole was most commonly prescribed (49%). On comparison of clinical cure rates in patients who received topical antifungal monotherapy (31%) and itraconazole cotherapy (70%), it was found that itraconazole cotherapy was better and the difference between the two therapies was statistically significant (P = 0.001).

Conclusion: From the findings of the present analysis, clinical cure rates obtained with itraconazole were more than satisfactory. Although the standard duration of therapy ranges from 1 to 2 weeks, long-term treatment is warranted and that is with topical antifungals and other supportive measures.

Key words: Clinical cure, Dermatophytosis, Efficacy, Itraconazole

INTRODUCTION

Superficial fungal infections are caused by dermatophytes, non-dermatophytic molds, and commensal yeasts.[1] According to published literature, the global prevalence rate of superficial mycotic infection has been found to be 20–25%.[2] The recent prevalence of dermatophytosis in India ranges from 36.6 to 78.4%.[3] Hot and humid climate in the tropical and subtropical countries like India makes dermatophytosis a very common superficial fungal infection.[1,4]

Although usually painless and superficial, these fungi can behave in an invasive manner, causing deeper and disseminated infection and should not be neglected.[5] The lesions may become widespread and may have significant negative social, psychological, and occupational health effects and can compromise the quality of life significantly.[6]

Various antifungal agents, both topical and systemic, have been introduced into clinical practice for effectively treating

Access this article online

www.ijss-sn.com

Month of Submission : 03-2020
Month of Peer Review : 04-2020
Month of Acceptance : 05-2020
Month of Publishing : 05-2020

Corresponding Author: Dr. Harshal Mahajan, Corporate Enclave, Medical Services, Glenmark Pharmaceuticals Ltd., Andheri (East), Mumbai, Maharashtra, India.

dermatophytic conditions. The commonly used drugs include azoles, allylamines, and griseofulvin.[7]

Itraconazole is orally administered triazole antifungal. It is commonly used systemic antifungal among the commercially available antifungal agents.[7] Itraconazole acts by inhibiting fungal 14-α-demethylase enzyme, which causes deficiency of ergosterol synthesis and accumulation of methyl precursors which ultimately leading to disruption of fungal cell membrane.[8] Efficacy of itraconazole against dermatophytic infections is very well proven.[9]

Intrinsic pharmacokinetic properties of itraconazole make its absorption erratic, with significant inter- and intra-individual differences in absorption and thus bioavailability, food and drug interactions, etc. Lately, quality of itraconazole has been topic of debate, which is considered to affect the bioavailability of the molecule.[10] Thus, it becomes imperative to test the clinical effectiveness and safety of itraconazole in dermatophytosis so that the technological advancement claims in manufacturing process actually translate into patient benefit, in the real-world experience.

To the best of our knowledge, the present study is first of its kind to analyze the effectiveness and safety of itraconazole in such a large number of patients with dermatophytosis.

MATERIALS AND METHODS

The present retrospective study was carried out at 150 centers across India using a pretested questionnaire. The questionnaire was designed to assess the effectiveness and safety of itraconazole 100 mg twice daily in the treatment of superficial fungal infections. The survey period was from July 2018 to July 2019. Patients with chronic dermatophytosis were not considered for this analysis. Dermatologists and general physicians involved in the management of superficial fungal infections with itraconazole 100 mg were identified through "SCRIP intelligence" database. Among these, 150 doctors who were maintaining the patients' clinical record were selected across four zones (East, South, West, and North) each by convenient sampling to have uniform representation of population across country.

Each doctor was given survey questionnaire booklet containing survey forms. These questionnaire booklets were collected after the end of survey period and data from all the patients were assessed to evaluate the effectiveness and safety of itraconazole 100 mg. Data analysis up to 4 weeks of treatment with itraconazole was considered for this study. Ethics committee approval was obtained before the start of the study.

Efficacy evaluation was considered as percentage of patients achieving clinical cure. All adverse events (AEs) were assessed for severity. Multiple occurrences of the same AE were only counted once for each patient. Statistical analysis was done for comparing cure rates of topical antifungal monotherapy and itraconazole-based combination antifungal therapy using Fisher's exact test. $P < 0.05$ was taken as statistically significant.

RESULTS

A total of 1100 survey forms were analyzed. Males (657) outnumbered females (443), with a male:female ratio of 1.48. On analyzing the age-wise distribution, it was found that all the age groups had almost equal number of patients, except in >60 years age group [Table 1].

On analyzing the diagnosis, it was found that tinea corporis was encountered in 33% of the patients followed by tinea cruris (29%) and tinea cruris et corporis (28%) [Figure 1].

Effectiveness Evaluation

Out of 1100 patients, 341 patients (31%) responded well to topical therapy alone and were considered as clinically cured as per medical records. In remaining patients who did not respond well to topical monotherapy, itraconazole was found to be added in 652 patients as 100 mg twice daily for 4 weeks. Of these, 456 patients (70%) responded well to therapy in 4 weeks and were considered as clinically cured. Among the topical antifungals coprescribed with itraconazole, luliconazole was most commonly prescribed (49%) [Table 2]. Evaluation of effectiveness parameters is mentioned in detail in Figure 2.

On analyzing clinical cure rates and demographic parameters in the patients, it was found that males and females had almost same clinical cure rates, while in age groups, clinical cure rates reduced with progression of age [Figure 3].

On comparison of clinical cure rates in patients who received topical antifungal monotherapy (31%) and itraconazole cotherapy (70%), it was found that

Table 1: Sex distribution in patients of the present study

Demographic parameter	*n* (%)
Sex	
Male	657 (60)
Female	443 (40)
Age (in years)	
21–40	401 (36)
41–60	388 (35)
>60	311 (29)

itraconazole cotherapy was better and the difference between the two therapies was statistically significant ($P = 0.001$) [Figure 4].

Safety Evaluation

Adverse effects were encountered in 71 patients (10.9%), of which gastrointestinal upset was most commonly encountered adverse effect, seen in 55 patients (8.4%) [Table 3].

DISCUSSION

Superficial dermatophytosis is no longer a simple, cutaneous fungal infection that is easily amenable to treatment. It has evolved into a chronic and recurrent, difficult-to-treat infection which affects the physical and the social well-being of the affected patients. Widespread resistance to conventional doses of antifungals with increasing clinical failure rates warrants the search for an effective first-line antifungal drug that brings about rapid clinical and mycological cure in dermatophytosis.[11]

Itraconazole is a triazole antifungal drug which is increasingly being used as a first-line drug for dermatophytosis, but it is being given for longer periods as compared to before.[12,13]

Table 2: Topical antifungal drugs prescribed monotherapy and in combination with itraconazole in the patients who were clinically cured

Molecule	Topical monotherapy (%)	Coprescribed with itraconazole (%)
Ciclopirox	43 (13)	78 (17)
Terbinafine	32 (9)	26 (6)
Luliconazole	120 (35)	221 (49)
Amorolfine	34 (10)	36 (8)
Sertaconazole	65 (19)	64 (13)
Eberconazole	47 (14)	31 (7)
Total	341	456

Table 3: Safety evaluation in patients of the present study who were prescribed with itraconazole

Category	Subcategory	*n* (%)
Adverse event	Gastrointestinal intolerance	55 (8.4%)
	Headache	11 (1.7%)
	Pedal edema	5 (0.8%)
	Total	71 (10.9%)
Patient adherence	Good	521 (80%)
	Average	72 (11%)
	Poor	59 (9%)

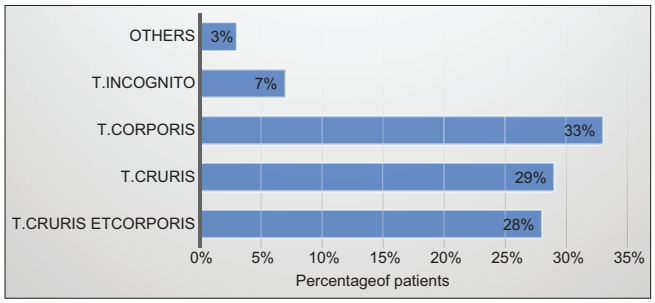

Figure 1: showing diagnosis in patients of the present study

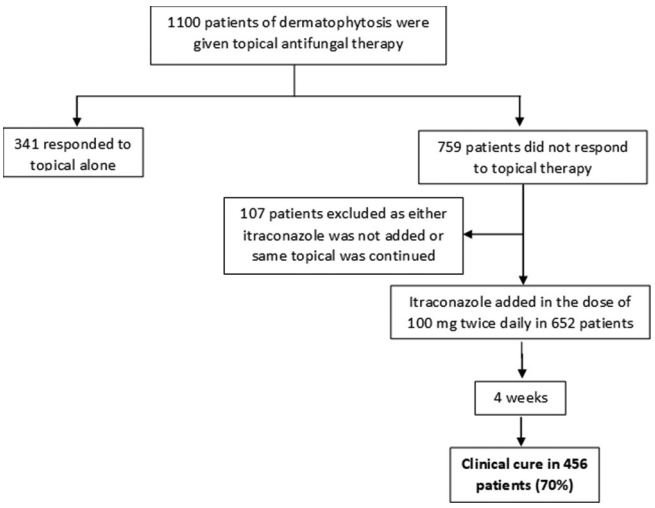

Figure 2: Effectiveness evaluation in patients of the present study

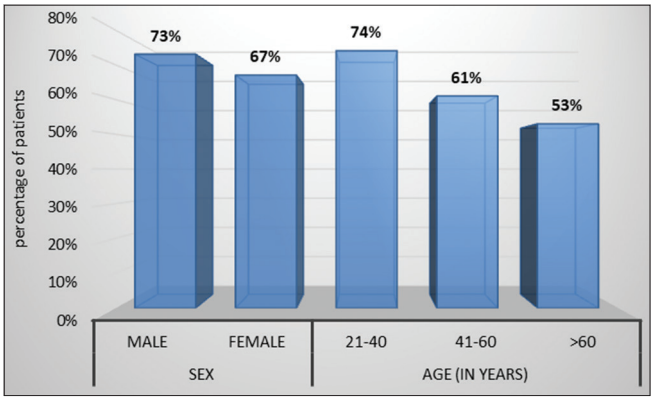

Figure 3: Age and sex wise distribution of clinical cure rates

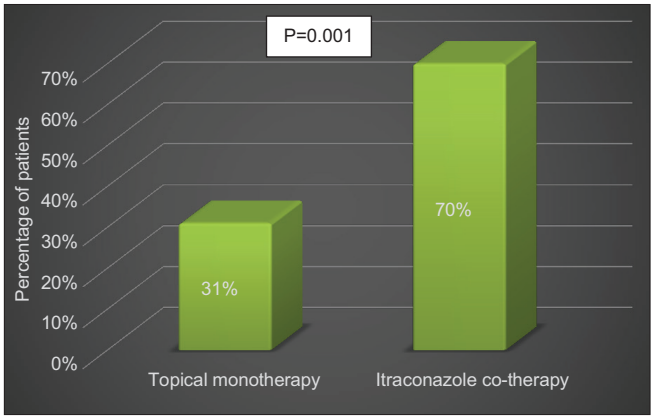

Figure 4: Comparison of clinical cure rates in patients who received topical monotherapy and itraconazole co-therapy

Conventional dose for itraconazole is 200 mg/day for 1–2 weeks, but in the current scenario in India, it is widely used beyond 4 weeks.

We conducted this survey to find out the effectiveness and safety of itraconazole in patients with dermatophytosis. In our analysis, it was found that itraconazole is being commonly used for all variants of dermatophytosis along with different drugs as combination. In recently published article by Ardeshna *et al.*, recalcitrant recurrent dermatophyte infections were successfully treated by a combination of itraconazole and isotretinoin.[12] In addition, role of anti-histamines, salicylic acid, and moisturizers has been suggested in consensus statement by Rajagopalan *et al.*[3]

The results of our analysis suggest that itraconazole achieves clinical cure in much shorter duration. In our analysis, 70% of the patients achieved clinical cure within 4 weeks of itraconazole-based combination therapy. This is similar to an earlier analysis in patients of dermatophytosis who also found itraconazole to have higher cure rates.[14]

Recently published literature cites the rise of trichophyton mentagrophytes, as the most common cause of dermatophytosis in India.[15] It is characterized by significant inflammatory lesions and is intrinsically less sensitive to conventional antifungal agents.[15] Among the commercially available systemic antifungal drugs, itraconazole is the commonly prescribed drug for the treatment of dermatophytosis.[7] One of the reasons for such upper hand of itraconazole in the class of systemic antifungals might be attributed to the fact that it has found to have better MIC values, as compared to other systemic antifungal agents, in a clinical analysis.[16]

Itraconazole can cause gastric upset, headache, taste alteration, and jaundice, and rarely, it can cause hypokalemia, torsade de pointes, and heart failure.[13] However, in our analysis, side effects such as gastrointestinal upset, headache, and pedal edema were seen.

Most of the dosage forms of systemic antifungal drugs mentioned in dermatology textbooks, however, have been found to be non-effective in the therapy of the dermatophytosis in India. Duration of treatment mentioned in the Western literature is not applicable to treat dermatophytosis in a tropical country like India.[15] Even in our analysis, only 70% of the patients achieved clinical cure within 4 weeks although all patients were prescribed topical antifungal.

In the current scenario, combination therapy is the need of hour in the management of dermatophytosis. Topical antifungal drugs are preferred with systemic since they provide high concentration of the drug at the site of action. Different classes of topical and systemic AFAs may be combined. Although eberconazole and sertaconazole have the advantage of anti-inflammatory activity,[5,17] in our analysis, luliconazole was the most commonly used topical antifungal.

It is a general convention that two drugs can be synergistic when they act through different mechanisms of actions to produce enhanced common end effect.[18] Still, some researchers believe that drug delivery of both the drugs to their site of action is more important than mechanism of action to achieve the synergistic effect.[19] Systemic along with topical therapy will ensure their optimal concentration in the stratum corneum along with deeper layers of skin for effective antifungal action. These can be the attributable factor for enhanced cure rates observed in the present study with itraconazole and concomitant luliconazole therapy.

This has been corroborated by the findings of the present study, i.e., satisfactory clinical cure rates obtained in patients with concomitant topical luliconazole therapy. It has also been cited in the literature that combination therapy of systemic and topical antifungal drugs should be used in the treatment of recalcitrant dermatophytosis.[20]

This analysis has certain limitations. Due to the retrospective design, the possibility of selection bias cannot be ruled out. Treatment with other antifungals such as topical agents, anti-histamines, and other drugs may have impacted the final outcome. Long-term combination and comparative studies to address the shortcomings of the present analysis are warranted.

CONCLUSION

From the findings of the present analysis, clinical cure rates obtained with itraconazole were more than satisfactory. Although the standard duration of therapy ranges from 1 to 2 weeks, long-term treatment is warranted and that is with topical antifungals and other supportive measures. Consequently, with regard to the treatment of dermatophytosis, counseling is indeed the cornerstone of therapy. Systemic treatment provided in a systematic manner, based on the clinical response seen in patients, will definitely yield a good therapeutic outcome. Furthermore, the duration of treatment needs to be individualized, with complete cure considered as the end point.

REFERENCES

1. Gupta C, Tripathi K, Tiwari S, Rathore Y, Nema S, Dhanvijay AG. Current trends of clinicomycological profile of dermatophytosis in Central India.

IOSR J Dent Med Sci 2014;13:23-6.
2. Havlickova B, Czaika V, Friedrich M. Epidemiological trends in skin mycoses worldwide. Mycoses 2008;52:2-15.
3. Rajagopalan M, Inamadar A, Mittal A, Miskeen AK, Srinivas CR, Sardana K, *et al*. Expert consensus on the management of dermatophytosis in India (ECTODERM India). BMC Dermatol 2018;18:6.
4. Falahati M, Akhlaghi L, Lari AR, Alaghehbandan R. Epidemiology of dermatophytoses in an area South of Tehran, Iran. Mycopathologia 2003;156:279-87.
5. Bristow I, Spruce M. Fungal foot infection, cellulitis and diabetes: A review. Diabet Med 2009;26:548-51.
6. Jerajani H, Janaki C, Kumar S, Phiske M. Comparative assessment of the efficacy and safety of sertaconazole (2%) cream versus terbinafine cream (1%) versus luliconazole (1%) cream in patients with dermatophytoses: A pilot study. Indian J Dermatol 2013;58:34-8.
7. Sahoo A, Mahajan R. Management of tinea corporis, tinea cruris, and tinea pedis: A comprehensive review. Indian Dermatol Online J 2016;7:77-86.
8. Lestner J, Hope W. Itraconazole: An update on pharmacology and clinical use for treatment of invasive and allergic fungal infections. Expert Opin Drug Metab Toxicol 2013;9:911-26.
9. Bhatia A, Kanish B, Badyal DK, Kate P, Choudhary S. Efficacy of oral terbinafine versus itraconazole in treatment of dermatophytic infection of skin-a prospective, randomized comparative study. Indian J Pharmacol 2019;51:116-9.
10. Sardana K, Khurana A, Singh A, Gautam RK. A pilot analysis of morphometric assessment of itraconazole brands using dermoscopy and its relevance in the current scenario. Indian Dermatol Online J 2018;9:426-31.
11. Rengaswamy M, Chellam J, Ganapati S. Systemic therapy of dermatophytosis: Practical and systematic approach. Clin Dermatol Rev 2017;1:S19-23.
12. Ardeshna K, Rohatgi S, Jerajani H. Successful treatment of recurrent dermatophytosis with isotretinoin and itraconazole. Indian J Dermatol Venereol Leprol 2016;82:579-82.
13. Donckar P, Pande S, Richarz U, Garodia N. Itraconazole: What clinicians should know? Indian J Drugs Dermatol 2017;3:4-10.
14. Shakya N, Jha M, Dangol A, Shakya S, Shah A. Efficacy of itraconazole versus terbinafine for the treatment of tinea cruris. Med J Shree Birendra Hosp 2012;11:24-6.
15. Verma S, Madhu R. The great Indian epidemic of superficial dermatophytosis: An appraisal. Indian J Dermatol 2017;62:227-36.
16. Dabas Y, Xess I, Singh G, Pandey M, Meena S. Molecular identification and antifungal susceptibility patterns of clinical dermatophytes following CLSI and EUCAST guidelines. J Fungi (Basel) 2017;3:17.
17. Moodahadu-Bangera LS, Martis J, Mittal R, Krishnankutty B, Kumar N, Bellary S, *et al*. Eberconazole--pharmacological and clinical review. Indian J Dermatol Venereol Leprol 2012;78:217-22.
18. Tallarida R. Drug synergism: Its detection and applications. J Pharmacol Exp Ther 2001;298:865-72.
19. Vakil V, Trappe W. Drug combinations: Mathematical modeling and networking methods. Pharmaceutics 2019;11:208.
20. Hay R. Therapy of skin, hair and nail fungal infections. J Fungi (Basel) 2018;4:99.

How to cite this article: Mahajan H, Dhoot D, Barkate H. Clinical Assessment of Itraconazole in Dermatophytosis (CLEAR Study): A Retrospective Evaluation. Int J Sci Stud 2020;8(2):36-40.

Source of Support: Nil, **Conflicts of Interest:** None declared.

Print ISSN: 2321-6379
Online ISSN: 2321-595X

Original Article

Clinicopathological Correlation of Sinonasal Masses with Pre-operative Computed Tomography Findings

S Namrata[1], Santhi T[2]

[1]Postgraduate Student, Department of Otorhinolaryngology, Government T D Medical College, Alappuzha, Kerala, India, [2]Additional Professor (ENT), Department of Otorhinolaryngology, Government T D Medical College, Alappuzha, Kerala, India

Abstract

Aim of the Study: The aim of the study was to study the clinical, radiological, and histopathological correlation of sinonasal masses.

Materials and Methods: This was a descriptive study conducted on 72 patients with sinonasal masses at Government T D Medical College, Alappuzha, over a period of 18 months from January 01, 2014, to June 30, 2015.

Results: Age group was from 13 to 85 years with a male to female ratio of 1.3:1. Nasal obstruction was the most common symptom followed by nasal discharge and headache. Of the 72 cases, 59 belonged to the non-neoplastic group and 13 to the neoplastic group of sinonasal masses. Clinically, nasal polyp was the most common presentation. Sinonasal polyps (65.3%) formed the majority of the non-neoplastic lesions, vascular lesion (6.9%) was the most common benign neoplastic mass, and malignancy was seen in 6.9% of cases. After clinical examination and computed tomography scan of the nose and paranasal sinuses, patients underwent surgery. Finally, clinical, radiological, and histopathology correlation of all the sinonasal masses were done. The clinical diagnosis with computed tomography (CT) scan correlation was the same except in three cases and in one case with histopathology. Histopathology and CT scan result correlated well except in three cases. It was found that there was a significant association between the clinical, radiological, and histopathological diagnoses ($P < 0.05$) and that these modalities were complementary to each other. It was also possible to classify the lesions as non-neoplastic, neoplastic benign, and malignant using these modalities. This was important because even though initial presentation of these masses was similar, management of each of them varied significantly.

Conclusion: Histopathology still remains the gold standard in the diagnosis of sinonasal masses, while CT scan is indispensable in studying the anatomical variants and providing the route map before and during endoscopic sinus surgeries.

Key words: Clinical presentation, Histopathology, Nasal endoscopy, Radiology, Sinonasal mass

INTRODUCTION

Sinonasal diseases are one of the most commonly diagnosed diseases in India. The majority of patients presenting with rhinosinusitis and sinonasal masses belong to poor socioeconomic status. These sinonasal masses may be congenital or acquired. The acquired can either be non-neoplastic or neoplastic, but it is quite impossible to differentiate them clinically and are often diagnosed as a nasal polyp.[1] Polyp is defined as pedunculated prolapsed mucosa and is used to describe any mass that projects from the normal surface.[2] Sinonasal masses can originate from the epithelial mucosa, mucous gland, bony structures, minor salivary glands, neural tissue, and lymphatics.[3]

Diagnostic nasal endoscopy (DNE) is very useful in understanding the nasal pathology such as the type of mass, discharge, synechiae, bleeding point if any, structures on the lateral nasal wall, septum, and the various anatomic variations.[4] Patients with significant pathology can be planned for surgery. Computed tomography (CT) scan should be performed to know the anatomy and extent

Access this article online

www.ijss-sn.com

Month of Submission : 03-2020
Month of Peer Review : 04-2020
Month of Acceptance : 05-2020
Month of Publishing : 05-2020

Corresponding Author: Dr. Santhi T, Department of Otorhinolaryngology, Government T D Medical College, Vandanam, Alappuzha - 688 005, Kerala, India

of the disease. It is now the most commonly used imaging modality for various indications in head and neck pathologies. CT scan can delineate with contrast soft tissue pathologies and is now the first choice in diagnosing malignancy and inflammatory lesions.[5,6]

CT scan with fine coronal sections at the level of osteomeatal complex (OMC) is an excellent technique in assessing bony detail, extent of the disease, anatomical variations, and hyperdensities.[7] CT scan can also reveal mucosal thickening and secretions in the sinuses, but the mucosal thickening cannot be interpreted specifically for sinusitis.[8] Hence, at least 4–6 weeks of aggressive medical therapy should be given prior to CT so that extent of the disease can be delineated amidst irreversible mucosal or bony changes. Again, one has to keep in mind that around 40% of the asymptomatic population has mucosal changes in the CT.[9]

The primary objective of endoscopic sinus surgery is to restore the function of the paranasal sinuses (PNS) by reestablishing aeration and proper mucociliary clearance patterns.[10] A pre-operative CT imaging can provide an accurate route to perform endoscopic sinus surgery. A coronal view of the CT can give an excellent correlation with the findings during sinus surgery.[8] For patients being considered for endoscopic sinus surgery, the CT should be carefully interpreted before beginning surgery and should be available for review during the case. All CT scans of PNS should be carefully examined for the extent of disease, and any findings should be clinically correlated. The presence of agger nasi cells, frontal cells, infraorbital cells, and the attachment of the uncinate process is all important to identify and will help in safely opening each sinus.[11]

Despite the widespread use of CT, its true accuracy in diagnosing sinus diseases is still not clear. If CT findings are not interpreted in the light of the symptoms, many people who have incidental changes will be labeled as having sinus disease and will inadvertently undergo unnecessary surgery.[12]

The combination of DNE with a conventional CT scan has proven to be the ideal method for the examination of inflammatory disease of the PNS. In so doing, diseases and lesions that otherwise might have gone undiagnosed can be identified and consequently treated.[13]

Even so, histopathology of the surgical specimen is necessary as neoplasms of the sinuses and nasal cavity account for 0.2–0.8% of all carcinomas.[14]

This is a study to correlate the clinicopathological features of the sinonasal masses with the pre-operative CT scans which are necessary for an accurate diagnosis and proper management of the condition.

MATERIALS AND METHODS

The Main Objectives of the Study

The objectives of the study were as follows:

1. To assess the clinicopathological correlation of sinonasal masses with pre-operative computed tomography findings in patients who had undergone surgery for the nasal masses
2. To assess the role of CT in diagnosing various sinonasal pathologies
3. To assess the importance of clinical correlation in the surgical management of chronic sinus disease.

Study Design

This study was prospective study.

Study Setting and Duration

The study was conducted at Government T D Medical College, Alappuzha, Kerala, in the ENT department for a period of 18 months from January 01, 2014, to June 30, 2015.

Inclusion Criteria

The following criteria were included in the study.

1. All patients above 12 years of age with clinically diagnosed sinonasal masses and willing to do a CT scan of the nose and PNS
2. Sex-both males and females were included in the study.

Exclusion Criteria

The following criteria were excluded from the study.

1. Patients below 12 years to avoid radiation exposure during CT scan and above 85 years due to associated comorbidities where CT scan with contrast is contraindicated
2. Patients with congenital nasal masses
3. Patients with lesions arising from the nasopharynx
4. Patients who have been previously operated for sinonasal masses.

Method of Data Collection

- Informed consent was taken
- Biodata of the patient was collected
- Patients were clinically evaluated with a detailed history and complete physical examination
- DNE was performed
- Patients with sinonasal masses were planned for surgery and sent for a pre-operative CT scan. Coronal and axial cuts of CT scan of nose and PNS with contrast were studied
- Operative findings were recorded systematically

- Confirmation of the findings was done by histopathological examination
- All details were recorded in the pro forma.

Study Variables

- Age
- Sex
- Duration
- Laterality – unilateral or bilateral
- Clinical diagnosis – symptomatology of sinonasal pathology – (a) nasal obstruction, (b) rhinorrhea, (c) epistaxis, (d) hyposmia, (e) mouth breathing, (f) eye symptoms, (g) facial swelling, and (h) headache
- DNE
- CT diagnosis – findings of CT scan of nose and PNS, axial, and coronal cuts such as (a) nature and extent of the lesion, (b) involvement of the OMC, (c) involvement of the PNS, (d) mucosal thickening, (e) bone erosion/destruction/expansion, (g) anatomical variants such as concha bullosa, paradoxical middle turbinate, Haller cell, Onodi cell, and deviated nasal septum, and (h) level of the cribriform plate
- Histopathology diagnosis.

Study Procedure

Both the Institutional Research Committee and the Institutional Ethics Committee approved the study.

Patients above 12 years with clinically diagnosed sinonasal masses who attended the outpatient department of ENT, T D Medical College Alleppey, over a period of 18 months (from January 01, 2014, to June 30, 2015) were considered for the study. Thus, a total of 72 patients with sinonasal masses were enrolled for this study.

The aims, objectives, benefits of the study, need for the surgery, and its possible complications were explained to the patients. A valid written informed consent was taken. Nasal endoscopy was done. All patients before nasal endoscopy underwent bilateral nasal packing with 4% lignocaine and decongestant for 10 min and then nasal endoscopy was done using a 0-degree adult nasal endoscope. CT scans with the contrast of the nose and PNS were taken in both axial and coronal sections.

A provisional diagnosis was made after correlating clinical assessment with radiological investigations. The operative methods included polypectomy, endoscopic sinus surgery, or maxillectomy. Histopathology of the surgical specimens using hematoxylin and eosin stain was carried out in all the 72 cases. PAS and GMS stain were done in suspected cases of fungal sinusitis and certain medical conditions. In very few cases, immunohistochemistry was performed to confirm the diagnosis. Clinical and radiological findings were compared with the histopathological findings and the results were analyzed.

Statistical Analysis

Data obtained were entered in an open office spreadsheet and analyzed with SPSS 16.0. Percentages and proportions were used for qualitative variables. Association between the main study variables was found using *P*-value ($P < 0.05$-significant). Mean and standard deviation was used for quantitative variables.

Ethical Considerations

Permission to conduct the study was obtained from the Institutional Ethics Committee and Institutional Research Committee of T D Medical College, Alappuzha. The study was commenced only after getting clearance from the Human Institutional Ethics Committee.

RESULTS

In the present study, the age distribution of the patients ranged from 13 to 85 years (mean age 42.75). The 4th and 5th decade was the most common to be involved with 37 patients (51.4%), as shown in Table 1.

The male to female ratio was 1.3:1 [Table 2].

Thirty patients (41.6%) presented to the hospital within duration of 1 year of onset of symptoms, among whom seven patients (9.7%) presented within 3 months. Forty-two patients (58.3%) had symptom duration of more than 1 year [Figure 1].

The most common presenting symptom was nasal obstruction seen in 59 patients (81.9%) followed by nasal discharge in 44 patients (61.1%) and headache in 42 patients (58.3%). The other symptoms were hyposmia (48.6%), epistaxis (37.5%), facial swelling (19.4%), eye involvement (13.9%), and mouth breathing (12.5%). Eye symptoms were seen in ten patients (13.9%). They were proptosis,

Table 1: Demographic profile of the study population

Age group	Frequency	Percent
13–25	12	16.7
26–40	16	22.2
41–60	37	51.4
61–85	7	9.7

Table 2: Sex distribution of the study population

Sex	Frequency	Percent
Male	41	56.9
Female	31	43.1

periorbital edema, and restriction of eyeball movements or reduced vision. The frequency of symptoms is shown in Table 3.

On clinical examination out of the 72 sinonasal masses, 59 were non-neoplastic and 13 were neoplastic. The majority of the patients with non-neoplastic lesions had bilateral masses (66.7%). Twenty-four of 72 patients (33.3%) presented with unilateral nasal masses. Forty-eight patients had bilateral nasal masses, among whom 46 (80.7%) had non-neoplastic and two (13.3%) had neoplastic masses. Among the unilateral masses, 11 were of neoplastic type (84.6%) and 13 were of non-neoplastic type (22%). The frequency of the patients with unilateral and bilateral masses is given in Table 4.

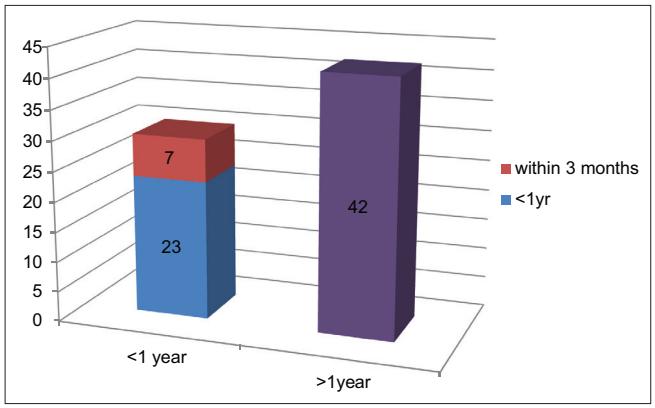

Figure 1: Duration of symptoms

Table 3: Frequency of symptoms

Symptoms	Number of patients	Percentage
Nasal obstruction	59	81.9
Nasal discharge	44	61.1
Headache	42	58.3
Hyposmia	35	48.6
Epistaxis	27	37.5
Facial swelling	14	19.4
Eye involvement	10	13.9
Mouth breathing	9	12.5

Table 4: Relationship between laterality and type of sinonasal mass

Laterality with number of patients	Type of sinonasal mass		Total
	Neoplastic	Non-neoplastic	
Laterality			
Unilateral			
Count	11	13	24
Percentage	84.6	22	33.3
Bilateral			
Count	2	46	48
Percentage	15.4	77.7	66.7
Total			
Count	13	59	72
Total percentage	100.0	100.0	100.0

On endoscopic examination, the nasal masses appeared as polypoidal, fleshy, granular or ulceroproliferative. Some also created a bulge in the lateral nasal wall.

Clinically sinonasal polyposis was the most common diagnosis in 47 patients (65.3%). The other clinical diagnoses were fungal sinusitis in ten patients (13.9%), malignancy, and vascular lesions in five patients each (6.9% each). Inverted papilloma was diagnosed in three patients (4.2%) and frontoethmoid mucocele in two patients (2.8%), as shown in Table 5.

Of the 72 patients, 59 patients (82%) were clinically diagnosed as non-neoplastic and 13 patients (18%) were diagnosed with a neoplastic lesion, among whom eight (11.1%) were benign and five (6.9%) were malignant [Table 6].

In the non-neoplastic group, the maximum number of patients with sinonasal polyps comprised 47 patients (65.3%). In the neoplastic malignant group, growth in the nasal cavity had a maximum number of patients comprising of five patients (6.9%), whereas in benign group maximum number of patients with inverted papilloma (4.2%) were seen in three patients [Figure 2].

CT scan was done in all the 72 patients. Mucosal thickening was the most common finding in the CT scan (83.3%), followed by deviated nasal symptom (80.6%), OMC disease (72.2%), and frontoethmoidal disease (61.6%). Bone erosion (25%) was found in neoplastic malignant diseases and in fungal diseases. Anatomical variations such as concha bullosa (26.4%) and paradoxical middle turbinate (20.8%) were also noted [Figure 3].

According to CT scan, 49 patients (68.1%) had sinonasal polyps, eight patients (11.1%) had malignancy, fungal

Table 5: Clinical diagnosis of sinonasal masses with percentage of frequency

Clinical diagnosis	Frequency	Percentage
SNP	47	65.3
Malignancy	5	6.9
Fungal sinusitis	10	13.9
Mucocele	2	2.8
Vascular lesions	5	6.9
IP	3	4.2

Table 6: Neoplastic and non-neoplastic lesions – clinical diagnosis

Clinical diagnosis	Frequency	Percent
Neoplastic benign	8	11.1
Neoplastic malignant	5	6.9
Total	13	18

disease in seven patients (9.7%), vascular lesion in four patients (5.6%), and mucocele and inverted papilloma in two patients (2.8%) each [Table 7].

Clinical diagnosis correlated with the radiological diagnosis in all except in three patients [Table 8] and *P*-value was found to be <0.001, which means there is a significant association between the clinical and radiological examination.

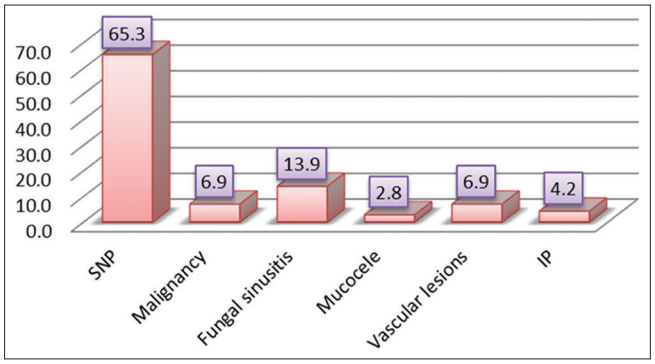

Figure 2: Clinical diagnosis of sinonasal masses

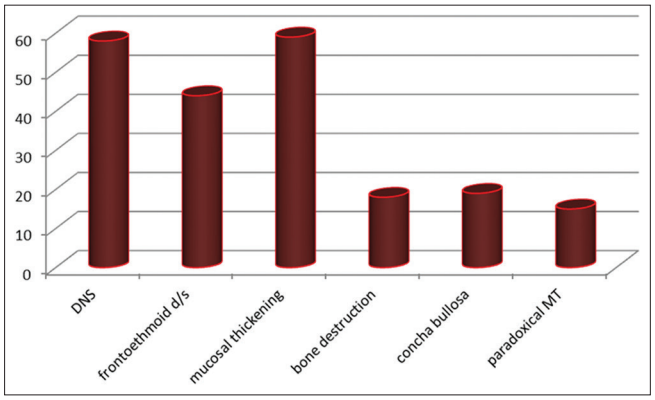

Figure 3: Common findings in radiology

Table 7: CT diagnosis of the sinonasal masses

CT diagnosis	Frequency	Percent
SNP	49	68.1
Malignancy	8	11.1
Fungal sinusitis	7	9.7
Mucocele	2	2.8
Vascular lesions	4	5.6
IP	2	2.8

The surgical methods employed in the study were endoscopic polypectomy (33.3%), endoscopic sinus surgery (62.5%), and maxillectomy (4.2%).

Histopathology was carried out in all the 72 patients and reported in Table 9.

Histopathology examination revealed that 43.1% (31 cases) of the polyps to be inflammatory, while 22.2% (16 cases) were allergic in nature making a total of 47 cases of sinonasal polyps. Other non-neoplastic lesions were eight cases of aspergillosis (11.1%), three cases of mucormycosis (4.2%), and two cases of mucocele (2.8%). Among the benign neoplastic lesions, hemangiomatous lesions (five cases) were the most common followed by inverted papilloma (three cases). Squamous cell carcinoma (SCC) represented 4.2% of all sinonasal neoplastic lesions (three cases). A rare case of angiosarcoma was diagnosed in one patient by histopathology alone.

In the present study, the histopathology report changed the clinical diagnosis in one patient (1.38%) and in 71 patients (98.6%), clinical and histopathology diagnosis was the same [Table 10] showing a significant association between clinical diagnosis and histopathology report with $P < 0.001$.

Eight patients (11.1%) had clinically benign lesions and five patients (6.9%) had clinically malignant lesions. In one patient, who was clinically diagnosed as non-neoplastic lesion, the histopathology report came as angiosarcoma.

In this study, the histopathology report varied from the CT diagnosis of three patients (4.16%). Eight patients had malignant lesion according to radiology, of which two were non-neoplastic (fungal disease) and two were inverted papilloma (neoplastic benign) according to the histopathology reports [Table 11]. $P < 0.001$ indicating that there was a significant correlation between CT diagnosis and histopathology.

In the present study, it was finally concluded that out of 72 patients, 60 patients (83.4%) had non-neoplastic and 12 patients (16.7%) had neoplastic sinonasal masses, of which eight patients (11.1%%) had benign and four patients (5.6%) had malignant pathology.

Table 8: Correlation between clinical diagnosis and radiological diagnosis

CT diagnosis	Clinical diagnosis		Total (%)	Chi-square value	*P*-value
	Neoplastic (%)	Non-neoplastic (%)			
Neoplastic	12 (85.7)	2 (14.3)	14 (100.0)	54.569	<0.001
Non-neoplastic	0 (0.0)	58 (100.0)	58 (100.0)		
Total	12 (16.7)	60 (83.3)	72 (100.0)		

DISCUSSION

The objectives of the study were to find out the clinical and radiological findings of sinonasal masses and their correlation with the histopathology of the sinonasal masses.

Sinonasal masses form a heterogeneous group of lesions with a broad spectrum of histopathological features.[15] Commonly presenting as nasal polyps, it is difficult to differentiate these as neoplastic and non-neoplastic lesions clinically. Furthermore, inability to differentiate benign from malignant lesions leads to a significant delay in therapy.[16]

In the study at a tertiary care hospital in Maharashtra by Lathi *et al.*, the mean age group of the presentation was 31.2. The male to female ratio was 1.5:1.[2] The age group of presentation for non-neoplastic lesions was 11–40 years, 11–50 years for benign lesions, and 41–70 years for malignant lesions. Non-neoplastic masses were 80 (71.4%) and neoplastic were 32 (28.6%). Benign lesions were 19 (17%). Malignant lesions of 13 cases (11.6%) were noted in the 3rd–6th decade of life.[2]

In a study period of 2 years at Jaipur by Rawat *et al.*,[17] 264 patients with sinonasal masses were included among whom the mean age of presentation was 30.1 (21–30 years) for non-neoplastic lesions, 28 years for benign neoplastic lesions (11–20 years), and 53 years for malignant neoplastic lesions (beyond 40 years). The male to female ratio was 2.1:1. The number of non-neoplastic lesions was 181 (68.56%), benign lesions 60 (22.72%), and malignant 23 (8.71).[17]

Similarly, at Uttarakhand in a study of 110 cases over a period of 12 months, the male to female ratio was 1.8:1.[18] The mean age of presentation for non-neoplastic lesions was 39.1, for benign lesions 27.1 and for malignant lesions 51 years.[18] Non-neoplastic masses were diagnosed in 63 patients (57.27%) and neoplastic lesions were noted in 47 patients (42.73%), among whom 23 were benign and 24 were malignant (51.07%).

In this study, the mean age for non-neoplastic lesions was more when compared with other studies, as a large percentage of patients with benign lesions in the study was sinonasal polyposis, which was mostly seen in the age group of 40–60 years. The mean age of presentation in this study was 42.75 years and the male to female ratio was 1.3:1. In most of the studies, males were affected more when compared to females and the present findings are similar to other studies.[2,17,18]

The most common presenting symptoms in the study were nasal obstruction found in 81.9% cases followed by nasal discharge (61.1%) and headache (58.3%).

The presentation of clinical symptoms was comparable to the findings by Lathi *et al.* with nasal obstruction (97.3%), nasal discharge (49.1%), and headache (16.9%)[2] and also in similar studies by Rawat *et al.*[17] with the nasal block (97.5%), nasal discharge 49.1%, and hyposmia 31.3%[18] and Bist *et al.* with nasal obstruction (82.7%), nasal discharge (69.09%), and headache (60.9%),[18] respectively.

Table 9: Diagnosis of various sinonasal masses by histopathology

Histopathology report	Frequency	Percent
Inflammatory polyp	31	43.1
Allergic polyp	16	22.2
Squamous cell carcinoma of maxilla	3	4.2
Mucormycosis	3	4.2
Aspergillosis	8	11.1
Mucocele	2	2.8
Vascular lesions	5	6.9
Inverted papilloma	3	4.2
Angiosarcoma	1	1.4

Table 10: Association between clinical diagnosis and histopathology

Clinical diagnosis	Histopathology report		Total (%)	Chi-square value	*P*-value
	Neoplastic (%)	Non-neoplastic (%)			
Neoplastic	11 (100.0)	0 (0.0)	11 (100.0)	52.57	<0.001
Non-neoplastic	2 (3.3)	59 (96.7)	61 (100.0)		
Total	13 (18.1)	59 (81.9)	72 (100.0)		

Table 11: Association between CT scan diagnosis and histopathology report

CT diagnosis	Histopathology report		Total (%)	Chi-square value	*P*-value
	Neoplastic (%)	Non-neoplastic (%)			
Neoplastic	10 (71.4)	4 (28.6)	14 (100.0)	43.835	<0.001
Non-neoplastic	0 (0.0)	58 (100.0)	58 (100.0)		
Total	10 (13.8)	62 (86.1)	72 (100.0)		

In this study, it was revealed that 58.3% of patients with sinonasal mass presented to the hospital after 1 year of onset of symptoms. The remaining 41.6% of patients presented within 1 year of onset, of which 9.7% presented within 3 months.

This was because in the case of the malignant condition, the patients reported the symptoms early as they were either nasal bleeding or facial swelling. On the other hand, mild and chronic symptoms such as nasal obstruction, nasal discharge, and headache were reported to the hospital only after they became troublesome. In the study by Bist *et al*.,[18] 72% of the patients were symptomatic within a year itself.

Polyp was the predominant nasal endoscopic feature in the present study, which was consistent with most of the previous studies.[2,17,18]

According to this study, 33.3% of sinonasal masses were unilateral and 66.7% were bilateral. Eye symptoms were seen in 10 (13.9%) cases. Eye symptoms were mostly seen in non-neoplastic lesions (11.1%) which were contrary to a similar study by Bist *et al*.[18] who reported 11 cases with proptosis (10%) and six cases with restricted eyeball movements (5.45%). Eye symptoms were seen in two cases of malignancy, two cases of frontoethmoid mucocele, two cases of massive polyposis, and four cases of fungal sinusitis. In a similar study by Rawat *et al*.,[17] eye symptoms (proptosis) presented in 19 cases (10.7%), of which eight were non-neoplastic, five were benign, and six were malignant. This was comparable to the present study. The reduced vision was seen in one patient in our study whose histopathology report came as angiosarcoma.

High incidence of eye symptoms in fungal disease may be due to the invasive nature of fungal infection (mucormycosis) and immunocompromised status of two of the patients at the time of presentation.[19]

Palpable cervical lymph nodes were not detected in any of the patients in this study, while palpable neck lymph nodes were seen in ten patients (9.09%)[18] as a larger percentage of sinonasal malignancy (24.76%) was noted in their study which accounts for the neck metastasis. This may be due to early diagnosis of the disease and the fact that metastasis to cervical lymph nodes occurred late in malignancy of the nose and PNS.

Since the patients in the study group required surgery, CT scan with contrast of the PNS was advised as it depicted better the anatomy of the nose and PNS. It was also helpful to look for the various anatomical variations that may determine the course of the surgery. Mass in the nose or the PNS was seen in the CT of all the patients.

Bone erosion was seen in 25% of the cases on CT. This was either due to malignancy or invasive fungal sinusitis and was similar to another study.[19] Mucosal thickening was found in 59 patients (81.9%). OMC disease was seen in 52 patients (72.2%). Although CT scan helps in diagnosis and tumor staging, it is not totally reliable in assessing the extension of the sinonasal mass lesions as retained/inspissated secretions and thickened mucosa within the PNS can be misinterpreted as an extension of the malignancy (false positive).[18] Therefore, MRI may be needed to differentiate between true disease infiltration and obstruction secondary to infiltration of the draining ostia. MRI is also helpful in distinguishing between tumor and retained secretions in the sinus cavities, which makes it a useful tool in tumor surveillance.[20]

Thus, radiological investigations help in understanding the type of pathology, extension of lesion, and associated sinus involvement. CT scans are far more diagnostic than plain X-rays and have effectiveness comparable to endoscopic examination.[17]

Many of the non-neoplastic and benign neoplastic nasal masses undergo surgical excision, while malignant neoplastic nasal masses require wide surgical excision, radiotherapy, or chemotherapy either alone or in combination.[21]

In this study, histopathology was done in all the patients. The distribution of various lesions into non-neoplastic and neoplastic in the study was compared with other studies.

Among the non-neoplastic lesions, nasal polyps were the most common lesions seen, forming 78.3% of the non-neoplastic (83.3%) lesions. Other studies have also reported higher proportions of polyps in non-neoplastic lesions. Lathi *et al*.[2] reported 70% of non-neoplastic polyps (71.4%) presented as nasal polyps, while in other studies, 78.4% were polyps of 68.6% non-neoplastic polyps[17] and 93% cases were polyps out of the 56.4% of non-neoplastic lesions.[18]

Among the benign lesions, lobular capillary hemangioma was the most common one diagnosed in 6.9% of patients (five cases) which was the same as by Lathi *et al*.[2] while inverted papilloma formed 4.2% of the benign neoplasms in the present study and formed 36.8% of benign neoplastic cases in the study by Lathi *et al*.[2]

In the study by Bist *et al*.,[18] 56.4% cases were non-neoplastic lesions, 19.8% were benign, and 23.7% were of malignant nature. Angiofibroma formed 35% of the benign cases and carcinoma of the nasal cavity 45.83%, of which SCC was the most common histopathological diagnosis in 33.3%.

Among the malignant lesions, malignancy of maxilla was the most common lesion seen in 4.2% of patients (three cases) in our study. The most common histopathological type was SCC seen in three of the total four patients with neoplastic malignant lesions (75%). The results were partly in accordance with another study where nasal polyps, angiofibroma, and SCC were the most common non-neoplastic, benign, and malignant lesions, respectively.[18]

The variation noted between CT diagnosis and histopathology was 4.16% in the current study (three patients). This was in accordance with a similar study on sinonasal masses, in which 3.63%[18] of cases showed a difference in radiologic and pathologic findings and in another study showed 3.62%.[22]

Following the histopathology report, clinical diagnosis had to be changed in only one case (1.38%). Another similar study reported 1.1% of patients with histopathologic findings different from their clinical diagnosis and led to an alteration in management.[23]

Two other studies observed that only 0.3% of their patients had histopathological findings different from their clinical diagnosis.[24,25] However, in one study, histopathology report varied from the clinical diagnosis in almost 6% of cases.[24]

From all these studies, it is clear that histopathological findings do remain the gold standard for the accurate diagnosis and further management of sinonasal masses.

Relying only on clinical features of sinonasal masses can lead to inaccurate diagnosis and management. Therefore, it is essential to correlate clinical, radiological, and pathological findings in the management of sinonasal masses as these modalities are complementary to each other.

Limitations

There were a few limitations in the study.

There was no control group for correlating the several anatomical variations observed in the study.

Some landmarks shown on CT were not revealed during endoscopic surgery unless they were diseased or pathological.

CONCLUSION

- Sinonasal masses have various differential diagnoses. Neoplastic lesions should be distinguished from non-neoplastic lesions
- Benign conditions show a peak during the third or fourth decade of life, while malignancy is generally observed after the 4th decade
- Polyps are the most common non-neoplastic lesions. SCC is the most common malignant tumor of the sinonasal tract histologically
- Allergic polyps were usually bilateral whereas neoplastic benign and malignant lesions usually present unilaterally
- Nasal obstruction is the most common symptom
- CT scan as an imaging modality should be done following DNE for understanding the nature and extent of the disease and for planning surgical management
- MRI is currently used for evaluation of sinus disease in cases of aggressive sinus infection with ocular/intracranial complications or potential invasive fungal sinusitis in immunocompromised patients
- Complete surgical resection followed by adjuvant radiotherapy is an effective and safe approach in the treatment of sinonasal malignancies and is associated with a better survival rate
- Correlation of clinical, radiological, and pathological modalities is of utmost importance for an accurate diagnosis. All these are complementary to each other. In some cases, immunohistochemistry may also have to be done for confirming the diagnosis
- An exhaustive workup of patients with sinonasal mass and a thorough histopathology evaluation should be done so that a correct and timely intervention can be made.

REFERENCES

1. Dasgupta A, Ghosh RN, Mukherjee C. Nasal polyps-histopathologic spectrum. Indian J Otolaryngol Head Neck Surg 1997;49:32-7.
2. Lathi A, Syed MM, Kalakoti P, Qutub D, Kishve SP. Clinico-pathological profile of sinonasal masses: A study from a tertiary care hospital of India. Acta Otorhinolaryngol Ital 2011;31:372-7.
3. Groves J, Gray RF. Tumours and cysts of the nose, paranasal sinuses and jaws. In: A Synopsis of Otolaryngology. 4th ed. Bristol: Wright; 1985. p. 215-26.
4. Maru Y, Gupta Y. Nasal endoscopy versus other diagnostic tools in sinonasal diseases. Indian J Otolaryngol Head Neck Surg 2016;68:202-6.
5. Sonkens JW, Harnsberger HR, Blanch GM, Babbel RW, Hunt S. The impact of screening sinus CT on the planning of functional endoscopic sinus surgery. Otolaryngol Head Neck Surg 1991;105:802-1.
6. Varshney H, Varshney J, Biswas S, Ghosh SK. Importance of CT scan of paranasal sinuses in the evaluation of the anatomical findings in patients suffering from sinonasal polyposis. Indian J Otolaryngol Head Neck Surg 2016;68:167-72.
7. Kanwar SS, Mital M, Gupta PK, Saran S, Parashar N, Singh A. Evaluation of paranasal sinus diseases by computed tomography and its histopathological correlation. J Oral Maxillofac Radiol 2017;5:46-52.
8. Okuyemi KS, Tsue TT. Radiologic imaging in the management of sinusitis. Am Fam Physician 2002;66:1882-6.
9. Leung RS, Katial R. The diagnosis and management of acute and chronic sinusitis. Prim Care 2008;35:11-24.
10. Lee JT, Kennedy DW. Endoscopic sinus surgery. In: Bailey BJ, Johnson JT, Newlands SD, editors. Head and Neck Surgery-Otolaryngology. 4th ed. Philadelphia, PA: Lippincott Williams and Wilkins; 2006. p. 460-74.
11. Lal D, Stankiewicz JA. Primary sinus surgery. In: Flint PW, Haughey BH,

Lund VJ, Niparko JK, Richardson MA, Robbins KT, *et al*. Cummings Otolaryngology Head and Neck Surgery. 4th ed., Vol. 1. Philadelphia, PA: Elsevier Mosby; 2005. p. 740-51.
12. Jones NS. CT of the paranasal sinuses: A review of the correlation with clinical, surgical and histopathological findings. Clin Otolaryngol Allied Sci 2002;27:11-7.
13. Stammberger H, Posawetz W. Functional endoscopic sinus surgery. Concept, indications and results of the Messerklinger technique. Eur Arch Otorhinolaryngol 1990;247:63-76.
14. Kazi M, Awan S, Junaid M, Qadeer S, Hassan NH. Management of sinonasal tumors: Prognostic factors and outcomes: A 10 year experience at a tertiary care hospital. Indian J Otolaryngol Head Neck Surg 2013;65:155-9.
15. Shirazi N, Bist SS, Selvi TN, Harsh M. Spectrum of sinonasal tumors: A 10-year experience at a tertiary care hospital in North India. Oman Med J 2015;30:435-40.
16. Garg D, Mathur K. Clinico-pathological study of space occupying lesions of nasal cavity, paranasal sinuses and nasopharynx. J Clin Diagn Res 2014;8:FC04-7.
17. Rawat DS, Chadha V, Grover M, Ojha T, Verma PC. Clinico-pathological profile and management of sino-nasal masses: A prospective study. Indian J Otolaryngol Head Neck Surg 2013;65:388-93.
18. Bist SS, Varshney S, Baunthiyal V, Bhagat S, Kusum A. Clinico-pathological profile of sinonasal masses: An experience in tertiary care hospital of Uttarakhand. Natl J Maxillofac Surg 2012;3:180-6.
19. Venugopal M, Sagesh M. Proptosis: The ENT surgeon's perspective. Indian J Otolaryngol Head Neck Surg 2013;65:247-50.
20. Raghavan P, Phillips CD. Magnetic resonance imaging of sinonasal malignancies. Top Magn Reson Imaging 2007;18:259-67.
21. Chatterjee P, Sharma P, Khanna S. A clinicopathological and radiological study of sinonasal mass. Indian J Med Res Pharm Sci 2014;1:21-6.
22. Somani S, Kamble P, Khadkear S. Mischievous presentation of nasal masses in rural areas. Asian J Ear Nose Throat 2004;2:9-17.
23. Diamantopoulos II, Jones NS, Lowe J. All nasal polyps need histological examination: An audit-based appraisal of clinical practice. J Laryngol Otol 2000;114:755-9.
24. Kale SU, Mohite U, Rowlands D, Drake-Lee AB. Clinical and histopathological correlation of nasal polyps: Are there any surprises? Clin Otolaryngol Allied Sci 2001;26:321-3.
25. Garavello W, Gaini RM. Histopathology of routine nasal polypectomy specimens: A review of 2,147 cases. Laryngoscope 2005;115:1866-8.

How to cite this article: Namrata S, Santhi T. Clinicopathological Correlation of Sinonasal Masses with Pre-operative Computed Tomography Findings. Int J Sci Stud 2020;8(2):41-49.

Source of Support: Nil, **Conflicts of Interest:** None declared.

Print ISSN: 2321-6379
Online ISSN: 2321-595X

Original Article

A Clinical and Radiographic Comparative Evaluation of Self-healing Extraction Socket versus Use of Autogenous Dentin and Demineralized Freeze-Dried Bone Allograft for Socket Preservation Following Tooth Extraction

Nilesh D Jadhav[1], Lalith Vivekananda[2], Shweta Kokane[3]

[1]M.Sc Periodontology and Oral Implantology, Universitat Jaunme I, Castellon, Castellon de la Plana, Spain, [2]Professor, Dental Science Masters Programme, Castellon de la Plana, Spain, [3]Practising Dental Surgeon

Abstract

Introduction: Preservation of alveolar dimensions after tooth extraction is crucial to achieve optimal esthetic and functional prosthodontic results. With the increasingly frequent use of dental implants to replace non-restorable teeth, preservation of the existing alveolus is essential to maintain adequate bone volume for placement and stabilization of the implants. The aim of the study was to clinically and radiographically compare and evaluate autogenous dentin as bone graft with demineralized freeze-dried bone allograft (DFDBA) and extraction socket left alone for healing.

Materials and Methods: Ethical clearance was obtained for the study. A written informed consent was taken from all the participants. A total of 45 randomly selected adult patients were divided into three groups: (1) Extraction socket with graft material placement: Autogenous dentin (natural tooth dentin) as a bone graft (15 participants). (2) Extraction socket with graft material placement: DFDBA as a bone graft (15 participants). (3) Extraction socket to be left alone for healing (15 participants). The cases were examined at 3, 6, and 9 months post-intervention. For each visit, clinical and radiographic assessment radiovisiography was done to access the bone tissue healing. The mean buccolingual bone ridge width and height were compared both clinically and radiographically. The data collected were subjected to statistical analysis using SPSS 22.0. ANOVA and paired *t*-test were carried out for comparing the mean bone buccolingually on the radiograph. All $P < 0.05$ were considered to be statistically significant.

Results: The mean buccolingual ridge width measured by Vernier caliper for the I group was 7.13 ± 0.91, for II group, it was 6.20 ± 0.86, and for the III group was 5.33 ± 0.61. The difference between the groups was statistically significant at 9 months. The mean height of the bone measured by radiograph showed that for I group, it was 6.33 ± 0.88, for II group, it was 6.13 ± 0.83, and for the III group, it was 5.33 ± 0.61. The difference in the mean outcome was significant between I and III as well as II and III groups.

Conclusion: The results of the grafted sites showed statistically significant difference compared to non-grafted sites. The alveolar ridge preservation shows reduction in buccolingual shrinkage. The present investigation shows that augmenting the extraction socket with biomaterials may have the possibility to limit the buccolingual and coronal apical shrinkage.

Key words: Autogenous dentin, Healing, Socket preservation

Access this article online

IJSS

www.ijss-sn.com

Month of Submission : 03-2020
Month of Peer Review : 04-2020
Month of Acceptance : 05-2020
Month of Publishing : 05-2020

INTRODUCTION

A regularly performed procedure in the dental set up is tooth extraction. Lack of preventive measures causes compromised health of not only the tooth but also the alveolar bone. After tooth extraction, the remaining socket heals from the apex toward the crest.[1] When no additives

Corresponding Author: Nilesh D Jadhav, Universitat Jaunme I, Castellon, Castellon de la Plana, Spain.

are placed into the socket at the time of the extraction, the soft-tissue infiltration at the crest often results in facial and crestal bone loss.[2] Dimensional changes after tooth extraction often result in bone resorption that complicates placement of implants or traditional prosthesis.[3] With the increasingly frequent use of dental implants to replace non-restorable teeth, preservation of the existing alveolus is essential to maintain adequate bone volume for placement and stabilization of the implants.[4] Therefore, preserving the alveolar dimension of the socket after extraction aids in successful accomplishment of dental implants. Socket preservation is a surgical procedure, in which graft material or a scaffold is placed in a fresh extraction socket to preserve the alveolar ridge for a future prosthesis.[5,6] There are many techniques, like using autogenous, allogeneic, xenograft, and alloplast graft materials, to guide and assist specialized cellular components of the periodontium to participate in the regenerative process to preserve bone width and height of the alveolus.[7] At present, all extracted teeth are generally considered clinical waste and, therefore, are simply discarded.[8] Recently, however, several studies have reported that extracted teeth from patients, which undergo a process of cleaning, grinding, demineralization, and sterilization, can be a very effective graft to fill alveolar bone defects in the same patient.[9,10] This study aims to evaluate the efficacy of autogenous dentin graft material in achieving good bone fill, which is essential for preservation of alveolar ridge dimensions.

MATERIALS AND METHODS

Ethical clearance was obtained before the start of the study. Forty-five adult patients, free of any known systemic illness (such as diabetes mellitus, hypertension, or on drugs like steroids) who agreed to participate in the study, were randomly selected from a private clinic for the study. The study is a pilot study, to check the feasibility of the method; hence, no statistical assessment of sample size was done. The selected patients were divided into three different groups as follows:

- Extraction socket with graft material placement: Autogenous dentin (natural tooth dentin) as a bone graft
- Extraction socket with graft material placement: Demineralized freeze-dried bone allograft (DFDBA) as a bone graft
- Extraction socket to be left alone for healing.

A baseline assessment of the clinical width of the alveolar ridge before extraction was done and recorded with the help of a Vernier caliper. The height was recorded using radiovisiography (RVG). After intervention, the same assessment was done after 3 months, 6 months, and 9 months. Difference in the clinical parameters between the all the four groups pre- and postoperatively, at baseline, at 15 days, 3 months, 6 months, and 9 months, was calculated using SPSS 22.0 (IBM Analytics, New York, U.S.A). Data were compared by applying ANOVA and *t*-test. All $P < 0.05$ were considered to be statistically significant.

RESULTS

Table 1 shows the clinical comparison of mean ridge with at the baseline.

The mean ridge width of Group I at baseline was 9.06 ± 0.79. At 3 months, it was 5.53 ± 0.63 and at 6 months, it was 7.00 ± 0.84. The difference between the measurements was significant after 6 months as compared to 3 months and baseline ($P < 0.001$). At 9th month, it was 7.13 ± 0.91, this was higher than the measurements at 6 months but not significant ($P = 0.164$). In Group II, the mean difference at 9 months (5.33 ± 0.61) was significantly higher than at 6 months (5.33 ± 0.61) and 3 months (4.86 ± 0.91). Table 2 shows the mean mesiodistal width comparison measured using the RVG.

The mean bone width of Group A at baseline was 9.06 ± 0.79. At 3 months it was 5.53 ± 0.63. No difference was seen between baseline and 3 months ($P < 0.792$). At 6 months it was 6.80 ± 0.77. This was not significantly different than the score at 3 months ($P = 0.207$). At 9 months, the mean ridge width was 6.93 ± 0.91, significant higher than 6 months ($P = 0.020$). The mean bone width of Group B at baseline was 9.13 ± 1.06. At 3 months it was 4.66 ± 0.48. No difference was seen between baseline and 3 months ($P < 0.871$). At 6 months it was 5.73 ± 0.79. This was not significantly higher than at 3 months ($P = 0.664$). At 9 months, the mean ridge width was 6.13 ± 0.83, significant higher than 6 months ($P = 0.020$). The mean bone width of Group C at baseline was 9.80 ± 0.94. At 3 months it was 4.86 ± 0.91. No difference was seen between baseline and 3 months ($P = 0.440$). At 6 months it was 5.33 ± 0.61. This was significantly higher than the mean bone width at 3 months ($P = 0.021$). At 9 months, the mean ridge with did not change. Table 3 shows the mean bone height measured with RVG.

The mean bone height of Group A at baseline was 9.06 ± 0.79. At 3 months it was 3.73 ± 1.09. The difference was statistically significant ($P < 0.001$). At 6 months it was 6.46 ± 0.51. This was significantly lower than the score at baseline ($P < 0.001$). At 9 months, the mean ridge width was 6.93 ± 0.91. No significant difference was seen when compared to 6 months ($P = 0.201$). The mean bone height of Group B at baseline was 9.20 ± 1.06. At 3 months it was

Table 1: Comparison of mean ridge width (buccolingual) in millimeter (mm) among the three groups (measured with Vernier caliper)

Measurement	Ridge width			*P*-value		
	Group A	Group B	Group C	Group A versus Group B	Group A versus Group C	Group B versus Group C
	Mean±SD	Mean±SD	Mean±SD			
Baseline	9.06±0.79	9.13±1.06	9.80±0.94	-	-	-
3 months	5.53±0.63	4.80±0.67	4.86±0.91	0.029	0.051	0.968
6 months	7.00±0.84	5.86±0.91	5.33±0.61	0.001	<0.001	0.176
9 months	7.13±0.91	6.20±0.86	5.33±0.61	0.008	<0.001	0.015

SD: Standard deviation

Table 2: Comparison of mean bone width (mesiodistal) in millimeters (mm) among the three groups (measured using RVG with grid)

Measurement (mm)	Bone width			*P*-value		
	Group A	Group B	Group C	Group A versus Group B	Group A versus Group C	Group B versus Group C
	Mean±SD	Mean±SD	Mean±SD			
Baseline	9.06±0.79	9.13±1.06	9.80±0.94	-	-	-
3 months	5.53±0.63	4.66±0.48	4.86±0.91	0.004	0.034	0.718
6 months	6.80±0.77	5.73±0.79	5.33±0.61	0.001	<0.001	0.305
9 months	6.93±0.88	6.13±0.83	5.33±0.61	0.021	<0.001	0.021

SD: Standard deviation, RVG: Radiovisiography

Table 3: Comparison of mean bone height in millimeters (mm) among the three groups (measured using RVG with grid)

Measurement (mm)	Bone height			*P*-value		
	Group A	Group B	Group C	Group A versus Group B	Group A versus Group C	Group B versus Group C
	Mean±SD	Mean±SD	Mean±SD			
Baseline	9.06±0.79	9.20±1.26	9.80±0.77	-	-	-
3 months	3.73±1.09	4.60±0.91	4.33±0.61	0.030	0.172	0.697
6 months	6.46±0.51	5.60±0.98	4.60±0.82	0.014	<0.001	0.004
9 months	6.53±0.63	5.66±0.97	4.93±0.96	0.025	<0.001	0.067

SD: Standard deviation, RVG: Radiovisiography

4.60 ± 0.91. There was a statistically significant difference seen between baseline and 3 months score ($P < 0.001$). At 6 months it was 5.60 ± 0.98. This was significantly higher than at 3 months ($P = 0.001$). At 9 months, the mean bone height was 5.66 ± 0.97. There was no significant difference between the scores at 9 months and 6 months ($P = 0.334$). The mean bone height of Group C at baseline was 9.80 ± 0.77. At 3 months it was 4.33 ± 0.61. Statistically significant difference was seen between baseline and 3 months ($P < 0.001$). At 6 months it was 4.60 ± 0.82. This was not significantly higher than the mean bone height at 3 months ($P = 0.104$). At 9 months, the mean bone height was 4.93 ± 0.96. No significant difference was seen between 9 months and 6 months score.

DISCUSSION

The primary aim of this study was to assess whether the use of a ridge preservation technique significantly minimizes alveolar ridge resorption following tooth extraction on the basis of radiographic and clinical parameters. It is well documented that avulsed teeth that are implanted back into their sockets undergo firm reattachment to bone, which is formed directly on root dentin or cementum, leading to ankylosis.[11] An ankylosed root is continuously resorbed and replaced by bone, eventually resorbing the entire root, while the alveolar process is preserved during this period and later.[12-15] In the present study, the use of autogenous dentin as bone graft for socket preservation showed significant results ($P = 0.029$), this is also in agreement with another study that reported favorable wound healing with minimal complications and good bone support for the implants.[16] No implant was lost after 12 months of function following prosthetic rehabilitation. Another study[17] supported the present study of the use of autogenous dentin as bone graft in immediate extraction sockets for the ridge preservation, in this study, the patient was followed up till 2 years after grafting of the extraction sites. A study reported that FDBA as a bone graft material results in socket preservation

resulted about a 1 mm gain of ridge height, while extraction alone had a loss of about 1 mm in ridge height similar to our findings.[18] In the present study, the control group depicted bone loss buccolingually and coronoapically, statistically significant bone loss compared to the autogenous dentin group. This is also in agreement with another study,[19] which reported that after 180 days of healing, the healed ridge is a non-load carrying tissue with obviously no demand for mineralized tissue. In the present investigation, mucoperiosteal flap was not raised for tooth extraction. By elevating the periosteum, the blood supply of the exposed bone surface will be compromised, leading to osteoclastic activity and bone resorption. A recent study proved that connective tissue membrane could preserve socket width, amount of keratinized tissue, and the gingival level more effectively than DFDBA alone.[20] Another study conducted in 36 single-rooted extraction sockets with DFDBA alone (control) and DFDBA along with platelet-rich fibrin (PRF) (test group) concluding that PRF could be used as an adjunct along with DFDBA for socket preservation.[20,21] Two more studies reported that Wilderman[22] Moghaddas *et al*.[22,23] concluded that radiographs with a grid aids in increasing the accuracy of the linear measurements for the treatment planning which also helped in recording the bone fill at intervals of 3 months, 6 months, and 9 months, thus supporting the current study of use of dental grids as one of the way of standardizing the study. However, the findings from the present study show that it might be reasonable to use autogenous dentin as a bone graft for ridge preservation followed by DFDBA. These grafts have the potential to limit shrinkage occurring after tooth extraction.[24-26] Yet, the biologic process after tooth extraction cannot be altered. Hence, further longitudinal studies are required to evaluate the amount of bone loss after socket preservation and also evaluating histologically, the quality of bone formed with a surgical reentry at the time of implant placement.

CONCLUSION

It Can Be Concluded by the Present Study

The results of the grafted sites showed statistically significant difference compared to non-grafted sites. The present investigation shows that augmenting the extraction socket with biomaterials may have the possibility to limit the buccolingual and coronal apical shrinkage. Over the long term, complications such as loss of function and inadequate bone for the placement of dental implants can be prevented.

REFERENCES

1. Sakkas A, Wilde F, Heufelder M, Winter K, Schramm A. Autogenous bone grafts in oral implantology-is it still a “gold standard”? A consecutive review of 279 patients with 456 clinical procedures. Int J Implant Dent 2017;3:23.
2. Gual-Vaques P, Polis-Yanes C, Estrugo-Devesa A, Ayuso-Montero R, Mari-Roig A, Lopez-Lopez J. Autogenous teeth used for bone grafting: A systematic review. Med Oral Patol Oral Cir Bucal 2017;23:e112-9.
3. Elo JA, Herford AS, Boyne PJ. Implant success in distracted bone versus autogenous bone-grafted sites. J Oral Implantol 2009;35:181-4.
4. Her S, Kang T, Fien MJ. Titanium mesh as an alternative to a membrane for ridge augmentation. J Oral Maxillofac Surg 2012;70:803-10.
5. Lizio G, Corinaldesi G, Marchetti C. Alveolar ridge reconstruction with titanium mesh: A three-dimensional evaluation of factors affecting bone augmentation. Int J Oral Maxillofac Implants 2014;29:1354-63.
6. Torres J, Tamimi F, Alkhraisat MH, Manchón Á, Linares R, Prados-Frutos JC, *et al*. Platelet-rich plasma may prevent titanium-mesh exposure in alveolar ridge augmentation with anorganic bovine bone. J Clin Periodontol 2010;37:943-51.
7. Misch C, Jensen O, Pikos M, Malmquist J. Vertical bone augmentation using recombinant bone morphogenetic protein, mineralized bone allograft, and titanium mesh: A retrospective cone beam computed tomography study. Int J Oral Maxillofac Implants 2015;30:202-7.
8. Park M, Mah YJ, Kim DH, Kim ES, Park EJ. Demineralized deciduous tooth as a source of bone graft material: Its biological and physicochemical characteristics. Oral Surg Oral Med Oral Pathol Oral Radiol 2015;120:307-14.
9. Koga T, Minamizato T, Kawai Y, Miura K, Asahina I, Nakatani Y, *et al*. Bone regeneration using dentin matrix depends on the degree of demineralization and particle size. PLoS One 2016;11:e0147235.
10. Kim YK, Lee JH, Um IW, Cho WJ. Guided bone regeneration using demineralized dentin matrix: Long-term follow-up. J Oral Maxillofac Surg 2016;74:515.e1-9.
11. Park CH, Abramson ZR, Taba M Jr., Jin Q, Chang J, Kreider JM, *et al*. Three-dimensional micro-computed tomographic imaging of alveolar bone in experimental bone loss or repair. J Periodontol 2007;78:273-81.
12. Kim YK, Kim SG, Yun PY, Yeo IS, Jin SC, Oh JS, *et al*. Autogenousteethused for bone grafting: A comparison with traditional grafting materials. Oral Surg Oral Med Oral Pathol Oral Radiol 2014;117:e39-45.
13. Andersson L. Dentin xenografts to experimental bone defects in rabbit tibia are ankylosed and undergo osseous replacement. Dent Traumatol 2010;26:398-402.
14. Murata M, Akazawa T, Mitsugi M, Um IW, KimKW, Kim YK. Human dentin as novel biomaterial for bone regeneration. In: PignatelloR, editor. Biomaterials: Physics and Chemistry. Croatia: In Tech; 2011. p. 127-40.
15. Kim YK. Bone graft material using teeth. J Korean Assoc Oral Maxillofac Surg 2012;38:134-8.
16. Kim S, Kim S, Kim K. Effect on bone formation of the autogenous tooth graft in the treatment of peri-implant vertical bone defects in the minipigs. Maxillofac Plast Reconstr Surg 2015;37:2.
17. Cardarpoli G, Araujo M, Lindhe J. Dynamics of bone tissue formationinextractionsite. An experimental study indogs. J Clin Periodontol 2003;30:809-18.
18. Araujo MG, Lindhe J. Dimensional ridge alterations following tooth extraction. An experimental study in thedog. J Clin Periodontol 2005;32:212-8.
19. Cardarpoli G, Araujo M, Lindhe J. Healing of extraction sockets and surgically produced augmented and non-augmented-defects in the alveolar ridge. An experimental study in dog. J Clin Periodontol 2005;32:435-40.
20. Amler MH. The time sequence of tissue regeneration in human extraction wounds. Oral Surg Oral Med Oral Pathol 1969;27:309-18.
21. Cardaropoli D, Tamagnone L, Roffredo A, Gaveglio L. Relationship between the buccal bone plate thickness and thehealing of postextraction socketswith/without ridge preservation. Int J Periodontics Restorative Dent 2014;34:211-7.
22. Wilderman MN. Repair after periosteal retention procedure. J Periodontol 1963;34:487-503.
23. Moghaddas H, Amjadi MR, Naghsh N. Clinical and biometrical evaluation of socket preservation using demineralized freeze-dried bone allograft with and without the palatal connective tissue as a biologic membrane. Dent Res J 2012;9:758-63.
24. Thakkar DJ, Deshpande NC, Dave DH, Narayankar SD. A comparative evaluation of extraction socket preservation with demineralized freeze-

dried bone allograft alone and along with platelet-rich fibrin: A clinical and radiographic study. Contemp Clin Dent 2016;7:371-6.
25. Deshpande A, Bhargava D. Intraoral periapical radiographs with grids for implant dentistry. J Maxillofac Oral Surg 2014;13:603-5.
26. Srivastava S, Tandon P, Gupta KK, Srivastava A, Kumar V, Shrivastava T. A comparative clinico-radiographic study of guided tissue regeneration with bioresorbable membrane and a composite synthetic bone graft for the treatment of periodontal osseous defects. J Indian Soc Periodontol 2015;19:416-23.

How to cite this article: Jadhav ND, Vivekananda L, Kokane S. A Clinical and Radiographic Comparative Evaluation of Self-healing Extraction Socket versus Use of Autogenous Dentin and Demineralized Freeze-Dried Bone Allograft for Socket Preservation Following Tooth Extraction. Int J Sci Stud 2020;8(2):50-54.

Source of Support: Nil, **Conflicts of Interest:** None declared.

Print ISSN: 2321-6379
Online ISSN: 2321-595X

Original Article

Prevalence of Periodontitis in the Sample Population of Jammu Region – A Cross-Sectional Study

Anuradha Gandral[1], Romesh Singh[2], Manik Sharma[3], Bhanu Kotwal[4], Abhiroop Singh[5], Vineet Kotwal[6]

[1]Dental Surgeon, Department of Periodontics, Indira Gandhi Government Dental College, Jammu, Jammu and Kashmir, India, [2]Professor and Head, Department of Periodontics, Indira Gandhi Government Dental College, Jammu, Jammu and Kashmir, India, [3]Associate Professor, Department of Periodontics, Indira Gandhi Government Dental College, Jammu, Jammu and Kashmir, India, [4]Lecturer, Department of Periodontics, Indira Gandhi Government Dental College, Jammu, Jammu and Kashmir, India, [5]Registrar, Department of Oral Surgery, Indira Gandhi Government Dental College, Jammu, Jammu and Kashmir, India, [6]Assistant Professor, Department of Periodontics, Indira Gandhi Government Dental College, Jammu, Jammu and Kashmir, India

Abstract

Aim: The aim of the present study is to evaluate the status of periodontal disease in the sample population of Jammu region.

Materials and Methods: The study included 400 males (200 cigarette smokers and 200 non-smokers) aged 16–65 years. The subjects were randomly selected from the patients attending the dental outpatient Department of Periodontics, Indira Gandhi Government Dental College, Jammu. Community periodontal index (CPI) score was recorded for each patient and a questionnaire was completed by each patient.

Results: Periodontal condition as assessed by CPI score showed that there was a statistically significant difference in the findings between tobacco consumers and non-tobacco consumers, and periodontal health was altered in the subjects who were tobacco consumers.

Conclusion: The increasing prevalence of periodontal diseases is a concerning problem which needs immediate intervention, if not, it would have a serious negative impact on the future oral health.

Key words: Periodontitis, Pocket, Smoking

INTRODUCTION

Chronic periodontitis (CP) is a major oral health problem and it is considered as one of the reasons for tooth loss in developing and developed nations. Worldwide, the prevalence of CP in the general adult population is reported to be 30–35%, with approximately 10–15% diagnosed with severe CP.[1]

India is one of the major emerging market economies with a population of over 1 billion and is very diverse in geography, culture, tradition, habits, and even race. This diversity also extends to literacy rates, health indicator rates infant mortality rate, and hygiene practices. This variation is reflected in the periodontitis prevalence as is revealed by the two major surveys conducted.[2,3]

Periodontitis prevalence in India has also been reported. Chawla *et al.*, 1975, carried out a study in 1416 rural children and 189 factory workers in Lucknow area to assess the efficacy of oral hygiene measures and professional scaling in the prevention of disease progression. The authors reported the prevalence of gingivitis and periodontal disease in Lucknow children and adult samples to vary between 93% and 100%. They concluded that scaling half-yearly can prevent apical migration of epithelial attachment. Madden *et al.*, 2000, carried out a study in two villages in a rural area in Andhra Pradesh. One hundred and sixty participants were interviewed and examined with the community periodontal index (CPI) of

Access this article online

www.ijss-sn.com

Month of Submission : 03-2020
Month of Peer Review : 04-2020
Month of Acceptance : 05-2020
Month of Publishing : 05-2020

Corresponding Author: Anuradha Gandral, Department of Periodontics, Indira Gandhi Government Dental College, Jammu, Jammu and Kashmir, India.

treatment needs index. The authors noted a high prevalence of CP in this population.[4,5]

There also prevails a view that people in Asia are particularly susceptible to periodontitis. This view of a particularly high prevalence of periodontal diseases appears to have originated from early epidemiological studies using an index system that gave weight to gingivitis and moderate periodontitis resulting from poor oral hygiene and calculus deposition.[6]

Albandar, in an overview, concluded that subjects of Asian ethnicity had the third highest prevalence of periodontitis.[7]

The studies on the prevalence of periodontitis in a rural and urban population in different parts of the world have provided data primarily on populations of different ethnic origins. Corraini *et al.*, 2008,[8] studied the prevalence of periodontitis and its association with demographic, socioeconomic, and behavioral risk factors in an untreated and isolated population in Brazil, and 83% of the population had >4 mm probing depths. Wang *et al.*, 2007,[9] performed a descriptive study of periodontal disease conditions among a selected sample of 400 participants in China. The authors observed that periodontal disease was widespread, and very few of the population had access to the oral care facilities. Nalçaci *et al.*, 2007,[10] assessed the oral health status of people aged 65 years and above in a rural district of Turkey. The authors reported a higher level of tooth loss with increasing age. A cross-sectional study performed in a rural area in Brazil, wherein a total of 172 participants were examined for periodontal and oral hygiene parameters, and the prevalence of periodontitis was estimated to be 24.4%.[11]

MATERIALS AND METHODS

A cross-sectional study design was used. This study included 400 males aged 16–65 years attending the dental outpatient Department of Periodontics, Indira Gandhi Government Dental College, Jammu. CPI was used as an epidemiological tool. Patients were randomly selected depending on the following criteria.

Inclusion Criteria

The following criteria were included in the study:

- Over 18 years of age and not older than 65 years of age.
- More than 10 natural teeth present.

Exclusion Criteria

The following criteria were excluded from the study:

- Chronic systemic pathology, such as diabetes, other endocrine pathologies, and hematological pathologies.
- Periodontal health, with no clinical signs of periodontal inflammation (CPI =0).

Subjects were Divided into Two Groups

- Cigarette smokers
- Non-smokers.

Clinical Examination

The periodontal examination was conducted using the mouth mirror and community periodontal index of treatment needs probe, and the CPI score was recorded.

Codes and criteria of CPI index

Code-0=No periodontal disease (healthy periodontium).

Code-1=Bleeding observed during or after probing.

Code-2=Calculus or other plaque retentive factors either seen or felt during probing.

Code-3=Pathological pocket 4–5 mm in depth. Gingival margin situated on a black band of the probe.

Code-4=Pathological pocket 6 mm or more in depth. The black band of the probe is not visible.

An oral health questionnaire was also formulated and was filled by each subject [Figure 1].

RESULTS

The majority of the study group constituted the young adults under 35 years of age (47% of the total sample), 51% were having the periodontal disease and were consuming tobacco. In the oldest age group (over 55 years), only a small proportion (11%) had periodontal disease and were consuming tobacco.

The periodontal condition was measured by CPI score per person showed that in the group studied, there were statistically significant differences between tobacco consumers and non-tobacco consumers for CPI score of 1 ($P = 0.007$; non-tobacco consumers more likely to have gingival bleeding), 2 ($P = 0.004$; tobacco consumers more likely to have calculus present), CPI score 3 ($P = 0.001$; non-tobacco consumers more likely to have shallow pockets), and CPI score 4 ($P = 0.045$; tobacco consumers more likely to have deep pockets), as shown in Tables 1-3.

DISCUSSION

One of the landmark reports by Shah *et al.*, 2007, available about periodontitis prevalence in the Indian

Table 1: Study group according to age and tobacco consumption

Age, *n* (%)	16–65 years	<35 years	35–44 years	45–55 years	More than 55 years
Tobacco consumers	200 (50%)	96 (51%)	44 (48%)	28 (37%)	32 (73%)
Non-tobacco consumers	200 (50%)	92 (49%)	48 (52%)	48 (63%)	12 (27%)
Total	400 (100%)	188 (47%)	92 (23%)	76 (19%)	44 (11%)
Chi-square		0.09	1.18	5.27	9.08
P value		0.78	0.68	0.03	0.00

Table 2: Mean and standard deviation according to age among tobacco and non-tobacco consumption

Group	N	Mean age	Standard deviation
Tobacco consumers	200	38.08	13.22
Non-tobacco consumers	200	37.35	12.07

population is the multicentric study carried out by the Government of India in collaboration with the World Health Organization. A total of 22,400 participants covering both rural and urban districts of seven different states of India were examined for their periodontal status. A prevalence of 100% for periodontal disease was reported for the states of Orissa and Rajasthan. In addition, a varied prevalence of attachment loss >3 mm was observed in different states (Maharashtra – 78%, Orissa – 68%, and Delhi – 46%).[2]

The prevalence rates for periodontitis observed in most of the studies in the Indian population are high (ranging from 27% to 100%). Studies done in various populations worldwide have shown similarly high prevalence rates in developing countries as compared to developed countries, wherein a decrease in the prevalence of periodontitis has been observed. The periodontitis prevalence observed in a Brazilian rural population ranged between 24.4% and 83%,[8,11] and in a Thai population, it ranged from 92% to 100%.[12] About 100% of a Vietnamese study population exhibited at least one site with attachment loss, and 90% of the adult participants in a Guatemalan population exhibited at least one site with clinical attachment level ≥6 mm.[13]

Smoking is on the rise in the developing world, but falling in developed nations. About 15 billion cigarettes are sold daily or 10 million every minute.[14] Smoking has clearly been implicated contributing to periodontal breakdown and in impeding the healing of periodontal tissues.[15]

The findings in the present study are consistent with the study of Feldman *et al.*,[16] showed that tobacco consumers with periodontal disease had less clinical inflammation and gingival bleeding when compared with non-tobacco consumers. This may be explained by the fact that one of the numerous tobacco smoke by-products, nicotine, exerts local vasoconstriction, reducing blood flow and edema, and acts to inhibit what are normally early signs of periodontal problems by decreasing gingival inflammation, redness, and bleeding.

Patient Name:.....Sex: M/F

Age:. ..... Address:.. .....

Occupation: .....

Please give only one answer to each question

1. How often do you brush your teeth each day?
   - ☐ 1 ☐ 2 ☐ 3 ☐ 4
   - ☐ After each meal ☐ Sometimes
2. How many minutes do you brush your teeth for?
   - ☐ 1 ☐ 2 ☐ 3 ☐ 4 ☐ Over 4 minutes
3. What type of tooth brushing movements do you employ?
   - ☐ Vertical ☐ Horizontal ☐ Combined
4. Do you use a mouthwash?
   - ☐ Yes ☐ No
   - *If yes, how often?*
   - ☐ 1/day ☐ 2/day
   - ☐ 3/day ☐ more than 3/day
5. Which secondary methods for plaque control do you use?
   - ☐ Dental floss ☐ Inter-dental brushes
   - ☐ Toothpicks ☐ None
6. Do you, or did you use an electric toothbrush?
   - ☐ Yes ☐ No
7. On what is your daily diet mainly based?
   - ☐ Potato chips ☐ Vegetables
   - ☐ Milk products ☐ Meat
8. Do you have bleeding gums?
   - ☐ Yes ☐ No
   - *If yes, are these:*
   - ☐ Spontaneous ☐ Provoked ☐ Not constant
9. Do you have any health problems?
   - ☐ Yes ☐ No
   - *If yes, please give details.*
10. Do you smoke?
    - ☐ Yes ☐ No ☐ I quit smoking
11. If you are a smoker, how many cigarettes do you smoke daily?
    - ☐ 1-10 cigarettes ☐ 11-20 cigarettes
    - ☐ 21-40 cigarettes ☐ Over 40 cigarettes

Figure 1: Proforma

In this study, we used the CPI as recommended by the World Health Organization. CPI is not a perfect measure of periodontal disease and excludes measurement of attachment loss, gingival recession, alveolar bone level, and other clinical periodontal parameters. Nevertheless, it was originally proposed as an appropriate estimation of disease in large epidemiological surveys and has contributed to an understanding of the epidemiology of periodontal disease on a global level.[17]

Table 3: CPI scores according to reported tobacco consumption

CPI scores	Code 1 bleeding (%)	Code 2 calculus (%)	Code 3 shallow pockets 4–5 mm	Code 4 deep pocket more than or equal to 6 mm	Total
Tobacco consumers	14 (7)	116 (58)	29 (15)	41 (21)	200 (100)
Non-tobacco consumers	31 (15.6)	87 (43.6)	56(28)	26(13)	200(100)
Chi-square	7.3	8.5	10.9	4.1	
P value	0.007	0.004	0.001	0.045	

CPI: Community periodontal index

CONCLUSION

The present study shows that tobacco consumers showed bad periodontal health. The findings highlight the need for preventive strategies aimed at young individuals, many of whom take up smoking as a habit, early in life. However, more variables could have improved the scope of the study.

REFERENCES

1. World Health Organization. The WHO Global Oral Health Data Bank. Geneva: World Health Organization; 2007.
2. Shah N, Pandey RM, Duggal R, Mathur VP, Rajan K. Oral Health in India: A Report of the Multi Centric Study. New Delhi: Directorate General of Health Services, Ministry of Health and Family Welfare, Government of India and World Health Organization Collaborative Program; 2007.
3. Mathur VB, Talwar PP. National Oral Health Survey and Flouride Mapping 2002-2003. New Delhi, India: Dental Council of India; 2004.
4. Chawla TN, Nanda RS, Kapoor KK. Dental prophylaxis procedures in control of periodontal disease in Lucknow (Rural) India. J Periodontol 1975;46:498-503.
5. Madden IM, Stock CA, Holt RD, Bidinger PD, Newman HN. Oral health status and access to care in a rural area of India. J Int Acad Periodontol 2000;2:110-4.
6. Corbet EF. Periodontal diseases in Asians. J Int Acad Periodontol 2006;8:136-44.
7. Albandar JM, Rams TE. Global epidemiology of periodontal diseases: An overview. Periodontol 2000 2002;29:7-10.
8. Corraini P, Baelum V, Pannuti CM, Pustiglioni AN, Romito GA, Pustiglioni FE, *et al.* Risk indicators for increased probing depth in an isolated population in Brazil. J Periodontol 2008;79:1726-34.
9. Wang QT, Wu ZF, Wu YF, Shu R, Pan YP, Xia JL, *et al.* Epidemiology and preventive direction of periodontology in China. J Clin Periodontol 2007;34:946-51.
10. Nalçaci R, Erdemir EO, Baran I. Evaluation of the oral health status of the people aged 65 years and over living in near rural district of Middle Anatolia, Turkey. Arch Gerontol Geriatr 2007;45:55-64.
11. De Macêdo TC, Costa Mda C, Gomes-Filho IS, Vianna MI, Santos CT. Factors related to periodontal disease in a rural population. Braz Oral Res 2006;20:257-62.
12. Dowsett SA, Archila L, Kowolik MJ. Oral health status of an indigenous adult population of Central America. Community Dent Health 2001;18:162-6.
13. Do LG, Spencer JA, Roberts-Thomson K, Ha DH, Tran TV, Trinh HD, *et al.* Periodontal disease among the middle-aged Vietnamese population. J Int Acad Periodontol 2003;5:77-84.
14. World Health Organization. Western Pacific Region, Fact Sheets. Geneva: World Health Organization; 2002.
15. Johnson NW, Bain CA. Tobacco and oral disease. EU-working group on tobacco and oral health. Br Dent J 2000;189:200-6.
16. Feldman RS, Bravacos JS, Rose CL. Association between smoking different tobacco products and periodontal disease indexes. J Periodontol 1983;54:481-7.
17. Cutress TW, Ainamo J, Sardo-Infirri J. The community periodontal index of treatment needs (CPITN) procedure for population groups and individuals. Int Dent J 1987;37:222-33.

How to cite this article: Gandral A, Singh R, Sharma M, Kotwal B, Singh A, Kotwal V. Prevalence of Periodontitis in the Sample Population of Jammu Region – A Cross-Sectional Study. Int J Sci Stud 2020;8(2):55-58.

Source of Support: Nil, **Conflicts of Interest:** None declared.

Print ISSN: 2321-6379
Online ISSN: 2321-595X

Original Article

Analyzing the Effect of Single Intraoperative Intravitreal Bevacizumab on Central Macular Thickness in Diabetes Mellitus Patients Undergoing Phacoemulsification Under Local Anesthesia

Ganesh Sathyamurthy[1], N Mohamed Abdul Kayoom[2], Pavan S Mahajan[3], V Lima[3], T Kavitha[3], P V Manjusha[4]

[1]Assisstant Professor, Department of Ophthalmology, Rajarajeshwari Medical College, Bengaluru, Karnataka, India, [2]Post Diploma, DNB Resident, Department of Ophthalmology, MRC Eye Hospital, Mysore, Karnataka, India, [3]Resident, Department of Ophthalmology, MRC Eye Hospital, Mysore, Karnataka, India, [4]Resident, Department of Ophthalmology, K. R. Hospital, Mysore, Karnataka, India

Abstract

Aim: The aim of the study was to assess the effect of combined phacoemulsification and single intraoperative intravitreal injection of bevacizumab on the central macular thickness (CMT) in diabetic patients.

Materials and Methods: A prospective observational study was conducted on 30 eyes with diabetic retinopathy from February 2018 to February 2019. All patients underwent thorough ophthalmic evaluation. Phacoemulsification performed by a single surgeon using either 0.5% topical proparacaine eye drops or sub-tenon local anesthesia as per the preference of the surgeon in individual case. Bevacizumab 0.05 ml (1.25 mg) was injected intravitreal using a 30-gauge needle through the pars plana into the vitreous cavity after intraocular lens implantation. Patients were followed postoperatively at day 1 then at 1 week and 1 month, respectively, for recording the CMT and best corrected visual acuity at 1 month postoperatively.

Results: The mean CMT for all the patients at post-operative day 1 and month 1 was 277.96 ± 142.40 μm and 289.50 ± 155.74 μm, respectively. Patients with <10 years of diabetes had mean CMT of 329.09 μm and 318.90 μm, at post-operative day 1 and at 1 month, respectively, while those with diabetes more than 10 years had mean CMT of 248.36 μm and 272.47 μm, respectively. In mild non-proliferative diabetic retinopathy (NPDR) and stable proliferative diabetic retinopathy group no significant worsening occurred in CMT thickness, while in moderate NPDR, four out of 13 cases showed significant increase in CMT (>10%) at 1 month. In severe NPDR, out of 4 cases 1 case showed significant increase in CMT while other three cases showed modest reduction of CMT.

Conclusion: Intravitreal administration of 1.25 mg bevacizumab at the time of cataract surgery is a safe and effective way in avoiding new onset maculopathy in diabetic retinopathy patients. It is also effective to treat pre-existing clinically significant macular edema and prevent its progression to some extent in few cases.

Key words: Anti-VEGF, Central retinal thickness, Diabetic maculopathy, Intravitreal bevacizumab, Optical coherence tomography, Phacoemulsification

INTRODUCTION

Phacoemulsification is one of the most common surgical procedures for cataract.[1] It has been shown that even an uncomplicated phacoemulsification may lead to macular edema in non-diabetic patients and those who are not predisposed to this complication.[2] Diabetes mellitus has been linked to increased risk of postoperative macular edema.[3]

The pathogenesis of these complications may be related to the changes and rise in the concentration of angiogenic factors in response to surgical trauma and inflammation.[4] The most relevant angiogenic factor is vascular endothelial growth factor (VEGF).[5] According to Patel *et al.*[6] raised VEGF levels in aqueous sample obtained from diabetic

Access this article online

www.ijss-sn.com

Month of Submission : 03-2020
Month of Peer Review : 04-2020
Month of Acceptance : 05-2020
Month of Publishing : 05-2020

Corresponding Author: N Mohamed Abdul Kayoom, Department of Ophthalmology, Mysore Race Club Eye Hospital, Siddartha Layout, Mysuru, Karnataka, India.

patients 1 day after surgery approximately was noted to be 10 times higher than those of controls.

There is an important role of angiogenic factors such as VEGF in progression of diabetic macular edema (DME). Hence, the advent of anti-VEGF therapies in prophylaxis and treatment of post-cataract surgery DME has gained much interest.

Cataract surgery provides the ideal setting for administration of intravitreal medications in a sterile surgical field. Intravitreal injections of bevacizumab (Avastin) have been employed for the treatment of neovascular and exudative ocular diseases since 2005.[7]

Bevacizumab (Avastin) is a recombinant full-length humanized monoclonal antibody (149 kDa), which binds to the receptor binding domain of all isoforms of VEGF-A. The recommended dose is 1.25 mg intravitreally every 4 weeks. Bevacizumab can penetrate all layers of the retina. After intravitreal injection, its vitreous half-life is 9.8 days, and plasma half-life is 17–21 days.[8]

Optical coherence tomography (OCT) has been shown to be highly reproducible in measuring macular thickness in normal individuals and diabetic patients. It is an objective, non-contact, non-invasive, well tolerated, and highly reproducible method for quantitative retinal thickness measurements, with good reproducibility, and with approximately 10 µm resolution. OCT is a well-established method of analyzing the *in vivo* retinal architecture. OCT is the single most important diagnostic and prognostic tool in the management of DME.[9]

There is growing evidence in support of a more interventional approach. A shift in attitude toward earlier cataract extraction in diabetes mellitus has contributed to an improved visual outcome. In the present study, we evaluated the efficacy of intravitreal injection of bevacizumab after the phacoemulsification in patients with stable diabetic retinopathy without a present or history of DME.

MATERIALS AND METHODS

A prospective observational study, conducted from February 2018 to February 2019. The estimated minimum sample size given by statistician was 30 cases.

Inclusion Criteria

The following criteria were included in the study:

- Sight-limiting cataract in diabetic patients with poor fundus view precluding adequate monitoring and/or laser therapy.
- Diabetic patients with non-proliferative diabetic retinopathy (NPDR) and stable proliferative diabetic retinopathy (PDR) according to the established criteria by the Early Treatment Diabetic Retinopathy Study (ETDRS).
- Adequate metabolic control for at least 2 months before the procedure considered as having glycosylated hemoglobin (HbA1c) with figures equal to or below 7.
- Arterial blood pressure control was defined as below 140/90 mmHg during at least three visits before the operation.

Exclusion Criteria

The following criteria were excluded from the study:

- Diabetic patients who have previously received grid/focal laser, steroid implants, anti-VEGF, etc., for diabetic retinopathy in past 3 months.
- Diabetic patients with tractional retinal detachment involving macula, active PDR, vitreous hemorrhage, etc.
- Other macular pathologies affecting vision such as age-related macular degeneration (wet ARMD), choroidal neovascular membrane, and macular edema secondary to vascular occlusion.
- Patients with inadequate metabolic control, kidney failure, uncontrolled high arterial blood pressure, recent myocardial infarction, and cerebral vascular accident.
- Cases with optic nerve diseases, glaucoma, and ocular hypertension and uveitic patients.
- Cases complicated with posterior capsular tear and vitreous loss during cataract surgery.

Methodology

All the patients with known diabetes and visually significant cataract were selected based on the inclusion criteria. A detailed history, the fasting and postprandial blood sugar levels, HbA1c level, and blood pressure were recorded for all the patients.

Patients underwent a detailed ophthalmic evaluation including Snellen best corrected visual acuity and slit lamp evaluation of the anterior segment was done to know the lenticular status of the eye and to rule out the presence of any rubeosis. Other details regarding the status of the cornea, iris, and anterior chamber were also noted. Comprehensive dilated fundus examination was carried out using slit lamp biomicroscopy with the help of a 90D/78D lens and indirect ophthalmoscopy using a 20D condensing lens. Details regarding the fundus were noted and diagrams drawn for the same. Fundus photos were taken using Topcon TR50EX retinal camera if required in selected cases.

In cases in which fundus details were obscured by the density of the cataract, retinopathy grading was based on the 1st post-operative day examination. Grades of retinopathy were defined according to the Wisconsin epidemiologic study of diabetic retinopathy and clinically significant macular edema (CSME) was classified based on the ETDRS.

A-scan biometry noting axial length of eye and intraocular lens power calculation, measurement of macular thickness with spectral domain OCT was done. If macular thickness measurement was not possible by OCT because of hazy view secondary to the cataractous lens, then OCT was done on the immediate 1st post-operative day.

The Institutional Review Board approved all aspects of this investigation, and all subjects gave informed consent before enrollment in this study. The consent forms were explained in patients own vernacular language.

Operative Details

All phacoemulsification procedures were performed by a single surgeon using either 0.5% topical proparacaine eye drops or sub-Tenon local anesthesia as per the preference of the surgeon in individual case.

Patients' eyes were prepped and sterilized, 2.8 mm microkeratome clear corneal incision was done. Two corneal stab wounds were done using 20 gauge MVR blades. Capsulorhexis was done followed by hydro-dissection and stop and chop/direct chop phacoemulsification of the nucleus.

Foldable single piece intraocular lense (IOL) was implanted in the bag. Bevacizumab 0.05 ml (1.25 mg) was injected intravitreal using a 30-gauge needle through the pars plana (3.0–3.5 mm from the limbus) into the vitreous cavity. Subconjunctival injection of gentamicin + dexamethasone was given at the completion of surgery.

All eyes were treated postoperatively with combination of gatifloxacin 0.3% and prednisolone acetate 1% eye drops 8 times daily for 1st week then 6 times daily for 2 weeks and then tapered as 4 times daily for 2 weeks and 2 times daily for next 2 weeks.

Patients were followed postoperatively at day 1 then at 1 week and 1 month respectively for recording the CMT and best corrected visual acuity at 1 month postoperatively.

In the present study, all data were compiled and analyzed statistically by Cramer's V Test (Cross tablulations), Chi-square test, Paired-Samples *t*-test, and Repeated measure ANOVA. All the statistical methods were carried out through the SPSS for Windows (version 23.0).

$P \leq 0.05$ was considered to be statistically significant.

RESULTS

Thirty eyes of 27 patients with DR were studied and followed up for a period of 1 month. The study participants were in the age group of 43–82 years. Majority of patients were in the age group of 61–70 years. The mean age ± standard deviation (years) was 61.167 ± 8.77333.

Ninteen of 30 eyes in the study population were having history of diabetes for more than 10 year duration. Moderate NPDR was most frequent both overall and in >10 year diabetic age group. Mild NPDR was the most common type of retinopathy in <10 years diabetic age group. Stable proliferative diabetic retinopathy is seen in >10 year diabetic age group only [Figure 1].

Central Macular Thickness (CMT) Distribution

At day 1 postoperatively, the study participants were grouped according to the CMT as, Group 1 with CMT <250 μ and Group 2 with CMT value ≥250 μ 18 patients had CMT <250 μ, and in 12 patients it was >250 μ.

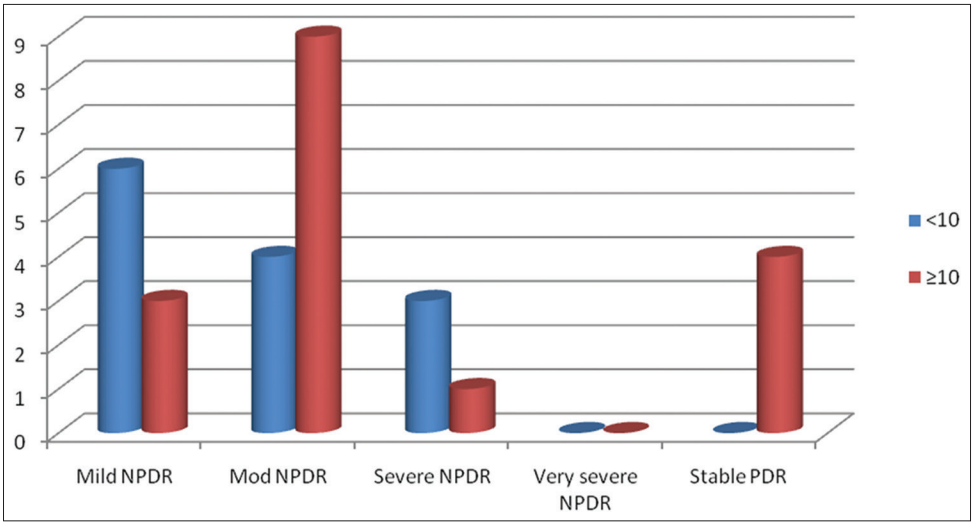

Figure 1: Duration and severity of diabetes mellitus in the study population

Change in Mean CMT at 1 Month in <250 μ and >250 μ CMT Group

The change in mean CMT is depicted in Table 1 and 2. The mean CMT for all the patients at post-operative day 1 and month 1 was 277.96 ± 142.40 and 289.50 ± 155.74, respectively.

In <250 μ CMT group, 33.33% cases showed decrease, another 33.33% cases showed no change, and remaining 33.33% cases showed increase in CMT which was <10%.

While, in >250 μ group, 58.4% cases showed increase CMT, of which in 41.7% cases the increase was >10%, while 41.7% cases showed decrease in CMT at 1 month postoperatively [Table 3].

Diabetic Age versus CMT at 1 Month

Duration of diabetes was correlated with change in CMT at 1 month.

<10 years diabetes had a mean decrease of 10.19 μm value while those with diabetes of ≥10 year duration had a mean increase of 24.11 μm at 1 month postoperatively [Table 4].

Levels of Retinopathy versus Mean CMT at 1 Month

The level of retinopathy at baseline was correlated with mean CMT at 1 month.

In mild NPDR and stable PDR group, no significant worsening occurred in CMT thickness.

While in moderate NPDR 4 (i.e., 13.33%), of 13 cases showed significant increase in CMT (>10%) at 1 month.

Table 1: <250 μ CMT group (Group 1)

CMT	Mean±SD	*P* value
Day 1	193.72±30.30	0.179
Month 1	194.22±32.05	

standard deviation

Table 2: >250 μ CMT group (Group 2)

CMT	Mean±SD	*P* value
Day 1	404.33±151.68	0.194
Month 1	432.41±158.83	

standard deviation

Table 3: Change in macular thickness at 1 month postoperatively

Column1	<250 μ CMT group	>250 μ CMT group
<10% increase	33.30%	16.70%
>10% increase	33.30%	41.70%
Decrease	0	41.70%
No change	33.33%	0
Total	100	100

In severe NPDR, of 4 cases 1 case showed significant increase in CMT while other three cases showed modest reduction of CMT [Table 5].

DISCUSSION

Diabetic patients pose a challenge due to their early formation of cataracts and propensity to develop macular edema after cataract surgery. Macular edema is a leading cause of an unfavorable visual outcome in patients with diabetes, especially in patients with pre-existing diabetic retinopathy. The most relevant angiogenic factor is VEGF. According to Patel *et al.*[6] raised VEGF levels in aqueous sample obtained from diabetic patients 1 day after surgery approximately was noted to be 10-times higher than those of controls.

Therefore, it could be postulated that controlling this VEGF increase would fruitfully play an important role in preventing postoperative increase in CMT and thereby in improving the vision outcome of the patients after cataract surgery.

In the present study, those with <10 years diabetes had a mean decrease of 10.19 μm value while those with diabetes of ≥10 year duration had a mean increase of 24.11 μm at 1 month postoperatively.

A study was done by Kim *et al.*[9] to assess the incidence or progression of macular edema after cataract surgery in diabetic patients where all the patients were with normal center point thickness. In their study, they found that those with diabetes duration of ≥10 years had an increase of center point thickness at 1 month of 83 μm, whereas the group with <10 years' duration had an increase of only 18 μm at 1 month postoperatively.

Table 4: Diabetic age versus CMT at 1 month

Diabetic age (years)	Mean CMT		*P* value
	Day 1	Month 1	
<10	329.09	318.9	0.508
≥10	248.36	272.47	

Table 5: Levels of retinopathy versus mean CMT at 1 month

Level of retinopathy	Mean CMT		*P* value
	Day 1	Month 1	
Stable PDR	172.5	166	0.716
Mild NPDR	282.7	282.7	
Moderate NPDR	256.46	286.23	
Severe NPDR	496	491	

In the present study, those with ≥10 year diabetic age group out of 19 cases two cases showed loss of at least one line and two more cases there was no change in Visual Acuity (VA) and the rest 15 cases showed improvement of ≥2 lines of VA (with $P < 0.05$) while all patients with diabetic age <10 year gained ≥3 lines ($P = 0.00$).

Kim *et al.*[9] also showed that the group with diabetes of ≥10 years had a modest gain of 1 line (0.10 log MAR units) of VA at 1 month, whereas the group with duration <10 years gained more than 2 lines (0.24 log MAR units) of VA ($P = 0.04$).

In the present study, in mild NPDR and stable PDR group no significant worsening occurred in CMT thickness and all showed improvement in visual acuity of ≥3 lines on Snellen visual acuity chart at 1 month. While in moderate NPDR 4 (i.e., 13.33%), of 13 cases showed significant increase in CMT (>10%) at 1 month. The findings of this study agrees with the published reports of Pollack *et al.*[10] and Malecaze *et al.*[11] who showed that level of diabetic retinopathy is a risk factor for thickening of the retina after cataract surgery. Kim *et al.*[9] in their study showed that the group with moderate or severe NPDR or proliferative diabetic retinopathy had the largest increase in center point thickness of 145 μm at 1 month after surgery, which was correlated inversely with VA improvement thus patients in these groups showed least improvement from baseline, of <1 line (0.08) of VA at 1 month after surgery.

In present study, progression of maculopathy occurred in 16.65% of the eyes at the end of 1 month. Cheema *et al.*[12] have reported that progression of diabetic maculopathy occurred in 51.51% of eyes that did not receive intravitreal bevacizumab (control group) and 5.71% of eyes that did receive intravitreal bevacizumab (intervention group) after cataract surgery with IOL implantation.

Kim *et al.*[9] demonstrated that 22% of diabetic patients developed increases in center point thickness of >30% at 4 weeks after uncomplicated phacoemulsification. While in the present study in <250 μ CMT group 2/3rd cases showed either reduction or no change and in remaining 1/3rd of the cases the increase was <10% at 1 month postoperatively.

We Acknowledge Some Limitations to Our Study

1. Small sample size and short duration of follow-up, which precludes the determination of the long-term safety and efficacy of prophylactic use of bevacizumab combined with phacoemulsification.
2. Control group was not included.

CONCLUSION

1. Intravitreal administration of 1.25 mg bevacizumab at the time of cataract surgery is a safe and effective way in avoiding new onset maculopathy in diabetic retinopathy patients.
2. It is also effective to treat pre-existing CSME and prevents its progression to some extent in few cases.

REFERENCES

1. Chiselita D, Poiata I, Tiutiuca C. Cataract surgery in diabetic patients. Oftalmologia 1999;47:73-80.
2. Degenring RF, Vey S, Kamppeter B, Budde WM, Jonas JB, Sauder G. Effect of uncomplicated phacoemulsification on the central retina in diabetic and non-diabetic subjects. Graefes Arch Clin Exp Ophthalmol 2007;245:18-23.
3. Vedantham V, Kim R. Intravitreal injection of triamcinolone acetonide for diabetic macular edema ophthalmic practice. Ophthalmic Pract 2006;54:133-7.
4. Simo R, Carrasco E, Garcıa-Ramırez M, Hernandez C. Angiogenic and antiangiogenic factors in proliferative diabetic retinopathy. Curr Diabetes Rev 2006;2:71-98.
5. Funatsu H, Yamashita H, Ikeda T, Mimura T, Eguchi S, Hori S. Vitreous levels of interleukin-6 and vascular endothelial growth factor are related to diabetic macular edema. Ophthalmology 2003;110:1690-6.
6. Patel JI, Hykin PG, Cree IA. Diabetic cataract removal: Postoperative progression of maculopathy-growth factor and clinical analysis. Br J Ophthalmol 2006;90:697-701.
7. Arevalo JF, Fromow-Guerra J, Quiroz-Mercado H, Sanchez JG, Wu L, Maia M, *et al*. Primary intravitreal bevacizumab (Avastin) for diabetic macular edema: results from the Pan-American collaborative retina study group at 6-month follow-up. Ophthalmology 2007;114:743-50.
8. Labriola LT, Kesen M, Csaky KG. Pharmacokinetics of anti-vascular endothelium growth factor pharmacological agents. In: Das A, Friberg TR, editors. Therapy for Ocular Angiogenesis. Philadelphia, PA: Wolters Kluwer Lippincott Williams Wilkins; 2011. p. 140-53.
9. Kim SJ, Equi R, Bressler NM. Analysis of macular edema after cataract surgery in patients with diabetes using optical coherence tomography. Ophthalmology 2007;114:881-9.
10. Pollack A, Leiba H, Bukelman A, Oliver M. Cystoid macular oedema following cataract extraction in patients with diabetes. Br J Ophthalmol 1992;76:221-4.
11. Malecaze F. Cataract surgery in diabetics. J Fr Ophtalmol 2003;26:525-7.
12. Cheema RA, Al-Mubarak MM, Amin YM, Cheema MA. Role of combined cataract surgery and intravitreal bevacizumab injection in preventing progression of diabetic retinopathy: Prospective randomized study. J Cataract Refract Surg 2009;35:18-25.

How to cite this article: Sathyamurthy G, Kayoom NMA, Mahajan PS, Lima V, Kavitha T, Manjusha PV. Analyzing the Effect of Single Intraoperative Intravitreal Bevacizumab on Central Macular Thickness in Diabetes Mellitus Patients Undergoing Phacoemulsification Under Local Anesthesia. Int J Sci Stud 2020;8(2):59-63.

Source of Support: Nil, **Conflicts of Interest:** None declared.

Print ISSN: 2321-6379
Online ISSN: 2321-595X

Original Article

Comparison of Thermal Conductivity, Flexural Strength, and Surface Hardness of Alumina Incorporated and Conventional Heat-Activated Denture Base Resins

P M Aparna[1], K Harsha Kumar[2], R Ravichandran[3], Vivek V Nair[3], H Zeenath[4], Noxy George Manjuran[4]

[1]Post Graduate Student, Department of Prosthodontics, Government Dental College, Thiruvananthapuram, Kerala, India, [2]Professor and Head, Department of Prosthodontics, Government Dental College, Thiruvananthapuram, Kerala, India, [3]Professor, Department of Prosthodontics, Government Dental College, Thiruvananthapuram, Kerala, India, [4]Assistant Professor, Department of Prosthodontics, Government Dental College, Thiruvananthapuram, Kerala, India

Abstract

Introduction: Commonly used polymethyl methacrylate (PMMA) denture base material cannot be considered as ideal due to inferior thermal and mechanical properties.

Aim: The aim of the study was to evaluate and compare the thermal conductivity, flexural strength, and surface hardness of heat cure acrylic resin incorporated with 10 wt.% and 15 wt.% alumina and conventional denture base resin.

Materials and Methods: A total of 108 specimens were prepared. Specimens were divided into three main groups. Group A specimens were disk shaped (50 mm × 5 mm) and used for measuring thermal conductivity. Groups B and C specimens were rectangular shaped (65 mm × 10 mm × 3 mm) and were used for measuring flexural strength and surface hardness, respectively. Each group was further divided into three subgroups (1, 2, and 3) depending on the concentration, namely, PMMA without filler (control), PMMA + 10 wt.% of Al2O3, and PMMA + 15 wt.% of Al_2O_3 containing 12 samples each. Thermal conductivity was measured using a modified guarded hot plate apparatus. Flexural strength was assessed with a three-point bending test using a universal testing machine. Hardness testing was conducted using a Vickers Hardness Tester. The results were analyzed using one-way ANOVA followed by *post hoc* comparison by Tukey's method.

Results: Mean values of thermal conductivity were (in W/mK) 0.190, 0.231, and 0.275 for subgroups A1, A2, and A3, respectively. The mean flexural strength values were (in MPa) 56.62, 66.73, and 74.24 for subgroups B1, B2, and B3, respectively. Mean values of surface hardness was calculated to be (in HV) 15.17, 16.51, and 17.91 for subgroup C1, C2, and C3, respectively. There was statistically significant improvement in thermal conductivity, flexural strength, and surface hardness after incorporation of alumina and the increase was in proportion to the weight percentage of alumina filler.

Conclusion: Incorporation of alumina into heat cure denture base resin significantly improved the thermal conductivity, flexural strength, and surface hardness.

Key words: Aluminum oxide, Flexural strength, Polymethyl methacrylate denture base resin, Surface hardness, Thermal conductivity

INTRODUCTION

Loss of teeth is a matter of great concern to the majority of people. Although dental implants are increasingly used in the treatment of edentulous patients, in many cases, a conventional complete denture is still the treatment of choice due to medical or financial reasons.[1] An ideal denture base material for complete denture fabrication should have adequate mechanical and physical properties, besides biocompatibility, and esthetics.[2,3] Polymethyl methacrylate (PMMA) denture base material which has been introduced in 1937 by Dr. Walter Wright is considered to be the most popular denture base material till date.[4] It is mainly due to its advantages such as favorable working characteristics, acceptable physical and esthetic properties,

Access this article online

www.ijss-sn.com

Month of Submission : 03-2020
Month of Peer Review : 04-2020
Month of Acceptance : 05-2020
Month of Publishing : 05-2020

Corresponding Author: Dr. P M Aparna, Pookaitha House, South Chittoor P O, Ernakulam, Kerala - 682 027, India.

ease of fabrication, and cost effectiveness.[5] However, it has certain limitations including low thermal conductivity, high thermal expansion coefficient, low elastic modulus, low impact strength, and low fatigue resistance.[6]

The thermal conductivity of PMMA is approximately 0.2 W/mK.[7] This rate is almost one-third of the coefficient of thermal conductivity of most metals. From the patient's perspective, the main problem with such a low thermal conductivity is their inability to sense transient temperature changes in the oral cavity. Lack of thermal conduction to underlying mucosa can also lead to reduction of its thickness and health.[8] With metal denture base, parotid secretion seems to increase as there is increase in the temperature of palatal soft tissues.[9] However, metal denture bases have some disadvantages including increased weight, difficulty with tissue replacement in cases where substantial loss of bone has occurred, difficulty in restoring denture borders within physiologic limits, difficulty with the relining process, esthetics, and high cost.[10] Because of these disadvantages, development of acrylic-based materials with improved thermal conductivity has always been a goal.

In addition, acrylic denture base materials have poor strength including low impact and fatigue resistance.[11] Fracture of acrylic denture bases primarily occurs due to impact or fatigue failure. Fatigue failure is caused by repeated flexure over a period of time.[12] Another property that can influence the surface characteristics of acrylic resins is the hardness, which indicates the ease of trimming and finishing of a material and its resistance to in service scratching during cleaning procedures.[13] Since patients practice a wide variety of methods for cleaning dentures other than recommended by the dentist it is essential to have a high surface hardness for denture base material to reduce the rate of denture abrasion.

Efforts to improve the physical and mechanical properties of PMMA have been made by different methods. These include chemical modification of PMMA and reinforcing with other materials. Addition of fillers and fibers is a commonly used method to improve its properties. These additives include Fibers (glass fiber, polyamide fiber, polyethylene and polypropylene fibers, and natural fibers), Fillers (Metal oxides: Alumina [Al_2O_3], zirconia [ZrO_2], titanium dioxide [TiO_2]; Noble metals: Silver [Ag], nanogold [Au], platinum [Pt], palladium [Pd]; Minerals: Hydroxyapatite fillers, silicon dioxide [SiO_2], silica-based filler; and Carbon family fillers: Nanocarbon, nanodiamonds), and Hybrid fiber reinforcement.[14]

As alternatives to metal powder fillers, thermally conducting ceramics may be useful for increasing the thermal conductivity while preserving many of the advantageous qualities of acrylic resins. Recent advances in the processing of ceramics have led to the development of thermally conducting ceramics, such as sapphire (single crystal form of Al_2O_3), silicon nitride (Si_3N_4), boron nitride, and aluminum nitride.

Aluminum oxide (Al_2O_3) commonly referred to as alumina possesses strong interatomic bonding, giving rise to its desirable material characteristics. Its high hardness, excellent dielectric properties, refractoriness, and good thermal properties make it the material of choice for a wide range of applications.[15] Furthermore, these ceramic powders have the advantage of being white, and therefore are less likely to alter the finished appearance of the denture base material compared to the metal powder incorporated denture base.[5] Thus, alumina possesses various favorable properties which may improve the physical and mechanical properties of PMMA.

In this context, the present study was conducted to evaluate and compare the thermal conductivity, flexural strength, and surface hardness of heat cure acrylic resin incorporated with 10 wt.% and 15 wt.% aluminum oxide microparticles and conventional denture base resin.

MATERIALS AND METHODS

Incorporation of Al_2O_3 Particles into PMMA Heat Cure Resin

Al_2O_3 particles (nanoshel, purity – 99.9%, and average particle size – 50–60 μm) were incorporated into the polymer of heat cure acrylic resin (DPI, The Bombay Burmah Trading Corporation Ltd., Mumbai) at two different concentrations, namely, 10% and 15% by weight. Appropriate amount of Al_2O_3 and acrylic resin polymer was weighed using a digital weighing balance and mixed together using a mortar and pestle. To ensure uniform distribution of Al_2O_3 in the polymer of heat cure acrylic resin "geometric dilution" method was employed for trituration.

Fabrication of Test Specimens

The properties evaluated in this study were thermal conductivity, flexural strength, and surface hardness. Thermal conductivity testing required disk shaped specimens measuring 50 mm diameter and 5 mm thickness. For testing flexural strength and surface hardness, rectangular blocks measuring 65 mm length 10 mm width and 3 mm thickness were required. Plexiglass molds of the above-mentioned dimensions were fabricated with high precision laser cutting machine. Wax patterns were prepared from plexiglass molds and were invested in denture flask in the conventional manner. The monomer and polymer

of the heat-polymerized acrylic resin were proportioned, mixed, packed, and pressed into the mold following manufacturer's instructions and processed. Dimensions of specimens were measured by a digital Vernier caliper with a measuring accuracy of ±0.1 mm. All specimens were stored in thermostatically controlled water bath at 37±1°C for 7 days, before testing.

Distribution of Specimens [Table 1]

Thermal conductivity testing

Thermal conductivity was tested using a modified guarded hot plate apparatus. The solid disk shaped specimens were placed between the two plates of the apparatus. A thin film of heat flux sensors was positioned on either side of the sample for the measurement of heat transmitted through the sample [Figure 1]. The thin film sensor had in built type T thermocouples. Both cold and hot plate were instrumented using type K thermocouples at the interface between the sample and the plates for the measurement of temperature on the surface of the sample. The hot plate was heated using a known power and the cold plate was cooled to a constant temperature using a recirculating chiller. The temperature on both sides of the sample was monitored using type K and type T thermocouples until the entire system reaches a steady state. The power to the hot plate was selected so as to create temperature gradient of 5–10°C across the thickness of the sample which in turn was ensured by the temperature measurement.



Figure 1: Sample with instrumentation

The steady state temperatures, the thickness of the sample and the heat transfer rate (measured using thin film heat flux sensors) were used to calculate thermal conductivity as follows.

$$k = q\frac{dx}{dT}$$

k = Thermal conductivity, W/m-K.
q = Heat flux, W/m^2.
dx = Thickness of the sample, m.
dT = $T_{cold} - T_{hot}$ = Temperature gradient across the sample, °C.

Flexural Strength Testing

The flexural strengths of the specimens were evaluated according to the ISO 1567, 1999, for denture base resins, by three-point bending test using universal testing machine (INSTRON). The rectangular specimens were inserted in relative points on the testing machine such that the span length was 50 mm. The specimens were centered on the device in such a way that the loading wedge, set to travel at a crosshead speed of 5 mm/min, engages the center of the upper surface of the specimen [Figure 2]. Specimens were loaded until fracture occurred.

Flexural strength was calculated using the following equation.

$$S = \frac{3PI}{2bd^2}$$

S: Flexural strength.
P: load at fracture.
I: distance between supporting wedges.
b: width of specimen.
d: thickness of specimen.

Table 1: Distribution of specimens

Group	Measured property	Shape of specimens	Subgroup	Description	Number of specimens
Group A	Thermal conductivity	Disc (50×5)	A1	PMMA (control)	12
			A2	PMMA + 10 wt.% AL_2O_3	12
			A3	PMMA + 15 wt.% AL_2O_3	12
Group B	Flexural strength	Rectangular (65×10×3)	B1	PMMA (Control)	12
			B2	PMMA + 10 wt.% AL_2O_3	12
			B3	PMMA + 15 wt.% AL_2O_3	12
Group C	Surface hardness	Rectangular (65×10×3)	C1	PMMA (Control)	12
			C2	PMMA + 10 wt.% AL_2O_3	12
			C3	PMMA + 15 wt.% AL_2O_3	12
Total					108

PMMA: Polymethyl methacrylate

Surface Hardness Testing

A Vickers Hardness Tester (HMV SCHIMADZO, model – HMV 2T ADW) was used to evaluate the surface hardness. To determine Vickers values, a load of 25 gram-force (gf) was applied for 15 s to specimens using a Vickers Hardness Tester [Figure 3]. Each specimen was subjected to three indentations (one at the center and two at the border), and the average hardness (HV) value was calculated.

RESULTS

Data were analyzed using computer software, Statistical Package for the Social Sciences (SPSS) version 16.0. Data were expressed in its mean and standard deviation. Analysis of variance (one-way ANOVA) was performed as parametric test to compare different groups. To facilitate multiple comparisons between groups, Tukey's method was employed as a *post hoc* test along with ANOVA. For all statistical evaluation, a two-tailed probability of value, <0.05 was considered significant.

Graphical representation of the mean values of thermal conductivity, flexural strength, and surface hardness is shown in Graphs 1-3, respectively.



Figure 2: Specimen being tested for flexural strength



Figure 3: Specimen being tested for surface hardness

Mean and standard deviation values of the thermal conductivity of subgroup A1, A2, and A3 are presented in Table 2. As per this study, maximum mean thermal conductivity was given by PMMA modified by adding 15 wt.% alumina. One-way ANOVA showed a statistically significant difference between mean values [Table 3]. Multiple comparisons with *post hoc* by Tukey's method revealed that comparison between subgroups (A1 and A2), (A1 and A3), and (A2 and A3) were statistically significant as $P < 0.001$ [Table 4].

Mean and standard deviation values of flexural strength of subgroup B1, B2, and B3 are presented in Table 5. Maximum flexural strength values were given by PMMA modified by adding 15 wt.% alumina and the least values were given by unmodified PMMA. One-way ANOVA showed a statistically

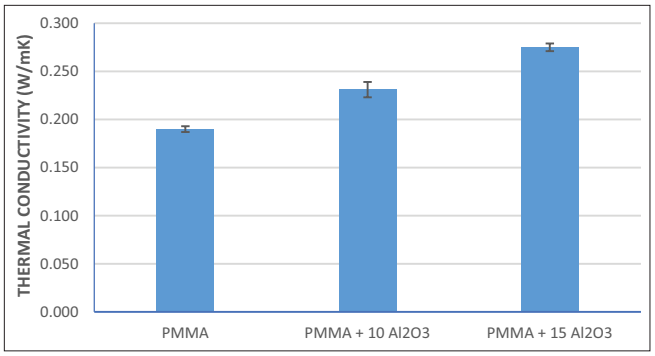

Graph 1: Comparison of mean values of thermal conductivity

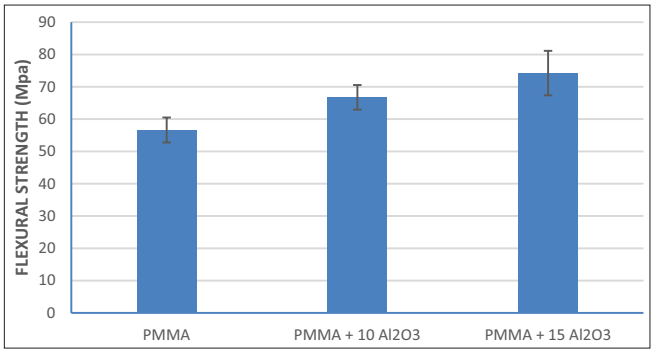

Graph 2: Comparison of mean values of flexural strength

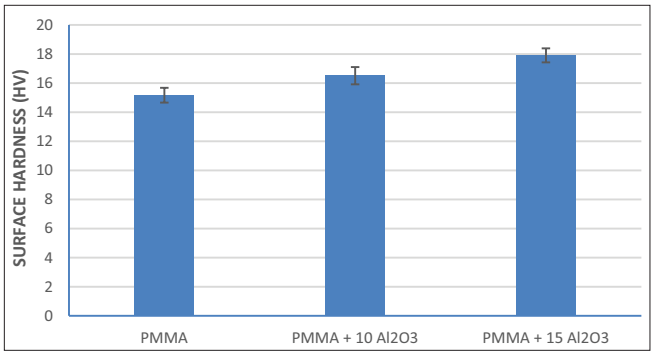

Graph 3: Comparison of mean values of surface hardness

Table 2: Mean and standard deviation of the thermal conductivity of three subgroups

Subgroup	*n*	Thermal conductivity (W/mK)	
		Mean	Standard deviation
A1	12	0.190	0.003
A2	12	0.231	0.008
A3	12	0.275	0.004
Total	36	0.232	0.036

Table 3: Comparison of the thermal conductivity among three subgroups using one-way ANOVA

ANOVA	Sum of squares	Degrees of freedom	Mean Square	F	*P*
Between groups	0.043	2	0.022	776.305	<0.001
Within groups	0.001	33	0		
Total	0.044	35			

Table 4: Inter group comparison of thermal conductivity among the three subgroups using Tukey *post hoc* test

Inter group comparison	Mean difference	Standard error	*P*
A1 versus A2	.0414	0.002	<0.001
A1 versus A3	.0850	0.002	<0.001
A2 versus A3	.0435	0.002	<0.001

Table 5: Mean and standard deviation of flexural strength of three subgroups

Subgroup	*n*	Flexural strength (MPa)	
		Mean	Standard deviation
B1	12	56.62	3.86
B2	12	66.73	3.81
B3	12	74.24	6.88
Total	36	65.86	8.82

Table 6: Comparison of flexural strength among three subgroups using one-way ANOVA

ANOVA	Sum of squares	Degrees of freedom	Mean square	F	*P*
Between groups	1877.277	2	938.639	36.703	<0.001
Within groups	843.928	33	25.574		
Total	2721.206	35			

Table 7: Inter group comparison of flexural strength among the three subgroups using Tukey *post hoc* test

Inter group comparison	Mean difference	Standard error	*P*
B1 versus B2	10.1083	2.0645	<0.001
B1 versus B3	17.6250	2.0645	<0.001
B2 versus B3	7.5167	2.0645	0.003

Table 8: Mean and standard deviation of the surface hardness of three subgroups

Subgroup	*n*	Surface hardness (HV)	
		Mean	Standard deviation
C1	12	15.17	0.51
C2	12	16.51	0.59
C3	12	17.91	0.48
Total	36	16.53	1.25

Table 9: Comparison of surface hardness among three subgroups using one-way ANOVA

ANOVA	Sum of squares	Degrees of freedom	Mean square	F	*P*
Between Groups	45.107	2	22.554	80.522	<0.001
Within Groups	9.243	33	0.28		
Total	54.35	35			

significant difference between mean values [Table 6]. *Post hoc* comparison of flexural strength values between the subgroups B1, B2, and B3 was performed using Tukey's method [Table 7]. The comparison between B1 and B2 showed a mean difference of 10.1083 and that change is statistically significant with $P < 0.001$. The comparison between B1 and B3 showed a mean difference of 17.6250 which is also statistically significant with $P < 0.001$. The comparison between B2 and B3 showed a mean difference of 7.5167 and that change is also statistically significant with $P = 0.003$.

Mean and standard deviation values of surface hardness of subgroup C1, C2, and C3 are given in Table 8. Maximum values of surface hardness were given by PMMA modified by adding 15 wt.% alumina. One-way ANOVA showed a statistically significant difference between mean values [Table 9]. Multiple comparisons with *post hoc* by Tukey's method revealed that comparison between subgroups (C1 and C2), (C1 and C3), and (C2 and C3) was statistically significant as $P < 0.001$ [Table 10].

DISCUSSION

PMMA has been the material of choice for the fabrication of dentures since 1930s because of its advantages such as favorable working characteristics, acceptable physical and esthetic properties, ease of fabrication, and cost effectiveness.[5] However, it cannot be considered as an ideal denture base material due to its inferior thermal and mechanical properties.

The thermal conductivity of PMMA is approximately 3 times lower than that of metals.[15] Various methods have been considered so far for increasing the thermal conductivity of denture base to provide the maximum

Table 10: Inter group comparison of surface hardness among the three subgroups using Tukey *post hoc* test

Inter group comparison	Mean difference	Standard error	*P*
C1 versus C2	1.34167	0.216	<0.001
C1 versus C3	2.74167	0.216	<0.001
C2 versus C3	1.40000	0.216	<0.001

gustatory response. One method is the replacement of acrylic denture base with metallic base. However, the use of metal as a denture base material has several disadvantages including increased weight of the denture, difficulty with the relining process, esthetics, and high cost.[15] Even though metallic denture bases have better thermal conductivity they are not widely used because of their relatively high cost. Another approach for improving thermal conductivity of denture base resin is to incorporate a material having better thermal conductivity. In addition to improvement in thermal conductivity, they also influence some of the mechanical properties.

Ellakwa *et al.*[15] investigated the effect of adding different proportions of aluminum oxide powder on the flexural strength and thermal diffusivity of heat-polymerized acrylic resin. Thermal diffusivity was found to increase in proportion to the weight percentage of alumina filler while the flexural strength shows significant increase up to incorporation of 15% followed by a reduction with 20%. Messersmith *et al.*[5] reported that thermal diffusivity of denture base resin was increased by the addition of thermally conducting sapphire whiskers at concentrations of 9.35 and 15%.

As alternatives to metal powder fillers, thermally conducting ceramics such as alumina may be useful for increasing the thermal conductivity while preserving many of the advantageous qualities of acrylic resins.[15] Most of the studies showed significant improvement in thermal conductivity with the incorporation of alumina. Along with thermal conductivity, alumina incorporation also resulted in significant improvement of flexural strength. However, the optimum concentration of reinforcement varied among authors.

Aluminum oxide (Al_2O_3), commonly referred to as alumina, possesses strong ionic interatomic bonding resulting in its desirable material characteristics. It can exist in several crystalline phases, which all revert to the most stable hexagonal alpha phase at elevated temperatures. Alpha phase alumina is the strongest and stiffest of the oxide ceramics. Its high hardness, excellent dielectric properties, refractoriness, and good thermal properties make it the material of choice for a wide range of applications.[15] The biocompatibility of aluminum has been shown by Kawahara *et al.*[16] The ceramic filler as opposed to metal filler has lower filler density. Thus, the weight of acrylic resin denture bases does not increase significantly. In addition, the ceramic powder being white is less likely to alter the final appearance of the denture base when compared to the metal powder incorporated denture base.[15]

The present study was conducted by the incorporation of alumina into the denture base resin at two different concentrations that matches with the majority of the previous studies. One of the popular commercially available denture base resins (DPI, The Bombay Burmah Trading Corporation Ltd., Mumbai) was modified by incorporating 10 wt.% and 15 wt.% of alumina microparticles. Geometric dilution was employed for the uniform distribution of alumina in the PMMA polymer. Along with thermal conductivity, flexural strength and surface hardness were also assessed in this study as these two parameters are important for an extended clinical service life of the prosthesis.

As endorsed by other authors, this investigation has also showed that addition of alumina increased the thermal conductivity of PMMA and this increase was proportional to the concentration of filler. PMMA modified with 15wt.% of alumina showed the highest mean thermal conductivity of 0.275±0.004W/mK. These results were in agreement with the studies by Ellakwa *et al.*[15] The improvement in thermal conductivity on addition of alumina can be attributed to the formation of thermally conducting pathways within the polymer matrix. This may be due to overlapping of thermal conductive particles inside the polymer matrix to bridge the insulating effect of PMMA matrix. The increase in the amount of fillers make the particles approximate and overlap each other forming conductive pathways and permit transition of heat from one side of the specimen to its opposite side thus increasing thermal conductivity.[17]

In addition to the increased temperature and taste perception, the increase in thermal conductivity could also minimize the development of porosities in the denture base resin. Since PMMA is a poor thermal conductor, the heat generated in thick segments of the denture base during polymerization cannot be dissipated. When heating is poorly controlled, the peak temperature of this resin can rise well above the boiling point of monomer and can cause boiling of unreacted monomer thereby causing porosity within the processed denture base. With the incorporation of alumina into PMMA, thermal conductivity is improved allowing the temperature to dissipate thereby reducing porosity.

This study also compared the flexural strength of unmodified resin and alumina incorporated resin. High flexural strength is crucial for denture wearing success, as alveolar resorption is a gradual and irregular process that leaves tissue-borne prostheses unevenly supported. Such dentures flex in the mouth around the midline during function and repeated occlusal loadings during mastication lead to the fatigue fracture.[12] There was also a significant improvement in flexural strength on addition of alumina into PMMA resin. This increase in flexural strength was proportional to the concentration of alumina particles. PMMA reinforced with 15 wt.% showed highest mean flexural strength (74.24 MPa).

These results were in agreement with the studies conducted by Ellakwa *et al.*[15] and Saritha *et al.*[18] Improved flexural strength could be attributed to uniform distribution of the filler particles within the matrix and transformation toughening. When sufficient stress develops and micro-cracks begin to propagate, the transformation phenomenon occurs, which depletes the energy for crack propagation. Therefore, proper distribution of the filler within the matrix can stop or deflect cracks.[17] However, certain studies have also proposed a reduction in flexural strength on incorporation of alumina at higher concentrations. Ellakwa *et al.*[15] showed that by increasing the filler loading to 20 wt.% there was substantial reduction in the flexural strength. Vojdani *et al.*[11] found that addition of 5wt% Al_2O_3 decreased mean flexural strength significantly. This reduction in flexural strength on increase in filler concentration could be attributed to decrease in cross section of load bearing polymer matrix; stress concentration because of too many filler particles; changes in the modulus of elasticity of the resin and mode of crack propagation through the specimen due to an increased amount of fillers; incomplete wetting of the fillers by the resin; and the fact that alumina acts as an interfering factor in the integrity of the polymer matrix.[19]

The decrease in flexural strength of PMMA with increased filler content could be overcome by treating the filler with coupling agent to ensure better wettability of the filler. Coupling agents provide good interfacial bond between the filler and resin matrix. These may provide an intermediate layer at the filler matrix interface. This layer may change the pattern and reduce magnification of stress.[8] In the present study, an improvement in flexural strength was noted with increasing the filler loading even without the use of silane coupling. This could be attributed to the uniform distribution of filler particles within the resin matrix.

Since aluminum oxide also possesses high hardness due to the high ionic interatomic bonding, the possibility of improvement in surface hardness through the incorporation of alumina was also investigated. There was a significant increase in the surface hardness of alumina incorporated PMMA. This finding is in agreement with the previous investigators, who have concluded that reinforcing dental restorative resins and acrylic resin with ceramic particles can produce some improvements in the surface hardness. This increase in hardness may have been due to the inherent characteristics of alumina. The most stable hexagonal alpha phase of Al_2O_3 is the strongest and stiffest of the oxide ceramics. Therefore, it is expected when Al_2O_3 particles are dispersed in a matrix, they increase its hardness and strength.[15]

The white color of alumina is not expected to adversely affect the esthetic appearance of denture base resin; however, the translucency was adversely affected as concentration of alumina increased. The decrease in translucency obtained in this study may be attributed to differences in the optical properties of the alumina and acrylic resin and its distributions within the resin matrix. Hence, further studies are required to find out the optimum concentration of alumina that would not adversely affect the optical property of acrylic denture base resin.

Aluminum oxide particles used in this study were microparticles rather than the highly expensive nanoparticles. Furthermore, favorable mechanical and thermal properties have been achieved with untreated alumina particles in this study without additional procedure of silanization. The study also has certain limitations. The results of the study were limited to two concentrations of the alumina (10 and 15 wt.%). Further research is needed to quantify the optimum filler distribution in the polymer matrix. Changes in only three properties (thermal conductivity, flexural strength, and surface hardness) were evaluated in this study. Elaborate research is needed to examine other physical and mechanical properties. The effect of aging on these reinforced denture base materials also needs to be evaluated. As this was an *in vitro* study, a direct correlation to the clinical situation could not be established. Long-term clinical studies and studies based on patient satisfaction also need to be conducted before prescribing alumina incorporated PMMA for denture fabrication.

CONCLUSION

Within the limits of the study, the following conclusions were drawn:

1. Incorporation of alumina significantly improved the thermal conductivity, flexural strength, and surface hardness of heat cure denture base resin
2. Magnitude of increase in these properties was proportional to the concentration of alumina incorporated.

REFERENCES

1. Carlsson GE, Omar R. The future of complete dentures in oral rehabilitation. A critical review. J Oral Rehabil 2010;37:143-56.
2. Chand P, Patel CB, Singh BP, Singh RD, Singh K. Mechanical properties of denture base resins: An evaluation. Indian J Dent Res 2011;22:180.
3. Meng TR, Latta MA. Physical properties of four acrylic denture base resins. J Contemp Dent Pract 2005;6:93-100.
4. John J, Gangadhar SA, Shah I. Flexural strength of heat-polymerized polymethyl methacrylate denture resin reinforced with glass, aramid, or nylon fibers. J Prosthet Dent 2001;86:424-7.
5. Messersmith PB, Obrez A, Lindberg S. New acrylic resin composite with improved thermal diffusivity. J Prosthet Dent 1998;79:278-84.
6. Eichhold WA, Woelfel JB. Denture base acrylic resins: Friend or foe? Compendium (Newtown, PA) 1990;11:720-5.
7. McCabe JF, Walls AW. Applied Dental Material. 9th ed. London: Black Well Scientific Publication; 2008. p. 110-23.
8. Yadav P, Mittal R, Sood VK, Garg R. Effect of incorporation of silane-treated silver and aluminum microparticles on strength and thermal conductivity of PMMA. J Prosthodont 2012;21:546-51.
9. Kapur KK, Fischer EE. Effect of denture base thermal conductivity on gustatory response. J Prosthet Dent 1981;46:603-9.
10. Tandon R, Gupta S, Agarwal SK. Denture base materials: From past to future. Indian J Dent Sci 2010;2:33-9.
11. Vojdani M, Bagheri R, Khaledi AA. Effects of aluminum oxide addition on the flexural strength, surface hardness, and roughness of heat-polymerized acrylic resin. J Dent Sci 2012;7:238-44.
12. Kelly E. Fatigue failure in denture base polymers. J Prosthet Dent 1969;21:257-66.
13. Powers JM, Sakaguchi RL. Craig's Restorative Dental Materials. 12th ed. Amsterdam, Netherlands: Elsevier; 2006. p. 79.
14. Gad MM, Fouda SM, Al-Harbi FA, Näpänkangas R, Raustia A. PMMA denture base material enhancement: A review of fiber, filler, and nanofiller addition. Int J Nanomed 2017;12:3801.
15. Ellakwa AE, Morsy MA, El-Sheikh AM. Effect of aluminum oxide addition on the flexural strength and thermal diffusivity of heat-polymerized acrylic resin. J Prosthodont 2008;17:439-44.
16. Kawahara H, Yamagami A, Nakamura M. Biologic testing of dental materials by means of tissw culture. Int Dent J 1968;l8:443-67.
17. Arora P, Singh SP, Arora V. Effect of alumina addition on properties of polymethylmethacrylate a comprehensive review. Int J Biotech Trends Technol 2015;9:1-7.
18. Saritha MK, Shadakshari S, Nandeeshwar DB, Tewary S. An *in vitro* study to investigate the flexural strength of conventional heat polymerised denture base resin with addition of different percentage of aluminium oxide powder. Asian J Med Clin Sci 2012;1:80-5.
19. Sehajpal SB, Sood VK. Effect of metal fillers on some physical properties of acrylic resin. J Prosthet Dent 1989;61:746-51.

How to cite this article: Aparna PM, Kumar KH, Ravichandran R, Nair VV, Zeenath H, Manjuran NG. Comparison of Thermal Conductivity, Flexural Strength, and Surface Hardness of Alumina Incorporated and Conventional Heat-Activated Denture Base Resins. Int J Sci Stud 2020;8(2):64-71.

Source of Support: Nil, **Conflicts of Interest:** None declared.

Print ISSN: 2321-6379
Online ISSN: 2321-595X

Original Article

Efficacy of Potassium Chloride 0.2 mmol as Adjuvant to 0.5% Ropivacaine versus Plain Ropivacaine 0.5% in Supraclavicular Brachial Plexus Block

Yerramsetti Atchyutha Ramaiah[1], Snehalatha Bhashyam[2], T Prem Sagar[3]

[1]Assistant Professor, Department of Anesthesiology and Critical Care, Rangaraya Medical College, Kakinada, Andhra Pradesh, India,
[2]Assistant Professor, Department of Anesthesiology and Critical Care, Rangaraya Medical College, Kakinada, Andhra Pradesh, India,
[3]Professor, Department of Anesthesiology and Critical Care, Rangaraya Medical College, Kakinada, Andhra Pradesh, India

Abstract

Background: Brachial plexus block is one of the most common regional anesthetic techniques used for upper limb surgeries. Various adjuvants have been tried for prolonging the duration of post-operative analgesia and also to enhance the quality of block. We aimed to study the effects of the addition of potassium chloride to ropivacaine in supraclavicular brachial plexus block compared to plain ropivacaine.

Materials and Methods: This prospective, randomized, double-blind, and controlled study includes 80 adult patients aged between 20 and 60 years with ASA Grade I and II scheduled for upper limb surgeries. These patients were randomly allocated into two groups of 40 each. The patients in the group I/non-KCL group received 30 ml of 0.5 % ropivacaine along with 1 ml normal saline (control group). Group II/KCL group received 30 ml of 0.5% ropivacaine along with 0.2 mmol (0.1 ml) of potassium chloride (prepared by adding 0.1 ml of potassium chloride diluted with normal saline to make a volume of 1 ml) (study group). The onset, duration of sensory and motor blockade, quality of sensory and motor blockade, and the duration of post-operative analgesia were compared between both the groups.

Results: The onset of sensory and motor blockade was earlier in Group II/ study group when compared to plain ropivacaine group/Group I and was statistically significant with a $P < 0.05$. The mean duration of sensory and motor blockade was prolonged in Group II with enhanced quality of analgesia compared to Group I.

Conclusion: In our study, it concludes that the addition of potassium chloride as an adjuvant to ropivacaine had a significant clinical advantage over plain ropivacaine on the onset, duration, quality of sensory and motor blockade, and post-operative analgesia in supraclavicular brachial plexus block.

Key words: Adjuvants, Potassium chloride, Ropivacaine, Supraclavicular brachial plexus block

INTRODUCTION

Peripheral nerve blocks have become a well-accepted component of regional anesthetic techniques, especially for upper limb surgeries over the past decade to abolish pain which is an unpleasant sensory and emotional impact that leads to actual or potential tissue damage.[1,2] The gate theory of pain was invented by Melzack and Wall in 1965.[3] Halsted, first performed the brachial plexus nerve block using a cocaine solution.[4] It has its potential advantages over general anesthesia with rare complications when correct technique and reasonable precautions like the use of ultrasound are exercised.[5,6] Previously used amino-ester local anesthetics lost their importance because of their short duration of action in addition to associated allergic reactions and systemic toxicity. There are continuous efforts to prolong the duration of brachial plexus blockade beyond

Access this article online

www.ijss-sn.com

Month of Submission : 03-2020
Month of Peer Review : 04-2020
Month of Acceptance : 05-2020
Month of Publishing : 05-2020

Corresponding Author: Dr. Snehalatha Bhashyam, H.NO: 8-11-18/1, Opp.: Indian Red Cross Society, Red Cross Street, Gandhinagar, Kakinada - 533 004, Andhra Pradesh, India.

the duration of local anesthetics and to overcome these drawbacks. These strategies include placement of indwelling perineural catheters to allow prolonged continuous infusion (or) the co-administration of adjuvants such as sodium bicarbonate,[7] potassium chloride,[7] vasoconstrictors,[8] opioids, the addition of enzymes,[9] enhancing blockade by pain and muscular exercise,[10] warming up of local anesthetic solutions,[11] α-2 agonists like clonidine,[12] dexmedetomidine,[13] midazolam, and dexamethasone[14] with varying degree of success. It is widely believed that the addition of potassium chloride improves the quality and duration of peripheral nerve block over when the local anesthetic was used alone. Various studies were done using potassium chloride as an adjuvant with 0.5% bupivacaine. Ropivacaine a commonly used amide local anesthetic is a first single enantiomer specific compound with reduced cardiotoxicity and neurotoxicity. However, post-operative pain relief and delayed onset of action is an issue. Hence, we aimed to compare the effects of adding potassium chloride to 0.5% ropivacaine to accentuate early-onset and prolong the duration of sensory and motor blockade following supraclavicular brachial plexus block in a group of patients undergoing upper limb surgeries.

MATERIALS AND METHODS

This prospective randomized and double-blind study was conducted in the orthopedic operation theater, Govt. General Hospital, Kakinada attached to Rangaraya Medical College between January 2019 and September 2019. After obtaining Institutional Ethical Committee approval and informed written consent. Eighty adult patients belonging to ASA Grade I and II, of both sexes, aged between 20 years and 60 years were taken up for the study.

Inclusion Criteria

The following criteria were included in the study.

1. Adult patients between 20 and 60 years of age
2. Patents belonging to ASA Grade I and II
3. Elective surgeries on the upper limb.

Exclusion Criteria

The following criteria were excluded from the study.

1. Refusal by patient
2. History of bleeding disorders or patients on anticoagulant therapy
3. History of active neurological, cardiac, respiratory, and renal diseases
4. Burns/local infection
5. Hyperkalemia, severe kidney or liver dysfunction, and respiratory disease
6. Known allergy to local anesthetic drugs
7. Pregnancy
8. Nerve injury
9. Peripheral neuropathy
10. Patient with ASA Grade III and IV
11. Weight <50 kg or >100 kg.

The patients satisfying the above criteria are subjected to the study and are randomly assigned into two groups of 40 each by computer-generated random numbers.

Group I/non-KCL group	Patients received 30 ml of 0.5 % ropivacaine along with 1 ml of normal saline (control group)
Group II/KCL group	Patients received 30 ml of 0.5% ropivacaine along with 1 ml of 0.2 mmol (0.1ml) of potassium chloride (prepared by adding 0.1 ml of potassium chloride diluted with normal saline to make a volume of 1 ml) (study group)

The study drug was prepared by an anesthetist who is not involved in the study. Being a double-blinded study, the anesthesiologist performing the procedure and the observer collecting the data were blinded to the drug administered. A pre-anesthetic evaluation was done for every patient and the procedure was explained along with visual analog scale (VAS) 0–10 and informed written consent was obtained preoperatively. All the necessary investigations were done.

Patients were shifted to the operation theatre and all the standard monitors such as non-invasive blood pressure, pulse oximeter, and electrocardiography monitors were connected. Baseline parameters such as oxygen saturation (SpO2), heart rate, and non-invasive blood pressure were recorded. Intravenous line secured limb and intravenous fluid started. All the patients were premedicated with injection midazolam 1 mg intravenously. After placing the patient in the supine position with face turned toward the contralateral shoulder, under aseptic precautions and the ultrasound guidance, using a high-frequency linear probe in optimum short-axis view, brachial plexus is identified, as round or oval hypoechoic structures (a bunch of grapes) lying posterolateral to the subclavian artery. Brachial plexus block was given by the supraclavicular approach. Neural localization was achieved by a nerve stimulator (with a current of 0.5 mA and a frequency of 2 Hz) connected to 22 G, 50 mm insulated short bevel needle (Stimuplex® HNSII, B Braun) after local infiltration with lignocaine 2%. The endpoint taken is the hand twitches elicited at the current of 0.5 mA. After negative aspiration, 31 ml of the drug with and without adjuvants was injected. Patients were monitored closely after completion of the local anesthetic injections. The onset, duration of sensory and motor blockade, quality of sensory and motor blockade, and the duration of post-operative analgesia were noted. Block is considered to have failed if sensory anesthesia was not achieved within 30 min, general anesthesia is given subsequently to those patients, and those patients are excluded from the study.

Vital parameters such as non-invasive blood pressure, pulse rate, and oxygen saturation were observed every 5 min for the first 30 min and thereafter every 15 min until the completion of surgery. The duration of surgery was noted. The time of injection was considered as 0 min. In the two groups, the following parameters were noted.

The Onset and Duration of Sensory and Motor Blockade

Onset of sensory block was taken as the time from injection of a local anesthetic to time of loss of pain on pinprick duration of sensory blockade was the time from the onset of loss of pain on pinprick to the reappearance of pain to pinprick and was checked every 3 min until the onset of loss of sensation after injection and thereafter every 30 min until the regain of sensation. The onset of motor block was taken as the time from injection of a local anesthetic to time of complete loss of movement duration of motor blockade was the time from the onset of paresis to the reappearance of motor movements and was checked every 3 min until the loss of movements and thereafter every 30 min until the regain of movements.

Sensory block was assessed by (pinprick)	Motor block was graded by (limb movement)
Grade	**Grade**
0 - No pain	5 - Normal movement of upper limb
1 - Mild pain-grimace	4 - Movement against resistance
2 - Moderate pain-withdrawal, and	3 - Movement against gravity
3 - Severe pain-screams.	2 - Movement along with gravity but not against resistance
	1 - Flickering movement and
	0 - No movement

The quality of sensory and motor block and the consumption of supplements after the block was graded as (1) complete sensory and motor blockade where supplements were not used, (2) partial sensory and motor blockade with some sparing that required supplemental drugs like opioids to continue surgery, and (3) total failure of sensory or motor blockade wherein surgery was done under general anesthesia.

Quality of Sensory Blockade

- Grade 0 – no analgesia
- Grade 1 – analgesia with dermatomal sparing
- Grade 2 – complete analgesia.

Quality of Motor Blockade

- Grade 0 – no movement
- Grade 1 – flickering movement of upper limbs
- Grade 2 – movement along with gravity, but not against resistance
- Grade 3 – movement against gravity.

Grades 3, 2, 1 were partial blocks, Grade 0 – no movement, i.e., complete motor paralysis.

Duration of Analgesia

The time between the brachial block and the first request for rescue analgesia is considered as duration of Analgesia. The duration of analgesia was noted according to 0–10 VAS for pain which was assessed every 1 h after shifting the patient to the post-operative ward. Rescue analgesia was given in the form of injection diclofenac sodium (1.5 mg/kg) intramuscularly when VAS >4. Patients were watched for bradycardia, convulsions, restlessness, disorientation, drowsiness, nausea, vomiting, and any other complications.

The sample size was calculated based on the primary outcome taken as the mean duration of analgesia with a mean difference of 4 h between the groups (observed from prior pilot observations) to detect a clinically significant variation of >25% between the groups using 5% alpha error (two-sided) and power of study being 80%; the sample size was calculated to be 37 per group (using power analysis and sample size software.com). Hence, 40 subjects were recruited in each group to compensate for dropouts.

Statistical Analysis

The collected data were subjected to statistical analysis using GraphPad.com software. Data were communicated as mean, standard deviation, and/or ratio or absolute numbers (%) and compared using Student's *t*-test, Fisher's exact test, and Chi-square test. $P < 0.05$ was considered statistically significant.

RESULTS

The present study includes 80, adult consented patients aged between 20 and 60 years, allocated into two groups of 40 each. Group I/non-KCL group received 30 ml of 0.5 % ropivacaine along with 1 ml normal saline (control group). Group II/KCL group received 30 ml of 0.5% ropivacaine along with 0.2 mmol (0.1 ml) of potassium chloride (prepared by adding 0.1 ml of potassium chloride diluted with normal saline to make a volume of 1 ml) (study

Table 1: Demographic data of the patients

Parameters	Group I	Group II	*P* value
	Mean±Std. deviation	Mean±Std. deviation	
	n=40	*n*=40	
Age in years	34.79±11.30	36.06±10.41	0.602
Weight in kg	64.71±8.48	66.15±7.97	0.436
Gender (%)			
Male	33	35	0.755*
Female	7	5	
ASA I/II	28/12	31/09	0.612*
Duration of surgery (min)	108.42±19.56	112.04±22.35	0.443

Data expressed as mean (SD) or ratio or absolute numbers, Student's *t*-test, *Chi-square test/Fisher's exact test

group) scheduled for elective upper limb surgeries under the supraclavicular approach of brachial plexus block. All the patients completed the study successfully.

Demographic data in terms of age, gender, body weight, ASA physical status, and duration of surgery were comparable between the two groups with no statistically significant difference between the two groups [Table 1].

The mean onset time of sensory and motor blockade was earlier in Group II/ KCL group which was 9.72±2.07 min and 16.85±5.91, respectively, when compared to Group I/ non-KCL group having a mean onset time of 12.04±3.92 min and 21.47±6.48 which was statistically significant with a $P < 0.05$ [Table 2] [Figure 1].

The mean duration of sensory and motor blockade in Group II/ KCL group was significantly prolonged with a mean duration of 469.17±28.07 min, and 421.57±20.07 min, respectively, when compared to Group I/non-KCL group having a sensory duration of 216.52±17.13 min and motor duration of 228.40±18.61 min which was statistically highly significant with a $P < 0.001$ [Table 2] [Figure 2].

The quality of sensory and motor block was higher in Group II/KCL than Group I/non-KCL group with a statistically significant, $P < 0.05$ [Table 3, Figures 3 and 4].

The number of supplements used in Group II/KCL was less when compared to Group I/non-KCL group. Supplements were used by 04 (10%) patients in Group II, whereas 14 (35%) members used supplements in Group I/non-KCL group [Table 4].

The mean duration of analgesia was prolonged in Group II/KCL group (517.04±28.80 min) when compared to Group I/non-KCL group (246.92±19.14 min) which was considered as statistically highly significant with a $P < 0.001$ [Table 5 and Figure 5]. Throughout the study, no side effects were observed.

DISCUSSION

Brachial plexus blockade provides the ideal operating conditions for the surgeon with good analgesia and complete muscular relaxation and sympathetic block which reduces post-operative vasospasm, pain, and edema. There are continuous efforts to prolong the duration of the Brachial plexus blockade beyond the duration of local anesthetics. Different local anesthetics alone or in combination with numerous adjuvants have been tried for a long time to prolong the duration of post-operative analgesia. Bupivacaine is a widely used regional anesthetic,[15] which, like all amide anesthetics, is well known

Table 2: Comparison of outcome parameters

Parameters	Group I	Group II	*P* value
	Mean±Std. deviation	Mean±Std. deviation	
	n=40	*n*=40	
The onset of sensory blockade (minutes)	12.04±3.92	9.72±2.07	*P*=0.001
The onset of motor blockade (minutes)	21.47±6.48	16.85±5.91	*P*=0.001
Duration sensory blockade (minutes)	216.52±17.13	469.17±28.07	*P*=0.0001**
Duration motor blockade (minutes)	228.40±18.61	421.57±20.07	*P*=0.0001**

Data expressed as mean (SD) or ratio or absolute numbers, Student's *t*-test, **Highly significant, *P*<0.001 significant

Table 3: Quality of sensory and motor blockade

Parameters	Group I	Group II	*P* value
	Mean±Std. deviation	Mean±Std. deviation	
	n=40	*n*=40	
Sensory blockade	1.871±0.338	2.00±0.00	*P*=0.018
Motor blockade	0.55±0.845	0.225±0.588	*P*=0.04

Data expressed as mean (SD) or ratio or absolute numbers, Student's *t*-test, *P*<0.05 significant

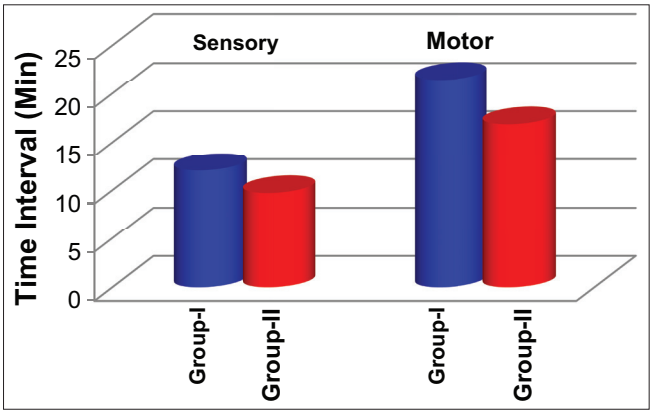

Figure 1: Onset of sensory and motor block

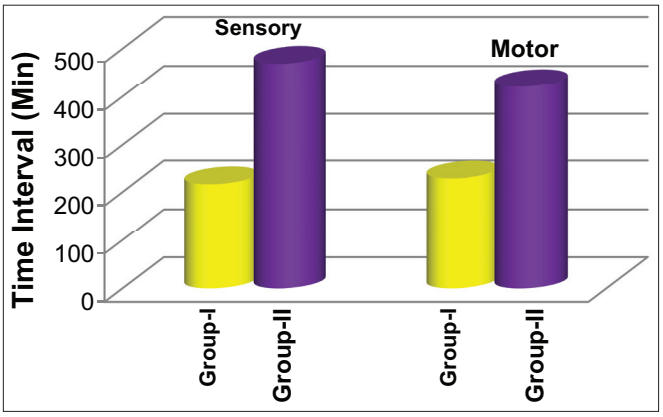

Figure 2: Duration of sensory and motor block

Table 4: Supplement used

Parameters	Group I	Group II
	Mean±Std. deviation	Mean±Std. deviation
	n=40 (%)	*n*=40 (%)
Not used	26 (65)	36 (90)
Used	14 (35)	4 (10)

Data expressed as a ratio or absolute numbers

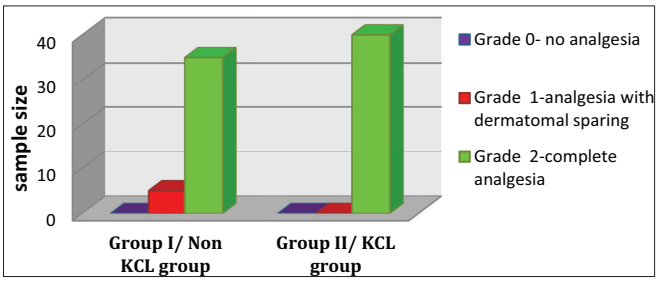

Figure 3: Quality of sensory block

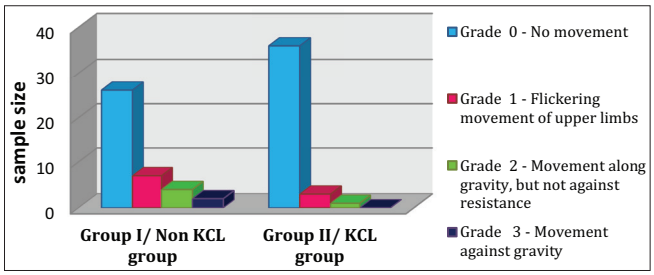

Figure 4: Quality of motor block

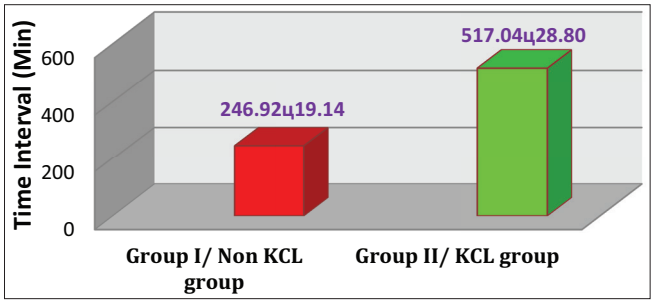

Figure 5: Mean duration of analgesia

for its cardiotoxicity when used in high concentration or with accidental intravascular administration. Ropivacaine, a local amide anesthetic is a first single enantiomer specific compound with reduced cardiotoxicity and neurotoxicity with a rapid recovery of motor function.

Potassium salt, as an adjuvant to local anesthetic, has been gaining popularity recently. Movement of ions through the nerve membrane is considered as one of the main steps in the process of excitation and propagation of nerve stimuli. A nerve impulse can be effectively blocked by the accumulation of ions outside the neuron. Thus, the administration of exogenous potassium chloride will reinforce and prolong the blockade produced by ropivacaine. It is widely believed that potassium chloride improves the quality and duration of peripheral nerve block over local anesthetic when used alone. It also improves the quality of recovery after surgery by providing an extended period of analgesia when compared with local anesthetic alone.

Ropivacaine is a long-acting local anesthetic structurally related to bupivacaine with all the assets of bupivacaine and without cardiotoxicity.[16] Hence, ropivacaine has been selected as the regional anesthetic of choice in our study for its improved quality of block and reduced potential toxicity wide margin of safety.[17]

Yasuda *et al.*[18] used a nerve stimulator and an insulated needle for supraclavicular brachial plexus block with a success rate of 98% of patients. For a similar reason, we used peripheral nerve stimulators through a supraclavicular approach to brachial plexus block in our study.

In our study, the mean onset time of sensory and motor blockade was earlier in Group II/KCL group when compared to Group I/non-KCL group with a statistically highly significant, $P < 0.001$. Our findings are inconsistent with the findings of Shivani *et al.*,[19] except that they used 0.375% bupivacaine instead of ropivacaine in their study.

Shobana and Chandrasekaran[7] study showed the addition of potassium chloride as an adjuvant to bupivacaine shortens the onset time of sensory block significantly. The result of our study is similar to their study which showed the addition of potassium chloride as an adjuvant to local anesthetic ropivacaine hastens the onset time of sensory block significantly.

Kumar *et al.*,[20] in his comparative study between bupivacaine and bupivacaine plus potassium chloride for brachial plexus block, demonstrated that 0.2 mmol of potassium chloride used as adjuvant prolonged the mean duration of sensory and motor blockade significantly. Our study also the mean duration of sensory and motor blockade was increased with 0.2 mmol of potassium chloride used as an adjuvant.

The quality of sensory and motor blockade was significantly improved in the potassium chloride group in our study. Shreedhar *et al.*[21] in their study on the effect of potassium chloride as a local anesthetic adjuvant for supraclavicular brachial plexus block for upper limb surgeries also proclaimed the addition of potassium chloride as an adjuvant improves operating quality.

The mean duration of analgesia was significantly prolonged in our study by the addition of 0.2 mmol of potassium

Table 5: Comparison of outcome parameters

Parameters	Group I	Group II	*P* value
	Mean±Std. deviation	Mean±Std. deviation	
	n=50	*n*=50	
Postoperative analgesia (minutes)	246.92±19.14	517.04±28.80	*P*=0.0001**

Data expressed as mean (SD) or ratio or absolute numbers, Student's *t*-test, **Highly significant, *P*<0.001 significant

chloride to the local anesthetic. Our result is similar to the study of Solanki *et al*.,[22] wherein the duration of post-operative analgesia is significantly prolonged by the addition of 0.2 mmol of potassium chloride.

CONCLUSION

In our study, it concludes that the addition of potassium chloride to ropivacaine quickened the onset time, prolonged the duration, and enhanced the quality of sensory and motor block compared to plain ropivacaine in supraclavicular brachial plexus block for upper limb surgeries.

ACKNOWLEDGMENTS

We are thankful to all the patients for their co-operation, and also the staff of the Department of Anesthesiology, Government General Hospital Rangaraya Medical College, Kakinada, Andhra Pradesh, for their assistance for this study.

REFERENCES

1. Aldrete JA, Barnes DR, Sidon MA, McMullen RB. Studies on the effects of the addition of potassium chloride to lidocaine. Anesth Analg 1969;48:269-76.
2. Abram SE. Chronic pain management. In: Barash PG, Cullen BF, Stoelting RK, editors. Clinical Anaesthesia. 5th ed. Philadelphia, PA: Lippincott Williams and Wilkins; 2006. p. 1449.
3. Raj PP. Chapter historical aspects of regional anaesthesia. In: Development of Regional Anaesthesia. 3rd ed. 2002. p. 23.
4. Bouaziz H, Brian PK, Macalou D, Heck M, Dap F, Benhamou D, *et al*. Sufentanil does not prolong the duration of analgesia in a mepivacaine brachial plexus block: A dose-response study. Anesth Analg 2000;90:383-7.
5. Vincent WS, Perlas A, Rawson R, Odukoya O. Ultrasound-guided supraclavicular brachial plexus block. Anesth Analg 2003;97:1514-7.
6. Klaastad Ø, Sauter AR, Dodgson MS. Brachial plexus block with or without ultrasound guidance. Curr Opin Anaesthesiol 2009;22:655-60.
7. Shobana, Chandrasekaran V. Comparative study of the efficacy of potassium chloride and sodium bicarbonate as an adjuvant to bupivacaine in supraclavicular subclavian perivascular approach of brachial plexus block. IOSR J Dent Med Sci 2016;15:116-9.
8. Bonica JJ, Backup PH, Pratt WH. The use of vasoconstrictors to prolong spinal anesthesia. Anesthesiology 1951;12:431-41.
9. Keeler JF, Simpson KH, Ellis FR, Kay SP. Effect of addition of hyaluronidase to bupivacaine during axillary brachial plexus block. Br J Anaesth 1992;68:68-71.
10. Okasha AS, El-Attar AM, Soliman HL. Enhanced brachial plexus blockade. Effect of pain and muscular exercises on the efficiency of brachial plexus blockade. Anaesthesia 1988;43:327-9.
11. Heath PJ, Brownlie GS, Herrick MJ. The latency of the brachial plexus block. The effect on the onset time of warming local anesthetic solutions. Anaesthesia 1990;45:297-301.
12. Culebras X, Van Gessel E, Hoffmeyer P, Gamulin Z. Clonidine combined with a long-acting local anesthetic does not prolong postoperative analgesia after brachial plexus block but does induce hemodynamic changes. Anesth Analg 2001;92:199-204.
13. Esmaoglu A, Yegenoglu F, Akin A, Turk CY. Dexmedetomidine added to levobupivacaine prolongs the axillary brachial plexus block. Anesth Analg 2010;111:1548-51.
14. Kumar S, Palaria U, Sinha AK, Punera DC, Pandey V. Comparative study of ropivacaine with or without dexamethasone in the supraclavicular block. Anesth Essays Res 2014;8:202-8.
15. Lund PC, Cwik JC. Bupivacaine-a new long-acting local anesthetic agent: A preliminary clinical and laboratory report. Anaesth Analog 1970;49:103-13.
16. Scott DB, Lee A, Fagan D, Bowler GM, Bloomfield P, Lundh R. Acute toxicity of ropivacaine compared with that of bupivacaine. Anesth Analg 1989;69:5639.
17. Kuthiala G, Chaudhary G. Ropivacaine: A review of its pharmacology and clinical use. Indian J Anaesth 2011;55:10410.
18. Yasuda I, Hirano T, Ojima T. Supraclavicular brachial plexus block using a nerve stimulator and an insulated needle. Br J Anaesth 1980;52:40911.
19. Shivani V, Rao G, Naik R, Hussain M. Comparative study on the onset time and duration of brachial plexus block with the addition of potassium chloride to bupivacaine versus plain bupivacaine. Asian Pac J Health Sci 2016;3:24-9.
20. Kumar GS, Srikanth D, Rao BS, Srinath M. Comparative study between bupivacaine and bupivacaine plus potassium chloride for brachial plexus block. Int J Sci Study 2017;5:42-7.
21. Shreedhar AM, Hegde BR, Patel L. Effect of potassium chloride as a local anesthetic adjuvant for supraclavicular brachial plexus block for upper limb surgeries. J Evol Med Dent Sci 2016;5:692-6.
22. Solanki N, Saran J, Kashyap M, Nanda HS. Evaluation of the post-operative analgesia in supraclavicular brachial plexus block with 0.375% plain bupivacaine+0.2 mmol potassium chloride (0.1 ml) as an adjuvant. Int J Sci Stud 2016;4:55-60.

How to cite this article: Ramaiah YA, Bhashyam S, Sagar TP. Efficacy of Potassium Chloride 0.2 mmol as Adjuvant to 0.5% Ropivacaine versus Plain Ropivacaine 0.5% in Supraclavicular Brachial Plexus Block. Int J Sci Stud 2020;8(2):72-77.

Source of Support: Nil, **Conflicts of Interest:** None declared.

Print ISSN: 2321-6379
Online ISSN: 2321-595X

Original Article

Role of Cumulative Anti-epileptic Drug Load on the Periodontal Health Tissues and Seizure Related Traumatic Oro-dental Injuries – A Comparative Cross-sectional Study in a Tertiary Health Institution in Jammu City

Nanika Mahajan[1], Palak Mahajan[2], Abhishek Khajuria[3], Bhanu Kotwal[4], Bhavana Kaul[5], Rakesh Gupta[6]

[1]Lecturer, Department of Pedodontics and Preventive Dentistry, Indira Gandhi Government Dental College, Jammu, Jammu and Kashmir, India, [2]Research Sc holar, Department of Computer Science and IT, University of Jammu, Jammu, Jammu and Kashmir, India, [3]Resident, Department of Dentistry, Government Medical College, Kathua, Jammu and Kashmir, India, [4]Lecturer, Department of Periodontics, Indira Gandhi Government Dental College, Jammu, Jammu and Kashmir, India, [5]Associate Professor, Pedodontics and Preventive Dentistry, Indira Gandhi Government Dental College, Jammu, Jammu and Kashmir, India, [6]Professor, Pedodontics and Preventive Dentistry, Indira Gandhi Government Dental College, Jammu, Jammu and Kashmir, India

Abstract

Introduction: Epilepsy is one of the most common neurological disorders. Recurrent episodes of seizures put patients at a higher risk of suffering orofacial injuries. The anti-epileptic drugs (AEDs) used to control seizures have been found to cause many adverse effects in the oral cavity.

Objective: The objective of the study was to assess the role of AEDs on dental health and frequency of seizure related head and intra-oral traumatic injuries.

Study Design/Materials and Methods: A comparative study was conducted between epileptic children and a control group which was formed from non-epileptic patients. The two groups were compared with regard to side effects of AEDs and orodental injuries. For statistical analysis, Pearson's Chi-square test was used to evaluate the correlation between the two groups.

Results: The common oral side effects of AED drugs seen were xerostomia, gingivitis, gingival hyperplasia, and glossitis. The epilepsy patients significantly showed more AED side effects as well as more trauma. The most common intra-oral injuries seen in epilepsy group were lips/cheek bite 28.7%, tongue injuries 33%, tooth cracked 37%, and tooth fracture 25.3%. Some children witnessed temporomandibular joint injuries, nose fractures, eye socket trauma, and even skull crack.

Conclusion: Epileptic children under medication had poor oral hygiene and an increased risk of gingival enlargement. Traumatic injuries to face and teeth are more common in patients with epilepsy. It is essential that dentists should be well versed with the side effects related to all AEDs, particularly belonging to the newer generation. It is necessary to provide prophylactic management to prevent oral trauma.

Key words: Anti-epileptic drugs, Epilepsy, Gingival hyperplasia, Oral trauma, Seizures

Access this article online

IJSS

www.ijss-sn.com

Month of Submission : 03-2020
Month of Peer Review : 04-2020
Month of Acceptance : 05-2020
Month of Publishing : 05-2020

INTRODUCTION

The overall prevalence of epilepsy in general population is 0.9%. Epilepsy is a chronic disorder of brain with unpredictably recurring seizures. According to International League Against Epilepsy, epilepsy is diagnosed when a person has two or more unprovoked seizures.[1] A seizure is

Corresponding Author: Dr. Nanika Mahajan, Department of Pedodontics and Preventive Dentistry, Indira Gandhi Government Dental College, Jammu, Jammu and Kashmir, India.

classified as "partial" when the electric discharge causing it occurs in a specific area of the brain or "generalized" when the discharge affects the entire brain cortex. When there is loss of awareness, seizures are termed complex [Table 1]. The classification of epilepsy is similar. Epilepsy can be partial or generalized. When the specific etiology is not known for certain, these cases are defined as idiopathic or primary epilepsy. When the etiology of seizures is known, the condition is known as secondary or acquired epilepsy.[2,3]

The first episode of seizure usually requires the need for diagnosis. The physician must rule out whether the seizure is in fact a real seizure or some other condition. The other conditions included in the differential diagnosis are syncope, migraine headaches, strokes, or transient ischemic attacks and non-epileptic events (or pseudoseizures), seen in association with such psychiatric conditions as conversion disorder, anxiety, and depression. There are three primary steps in the diagnosis of epilepsy: Health history taking, neurological examination, and laboratory testing. Depending on the history and examination findings, laboratory work may be ordered. This may include blood tests and special diagnostic tests such as electroencephalogram, computed tomography, magnetic resonance imaging, positron emission tomography, neuro sonography, and lumber puncture.[2]

Table 1: Simplified version of the classification of seizures according to the International League Against Epilepsy[1]

Partial seizures
Simple partial seizures (awareness not impaired) • with minor signs (focal motor, versive, phonatory) • with somatosensory or special-sensory symptoms (somatosensory, visual, auditory, olfactory, gustatory) • with autonomic symptoms • with psychic symptoms (déjà vu, illusions, hallucinations) Complex partial seizures • with simple partial onset followed by impairment of awareness • with impairment of awareness at onset Partial seizures evolving to secondarily generalized seizures • simple partial seizures evolving to generalized seizures • complex partial seizures evolving to generalized seizures • simple partial seizures evolving to complex partial and then to generalized seizures
Generalized seizures
Absence seizures Myoclonic seizures Clonic seizures Tonic seizures Tonic–clonic seizures Atonic seizures
Unclassified seizures

The main treatment options for epileptic patients are anti-epileptic drugs (AEDs), surgical treatments or vagus nerve stimulation. The type and severity of the disorder decides the treatment option to be chosen. If the seizures cannot be controlled by the medications, surgical interventions are considered.[3] However, despite successful surgical treatments, most patients remain on AEDs. More than 15 AEDs have been approved for the epileptic treatment by America and Europe.[4]

Earlier, a single AED was administered to manage the disorder but today, a combined regimen is being used to ensure better results. The classical AEDs include phenytoin (PHT), phenobarbital (Pb), sodium valproate (VPA), carbamazepine (CBZ), ethosuximide, and the diazepam family.

Most of the literature stresses on the AEDs and its effects on tooth supporting structures. The epileptic patients often become dental patients, as these patients are more prone to oral health problems. The reasons for that are particularly xerostomia, and gingival hyperplasia related to AEDs (PHT, Pb, and CBZ) administration. These drugs alter the metabolism and increase the removal of Vitamin D from the body, contributing to osteopenia and osteomalacia, which predispose individuals to teeth and adjacent soft-tissue injuries.[5,6] Current recommendations for the pharmacological antiepileptic treatment in Poland do not include the use of PHT as a drug of choice.[7-9] A different situation is in India, the United States, and the United Kingdom where it is usually recommended.[10-12]

Children who experience seizures are prone to traumatic injuries within the facial skeleton.[13-16] Hence, the study was carried out to evaluate the oral side effects of AEDs, the seizure related injuries of the oral cavity and also, the associated dental treatment needs.[17-20]

MATERIALS AND METHODS

A cross-sectional comparative study was carried out on 600 consecutive epileptic patients visiting the outpatient department of the Department of Pedodontics and Preventive Dentistry of a tertiary care, Government Medical College in Jammu city from March 2019 to February 2020.

Inclusion Criteria

Children aged (5–14 years) diagnosed with epilepsy according to the definition of epilepsy given by the Commission on Epidemiology and Prognosis, International League Against Epilepsy and were under anti-epileptic medication for at least 1 year (as per patients' case records) before the day of dental examination.

Exclusion Criteria

The following patients were excluded from the study: Patients who

1. Were currently not taking any medication
2. Had started the medication less than a year
3. Had only febrile seizures or only neonatal seizures
4. Were on other medications known to cause gingival overgrowth.

A comparative study was conducted between 300 epileptic children and a control group of 300 which was formed from non-epileptic patients.

The oral examination was carried out by a single dentist (S.S.Y) to limit intra-examiner variability. The oral examination was carried out to assess the various oral side effects of AEDs and oro-dental traumatic injuries. The oral side effects included xerostomia, gingival hypoplasia, gingivitis, and glossitis. The intra-oral traumatic injuries which were taken into consideration were lip, cheek and tongue injuries, tooth fracture, temporomandibular joint (TMJ) injuries, nose fracture, eye – socket trauma, and skull crack.

The two groups were compared with regard to side effects of AEDs and oro-dental injuries. For statistical analysis, Pearson's Chi-square test was used to evaluate the correlation between the two groups.

Informed and written consent was taken from parents/guardians in English/local language (Urdu) before the examination.

RESULTS

The cause of epilepsy in most of the patients with epilepsy in the present study was unknown. The AEDs assessed were PHT, CBZ, Pb, and VPA. Mono AED drug therapy was mostly prescribed by the physicians, a few were on dual therapy [Figure 1]. Rarely three or four drug regimen was prescribed.

The common oral side effects of AED drugs seen were xerostomia, gingivitis, gingival hypoplasia, and glossitis [Table 2].

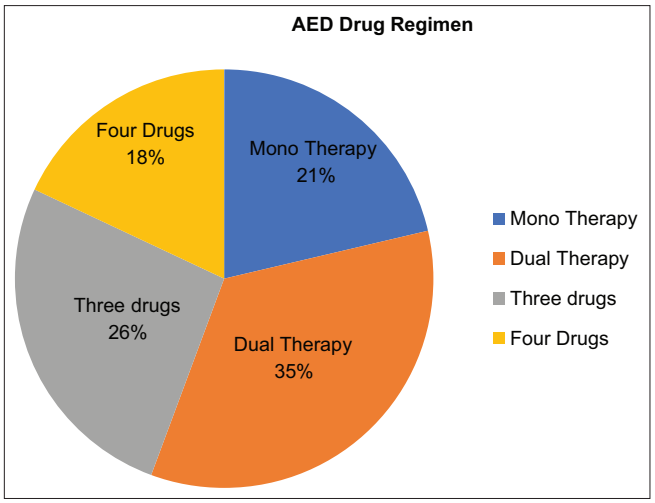

Figure 1: AED drug regimen used by patients

Table 2: Oral side effects seen in epileptic children on AED

Oral side effect of AED	*n*	%
Gingivitis	115	38.3
Gingival hyperplasia	99	33
Xerostomia	138	46
Glossitis	83	26.7

AED: Anti-epileptic drugs

Statistical Analysis

Chi-square

The Chi-square statistic is used to show whether or not there is a relationship between two variables.

This is the Chi-square equation:

$$\chi^2 = \sum_{i=1}^{n} \frac{(O_i - E_i)^2}{E_i}$$

Here,
χ^2=the Chi-square statistic
O_i=the observed frequency
E_i=the expected frequency
i=the number of the cell (cell 1, cell 2, etc.)
χ^2 value = 111.67 with degree of freedom=7.

Looking at our Chi-square table, we see that the critical Chi-square value for 7 degrees of freedom at the 0.001 probability level is 24.322. Since our calculated Chi-square value is greater than the critical Chi-square value, our results are significant at the 0.001 probability level.

We can also see that our results are also significant at the 0.01 as well as 0.05 probability levels. Therefore, there is a statistically significant relationship between traumatic

injuries between epileptic and non-epileptic patients using either 0.001 or 0.01 as our standard.

Pearson's correlation

The Pearson's correlation for traumatic injuries between epileptic and non-epileptic patients observed is 0.29 [Table 3]. The correlation between any two variables using Pearson's correlation will always be between –1 and +1.

The equation for Pearson's r is as follows:

$$r = \frac{\sum_{xy} - N\overline{xy}}{\sqrt{(\sum x^2 - N\overline{x}^2)(\sum y^2 - N\overline{y}^2)}}$$

This equation requires us to first calculate the sum of the product of all our data pairs, the means of both variables, and the sum of the squared values of both variables.

The value observed for our date is 0.29 which is very low. This indicates inadequate correlation for the traumatic injuries between epileptic and non-epileptic patients.

Hence, we can infer from both Pearson Chi-square test and correlation test that the traumatic injuries between epileptic and non-epileptic patients are highly independent of each other [Figure 2].

DISCUSSION

Most of the epileptic patients can be treated successfully with AEDs [Table 4]. Rarely, neurosurgery or vagus nerve stimulation is needed.[21,22] The later therapy options depend on the severity and type of epilepsy. In Europe and North America, more than 15 AEDs have been given approval for the management of epilepsy.[23] To control their seizures polydrug therapy is often indicated: ≤50%, attain control with one drug therapy; two drugs are required only in 10% cases, whereas 5% epileptic patients respond to three or four combinations of drug.[24] The quality of life of epileptic children gets affected due to deterioration in their oral health along with systemic and social problems.

The study done by Lundström *et al.* demonstrated that children and adolescents who took PHT develop larger number of gingival units with increase in depth of probing than individuals given CBZ during comparable period.[25] Findings in our study support previous reports that gingival enlargement seen in children on PHT medication is linked with the deposition of plaque in dentogingival areas with simultaneous inflammation of gingiva.[26,27] Non-modifiable factors such as genetic factor, age, and sex can predict individual's inherent risks for gingival hyperplasia.[26,28]

Table 3: Traumatic injuries in epileptic and non-epileptic patients

Injuries	Traumatic injuries				
	Epileptic patients		Non-epileptic patients		
	n	(%)	*n*	(%)	Total
Lip or cheek bite	86	28.7	94	31.3	180
Tongue injuries	99	33	6	2	105
Tooth crack	111	37	42	14	153
Tooth fracture	76	25.3	124	41.3	200
Nose fracture	69	23	12	4	81
TMJ injuries	71	23.7	75	25	146
Eye socket trauma	49	16.3	5	1.7	54
Skull crack	32	10.7	3	1	35
Total	593		361		954

TMJ: Temporomandibular joint

Table 4: AED drug regimen consumed by patients

AED drug regimen	*n*	%
Mono therapy	64	21.3
Dual therapy	103	34.3
Three drugs	79	26.3
Four drugs	54	18

AED: Anti-epileptic drugs

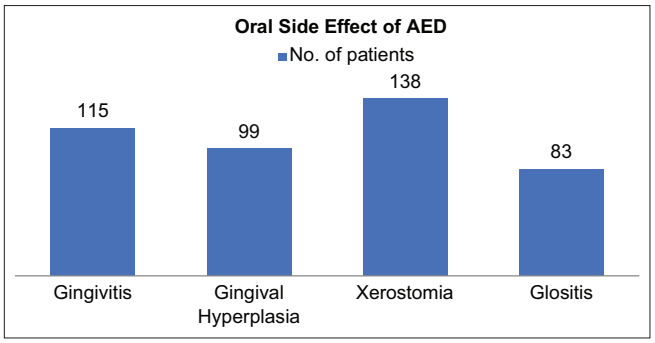

Figure 2: Oral side effects seen in epileptic children on AEDs

Gingival hyperplasia is characterized by the overgrowth of gingival subepithelial connective tissue and epithelium that develops about 1–3 months after the start of PHT treatment. This tissue enlargement typically begins at the interdental papilla and encroaches on the crowns of all teeth. Gingival overgrowth is not painful; however, gingival tissues that are traumatized during mastication, for example, may become tender. Growth hormone (GH) also creates conditions that allow plaque to accumulate easily, which increases bleeding in the dental sulcus and interdental papillary tissues. These factors make it much more difficult for patients to practice proper oral hygiene, resulting in the deterioration of their oral health. If left untreated, GH can shift the patient's dentition or cover the entire crown of the affected teeth.[29,30]

After numerous studies of the incidence of gingival hyperplasia in different populations treated with PHT,[31-35]

it is widely accepted that patients treated with PHT may experience gingival hyperplasia.

It is generally accepted that AEDs have side effects that diminish the patient's oral health; however, when the drugs are used short-term, such effects can be reversed, once treatment has ceased.[36] For patients taking AEDs for prolonged periods of time, good oral hygiene may be crucial to their ability to control the severity of GH. The role of the oral health-care professionals is critical in reducing the severity and extent of GH in patients on short-term or prolonged AED therapy. Patients need to attend educational sessions and prevention programs to motivate them to use proper oral hygiene, in addition to their regular visits to the dentist or dental hygienist. Such action should considerably diminish the side effects of AEDs therapy, such as GH.

The newer AEDs produce oral manifestations only infrequently. Xerostomia and stomatitis have been reported rarely as side effects of CBZ,[37] and rash that may involve the oral cavity has been associated with lamotrigine and can be exacerbated by the concomitant use of valproic acid.[38]

Valproic acid can cause direct bone marrow suppression, which can impair wound healing and increase post-operative bleeding and infections. Decreased platelet count is the most common and best-recognized hematologic effect of valproic acid; the incidence varies from 5% to 40%. Clinically, significant bleeding is uncommon because the thrombocytopenia is usually not severe. For elective surgery, laboratory evaluation — including bleeding time, fibrinogen level, prothrombin time, partial thromboplastin time, and von Willebrand factor level — is needed to assess the risk of peri- and post-operative bleeding. Bleeding as a potential side effect should be discussed with patients and their families in preparation for surgery.[39]

A number of drugs prescribed by dentists can jeopardize seizure control because they interact with AEDs. For instance, metronidazole, antifungal agents (such as fluconazole), and antibiotics (such as erythromycin) may interfere with the metabolism of certain AEDs.[40]

The co-administration of fluconazole and PHT is associated with a clinically significant increase in PHT plasma concentration, and the dose of the latter may require adjustment to maintain safe therapeutic concentrations. Other anticonvulsants, such as vigabatrin, lamotrigine, levetiracetam, oxcarbazepine and gabapentin, are unlikely to interact with fluconazole.

Clarithromycin increases the plasma concentration of CBZ, and co-administration of these drugs should be monitored very carefully to avoid CBZ toxicity.[41]

Valproic acid may be displaced from plasma proteins and metabolic pathways may be inhibited by high doses of aspirin; this interaction will free serum VPA concentrations resulting in subsequent toxicity.[42]

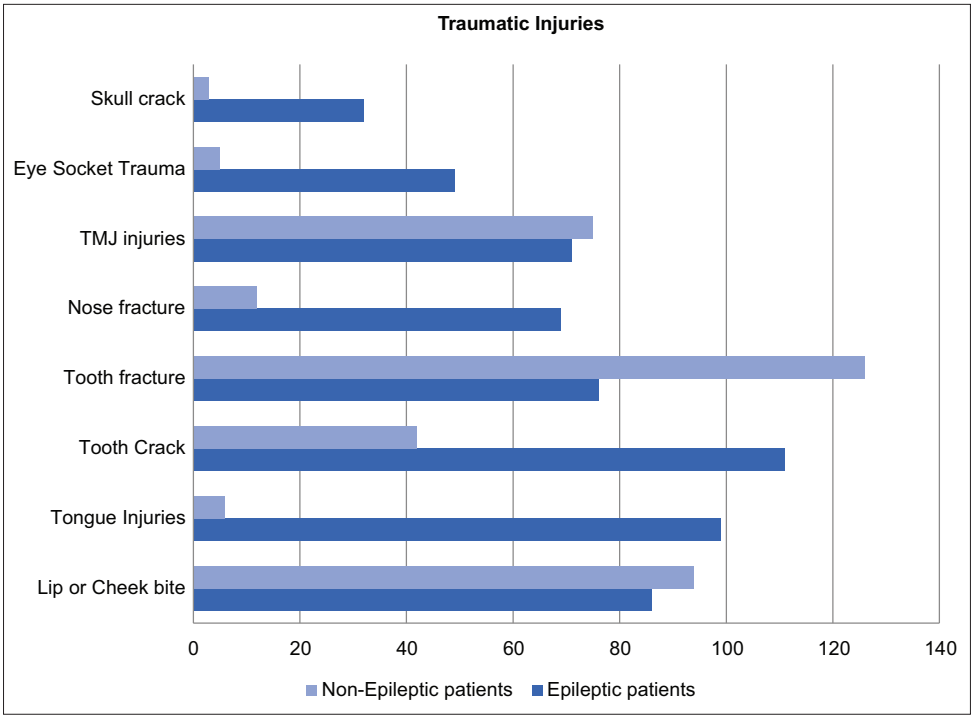

Figure 3: Traumatic injuries in epileptic and non-epileptic patients

The results showed that the patients with epilepsy were significantly more susceptible to facial and dental injuries than were the controls [Figure 3]. This has been reported by several other authors, including Martin, who stated that epileptic attacks can put patients at risk of suffering orofacial trauma.

According to Aragon and Burneo, the most common types of injuries that follow seizures are head trauma, fractures, and dental trauma.

The main aim of the scientists, as have been shown in a few publications, is focused on prevention of traumatic injuries in patients with epilepsy.[43] Many methods are invented for the prevention of intraoral injuries. Individually designed intraoral mouth guards, similar to those used by athletes, may be a great solution.

Individual, flexible intraoral mouth guards used during different sport disciplines, not only contact and extreme ones, provide excellent retention, stabilization, and high capacity to absorb energy, thus preventing trauma and reducing potential of the energy transferred to the temporomandibular joint or the base of the skull. They are made of a biocompatible material of proper thickness (3–5 mm). Most of the athletes, who use them, do not report their negative impact on speech or breathing.[34]

CONCLUSION

Traumatic injuries to face and teeth are more common in patients with epilepsy. It is essential that dentists should be well versed with the side effects related to all AEDs, particularly belonging to the newer generation.

Epileptic patients have severely inadequate mouth hygiene, oral health, and dental conditions. This is explained by the fact that these patients receive insufficient dental care because they spend only a short time in the dentist's chair due to the risk of seizure. Furthermore, their dental condition is worsened by injuries and damage caused to both hard and soft tissues in the maxilla-facial region during seizures. Therefore, protective measures such as the use of chlorhexidine and fluoride, education regarding oral hygiene, regular dental check-ups, and educating children to avoid sugary foods and drinks are crucially important.

Due to high frequency of dental trauma in epileptic patients, it is necessary to implement prophylactic management to prevent hard and soft tissues injuries. It seems that custom- made mouth guards in patients anticipating an epileptic seizure can be a good standard manner to prevent trauma. It is also necessary to pay special attention to the expansion and improvement of dental care concerning epileptic patients.

People with epilepsy can be safely treated in a general dental practice. A thorough medical history should be taken and updated at each visit. Seizure history must be taken into account when planning treatment. Dentists with a comprehension of seizure disorders can provide an invaluable service to their patients, providing not only oral health but also maintaining and promoting the systemic health of these patients.

REFERENCES

1. Proposal for revised classification of epilepsies and epileptic syndromes. Commission on classification and terminology of the international league against epilepsy. Epilepsia 2019;60:89-99.
2. Turner MD, Glickman RS. Epilepsy in the oral and maxillofacial patient: Current therapy. J Oral Maxillofac Surg 2005;63:996-1005.
3. Busschots GV, Milzman BI. Dental patients with neurologic and psychiatric concerns. Dent Clin North Am 1999;43:471-83.
4. Jacobsen PL, Eden O. Epilepsy and the dental management of the epileptic patient. J Contemp Dent Pract 2008;9:54-62.
5. Aragon CE, Burneo JG. Understanding the patient with epilepsy and seizures in the dental practice. J Can Dent Assoc 2007;73:71-6.
6. Joshi SR, Pendyala GS, Saraf V, Choudhari S, Mopagar V. A comprehensive oral and dental management of an epileptic and intellectually deteriorated adolescent. Dent Res J (Isfahan). 2013;10:562-7.
7. Owen H, Waddell-Smith I. Dental trauma associated with anaesthesia. Anaesth Intensive Care 2000;28:133-45.
8. Mattson RH, Gidal BE. Fractures, epilepsy, and antiepileptic drugs. Epilepsy Behav 2004;5:S36-40.
9. Ghafoor PA, Rafeeq M, Dubey A. Assessment of oral side effects of antiepileptic drugs and traumatic ORO-facial injuries encountered in epileptic children. J Int Oral Health 2014;6:126-8.
10. Fisher RS. Redefining epilepsy. Curr Opin Neurol 2015;28:130-5.
11. Newton CR, Garcia HH. Epilepsy in poor regions of the world. Lancet 2012;380:1193-2011.
12. Neligan A, Hauser WA, Sander JW. The epidemiology of the epilepsies. Handb Clin Neurol 2012;107:113-33.
13. Alving J, Beniczky S. Epileptic prodromes: Are they nonconvulsive status epilepticus? Seizure 2013;22:522-7.
14. Gawlak D, Mierzwińska-Nastalska E, Mańka-Malara K, Kamiński T. Comparison of usability properties of custom-made and standard self-adapted mouthguards. Dent Traumatol 2014;30:306-11.
15. Gawlak D, Mańka-Malara K, Łuniewska J, Hovhannisyan A, Stojak W, Stróżyńska A, *et al*. Prevention of traumatic injuries and dental treatment of epileptic patients. J Stomatol 2015;68:468-75.
16. Gawlak D, Mańka-Malara K, Kamiński T. Ocena użytkowania indywidualnych ochraniaczy jamy ustnej wykonanych technikąewtryskowątbadania wstępne. Dent Med Probl 2014;2:218-24.
17. de Kinderen RJ, Evers SM, Rinkens R, Postulart D, Vader CI, Majoie MH, *et al*. Side-effects of antiepileptic drugs: The economic burden. Seizure 2014;23:184-90.
18. Mehmet Y, Senem O, Sülün T, Hümeyra K. Management of epileptic patients in dentistry. Surg Sci 2012;3:47-52.
19. Behere PB, Marmarde A, Singam A. Dislocation of the unilateral temporomandibular joint a very rare presentation of epilepsy. Indian J Psychol Med 2010;32:59-60.
20. Gautam A, Verma PK, Srivastava R, Lodhi K. Esthetic correction of phenytoin induced gingival hyperplasia-case reports. Health Care 2013;1:28-31.
21. Akor F, Liu NM, Besag FM, Ahmed MA. Value of tongue biting in differentiating betweenepileptic seizures and syncope. Seizure 2013;22:328.
22. Singh NA, Khan M, Vijayalakshmi KR, Subhas GT, Nataraju B, Anitha M. Phenytoin, folic acid and gingival enlargement: Breaking myths. Contemp Clin Dent 2014;5:59-66.
23. International League against Epilepsy, International AED Database; 2010. Available from: http://www.aesnet.org/go/practice/aedinfo. [Last accessed

on 2017 Feb 25].
24. Kwan P, Brodie MJ. Early identification of refractory epilepsy. N Engl J Med 2000;342:314-9.
25. Lundström A, Eeg-Olofsson O, Hamp SE. Effects of anti-epileptic drug treatment with carbamazepine or phenytoin on the oral state of children and adolescents. J Clin Periodontol 1982;9:482-8.
26. Nuki K, Cooper SH. The role of inflammation in the pathogenesis of gingival enlargement during the administration of diphenylhydantoin sodium in cats. J Periodontal Res 1972;7:102-10.
27. Donnenfeld OW, Stanley HR, Bagdonoff L. A nine month clinical and histological study of patients on diphenylhydantoin following gingivectomy. J Periodontol 1974;45:547-57.
28. Hassell TM. Epilepsy and the oral manifestations of phenytoin therapy. In: Myers H, editor. Monographs in Oral Science. Basel: S. Karger; 1981.
29. Angelopoulos AP, Goaz PW. Incidence of diphenylhydantoin gingival hyperplasia. Oral Surg Oral Med Oral Pathol 1972;34:898-906.
30. Angelopoulos AP. A clinicopathological review. Diphenylhydantoin gingival hyperplasia: 2. Aetiology, pathogenesis, differential diagnosis and treatment. Dent J 1975;41:275-7, 283.
31. Klar LA. Gingival hyperplasia during dilantin-therapy; a survey of 312 patients. J Public Health Dent 1973;33:180-5.
32. Seymour RA, Smith DG, Turnbull DN. The effects of phenytoin and sodium valproate on the periodontal health of adult epileptic patients. J Clin Periodontol 1985;12:413-9.
33. Thomason JM, Seymour RA, Rawlins MD. Incidence and severity of phenytoin-induced gingival overgrowth in epileptic patients in general medical practice. Community Dent Oral Epidemiol 1992;20:288-91.
34. Prasad VN, Chawla HS, Goyal A, Gauba K, Singhi P. Incidence of phenytoin induced gingival overgrowth in epileptic children: A six month evaluation. J Indian Soc Pedod Prev Dent 2002;20:73-80.
35. Prasad VN, Chawla HS, Goyal A, Gauba K, Singhi P. Folic acid and phenytoin induced gingival overgrowth-is there a preventive effect? J Indian Soc Pedod Prev Dent 2004;22:82-91.
36. Dahllöf G, Axiö E, Modéer T. Regression of phenytoin-induced gingival overgrowth after withdrawal of medication. Swed Dent J 1991;15:139-43.
37. Ogunbodede EO, Adamolekun B, Akintomide AO. Oral health and dental treatment needs in Nigerian patients with epilepsy. Epilepsia 1998;39:590-4.
38. Li LM, Russo M, O'Donoghu MF, Duncan JS, Sander JW. Allergic skin rash with lamotrigine and concomitant valproate therapy: Evidence for an increased risk. Arq Neuropsiquiatr 1996;54:47-9.
39. Archarya S, Bussel JB. Hematologic toxicity of sodium valproate. Pediatr Hematol Oncol 2000;22:62-5.
40. Goulden KJ, Dooley JM, Camfield PR, Fraser AD. Clinical valproate toxicity induced by acetylsalicylic acid. Neurology 1987;37:1392-4.
41. Patsalos PN, Frosher W, Pisani F, van Rijn CM. The importance of drug interactions in epilepsy therapy. Epilepsia 2002;43:365-85.
42. Miners JO. Drug interactions involving aspirin (acetylsalicylic acid) and salicylic acid. Clin Pharmacokinet 1989;17:327-44.
43. Adewole RA, Ojini FI, Akinwande JA, Danesi MA. Oro-dental and maxillofacial trauma in epilepsy at a Tertiary hospital in Lagos. West Afr J Med 2011;30:114-7.

How to cite this article: Mahajan N, Mahajan P, Khajuria A, Kotwal B, Kaul B, Gupta R. Role of Cumulative Anti-epileptic Drug Load on the Periodontal Health Tissues and Seizure Related Traumatic Oro-dental Injuries - A Comparative Cross-sectional Study in a Tertiary Health Institution in Jammu City. Int J Sci Stud 2020;8(2):78-84.

Source of Support: Nil, **Conflicts of Interest:** None declared.