Case Report

DOI: 10.17354/ijss/2015/256

Endoscopic Resection of Cavernous Cystic Lymphangiomyoma of the Lower Oesophagus Incidentally Discovered: A Case Report

Dexter R Marak[1], K Lokendra[2], Amongla Imchen[1], S Ranita Devi[3], G S Moirangthem[4]

[1]Post Graduate Student, Department of Surgery, Regional Institute of Medical Science, Imphal, Manipur, India, [2]Registrar, Department of Surgery, Regional Institute of Medical Science, Imphal, Manipur, India, [3]Professor, Department of Surgery, Regional Institute of Medical Science, Imphal, Manipur, India, [4]Professor & Head, Department of Surgery, GI and Minimal Access Surgery, Regional Institute of Medical Science, Imphal, Manipur, India

Abstract

Lymphangioma of the esophagus is an extremely rare entity, with only 18 cases having been reported worldwide. We present a case of 61-year-old woman admitted for evaluation of a 2 years history of retrosternal discomfort and epigastric pain. On routine endoscopy, a smooth pedunculated bluish cystic mass about 2 cm in diameter over the lower esophagus was unexpectedly discovered. Cavernous cystic lymphangiomyoma was diagnosed on histopathological examination of the polypectomy specimen. Since no case of malignant transformation of these lesions has ever been reported in the literature, endoscopic resection seems to be an appropriate method both for the removal of the tumor and precise diagnosis. However, when endoscopic procedures are not feasible, surgical enucleation through right-sided thoracotomy approach, should only be considered for obstructive and symptomatic lesions; otherwise, regular upper gastrointestinal endoscopy follow-up and histopathological examination whenever required can be applied for asymptomatic cases.

Key words: Cavernous cystic lymphangiomyoma, Endoscopic polypectomy, Esophageal neoplasm

INTRODUCTION

Lymphangiomas are a rare form of benign vascular tumors. It is a mass with irregularly dilated lymphatic channels that contain chylous or serous fluid.[1] They are typically thin-walled structures and can be single or multiple. They are often classified based on the gross appearance of the abnormal lymphatic tissue as capillary, cavernous and cystic. Lymphangioma are usually observed in childhood. 90% of cases are manifested in the 2nd year of life. Only 1% of these tumors have been discovered in the gastrointestinal (GI) tract.[1] It is rare in adulthood and usually located in the neck (75%), axilla (20%), mediastinum, bone, and retroperitoneum (5%).[2] Gangl *et al.* collected only 32 patients with GI lymphangioma in their review of the literature; colon was the most frequent location followed by the duodenum and stomach.[3] To date, only 18 cases of esophageal lymphangiomas have been reported. Among the benign tumors of the esophagus, leiomyomas are the most common (65%) followed by the vascular tumors which represent only 2% of all esophageal benign neoplasms, but mostly they are hemangiomas.[4-6]

We present a case of cavernous cystic esophageal lymphangiomyoma incidentally discovered, both because of the extreme rarity of this lesion and to report its successful endoscopic removal.

Access this article online

IJSS

www.ijss-sn.com

Month of Submission : 03-2015
Month of Peer Review : 04-2015
Month of Acceptance : 04-2015
Month of Publishing : 05-2015

CASE REPORT

A 61-year-old woman weighing about 54 kg with a height of 154 cm was admitted on 7th January, 2015, MRD no 18309, for evaluation of a 2 years history of retrosternal discomfort and epigastric pain. Her chest X-ray posteroanterior view report shows cardiomegaly. Her electrocardiogram otherwise was within normal limits. Her X-ray barium swallow report reveals mildly

Corresponding Author: Dexter R Marak, Department of Surgery, Regional Institute of Medical Science, Lamphelpat Imphal - 795 004, Manipur, India. Phone: +91-9862701800. E-mail: dexter_marak06@yahoo.co.in

tortuous thoracic esophagus with no persistent narrowing or stricture, and upper stomach and its mucosal pattern appearing normal (Figure 1). The standard hematologic and biochemical laboratory blood tests were within normal limits. Consequently, she was advised for upper GI endoscopy which revealed a smooth pedunculated bluish cystic mass about 2 cm in diameter over the lower esophagus (Figure 2): Thus, an endoscopic polypectomy was performed with a diathermic loop (Figure 3). When the patient was released from the hospital, she was given a 2-week daily prescription of pantoprazole 40 mg and multivitamin syrup.

The histopathology report show strips of esophageal mucosa with sub-epithelium displaying numerous cavernous dilated lymphatic channels lined by flattened endothelial cells separated by fibrocollagenous tissue. The fibrocollagenous tissue also shows scattered bundles of smooth muscle with occasional follicles (Figure 4).

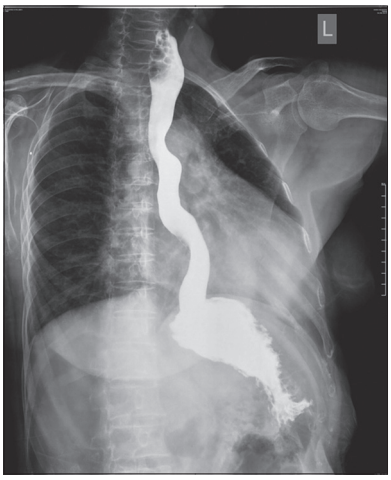

Figure 1: Barium swallow esophagus showing mildly tortuous thoracic esophagus with no persistent narrowing or stricture

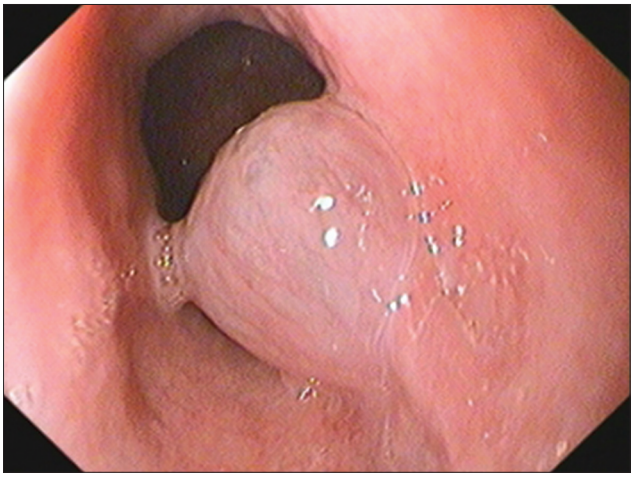

Figure 2: Upper gastrointestinal video endoscopy picture showing smooth pedunculated bluish cystic mass about 2 cm in diameter over the lower esophagus

Follow-up after 1 month, another endoscopy was performed, which showed complete healing of the esophageal mucosa. In addition, the area where the polypectomy had been previously performed was no longer visible. Consequently, the patient was given a 2-week prescription of pantoprazole. The subsequent clinical examination, 1½ month later, showed that the epigastric pain had disappeared. Based on these results, no further endoscopic examinations were carried out.

DISCUSSION

Lymphangioma of the esophagus is very rare, and only 18 cases were found in a Medline Literature search (Table 1). Of these, only seven were removed endoscopically. Brady *et al*. was the first to describe the endoscopic findings of an esophageal lymphangioma. It is rare in adulthood and if present is usually located in the neck and axilla. The esophagus is the most unusual location for its development.[7,8]

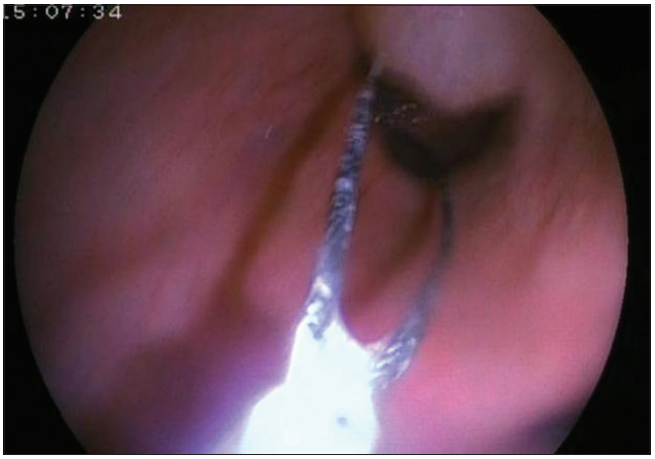

Figure-3: Endoscopic polypectomy with a diathermic loop

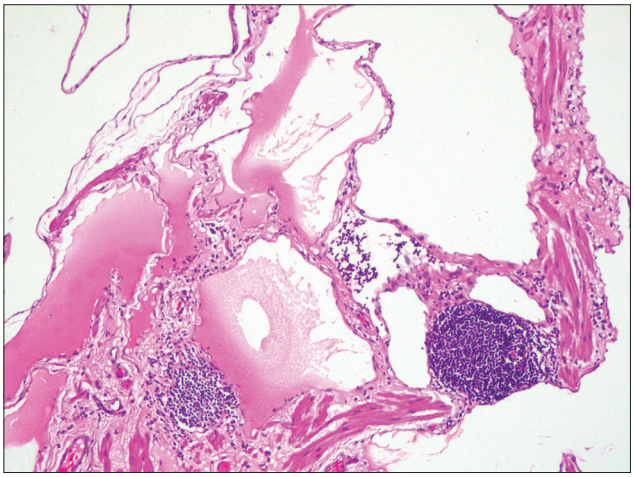

Figure-4: Biopsy specimen showing numerous cavernous dilated lymphatic channels lined by flattened endothelial cells (H and E, ×100)

Table 1: Cases of esophageal lymphangioma in a Medline literature search

Case number	Year	Author	Age (y)	Sex	Symptom	Site	Size (cm)	Treatment
1	1934	Watson-Williams	61	M		L	Unknown	Follow-up
2	1961	Schmidt						
3	1973	Brady	62	F	Epigastric pain	L	5.0	Follow-up
4	1979	Armengol Miro	64	M	Epigastric pain	L	1.0	ER
5	1980	Murata	56	M		L	1.8×1.2	ER
6	1980	Tamada	46	M	Dysphagia	L	Unknown	OS
7	1981	Arai	32	M		U	Unknown	OS
8	1983	Lieber	58	M	Dysphagia	L	1.5	ER
9	1989	Castellanos	66	F	Chest pain	M	1.5x2.0	OS
10	1994	Yoshida	55	M	Heart burn	M	4.0	OS
11	1996	Suwa	52	F	Dysphagia	L	2.2x2.0	ER
12	1997	Basak	69	F	Dysphagia	M	Unknown	OS (expired)
13	1997	Scarpi	64	M	Epigastric pain	L	Unknown	ER
14	2002	Lee	37	M	Dysphagia	L	Multiple	IF-α+ER
15	2004	Yoon	72	M	Vomiting	L	5.1x2.3x1.7	OS
16	2007	Best	63	M	Dysphagia	U	Multiple	Co2 laser
17	2009	Martin	43	F	Upper GI discomfort			
18	2013	Zhao	48.2±15.2	4M+2F			0.4-1.2	ER

This table form and content from case 1 to 12 refer to reference 7, ER: Endoscopic resection, IF-α: Interferon alpha, L: Lower esophagus, M: Middle esophagus, OS: Open surgery, U: Upper esophagus

Symptoms may vary depending on the location, dimension, and degree of obstruction.[9] In fact, the lesion can be completely asymptomatic or can cause dysphagia and odynophagia; in cases where patients have complained of chest pain in the midsternal area, lymphangioma was also present with either esophagitis, hiatal hernia, gastric ulcers or coronaropathy: for this reason, the correlation to the lymphangioma is difficult to determine.[10] Lymphangiomas are malformations of the lymphatic system characterized by lesions that are thin-walled cysts. On gross examination, the lesions are pale, smooth, with multicystic cut surface, and exude clear yellowish fluid.[10] Histologically, the masses show strips of the mucosa with the sub-epithelium displaying numerous dilated lymphatic channels lined by flattened endothelial cells with no blood within the vascular space. Lymphangioma can occur in every age, but several authors have reported a higher incidence during childhood.[10] The endoscopic appearance of lymphangiomas is known to be a submucosal polypoid mass with a translucent and lustrous surface; it is white or yellowish and softly deforms under the pressure of endoscope.[11] Endoscopic biopsy is necessary for definitive diagnosis, but endoscopic sampling may sometimes lead to misleading information because a normal surface epithelium covers the tumor. Since no case of malignant transformation of these lesions has ever been reported in the literature, endoscopic resection seems to be an appropriate method both for the removal of the tumor and precise diagnosis. However, when endoscopic procedures are not feasible, thoracotomic surgical resection of lesions, should only be considered for obstructive and symptomatic lesions; with consideration of possible conservative therapy of asymptomatic and non-obstructing lesions with regular upper GI endoscopic follow-up and histopathological biopsy examination whenever required.

Points to Ponder

Cavernous cystic lymphangiomyoma is a rare form of benign vascular tumor. It is very rare in adulthood and if present is usually located in the neck, axilla, mediastinum, bone, and retroperitoneum. The esophagus is the most unusual location for its development.

Endoscopic biopsy is necessary for definitive diagnosis, but endoscopic sampling may lead to misleading information because a normal surface epithelium covers the tumor. No case of malignant transformation of these lesions has ever been reported in the literature, so endoscopic resection seems to be an appropriate method both for the removal of the tumor and precise diagnosis.

CONCLUSION

The lymphangioma is a benign tumor which rarely involves the GI system. The current report describes a rare case of cavernous cystic lymphangiomyoma in lower esophagus of 61-years-old female patient. The lesion was detected incidentally during upper GI endoscopic procedure for her symptoms of retrosternal discomfort and epigastric pain. The lesion was successfully managed by endoscopic polypectomy with a diathermic loop and the diagnosis was established by histopathological examination of the polypectomy specimen.

REFERENCES

1. Lee BI, Kim BW, Kim KM, Song HJ, Cho SH, Choi H, *et al.* Esophageal lymphangiomatosis: A case report. Gastrointest Endosc 2002;56:589-91.
2. Bill AH Jr, Sumner DS. A unified concept of lymphangioma and cystic hygroma. Surg Gynecol Obstet 1965;120:79-86.

3. Gangl A, Polterauer P, Krepler R, Kumpan W. A further case of submucosal lymphangioma of the duodenum diagnosed during endoscopy. Endoscopy 1980;12:188-90.
4. Persichetti P, Tosato F, Paganini A, Grande M, Cassese M, Pescatore V, *et al.* Esophageal leiomyomas. Review of the literature and case records from our institute. Minerva Chir 1984;39:855-62.
5. Gutiérrez MT, Bascuas S, Trigo JE, Bueno A, Sousa R, Conde MA, *et al.* Benign tumors of the esophagus. Esophageal leiomyoma. Rev Esp Oncol 1985;32:307-14.
6. Watson RR, O'Connor TM, Weisel W. Solid benign tumors of the esophagus. Ann Thorac Surg 1967;4:80-91.
7. Brady PG, Milligan FD. Lymphangioma of the esophagus – diagnosis by endoscopic biopsy. Am J Dig Dis 1973;18:423-5.
8. Yoon YH, Kim KH, Baek WK, Kim JT, Son KH, Han JY, *et al.* Lymphangioma of the esophagus: surgical treatment. Ann Thorac Surg 2004;78:e51-3.
9. Yoshida Y, Okamura T, Ezeki T, Yano K, Kodate M, Murata I, Kaido M. Lyphangioma of the oesophagus: A case report and review of literature. Thorax 1994;49:1267-8.
10. Scarpis M, De Monti M, Pezzotta MG, Sonnino D, Mosca D, Milani M. Endocopic resection of esophageal lymphangioma incidentally discovered: A case report. Diagn Ther Endosc 1998;4:141-7.
11. Kuramoto S, Sakai S, Tsuda K, Kaminishi M, Ihara O, Oohara T, *et al.* Lymphangioma of the large intestine. Report of a case. Dis Colon Rectum 1988;31:900-5.

How to cite this article: Marak DR, Lokendra K, Imchen A, Devi SR, Moirangthem GS. Endoscopic Resection of Cavernous Cystic Lymphangiomyoma of the Lower Oesophagus Incidentally Discovered: A Case Report. Int J Sci Stud 2015;3(2):259-262.

Source of Support: Nil, **Conflict of Interest:** None declared.