Print ISSN: 2321-6379
Online ISSN: 2321-595X
DOI: 10.17354/ijss/2017/217

Original Article

Histopathological Study of Lesions of Colon - A 5-year Study

Pavani Manthini[1], Raghu Kalahasti[2], Srikanthbabu Yarlagadda[3], K P A Chandrasekhar[2], S Parimala Devi[2], Aravinda Basa[4], Manoja Vaddadi[4], Pramod Kumar Reddy Malyala[4]

[1]Post Graduate, Department of Pathology, SVS Medical College, Mahabubnagar, Telangana, India, [2]Professor, Department of Pathology, SVS Medical College, Mahabubnagar, Telangana, India, [3]Professor and Head, Department of Pathology, SVS Medical College, Mahabubnagar, Telangana, India, [4]Assistant Professor, Department of Pathology, SVS Medical College, Mahabubnagar, Telangana, India

Abstract

Introduction: Colon is part of the gastrointestinal tract that is also called the large intestine. One of the most common colon problems are inflammatory lesions, colorectal polyps, cancerous growths. Cancers of the colon and rectum altogether are the 3rd most common tumor type worldwide, and one of the leading causes of cancer-related death. Pathologic examination of biopsy, polypectomy, and resected specimens are crucial for determining local extent of disease, patient management, and prognosis assessment. This study also includes inflammatory lesions of large intestine and their etiology. Cancerous lesions are most common, and this study emphasizes on their early diagnosis and management.

Aims and Objectives: The aim of this study is to study the histomorphology of various lesion of colon and to evaluate the incidence, age, and sex ratio.

Materials and Methods: A 5-year study was done from January 2012 to December 2016, and a total of 102 cases were evaluated. The material for the study comprised resected specimens and biopsies of colon received in the Department of Pathology, SVS Medical College, Mahabubnagar.

Results: Out of 102 cases, neoplastic lesions are 56 cases, and non-neoplastic lesions are 46 cases. Among 56 neoplastic lesions, 48 were malignant and 8 cases were benign. Most common histological variant of the malignant tumor was well-differentiated adenocarcinoma, and most common benign tumor was adenomatous polyp. The majority of the patients are between 4th-8th decade of life. Predominantly males are affected.

Conclusion: Adenocarcinomas are the most common malignant lesions of colon in our study. As there is increasing incidence of malignancies early diagnosis by endoscopic biopsies in clinically suspicious patients is recommended for good management.

Key words: Adenocarcinoma, Colon, Histopathology, Malignant lesions, Polyps, Rectum

INTRODUCTION

Colorectal cancer is the third leading cancer worldwide, accounting for approximately 9% of all cancers. The incidence varies widely with higher incidence rates in North America, Australia, and Europe. Developing countries have lower rates; particularly Africa and Asia. However, with westernization of lifestyle, the incidence of colorectal cancer is increasing in many developing countries.

Access this article online

IJSS
www.ijss-sn.com

Month of Submission : 03-2017
Month of Peer Review : 04-2017
Month of Acceptance : 05-2017
Month of Publishing : 05-2017

Geographic differences for colorectal cancers are probably explained by dietary and other environmental exposures. A higher risk of colorectal cancers was found in subjects consuming a diet poor in fiber and rich in meat. Non-dietary causes include genetic predisposition. The large intestine measures approximately 150 cm in the adult. The lining epithelium is subject to variety of insults ranging from inflammatory, infections to neoplastic processes.

Adenocarcinoma is the most common malignancy arising in colorectal region. Non-neoplastic polyps are classified as hyperplastic, hamartomatous, juvenile, peutz jegher, inflammatory, and lymphoid polyps. When other benign

Corresponding Author: Dr. Pavani Manthini, H. No: 2-5-668, Subedari, Hanamkonda, Warangal - 506 001, Telangana, India.
Phone: +91-8686674468. E-mail: pavanidhonthula@gmail.com

conditions are adenoma, neuroma, lipoma, angioma. Inflammatory bowel diseases such as ulcerative colitis are premalignant conditions. Both macroscopic and microscopic appearance correlated with clinical diagnosis helps in early detection and better outcome.

Aims and Objectives

1. To study the histomorphology of various lesions of colon in our institution.
2. To evaluate the incidence, age, and sex ratio distribution among the patients with lesions of colon.

MATERIALS AND METHODS

A 5-year study was done from January 2012 to 2016 December in the Department of Pathology, SVS Medical College, Mahabubnagar, Telangana. Relevant clinical data regarding age, history, and examination were recorded in a pro forma. The study was done on 102 specimens with colon lesions which included both resected specimens and biopsies referred from the Department of Surgery, SVS Medical College and Hospital, Mahabubnagar. All biopsies and resected specimens received were immediately fixed in 10% formalin for 24 h. Gross features of specimen were noted, and multiple sections were taken. Routine tissue processing was done. Sections were stained with hematoxylin and eosin. After detailed study of the sections under the light microscope, the final diagnosis was given. The data were analyzed, and results were obtained.

RESULTS

Results of the study are shown in Tables 1-4 and Figures 1-7.

During the 5-year study period, total of 102 cases of colon lesions was observed. Out of 102 cases, 56 cases were neoplastic and 46 cases were non-neoplastic (Table 1). Among the neoplasms studied, benign were 8 cases, and malignant were 48 cases (Table 2).

The majority of cases among non-neoplastic lesions were chronic non-specific colitis - 25 cases (Table 3).

Adenomatous polyp was the most common benign lesion - 5 cases (Table 3).

Adenocarcinomas (48 cases) were the most common malignant neoplasms with well-differentiated histologic variant being the most common (Table 3).

Most common age group affected was 4-6th decade of life (50.9%) within the age range of 5-80 years. Predominantly males were affected.

There were 67 males and 37 females with M:F ratio being 1.9:1 (Table 4).

In our study, among the various lesions of colon, malignant lesions were more common (48 cases) (Table 3).

DISCUSSION

In our study of 102 cases, non-neoplastic cases constituted 46 cases, and neoplastic cases constituted 56 cases. Among the neoplastic lesions, malignant lesions constituted maximum number of cases (48 cases), and benign were (8 cases). Our finding was similar to Sulegaon *et al.*[1] study of 124 cases, in which neoplastic lesions were 77 cases and

Table 1: Nature of lesions of colon

Lesions	Number of cases (%)
Non-neoplastic lesions	46 (45.09)
Neoplastic lesions	56 (54.91)
Total	102 (100)

Table 2: Incidence of neoplasms of colon

Neoplastic lesions	Number of cases (%)
Benign	8 (14.3)
Malignant	48 (85.7)
Total	56 (100)

Table 3: Incidence of various morphological lesions of colon

Nature of lesions	Number of cases (%)
Non-neoplastic lesions	
Chronic nonspecific colitis	25 (24.5)
Tuberculosis	5 (4.9)
Ischemic colitis	10 (9.8)
Inflammatory bowel disease	6 (5.8)
Benign lesions	
Inflammatory polyp	1 (0.98)
Adenomatous polyp	5 (4.90)
Juvenile polyp	2 (1.96)
Malignant lesions	
Well-differentiated adenocarcinoma	29 (28.4)
Moderately differentiated adenocarcinoma	5 (4.9)
Poorly differentiated adenocarcinoma	3 (2.94)
Mucinous adenocarcinoma	7 (6.8)
Signet-ring cell adenocarcinoma	4 (3.9)
Total	102 (100)

Table 4: Age and sex incidence

Age in years	Males	Females	Total number of cases (%)
5-20	2	1	3 (2.94)
21-40	10	7	17 (16.66)
41-60	35	17	52 (50.9)
61-80	20	10	30 (29.4)
Total	67	37	104 (100)

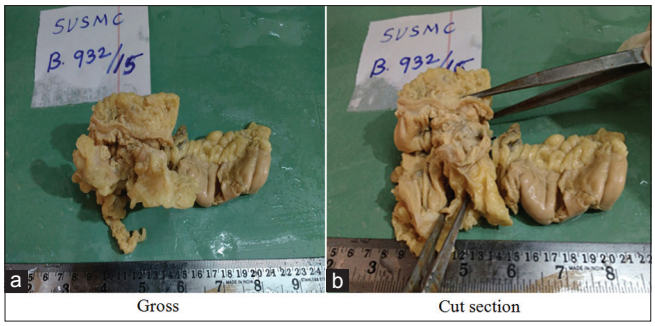

Figure 1: (a and b) Well-differentiated adenocarcinoma

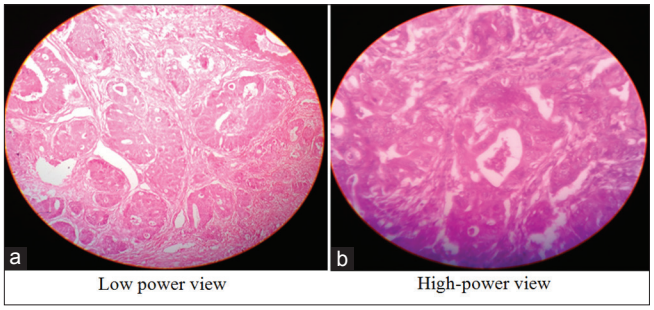

Figure 2: (a and b) Microscopy of well-differentiated adenocarcinoma

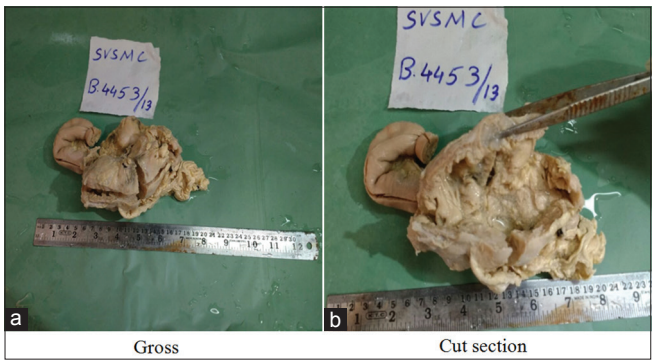

Figure 3: (a and b) Poorly differentiated adenocarcinoma

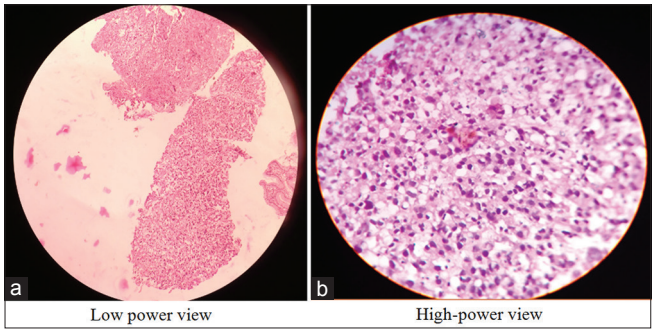

Figure 4: (a and b) Microscopy of poorly differentiated adenocarcinoma

non-neoplastic lesions were 47 cases and among neoplastic lesions, malignant lesions (68 cases) were more than benign lesions (9 cases). In our study among the various lesions of colon the common age group involved in our study

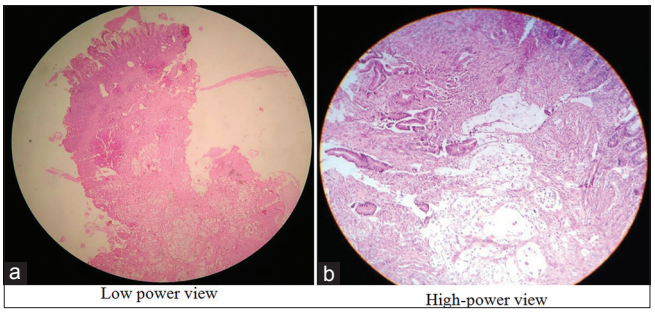

Figure 5: (a and b) Microscopy of mucinous adenocarcinoma



Figure 6: (a and b) Inflammatory polyp

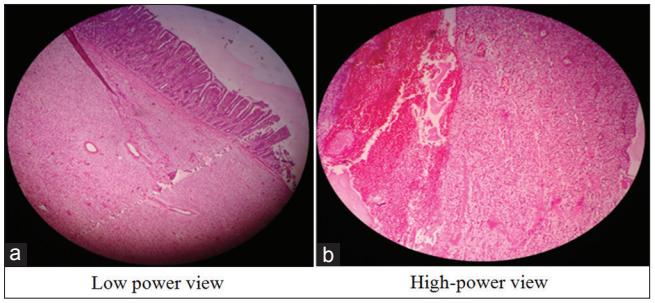

Figure 7: (a and b) Microscopy of inflammatory polyp

was 4-6th decade of life, i.e., 52 cases (50.9%), a finding consistent with Mohsin-ul-Rasool *et al.*[2] study of 446 cases, in which maximum number of cases were observed in 4-6th decade that is 210 cases (47.30%). In our study, males outnumbered females with male to female ratio of 1.9:1, finding consistent with Mohsin-ul-Rasool *et al.*[2] study, in which M:F ratio is 1.3:1. Peedikayil *et al.*,[3] also found that maximum cases are between age group of 40-80 years.

Juvenile Polyps

In our study, 2 cases of juvenile polyps in the rectum were noted. The most common symptom was bleeding per rectum. Dajani and Kamal and Roth and Helwig[4,5] also found rectum as the most common site for juvenile polyp. Grossly juvenile polyps are pedunculated, smooth surfaced, reddish masses with characteristic cystic spaces on cut section. Microscopy showed polypoidal lesion lined by tall columnar mucinous epithelium. Deeper stroma showed many glandular acini some are cystically dilated lined by one to two layers of columnar epithelium. In between

the glandular acini, plenty of inflammatory cells such as lymphocytes and neutrophils was seen.

Adenomatous Polyp

Totally 5 cases (4.90%) of adenomatous polyp were diagnosed. In our study among the polyps, most common were adenomatous polyp. Tony *et al.*[6] found that in southern India adenomatous polyp was the most common polyp. This finding in our study also corresponds to the study of Eshghi *et al.*[7]

Adenocarcinomas constituted the maximum number of cases in our study that is 48 cases. The most common histologic type was well-differentiated adenocarcinoma which constituted 29 cases followed by mucinous carcinoma 7 cases.

Our study is in accordance with the study series of Laishram *et al.*[8] and Chaitanya *et al.*,[9] where in the most common histological grade was well differentiated adenocarcinoma. Our finding was similar to Shah and Wani[10] in their study of 107 cases of colorectal carcinoma found that 72% of cases were of well-differentiated type while mucinous carcinoma constituted 20% of the cases. On gross well-differentiated adenocarcinoma (Figures 1 and 2) show ulcerative growth and histology shows tumor proper with intestinal mucosal glands and tumor area consisting of tumor cells that are arranged in glandular pattern. There is stratification of tumor cells with hyperchromatic pleomorphic nucleus, glandular crowding with scanty intervening stroma. Infiltration into muscularis propria is seen (Figure 5). On gross, mucinous carcinoma shows fungating mass, and on histology, shows tumor proper with tumor cells that are round to polygonal with hyperchromatic nuclei and arranged in glandular pattern. There are extensive pools of mucin, in which tumor cells are seen. In Ritesh *et al.* study and Caliskan *et al.*[11] study, the most common histologic type was moderately differentiated adenocarcinoma followed by mucinous adenocarcinoma.

CONCLUSION

During the 5-year study, malignant lesions of the colon were most common.

Among the malignant lesions, maximum cases were adenocarcinomas of well-differentiated type.

Among the benign lesions, majority of the cases were adenomatous polyps.

Most common age group affected was 4-6th decade of life. Predominantly, males were affected.

This study concludes that various types of lesions occur in colon affecting persons from early childhood to late adulthood. Biopsies from suspected lesions of colon help in early diagnosis while the extent of disease and assessment of prognosis can be made from the histopathological study of resected specimens.

REFERENCES

1. Sulegaon R, Shete S, Kulkarni D. Histological spectrum of large intestinal lesions with clinicopathological correlation. J Clin Diagn Res 2015;9:EC30-4.
2. Rasool M, Mubeen B, Saifandrabi R. Histopathological study of neoplastic lesions of large intestine in Kashmir valley, India. Int J Res Med Sci 2014;2:1097-100.
3. Peedikayil MC, Nair P, Seena SM, Radhakrishnan L, Sadasivan S, Naryanan VA, Balakrishnan V. Colorectal cancer distribution in 220 Indian patients undergoing colonoscopy. Indian J Gastroenterol 2009;28:212-5.
4. Dajani YF, Kamal MF. Colorectal juvenile polyps: An epidemiological and histopathological study of 144 cases in Jordanians. Histopathology 1984;8:765-79.
5. Roth SI, Helwig EB. Juvenile polyps of the colon and rectum. Cancer 1963;16:468-79.
6. Tony J, Harish K, Ramachandran TM, Sunilkumar K, Thomas V. Profile of colonic polyps in a southern Indian population. Indian J Gastroenterol 2007;26:127-9.
7. Eshghi MJ, Fatemi R, Hashemy A, Aldulaimi D, Khodadoostan M. A retrospective study of patients with colorectal polyps. Gastroenterol Hepatol Bed Bench 2011;4:17-22.
8. Laishram RS, Kaiho N, Shimray R, Devi SB, Punyabati P, Sharma DC. Histopathological evaluation of colorectal carcinomas status in Manipur, India. Int J Pathol 2010;8:5-8.
9. Chaitanya B, Ramakrishna BA, Shanthi V, Reddy S. Microscopy After Colonoscopy: An Institutional Experience In India. Int J Med Res Rev 2014;2:92-97.
10. Shah A, Wani NA. A study of colorectal adenocarcinoma. Indian J Gastroenterol 1991;10:12-3.
11. Caliskan C, Guler N, Karaca C, Makay O, Firat O, Korkut MA. Negative prognostic factors in colorectal carcinoma: An analysis of 448 patients. Indian J Surg 2010;72:243-8.

How to cite this article: Pavani M, Raghu K, Srikanthbabu Y, Chandrasekhar KPA, Parimala S, Aravinda B, Manoja V, Pramod M. Histopathological Study of Lesions of Colon - A 5-Year Study. Int J Sci Stud 2017;5(2):65-68.

Source of Support: Nil, **Conflict of Interest:** None declared.