Print ISSN: 2321-6379
Online ISSN: 2321-595X
DOI: 10.17354/ijss/2017/239

Original Article

Comparative Study between Parenchyma-preservation Surgery and Lobectomy in Lung Aspergilloma - A Retrospective Analysis

G Josephraj[1], P Rani[2], M Muthukumar[2], B Karthikeyan[3], Heber Anandan[4]

[1]Professor and Chief, Department of Cardiothoracic Surgery, Madurai Medical College, Madurai, Tamil Nadu, India, [2]Senior Assistant Professor, Department of Cardiothoracic Surgery, Madurai Medical College, Madurai, Tamil Nadu, India, [3]Junior Resident, Department of Cardiothoracic Surgery, Madurai Medical College, Madurai, Tamil Nadu, India, [4]Senior Clinical Scientist, Department of Clinical Research, Dr. Agarwal's Healthcare Limited, Chennai, Tamil Nadu, India

Abstract

Introduction: Aspergilloma is considered the most frequent and most easily recognized clinical form of pulmonary aspergillosis. It is most frequent tuberculosis that predisposes to aspergilloma.

Aim: This study is a retrospective study aimed at evaluating the complications between the parenchyma-preserving surgery and lobectomy while dealing with pulmonary aspergilloma patients.

Materials and Methods: A total of 146 patients underwent surgery for pulmonary aspergilloma at growth releasing hormone Cardio-Thoracic Surgery Department, Madurai. The patient's records were retrieved and 60 cases were studied with reference to clinical profile, radiological findings, and indications for surgery.

Results: Mortality rate is 2.8% in lobectomy and 0% in cavernostomy. 31% morbidity in post-lobectomy versus 4% morbidity in the post-cavernostomy group.

Conclusion: Parenchyma-preserving surgery can be carried out to treat pulmonary aspergilloma with negligible mortality and morbidity.

Key words: Aspergillosis, Lobectomy, Parenchyma-preserving surgery, Pulmonary aspergilloma, Tuberculous cavity

INTRODUCTION

Aspergilloma is considered the most frequent and most easily recognized clinical form of pulmonary aspergillosis although there are no data to support such an assertion.[1-3] All species of *Aspergillus* can produce Aspergilloma, which arises as a result of the colonization of a pre-existing cavity, cyst or bulla, or as a consequence of chronic diseases such as tuberculosis, bronchiectasis, bullous emphysema, advanced stages of pulmonary fibrosis or sarcoidosis, ankylosing spondylitis, or pulmonary infarction. It has also been described in cavities produced by other fungi. Of these diseases, it is most frequently tuberculosis that predisposes to aspergilloma.[4-6]

Pulmonary aspergilloma is the only surgically relevant manifestation of *Aspergillus* infection known for a century, and half now, controversy still surrounds its optimal management. The controversy surrounds the surgical management stems from the perceived threat of morbidity and mortality consequent to surgery, and it has led to recommendations of parenchyma-preserving surgeries as the best resort in symptomatic cases mainly with hemoptysis.[7-10]

Chronic lung aspergilloma caused by the colonization of pre-existing pulmonary parenchymal cavities with *Aspergillus* fungus, this cause the formation of the entangled mass of fungal hyphae, blood elements, and debris in the cavity. This is known as fungal ball/aspergilloma. This

Access this article online

www.ijss-sn.com

Month of Submission : 00-0000
Month of Peer Review : 00-0000
Month of Acceptance : 00-0000
Month of Publishing : 00-0000

AQ2

Corresponding Author: P Rani, Senior Assistant Professor, Department of Cardiothoracic Surgery, Madurai Medical College, Madurai, Tamil Nadu, India. Phone: 09003156763. E-mail: karthikeyanctsmbbs@gmail.com

is the most common presentation of the pulmonary aspergillosis.[11-14]

Other forms of lung *Aspergillus* infection non-invasive form results in respiratory symptoms related to immunological reaction to the fungus in the tracheobronchial tree. This form does not require surgical management.[6,15-17]

The third type of *Aspergillus* infection of the lung is invasive pulmonary aspergillosis - this occurs exclusively in the immunocompromised hosts. This is severe form erodes pulmonary vessels leads to thrombosis and hemorrhagic infarction.[18,19]

Most of the patients with pulmonary aspergilloma present with compromised lung function and nutritional status. For them, the surgical management is the least procedures in the form of cavernostomy instead of lobectomy. This study compares the complications of parenchyma-preserving surgery and lobectomy in patients with pulmonary aspergilloma and recommends minimal surgery in the form of cavernostomy for pulmonary aspergilloma is enough to deal with most cases which give rise to less morbidity and mortality.[16,17]

The real incidence of aspergilloma is unknown. In 1970, the British Tuberculosis and Thoracic Association[4] published a study of 544 patients with tuberculous cavities, of whom 11% had radiologic signs of aspergilloma.[3,20]

Aims

This study is a retrospective study aimed at evaluating the complications between the parenchyma-preserving surgery and lobectomy while dealing with pulmonary aspergilloma patients.

MATERIALS AND METHODS

This study was conducted in the Department of Cardiothoracic Surgery at Government Rajaji Hospital, Madurai, Tamil Nadu, India. The patients' records were retrieved and 60 cases were studied with reference to clinical profile, radiological findings, indications for surgery, and surgical procedures used and short- and long-term post-operative outcomes.

There were 37 male and 23 female patients in the age group of 26-58 years with the mean of 32 years. Overall, 30 cases of lobectomies with 30 cases of parenchyma-preserving surgery - cavernostomy were taken for the study. All the cases were operated under general anesthesia with double-lumen endotracheal tubes for adequate isolation and selective ventilation and operated through a standard posterolateral thoracotomy. Considerable adhesions were seen in all of my study cases. Significant intraoperative hemorrhage occurred despite liberal use of electrocautery. Of 60 cases, only one patient who had undergone lobectomy for pulmonary aspergilloma died of metabolic complication of diabetes mellitus.

RESULTS

A majority of patients were in the age group of 26-58 years comprising. Male patients were comparatively predominant in our study, comprising 61.7% and female patients about 38%.

The patients were largely admitted for the evaluation of hemoptysis, some cases with productive cough, few cases suffered from fever, chest pain, and dyspnea. The severity was categorized as moderate, severe, and massive depending upon whether the amount of bleeding over a 24 h period was <150 ml, 150-300 ml, or more than 300 ml, respectively.

During evaluation, the diagnosis of aspergilloma was made primarily on the radiological examination showing "cavity lesion" on plain chest radiography and demonstration of lung parenchymal cavity with free ball lesion (meniscus sign) on the computerized tomography chest.

Hemoptysis is the most common presentation in the study, comprising 52 cases followed by chronic cough and fever (Graph 1).

Cavitary lesion with air crescent sign is the most common radiological feature in our study followed by destroyed lung and bronchiectasis (Graph 2).

The most common location in right upper lobe followed by left upper lobe mostly because of the location of tuberculosis cavitary lesions in these locations (Graph 3 and Figures 1-5).

Lobectomy was done in 58% of cases and cavernostomy with obliteration of empty cavity and ligation open bronchi done in 42% of cases (Graph 4).

Post-operative course was uneventful in 42 out of 60 cases. One patient died of metabolic complication of diabetes mellitus 1 month after discharge immediately after admission. Mortality rate is 2.8% in lobectomy and 0% in cavernostomy. 12 cases developed complications out of 12, 11 cases in the lobectomy group. 31% morbidity in post-lobectomy versus 4% morbidity in post-cavernostomy group. Post-operative courses were complicated in lobectomy cases by persistent air leak exceeding 10 days in 5 cases and persistent pleural space in 3 cases as empyema.

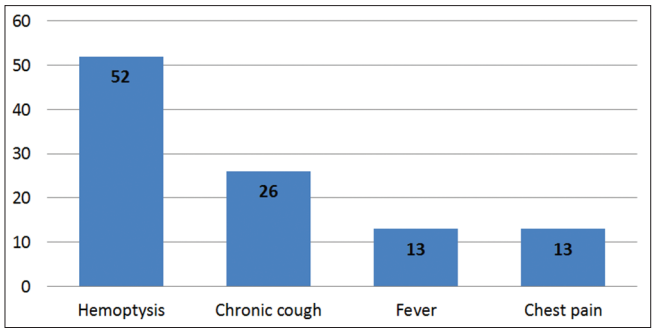

Graph 1: Clinical presentation of study patients

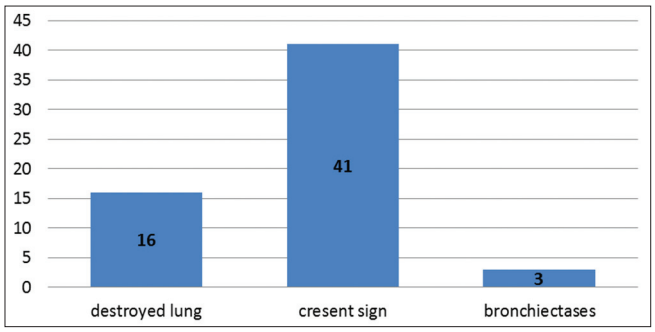

Graph 2: Radiological presentation of study patients

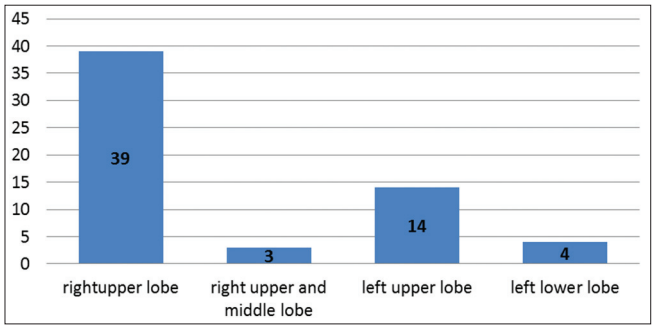

Graph 3: Location of aspergilloma

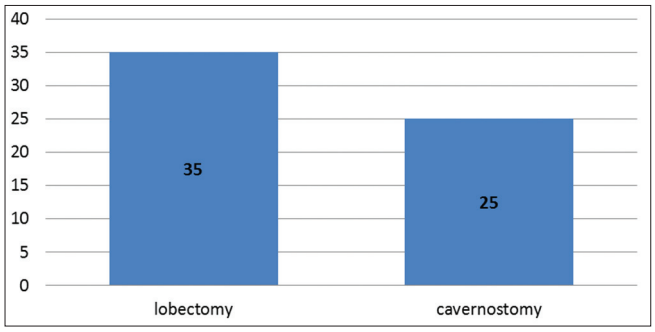

Graph 4: Procedure done

Massive hemorrhage occurred in 3 lobectomy cases. Air leak responded to prolonged tube drainage in 3 cases and two patients managed with thoracoplasty. Empyemas were managed with thoracostomy and local irrigation and resolved over 1 to 3 months. Massive hemorrhages were treated with blood transfusion and volume replacement.

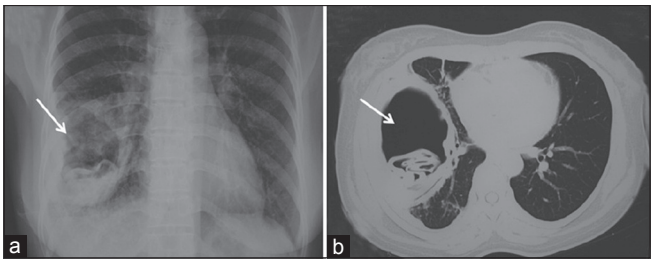

Figure 1: (a and b) Right lower lobe aspergilloma in old tuberculosis cavity

Figure 2: Right upper lobe aspergilloma in old tuberculosis cavity

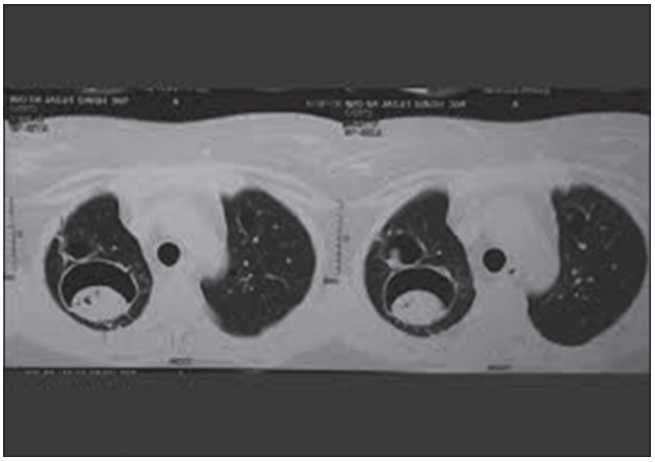

Figure 3: Right upper lobe aspergilloma in old tuberculosis cavity

Follow-up

Follow-up was completed in 59 cases for a mean period of 3.5 years. Two recurrences were in the follow-up cases. One patient who had a lobectomy earlier was treated with contralateral cavernostomy and the other is previous cavernostomy done case who refused for surgery is being managed conservatively for mild episodic hemoptysis.

Of 60 cases, 28 cases were diabetics. A definitive diagnosis was established in all cases by histopathological

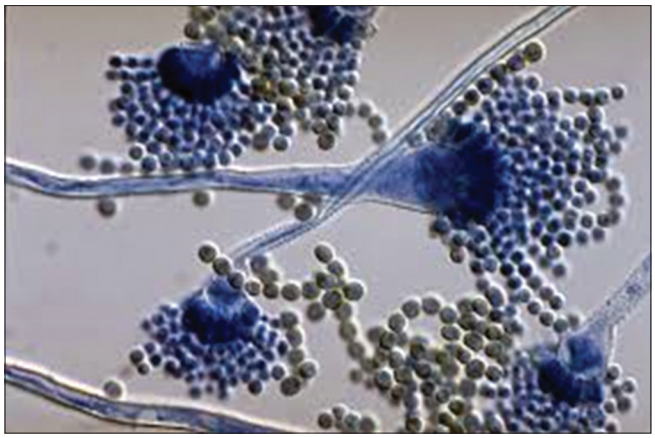

Figure 4: Electron microscopy of post of biopsy

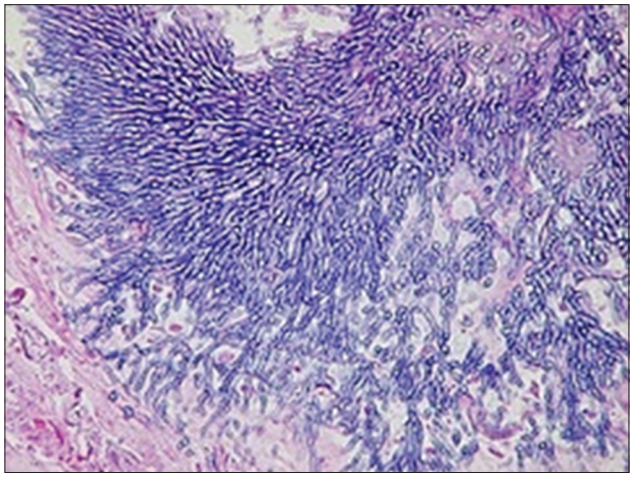

Figure 5: Histopathological examination of post of biopsy

examination and incidental radiological finding in 4 cases. Most of the cases wanted surgical management only for hemoptysis. Aspergilloma causes hemoptysis that can be massive or recurrent and indeed fatal and reportedly complicated 50-80%. Underlying postulated mechanism of hemoptysis includes erosion of vascular cyst wall by movement of ball, elaboration of trypsin-like substance or endotoxins by the fungus Type III antigen-antibody reaction, or the underlying disease itself. The bleeding is commonly from bronchial arteries and frequently remits on its own, very rarely fatal bleed from intercostals vessels. Patients presented with hemoptysis all managed with bed rest, antitussive, antifibrinolytics, and blood transfusion. No cases required emergency surgery or arterial embolization.

Review of the literature reveals that the major obstacle to acceptance of surgery as the treatment has been the high mortality and morbidity consequent to surgery. The surgery is the only definitive modality of treatment is now well-established and non-debatable issue. The drug therapy of aspergilloma has highly inconsistent and largely incomplete results though the antifungal therapy we have not used antifungal therapy in our cases at our institution.

DISCUSSION

Aspergillus fumigatus, the most common agent of aspergilloma, is a saprophytic fungus ubiquitously present over dead and decaying surfaces. In healthy hosts, it produces no disease. When it colonizes a pre-existing pulmonary cavity, mycetoma, or aspergilloma forms.[1,2,4] Natural history of aspergilloma varies from a stable lesion to progression and even spontaneous regression is reported in about 5% cases.[18,19] Predicted mortality due to aspergilloma is reported at a rate of 6% per annum.[18] A definitive diagnosis is established by histopathological examination and culture of the involved tissue but is largely entertained on the basis of characteristic radiological demonstration of fungal ball.[1,2,13] Sputum isolation has doubtful specificity given frequent airway colonisation.[1,2,4]

Serological diagnosis has reasonably good sensitivity and specificity but has limited clinical importance in a typical scenario. In our series, as is usually the case, radiology formed the basis of diagnosis. In addition, the culture of the resected specimen was always obtained. Aspergilloma manifests either as an incidental radiological finding or causes hemoptysis that can be massive, or recurrent and, indeed, fatal and reportedly complicates 50-80% of cases.[16]

Chronic lung aspergilloma caused by the colonization of pre-existing pulmonary parenchymal cavities with *Aspergillus* fungus. This causes the formation of the entangled mass of fungal hyphae, blood elements, and debris in the cavity. This is known as fungal ball/Aspergilloma. This is the most common presentation of the pulmonary aspergillosis.[11-14]

The bleeding is commonly from the bronchial arteries and frequently remits on its own. Very rare instances of first episode fatal bleed have been reported and are presumed to occur from intercostal vessels.[17] Patients presenting to us, including those with severe hemoptysis, could all be managed conservatively with bed rest, antitussives, antifibrinolytic, and blood transfusion.

Other forms of lung *Aspergillus* infection - non-invasive form results in respiratory symptoms related to immunological reaction to the fungus in the tracheobronchial tree. This form does not require surgical management.[6,15-17]

The third type of *Aspergillus* infection of the lung is invasive pulmonary aspergillosis - this occurs exclusively in the immunocompromised hosts. This is severe form erodes pulmonary vessels leads to thrombosis and hemorrhagic infarction.[18,19]

Most of the patients with pulmonary aspergilloma present with compromised lung function and nutritional status. For them, the surgical management is the least procedures in the form of cavernostomy instead of lobectomy. This study compares the complications of parenchyma-preserving surgery and lobectomy in patients with pulmonary aspergilloma and recommends minimal surgery in the form of cavernostomy for pulmonary aspergilloma is enough to deal with most cases which give rise to less morbidity and mortality.[16,17]

CONCLUSION

Surgery not only offers symptomatic control but also confers survival advantage and is being used even in asymptomatic cases to pre-empt massive bleed and death. A marked decline in morbidity and mortality in lung parenchyma-preserving surgery has led to its greater acceptance in recent years. Most of the deaths are due to respiratory failure in the post-operative period. Hence, judicious selection of cases and appraisal of respiratory functional reserve of the patient is important - with that parenchyma-preserving surgery preserves lung parenchyma and prevents respiratory failure. In conclusion, parenchyma-preserving surgery can be carried out to treat pulmonary aspergilloma with negligible mortality and morbidity.

REFERENCES

1. Battaglini JW, Murry GF, Keagy BA, Starek PJ, Wilcox BR. Surgical management of symptomatic pulmonary aspergilloma. Ann Thorac Surg 1985;39:512-6.
2. Chen J, Chang Y, Luh SP, Lee JM, Lee YC. Surgical treatment for pulmonary aspergilloma: A 28 year experience. Thorax 1997;52:810-3.
3. Nucci M, Pulcheri W, Spector N, Oliveira HP. Pulmonary mycetoma treatment in neutropenic patients. Rev Assoc Med Bras 1993;39:188.
4. Gilli SC, Gilbert MM, Frazatto Júnior C, Metze K, Ulson CM, Metze IL. Surgical treatment of fungal bolus in acute lymphoid leukemia. Rev Assoc Med Bras 1992;36:174-6.
5. Kay PH. Surgical management of pulmonary aspergilloma. Thorax 1997;52:753-4.
6. Caidi M, Kabiri H, Al Aziz S, El Malout A, Benosman A. Surgical treatment of pulmonary aspergilloma. 278 cases. Presse Med 2006;35:1819-24.
7. Oakley RE, Petrou M, Goldstraw P. Indications and outcome of surgery for pulmonary aspergilloma. Thorax 1997;52:813-5.
8. Shapiro MJ, Albelda SM, Mayock RL, McLean GK. Severe hemoptysis associated with pulmonary aspergilloma. Percutaneous intracavitary treatment. Chest 1988;94:1225-31.
9. Jewkes J, Kay PH, Paneth M, Citron KM. Pulmonary aspergilloma: Analysis of prognosis in relation to haemoptysis and survey of treatment. Thorax 1983;38:572-8.
10. Loeckell H. On the transthoracic evacuation of a pulmonary mycetoma using Maurer drainage. Prax Pneumol 1964;18:757-62.
11. Shirakusa T, Ueda H, Saito T, Matsuba K, Kouno J, Hirota N. Surgical treatment of pulmonary aspergilloma and *Aspergillus empyema*. Ann Thorac Surg 1989;48:779-82.
12. Park CK, Jheon S. Results of surgical treatment for pulmonary aspergilloma. Eur J Cardiothorac Surg 2002;21:918-23.
13. Henderson AH, Deslaurier J, Ritcey EL, Pearson JE. Surgery in pulmonary aspergillosis. J Thorac Cardiovasc Surg 1975;70:1088-94.
14. Henderson AH, Pearson JE. Treatment of bronchopulmonary aspergillosis with observations on the use of natamycin. Thorax 1968;23:519-23.
15. Lee JG, Lee CY, Park IK Kim DJ, Chang J, Kim SK, *et al*. Pulmonary aspergilloma: Analysis of prognosis in relation to symptoms and treatment. J Thorac Cardiovasc Surg 2009;138:820-5.
16. Allan A, Sethia B, Turner MA. Recent experience of the treatment of aspergilloma with a surgical stapling device. Thorax 1986;41:483-4.
17. Butz OR, Zvetina JR, Leininger BJ. Ten-year experience with mycetomas in patients with pulmonary tuberculosis. Chest 1985;87:356-8.
18. Sagan D, Gozdziuk K, Korobowicz E. Predictive and prognostic value of preoperative symptoms in the surgical treatment of pulmonary aspergilloma. J Surg Res 2010;163:35-43.
19. Addrizzo-Harris DJ, Harkin TJ, McGuinness G, Naidich DP, Rom WN. Pulmonary aspergilloma and AIDS. A comparison of HIV-infected and HIV-negative individuals. Chest 1997;111:612-8.
20. Niwa H, Yamakawa Y, Fukai I, Kiriyama M, Kobayashi Y, Masaoka A. Subclavian artery branch ligation reduces hemorrhage during resection of pulmonary aspergilloma. Ann Thorac Surg 1995;59:1234-5.

How to cite this article: Josephraj G, Rani P, Muthukumar M, Karthikeyan B, Anandan H. Comparative Study between Parenchyma-preservation Surgery and Lobectomy in Lung Aspergilloma - A Retrospective Analysis. Int J Sci Stud 2017;5(2):163-167.

Source of Support: Nil, **Conflict of Interest:** None declared.