

Long-term Benefits of Closed Mitral Commissurotomy and their Hemodynamic Profile

G Josephraj¹, M Muthukumar², P Rani², B Karthikeyan³, Heber Anandan⁴

¹Professor and Chief, Department of Cardiothoracic Surgery, Madurai Medical College, Madurai, Tamil Nadu, India, ²Senior Assistant Professor, Department of Cardiothoracic Surgery, Madurai Medical College, Madurai, Tamil Nadu, India, ³Junior Resident, Department of Cardiothoracic Surgery, Madurai Medical College, Madurai, Tamil Nadu, India, ⁴Senior Clinical Scientist, Department of Clinical Research, Dr. Agarwal's Healthcare Limited, Tirunelveli, Tamil Nadu, India

Abstract

Introduction: Cardiac surgery began to grow only after closed mitral commissurotomy (CMC) surgery which revolutionized the world and safeguard patients from the devastation of rheumatic fever and its common complication, rheumatic mitral stenosis. Event in modern era, CMC still plays a role in the treatment arms of rheumatic mitral stenosis.

Aim: This study is done to evaluate 50 patients who have completed 10 years or more after CMC and the long-term benefits attained by the patients.

Methods: Fifty patients who had completed 10 years following CMC surgery were chosen randomly and their clinical details collected and evaluated in terms of symptoms improvement or progression of the disease.

Results: Among 50 patients studies, 37 patients (74%) does not need any further intervention. 14% patients had mitral restenosis. 2% patients had mitral restenosis with left atrial clot. 10% patients had progression of disease associated with mitral regurgitation, aortic stenosis, and regurgitation.

Conclusion: This study had proved that CMC to be good palliative and cost-effective treatment allows for substantial reduction of cost and makes it the procedure of choice in developing nations like our country even in this modern era.

Key words: Balloon mitral valvotomy, Closed mitral commissurotomy, Mitral restenosis stenosis, Mitral valve replacement, Rheumatic fever, Rheumatic mitral stenosis

INTRODUCTION

In patients with mitral stenosis, the need for therapeutic intervention can be assessed by clinical and non-invasive data. Mitral valve replacement is indicated when marked dyspnea on mild exertion, dyspnea at rest or pulmonary edema, hemoptysis, atrial fibrillation, recurrent systemic emboli, or right ventricular failure occur in a patient with a mitral valve area (MVA) of $<1.5 \text{ cm}^2$ as measured by Doppler echocardiography.^{1,2} This treatment will entail life-long anticoagulation in the majority of patients.

Closed mitral commissurotomy (CMC) is considered a valid therapeutic alternative, but open commissurotomy and balloon valvotomy may be performed in patients with no significant calcification of valve cusps and no major concomitant mitral regurgitation.^{3,4}

Preservation of the subvalvular apparatus and left ventricular geometry can be considered the most important advantages of these techniques. More severe chronic symptoms are generally required as an indication for mitral valve replacement because of the additional long-term imponderabilities imposed by an implanted artificial device.^{5,6} Therefore, in patients with mitral stenosis different symptoms and clinical findings will eventually lead to different interventions.

Clinical symptoms and diagnostic findings in patients with mitral stenosis are usually determined by the extent of the stenosis. Compared to a normal MVA of $>4 \text{ cm}^2$,

Access this article online



www.ijss-sn.com

Month of Submission : 03-2017

Month of Peer Review : 04-2017

Month of Acceptance : 05-2017

Month of Publishing : 05-2017

Corresponding Author: M Muthukumar, Senior Assistant Professor, Department of Cardiothoracic Surgery, Madurai Medical College, Madurai, Tamil Nadu, India. Phone: 09003156763. E-mail: karthikeyanctsmbs@gmail.com

MVA in patients with severe mitral stenosis is usually reduced to <math><1.5\text{ cm}^2</math>. In older patients, symptoms are frequently influenced by concomitant diseases (e.g, atrial fibrillation, arterial hypertension, or lung disease). An important diagnostic element besides anamnesis, auscultation, electrocardiogram (ECG), and chest X-ray is echocardiography, which is required to measure non-invasively and reliably the mitral valve gradient (MVG), the MVA and morphologic changes to the valves, as well as concomitant valvular disease, ventricular functions and, where appropriate, left atrial thrombi.^{7,8}

CMC results in a significant reduction of MVG, accompanied by an increase in the MVA. The results and success of CMC are influenced by the morphology of the valves and the changes to the subvalvular apparatus.^{9,10}

Aim

This study is done to evaluate 50 patients who have completed 10 years or more after CMC and the long-term benefits attained by the patients.

MATERIALS AND METHODS

This study was conducted in the Department of Cardiothoracic Surgery at Government Rajaji Hospital, Madurai, Tamil Nadu, India. 50 patients who had completed 10 years following CMC surgery were chosen randomly and their clinical details collected and evaluated in terms of symptoms improvement or progression of the disease. Patients with associated coronary artery disease or other valvular diseases at the time of surgery were excluded from the study. Primary data were collected from the operative registers, discharge summary, post-operative follow-up notes, and personal communication. Initially, the selected patients for study were intimated by post, and they were asked to attend the outpatient department with all the available records with them.

Proper history taking, clinical examination, X-ray chest, ECG, echocardiogram, and transesophageal echo in selected patients were done and compared with the old records. All the collected data were compiled and following variables such as age, sex, symptoms, and mitral valve orifice were analyzed methodically.

RESULTS

A majority of patients were in the age group of 30-50 years comprising sex distribution in the following manner. Age corresponds to the present age and not at the time of operation. Female patients predominant in our study comprising 84% and male patients about 16% because of

the increased prevalence of rheumatic fever in females (Figures 1 and 2). Six patients had the New York Heart Association (NTHA) Class I symptoms. 30 patients had Class II and 13 patients Class III. Only 2 patients had Class IV symptoms (Figure 3). Only 9 patients comprising 18% of our study had atrial fibrillation, and its complications with 72% of patients were in sinus rhythm.

22 patients (44%) had mitral valve orifice of size 1-1.5 cm on echocardiogram, and only 6 patients (12%) had orifice <math><1\text{ cm}</math> with severe symptoms. Others had orifice more than 1.5 cm (Table 1).

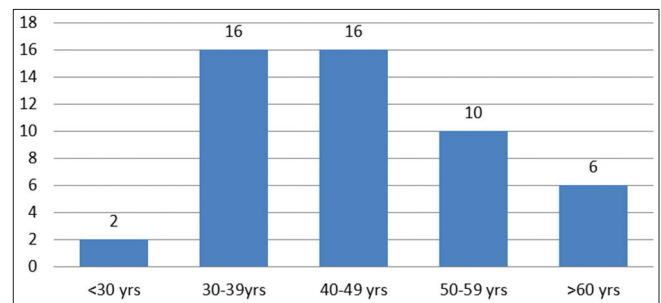


Figure 1: Distribution of study patients in age group

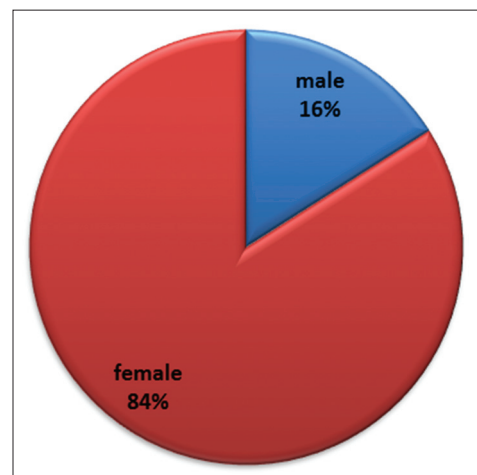


Figure 2: Distribution of gender

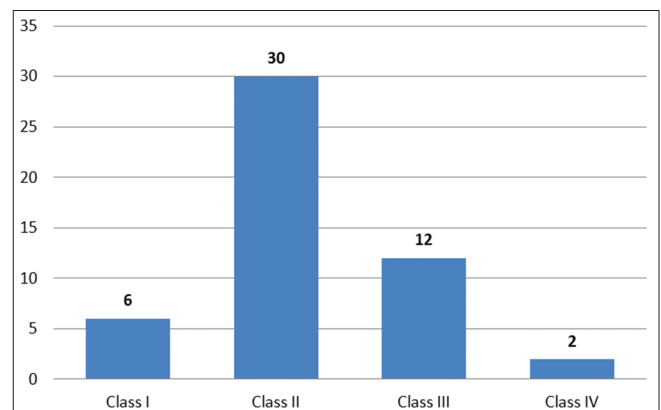


Figure 3: New York Heart Association class symptoms

34 patients (68%) had mitral valve orifice of size 1-1.5 cm on echocardiogram, and only 16 patients (32%) had orifice <1 cm with severe symptoms. Other had orifice more than 1.5 cm (Table 2).

15 patients (30%) had associated mitral valve regurgitation and two needed intervention. Seven patients (14%) had associated aortic valve pathology and two needed intervention. One patient had left atrial clot for whom mitral valve replacement along with excision of left atrial clot done (Table 3).

Seven patients comprising 14% of our study had mitral valve restenosis and mitral valve replacement is done for five among them two patients had undergone balloon mitral valvotomy. 37 patients (74%) did not need any intervention and they were on medical management with anti-failure plus penicillin prophylaxis (Figure 4).

DISCUSSION

From analyzing the data with regard to age of the patients, 32 patients are in the age group of 30-49 years. Hence, 64% of the patients are able to cope up with life during their prime age after CMC. The opening of the stenotic valve has helped the patients definitely and provided benefits even during their active life works.

Most of the female patients have undergone normal deliveries after the procedure, proving its effectiveness during the maximum stress and flow across the mitral valve.

Number of patients more than 50 years was 16, that is, 32%. These patients have definitely benefited from CMC procedure.

With regard to the sex distribution, 16% were males and 84% were females. Female patients benefited more following CMC. The reason for lesser benefit to the males may be due to the physical activity which produces more stress on the stenotic valve and progression of the disease and early myocardial damage.^{11,12}

Rheumatic fever history was definitely positive in 64% of patients and the remaining patients are not able to exactly know regarding the episode of rheumatic fever or no history of rheumatic fever.

Analyzing the clinical status and the functional status of the patients, 36 out of 50, that is, 72% were living in NYHA Class I or II which gives evidence that most of the patients are benefited symptomatically in the long term after CMC without restriction of physical activity.^{13,14}

Table 1: MVO size on echocardiogram

MVO	Number of patients
<1 cm	6
1-1.5	22
1.6-2.5	20
>2.5	4

MVO: Mitral valve orifice

Table 2: Wilkin’s score on echocardiogram

Score	Number of patients
<8	34
>8	16

Table 3: Associated lesions along with mitral pathology

Other lesion	Number of patients	Needed intervention
Mitral regurgitation	15	2
Aortic stenosis/regurgitation	7	2
Left atrial clot	1	1

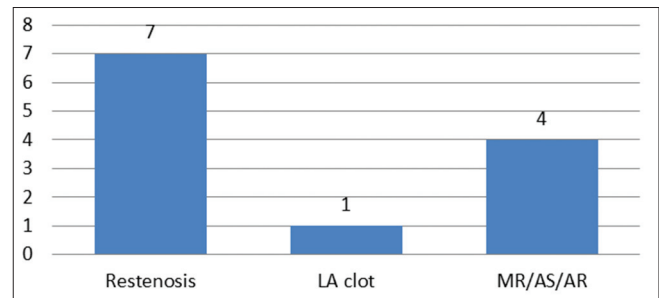


Figure 4: Patients needed intervention 10 years post closed mitral commissurotomy status

82% of patients we have studied were in sinus rhythm which gives a clue that valve opening following CMC definitely relieved the stasis in left atrium and delayed restenosis which is comparable to many studies.¹⁵⁻¹⁷

22 patients we have studied, that is, 44% had mitral valve orifice <1.5 cm² (moderate stenosis) and 24 (48%) had mitral orifice more than 1.5 cm², which is comparable to many other studies.¹⁸⁻²⁰

CONCLUSION

We conclude that CMC had done definitive role in good opening up of the valve and relieved the gradient across the valve. Restenosis after CMC was 14% which conclude good results of the procedure delayed the restenosis for more than 10 years. In a government set-up like our hospital, where there is still a prevalence of rheumatic heart

disease among the poor socioeconomic group who are not affordable, CMC procedure gives good hemodynamic, and symptomatic results in the long term with avoidance of prosthetic valve complications and without the need of sophisticated equipment for balloon mitral valvotomy. This study has proved that CMC to be good palliative and cost-effective treatment. The closed approach allows for a substantial reduction in cost compared to recent modern procedures making it procedure of choice in suitable cases in developing nations.

REFERENCES

- Cutler EC, Levine SA. Cardiomy and valvulotomy for mitral stenosis: Experimental observations and clinical notes concerning an operated case with recovery. *Boston Med Surg J* 1923;188:1023-7.
- Souttar HS. The surgical treatment of mitral stenosis. *Br Med J* 1925;2:603-6.
- Harken DE, Ellis LB, Ware PF, Norman LR. The surgical treatment of mitral stenosis: I. Valvuloplasty. *N Engl J Ed* 1948;239:801-9.
- Eguaras MG, Luque I, Montero A, Garcia MA, Calleja F, Roman M, *et al.* A comparison of repair and replacement for mitral stenosis with partially calcified valve. *J Thorac Cardiovasc Surg* 1990;100:161-6.
- Inoue K, Owaki T, Nakamura T, Kitamura F, Miyamoto N. Clinical application of transvenous mitral commissurotomy by a new balloon catheter. *J Thorac Cardiovasc Surg* 1984;87:394-402.
- Farhat MB, Boussadia H, Gandjbakhch I, Mzali H, Chouaieb A, Ayari M, *et al.* Closed vs. Open mitral commissurotomy in pure noncalcific mitral stenosis: Hemodynamic studies before and after operation. *J Thorac Cardiovasc Surg* 1990;99:639-44.
- Spencer FC. Results in closed mitral valvotomy. *Ann Thorac Surg* 1988;45:355.
- Burckhardt D, Hoffmann A, Kiowski W. Treatment of mitral stenosis. *Eur Heart J* 1991;12 Suppl B:95-8.
- Jacovella G, Vajola FS, Masini V, Rabitti G, Chidichimo G. Re-operations after commissurotomy. Indications and results. Our experience with 39 cases. *Minerva Cardioangiol* 1974;22:691-6.
- Detter C, Fischlein T, Feldmeier C, Nollert G, Reichenspurner H, Reichart B. Mitral commissurotomy, a technique outdated? Long-term follow-up over a period of 35 years. *Ann Thorac Surg* 1999;68:2112-8.
- Patel JJ, Shama D, Mitha AS, Blyth D, Hassen F, Le Roux BT, *et al.* Balloon valvuloplasty versus closed commissurotomy for pliable mitral stenosis: A prospective hemodynamic study 1991;18:1318-22.
- Multicenter experience with balloon mitral commissurotomy. NHLBI Balloon Valvuloplasty Registry Report on immediate and 30-day follow-up results. The National Heart, Lung, and Blood Institute Balloon Valvuloplasty Registry Participants. *Circulation* 1992;85:448-61.
- Essop MR. Relief of rheumatic mitral stenosis - When and how? *Am J Cardiol* 1994;73:85-7.
- Essop R, Rothlisberger C, Dullabh A, Sareli P. Can the long-term outcomes of percutaneous balloon mitral valvotomy and surgical commissurotomy be expected to be similar? *J Heart Valve Dis* 1995;4:446-52.
- Neelakandan B. Closed mitral valvotomy: Tactile control. *Ann Thorac Surg* 1996;61:775-6.
- Commerford PJ, Hastie T, Beck W. Closed mitral valvotomy: Actuarial analysis of results in 654 patients over 12 years and analysis of preoperative predictors of long-term survival. *Ann Thorac Surg* 1982;33:473-9.
- Rutledge R, McIntosh CL, Morrow AG, Picken CA, Siwek LG, Zwischenberger JB, *et al.* Mitral valve replacement after closed mitral commissurotomy. *Circulation* 1982;66:1162-6.
- Eskilsson J. Mitral stenosis after closed commissurotomy. A clinical and echocardiographic long-term follow-up study. *Acta Med Scand Suppl* 1982;664:1-116.
- Molajo AO, Bennett DH, Bray CL, Brooks NH, Rahman AN, Moussalli H, *et al.* Actuarial analysis of late results after closed mitral valvotomy. *Ann Thorac Surg* 1988;45:364-9.
- Salerno TA, Neilson IR, Charrette EJ, Lynn RB. A 25-year experience with the closed method of treatment in 139 patients with mitral stenosis. *Ann Thorac Surg* 1981;31:300-4.

How to cite this article: Josephraj G, Muthukumar M, Rani P, Karthikeyan B, Anandan H. Long-term Benefits of Closed Mitral Commissurotomy and their Hemodynamic Profile. *Int J Sci Stud* 2017;5(2):181-184.

Source of Support: Nil, **Conflict of Interest:** None declared.