

# Scar Endometriosis - A Cause for Painful Scar Swelling – A Surgeons Perspective

S Agarwal<sup>1</sup>, Mehul Baldha<sup>2</sup>, S Kansal<sup>3</sup>, H Makwana<sup>4</sup>

<sup>1</sup>Assistant Professor, Department of Obstetrics and Gynaecology, SMIMER, Surat, Gujarat, India, <sup>2</sup>Resident, Department of Surgery, Government Medical College, Surat, Gujarat, India, <sup>3</sup>Associate Professor, Department of Surgery, Government Medical College, Surat, Gujarat, India, <sup>4</sup>Registrar, Department of Surgery, Government Medical College, Surat, Gujarat, India

## Abstract

**Introduction:** The presence of functional endometrial tissue outside the uterine cavity in the vicinity of scar is described as scar endometriosis. It is a rare disease. It usually occurs in patients who had a history of gynecological or obstetrical surgery in the past.

**Objective:** To diagnose scar endometriosis and evaluation of management strategy in patients of scar endometriosis.

**Materials and Methods:** This study was conducted in New Civil Hospital, Government Medical College, Surat, from January 2013 to March 2016. The patients presenting with painful scar swellings with history of gynecological or cesarean were included in the study. All patients were investigated by ultrasonography (USG), fine needle aspiration cytology (FNAC), and preoperative investigations. Medical treatment was given in the form of oral contraceptive pills, progestogens, and aromatase inhibitor. A wide surgical excision was done in non-responding and other patients.

**Observation:** During this period, we got 167 cases of painful abdominal wall swelling who had history of lower segment cesarean section /gynecological surgery ranging from 3 months to 3 years. Out of 167 cases, 4 patients (2.4%) were confirmed to have scar endometriosis. All patients were offered both medical as well as surgical treatment, but only one patient responded to it while three patients (1.8%) ended up with surgical intervention in the form of wide excision of swelling which was found to be definitive management.

**Conclusion:** Scar endometriosis should always be suspected in women presenting with painful swelling in/or near the abdominal scar specially with history of gynecological or obstetric surgery. A pre-operative diagnosis should be made by imaging technique and FNAC. Medical treatment is not much helpful; wide excision is the treatment of choice.

**Key words:** Caesarian section, Painful scar, Scar endometriosis

## INTRODUCTION

Endometriosis is defined as the presence of functional endometrial tissue outside the uterine cavity. Incidence of it varies from 5% to 10% in all women of all reproductive age group. Ectopic sites range from pelvis to lungs to extremities.

Scar endometriosis is a rare disease with an incidence of <1%.<sup>1,2</sup> This disease causes severe pain varying with

menstrual cycle causing mental and physical trauma to patient. It can occur after any surgery involving chance of contact with endometrial tissue such as episiotomy, hysterotomy, ectopic pregnancy, laparoscopy, tubal ligation, but cesarean section lower segment cesarean section (LSCS) seems to be most common surgery.<sup>3</sup> The time interval between operation and presentation has varied from 3 months to 10 years in different series.<sup>4</sup> On examination usually, a nodular, extra-peritoneal tender swelling with restricted mobility is found near scar commonly at the lateral border. The ectopic endometrial tissue is more commonly found in the abdominal skin and subcutaneous tissue compared to muscle and fascia.<sup>5</sup> Diagnosis of scar endometriosis is often difficult as it has to be differentiated from stitch granuloma, incisional hernia, lipoma, dermoid cyst, neuroma, etc. Diagnosis can be made by good surgical and gynecological history, imaging techniques such as ultrasonography (USG), computed tomography

### Access this article online



www.ijss-sn.com

**Month of Submission :** 03-2016  
**Month of Peer Review :** 04-0000  
**Month of Acceptance :** 05-0000  
**Month of Publishing :** 05-0000

**Corresponding Author:** Dr. Mehul Baldha, Department of Surgery, Government Medical College, Surat, Gujarat, India.  
 E-mail: dr.mehulbaldha@gmail.com

(CT)/magnetic resonance imaging (MRI), and fine needle aspiration cytology (FNAC). Medical treatment with the use of progestogens, oral contraceptive pills (OCP), and aromatase inhibitor gives only partial relief in symptoms. There have been reports of the use of gonadotrophin agonist (leuprolide acetate), but it has been found to provide an improvement in symptoms only with no change in lesion size.<sup>6</sup> The treatment of choice is always wide excision of lesion, which is diagnostic as well as therapeutic at the same time.

## MATERIALS AND METHODS

This retrospective study was conducted in New Civil Hospital and Government Medical College from January 2013 to March 2016. A total of 167 patients presenting with painful abdominal wall swellings with history of gynecological or cesarian section were included in the study. All patients were investigated by USG, FNAC/biopsy and pre-operative investigations. Medical and surgical treatment options were offered to all in the form of OCP, progestogens, aromatase inhibitors (danazole or Latrozole) or surgery. Those patients unwilling to continue on medical treatment due to poor relief in symptoms, non-responding patients and patients willing for surgical treatment directly were offered wide surgical excision of the lesion with 1-2 cm of Histopathological examination (HPE) free margins with meshplasty. Symptomatic relief and recurrence were assessed on follow-up visits up to 2 months.

## OBSERVATION

In our study, out of 167 patients of painful anterior abdominal wall swelling in reproductive age group varying from 25 to 40 years, only four cases (2.4%) had scar endometriosis on FNAC/HPE of excised tissue. The common clinical presentation was painful abdominal wall swelling at or near scar. The time interval from LSCS to clinical presentation varies as per etiology. (Annexure-1). One patient opted for continuing medical management as her symptoms were markedly relieved. Rest of the three cases underwent surgery either as first line treatment or after failure of medical treatment. These cases were operated by wide excision with 1-2 cm HPE negative margins followed by prolenemeshplasty to cover the defect under spinal anesthesia. All cases had recovered well without any post-operative complication like hematoma, seroma or wound infection. Excised tissue was send for HPE to confirm endometrial glandular tissue histologically (Figure 1).

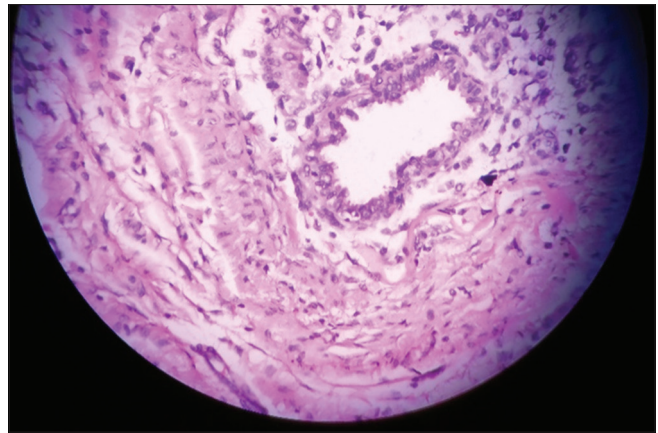


Figure 1: Histopathological examination of scar endometriosis

## DISCUSSION

Scar endometriosis is a rare disease with incidence rate 0.03-0.05% as per literature review.<sup>1,2</sup> In our study, it is 2.4% which can be due to lesser no of patients studied. It should be differentiated from other anterior abdominal wall swellings as stitch granuloma, seroma, hematoma, incisional hernia, dermoid cyst, neuroma, tuberculoma, etc. The time interval between LSCS and presentation varies from 3 months to 10 years in different series.<sup>4</sup> But in our study, it is 3 months to 3 years post LSCS. The mode of spread of endometrial tissue has different theories varying from iatrogenic inoculation of endometrial tissue, subsequently, stimulated by estrogen to produce scar endometrioma.<sup>4</sup> USG with color Doppler shows irregular shaped non-homogeneous hypoechoic lesion with altered vascularization. The CT/MRI is also contribute to diagnose scar showing solid well-circumscribed mass, giving a better distinction between the muscles and subcutaneous tissue.<sup>7</sup> FNAC/HPE of excised tissue is confirmatory diagnostic tool for scar endometriosis showing endometrial glandular tissue and stroma.<sup>8</sup> Medical management of scar endometriosis with progestogens, OCP or aromatase inhibitors give symptomatic relief partially with poor compliance due to the risk of side effect like amenorrhea, hirsutism, and acne. The treatment of choice is wide excision with 1-2 cm HPE negative margins to reduce chance of recurrence followed by meshplasty to cover the defect in muscles.<sup>9</sup> In the cases of repeated recurrence chances of malignant transformation should be kept in mind although chances of malignant transformation of scar endometriosis tissue are rare.<sup>10</sup>

Follow-up of cases of scar endometriosis is required because of chances of recurrence, which may require revision surgery. However, meticulous technique and utmost care during LSCS might be helpful in the prevention of disease.

## CONCLUSION

Scar endometriosis is a rare condition occurring after gynecological surgery/LSCS with the incidence of 0.3-0.5% of all cases of endometriosis.

The change in size and pain intensity during menses is the characteristic of the ectopic endometrial tissue. The definitive treatment is wide excision with 1 cm free margins followed by meshplasty to cover the defect in muscles.

A high index of suspicion should be kept in mind for patient presenting as post LSCS scar painful swelling. HPE is confirmatory for diagnosis.

## REFERENCES

1. Francica G, Giardiello C, Angelone G, Cristiano S, Finelli R, Tramontano G. Abdominal wall endometriomas near cesarean delivery scars: Sonographic and color doppler findings in a series of 12 patients. *J Ultrasound Med* 2003;22:1041-7.
2. Kaloo P, Reid G, Wong F. Caesarean section scar endometriosis: Two cases of recurrent disease and a literature review. *Aust N Z J Obstet Gynaecol* 2002;42:218-20.
3. Bumpers HL, Butler KL, Best IM. Endometrioma of the abdominal wall. *Am J Obstet Gynecol* 2002;187:1709-10.
4. Seydel AS, Sickel JZ, Warner ED, Sax HC. Extrapelvic endometriosis: Diagnosis and treatment. *Am J Surg* 1996;171:239.
5. Celik M, Bulbuodlu E, Buyukbese MA, Cetin Kaya A. Abdominal wall endometrioma: Localizing in rectus abdominis sheath. *Turk J Med Sci* 2004;34:341-3.
6. Rivlin ME, Das SK, Patel RB, Meeks GR. Leuprolide acetate in the management of cesarean scar endometriosis. *Obstet Gynecol* 1995;85:838-9.
7. Balleyguier C, Chapron C, Chopin N, Hélénon O, Menu Y. Abdominal wall and surgical scar endometriosis: Results of magnetic resonance imaging. *Gynecol Obstet Invest* 2003;55:220-4.
8. Hussain M, Noorani K. Primary umbilical endometriosis – A rare variant of cutaneous endometriosis. *J Coll Physicians Surg Pak* 2003;13:164-5.
9. Collins AM, Power KT, Gaughan B, Hill AD, Kneafsey B. Abdominal wall reconstruction for a large caesarean scar endometrioma. *Surgeon* 2009;7:252-3.
10. Hashim H, Shami S. Abdominal wall endometriosis in general surgery. *Internet J Surg* 2002;3.

**How to cite this article:** Agarwal S, Baldha M, Kansal S, Makwana H. Scar Endometriosis - A Cause for Painful Scar Swelling – A Surgeons Perspective. *Int J Sci Stud* 2016;4(2):225-227.

**Source of Support:** Nil, **Conflict of Interest:** None declared.

## ANNEXURE: 1

Cause of painful scar swelling	N (%)	Time of clinical presentation since surgery
Stitch granuloma	13 (7.7)	1-3 months
Haematoma	05 (3.0)	2 weeks to 2 months
Seroma	62 (3.7)	1-6 months
Abscess	43 (2.6)	1-6 months
Incisional hernia	22 (1.3)	3 months to 3 years
Hypertropic scar/keloid	15 (8.9)	6 months to 3 years
Endometrioma	04 (2.4)	6 months to 3 years
Tuberculoma	03 (1.8)	6 months to 3 years
Total	167	