Case Report

# Role of Bipedicle Advancement Flap in Closure of Post Traumatic Leg Defect: A Surgical Case Report

**A Veerasigamani[1], S Sivaraj[2]**

[1]Assistant Professor, Department of Plastic Surgery, Vinayaka Mission's Kirupananda Variyar Medical College & Hospitals, Salem, Tamil Nadu, India, [2]Assistant Professor, Department of Orthopedic Surgery, Vinayaka Mission's Kirupananda Variyar Medical College & Hospitals, Salem, Tamil Nadu, India

## Abstract

One of the most important goals in the management of severe open injury of the lower limb is to obtain adequate soft-tissue coverage which promotes adequate revascularization and good wound healing. Severe, lower extremity, soft tissue defects pose a significant challenge to the reconstructive surgeon and often require the placement of free flaps, which is a complex procedure. We report a case of 27-year-old male who came to us with the old fracture of both bones-right leg with chronic osteomyelitis and infected implant. After sequestrectomy and debridement, he had necrosis of overlying skin exposing the tibial shin. A bipedicled fasciocutaneous advancement flap was taken from the adjacent soft tissue and wound covered. Postoperatively wound healed well with good cosmetic result thus demonstrating the superiority of the conventional bipedicled advancement flap over other sophisticated methods of tissue transfer.

**Keywords:** Bipedicled flap, Chronic osteomyelitis, Fasciocutaneous flap, Tibia fracture

## INTRODUCTION

The commonest causes of large open wounds in the lower limbs are trauma, tumor resection, peripheral vascular disease and diabetes.[1] The primary aim of therapy in such cases is to restore and maintain stability and ambulation. The reconstructive strategies differ depending on underlying condition.[2] The main objective in the management of severe open wound of the lower limb is to provide adequate soft tissue coverage. This is because it takes a close wound, to promote revascularization of the underlying tissues, and to prevent late infections and nonunion which occur due to persistent bone ischemia. Soft-tissue closure of the defects of lower limbs is presently a more frequent procedure due to the increased incidence of "high energy" traumas that affect this location.[1] At many anatomical sites, bipedicled flaps provide best quality soft tissue cover. The indications for the use of bipedicled flap have not been well-defined. This simple technique is often not used due to the advent of more complex modalities of tissue transfer.[3,4] This case report describes our experience with lower extremity wound reconstruction using the bipedicled flap as an alternative to pedicled flaps and free flaps.

Access this article online

Website: www.ijss-sn.com

## CASE REPORT

A 27-year-old male patient presented to us with complaints of non-healing ulcer and seropurulent discharge over the anterior aspect of right leg. Patient had road traffic accident 8 months back with a degloving injury and Grade II open comminuted fracture of both bones right leg. He was treated surgically with wound debridement, intramedullary nailing and split skin grafting (SSG).

On the presentation to us, patient had infected implant with multiple sequestra with union of two cortices in tibia with discharging sinus (Figure 1). In view of persisting osteomyelitis, nail removal, debridement and sequestrectomy (Figure 2) done through anterolateral approach to tibia.

On the second post-operative day, there was necrosis of overlying skin exposing the shin of tibia (Figure 3). There

**Corresponding Author:**
Dr. A Veerasigamani, No: 88, 89, S. K City, Dasanaikenpatty, Salem - 636 201, Tamil Nadu, India. Phone: +91-9789273290.
Email- drnarenkapv@yahoo.com

was gross infection still persist. Hence on the 3rd day, surgical debridement was done along with external fixator application to provide additional support to the fracture site (Figure 4). Once the infection got subsided, the wound was left with exposed bone and wound gaping of size about 10 cm × 5 cm over the anteromedial aspect of middle third of the right tibia (Figure 5).

Bipedicle advancement flap was planned (Figure 6). The measurement for the bipedicle is done initially (Figure 7). If the primary defect length is considered as X. To be

**Figure 1: Multiple sequestra with union of two corticies and discharging sinus**

**Figure 2: Post sequesterectomy**

**Figure 3: Necrosis of overlying skin**

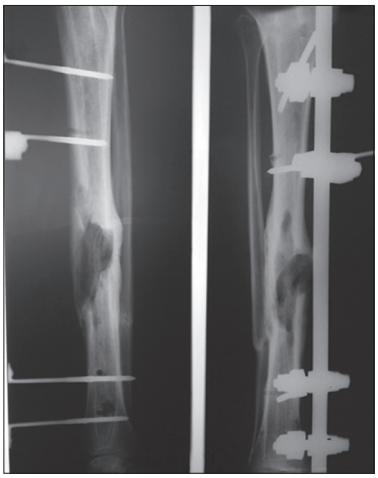

**Figure 4: Surgical debridement with external fixator**

**Figure 5: Primary defect area**

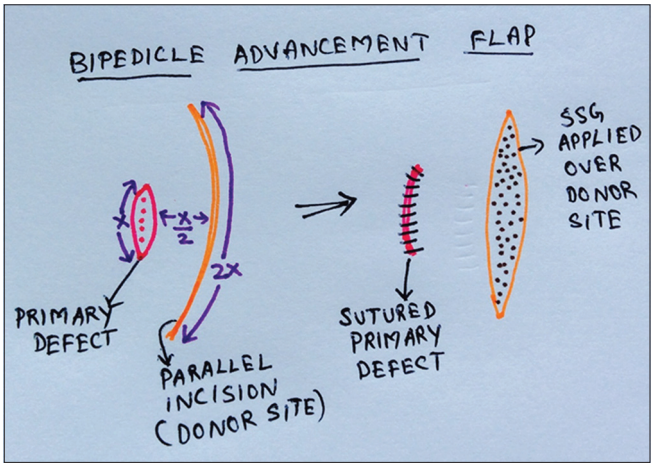


**Figure 6: Plan of bi-pedicle advancement flap**

adequate, the length of the incision should be twice that of the primary defect 2X. The width of the flap should be at least half the length of the primary defect X/2. The incision is curved parallel to the primary defect, which is a relaxing incision (Figure 8). Then mobilize the flap with the underlying fascia and its blood supply (Figure 9). A flap prepared with these dimensions can be moved easily into the new position and sutured to the primary defect (Figure 10). SSG is taken from the contralateral thigh (Figure 11). The donor site is closed with a SSG (Figure 12). Complete wound coverage with flap was achieved (Figure 13). Postoperatively wound healed, and fracture united well followed by removal of external fixator (Figures 14-16).

**Figure 7: Measurement for calculating incision**

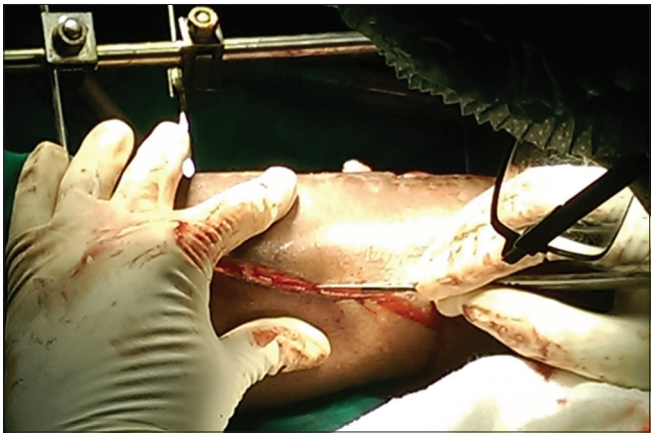

**Figure 8: Incision for the flap**

## DISCUSSION

Lower extremity trauma, with open soft tissue and tibial injuries, frequently occurs due to road traffic accidents and usually requires a plastic surgery involvement. The relatively unprotected anatomy of tibia leads to frequent bone exposure, which require soft tissue coverage. Open fractures of the tibia have high incidences of malunion and infection, and require emergent irrigation and debridement. Management of the mangled lower extremity requires the meticulous teamwork of the trauma, vascular, orthopedic and plastic surgeons.[5]

Closure of defects of the lower limb is still a significant problem when tendon or bone is exposed. Complex soft-tissue defects of lower limb pose a significant challenge to the plastic surgeon in reconstruction. It requires the use of free flaps, which is demanding on the patient as well as the operating surgeon. Bipedicled flaps are random flaps with blood supply from two pedicles. It allows the surgeon to use local tissue with an augmented blood flow. Bipedicled flaps are simple to elevate and economical in operating time.[6]

There has been a major switchover in the treatment of soft tissue defects in open fractures. A strong inclination has developed towards non-microvascular flaps rather than the time-consuming and tedious free flaps. The advent of reliable, robust and technically less demanding techniques has allowed covering small and moderate sized soft tissue

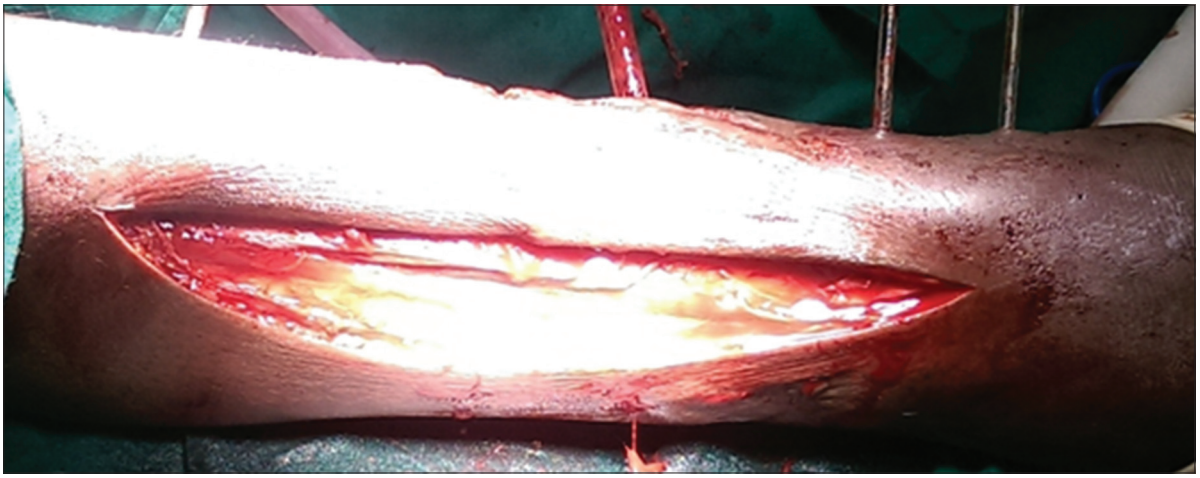

**Figure 9: After mobilizing the flap with the underlying fascia and its blood supply**

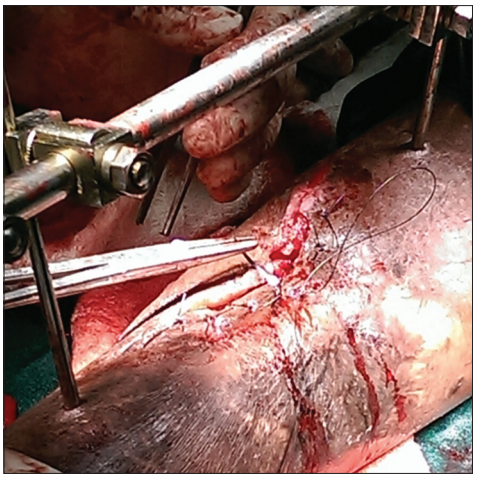

Figure 10: Primary defect is sutured

Figure 11: Split skin graft taken from contralateral thigh

Figure 12: Skin grafting to the donor site

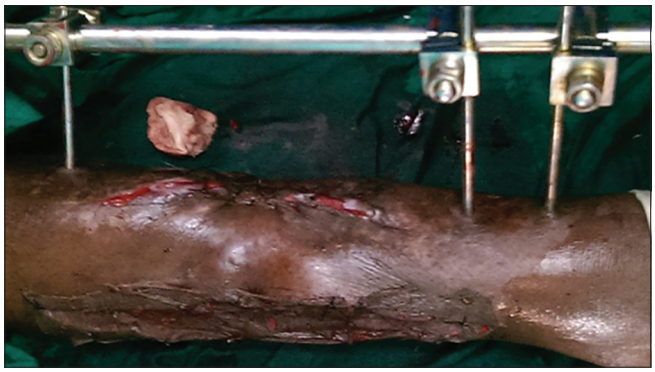

Figure 13: Complete wound coverage with flap

Figure 14: 1 month post-operative

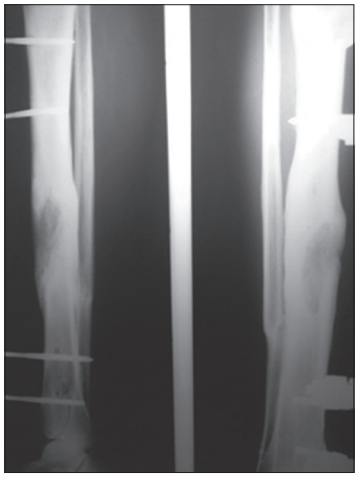

Figure 15: X-ray taken after 6 months

defects, which was once considered as a territory for a microvascular flap. The sharp decline in the usage of microvascular flaps in the management of acute lower limb trauma is also due to fairly high incidence of failure and the expense of the treatment. The injured limbs are even more difficult to salvage when they face failure of free flap.[7] These factors reveal that free flaps are useful only when the locoregional flaps are not possible either because of the large size of the defect or extensive local tissue trauma.

In 1996 Schwabegger *et al.* reported 12 cases of successful wound closure on the lower leg with the versatile bipedicled flap. Their study showed a low incidence of

**Figure 16: 6 months post-operative showing complete wound healing**

minor complications, whether it was used as a cutaneous, fasciocutaneous or as a myofasciocutaneous flap. They concluded that though it is an old method it is an invaluable and less complicated one.[8]

Saleh *et al*. in 2008 studied the various therapeutic options in the reconstruction of lower extremity injuries. They found that local random type of fasciocutaneous flaps are simple to raise and replace like with like tissue, appropriate for minor defects and do not need unusual surgical skills except for the disadvantage of unsightly donor site. Hence, they remain one of the useful methods of skin cover for lower extremity defects.[9]

## CONCLUSION

In plastic and reconstructive surgery, the pedicled fasciocutaneous and myocutaneous flaps are often used to treat larger defects of the lower leg. Bipedicled advancement flaps offer a safe, swift and a simple alternative for covering complex open wounds of the lower extremities.[6] As a result of the above procedure, full tissue closure, marked functional recovery, and good cosmetic results are achieved with the least damage to the donor site due to dual blood supply. This again emphasizes the fact that in spite of being a conventional procedure, it is a gold standard method. In addition, the operative technique is relatively short and simple to perform, and it doesn't need the use of microsurgical skills and instruments. If it is applied to selected indications and appropriate patients, the bipedicled flap is certainly a reliable alternative to the other, more sophisticated modern methods of tissue transfer.[10]

## REFERENCES


1. Rios-Luna A, Fahandezh-Saddi H, Villanueva-Martínez M, López AG. Pearls and tips in coverage of the tibia after a high energy trauma. Indian J Orthop 2008;42:387-94.
2. Kadam D. Limb salvage surgery. Indian J Plast Surg 2013;46:265-74.
3. Tobin GR. Myocutaneous and muscle flaps: Refinements and new applications. Curr Probl Surg 1986;23:315-93.
4. Dujon DG, Khan UD, Aslam S. Bipedicle flaps: simple solutions for difficult problems in the extremities. Br J Plast Surg 1997;50:641-5.
5. Parrett BM, Pribaz JJ. Lower extremity reconstruction. Rev Med Clin Condes 2010;21:66-75.
6. Granzow JW, Li A, Suliman A, Caton A, Goldberg M, Boyd JB. Bipedicled flaps in posttraumatic lower-extremity reconstruction. J Plast Reconstr Aesthet Surg 2013;66:1415-20.
7. Kamath JB, Shetty MS, Joshua TV, Kumar A, Harshvardhan, Naik DM. Soft tissue coverage in open fractures of tibia. Indian J Orthop 2012;46:462-9.
8. Schwabegger A, Ninković M, Wechselberger G, Anderl H. The bipedicled flap on the lower leg, a valuable old method? Its indications and limitations in 12 cases. Scand J Plast Reconstr Surg Hand Surg 1996;30:187-93.
9. Saleh Y, Waheeb B, Abd-Elaziz MA, El-Oteify M. A suggested algorithm for post-traumatic lower limb soft tissue reconstruction. Egypt J Plast Reconstr Surg 2007;31:87-96.
10. Zayakova YK. Application of pedicle flaps for wound coverage of lower leg. J IMAB 2013;19:382-6.


**How to cite this article:** Veerasigamani A, Sivaraj S. Role of Bipedicle Advancement Flap in Closure of Post Traumatic Leg Defect: A Surgical Case Report. Int J Sci Stud 2014;2(8):246-250.

**Source of Support:** Nil, Conflict of Interest: None declared.