Case Report

Acute Myeloid Leukemia with Expanded Erythropoiesis: Diagnostic Dilemma

Pankti Haria[1], Nikhil Majethia[1], Sangita Margam[2], Nitin Gadgil[3], Alka Kalgutkar[4]

[1]Postgraduate, Department of Pathology, Lokmanya Tilak Municipal Medical College, Sion, Mumbai, Maharashtra, India, [2]Assistant Professor, Department of Pathology, Lokmanya Tilak Municipal Medical College, Sion, Mumbai, Maharashtra, India, [3]Associate Professor, Department of Pathology, Lokmanya Tilak Municipal Medical College, Sion, Mumbai, Maharashtra, India, [4]Head, Department of Pathology, Lokmanya Tilak Municipal Medical College, Sion, Mumbai, Maharashtra, India

Abstract

The clinical importance of acute myeloid leukemia (AML)with erythroid predominance is poorly understood. It is defined as erythroid precursors >50% of the total nucleated cells of bone marrow aspiration smears. According to WHO classification 2008, these are classified as AML with myelodysplastic syndrome (MDS)related changes (AML-MRC), AML-M6, t-MDS/AML, based on the blast or erythroid precursor count. As the result of the predominance of the erythroid component, a slight difference in the blast count leads to this leukemic condition to be assigned a different category. However, the significance of this particular entity lies in the fact that they are associated with a better prognosis than other types of AML and this conditions are known to behave as an MDS rather than AML. We present a case report of 11-year-old female who presented with severe anemia, hepatospenomegaly. On investigating, her peripheral blood picture was suggestive of severe anemia with thrombocytopenia with acute leukemia with erythroblasts. Her bone marrow aspirate showed hypercellularity with reversal of M:E ratio with a picture of "AML with erythroid predominance." Cytogenetics and immunophenotyping were suggestive of AML.

Keywords: Acute, Erythroid precursor cells, Leukemia, Myeloid

INTRODUCTION

Leukemia is the most common childhood cancer diagnosis, its subtype, acute myeloid leukemia (AML), account for about 18 % of the childhood leukemias.[1,2] The entity "AML with expanded erythropoiesis" is an uncommon variant of AML, which is poorly understood. It is defined as myeloid neoplasms with >50% erythroid cells out of the total nucleated cells on bone marrow aspiration smears.[3]

CASE REPORT

An 11-year-old female child presented with fever with chills since 10-15 days with increased fatigability, abdominal distension and bleeding tendencies since one month. The patient had a history of pancytopenia 1 year back with increased erythroblasts and patient received vitamin B12 for the same. No history of any cytotoxic therapy/radiation or similar complaints in the past. Examination revealed severe pallor and inguinal and cervical lymphadenopathy. Per abdomen examination revealed soft non-tender, massive hepatosplenomegaly. No petechiae/ecchymosis/bony tenderness/clubbing. Investigations revealed hemogram: Hemoglobin = 4.8 g%, total leukocyte count = 110,900/ul, platelet (Plt)= 54,000/ul. Peripheral smear showed (Figure 1): Red blood cell (RBC)morphology – hypochromasia++, anisocytosis++, microcytosis++, macrocytosis+, erythroblasts and *n* RBCs seen. Differential white blood cell count: blast = 71%, myelocytes = 8%, metamyelocyte = 16%, polymorphs = 02%, lymphocytes = 3%. Plt - reduced on smear. Bone marrow aspiration report (Figure 2): Cellularity – hypercellular, M: E ratio-1:5, erythroid series-marked erythroid hyperplasia with increase in pronormoblasts along with megaloblasts. Also seen are features of dyserythropiesis (9%) like nuclear budding, giant pronormoblasts along with abnormal mitotic figures, Myeloid series-blasts = 88% myelocytes = 02%, metamyelocytes = 03%, polymorphs = 05%,

Access this article online

Website: www.ijss-sn.com

Corresponding Author:
Dr. Pankti Haria, 60, Bhaudaji Cross Road, Rajlaxmi Bldg, 3rd Floor, Matunga, Mumbai - 400 019, Maharashtra, India.
Phone: +91-9920558670. E-mail: drpankti09@gmail.com

lymphocyte = 01%, eosinophil = 01%, megakaryocytic series-suppressed. Hence, the impression based on the peripheral blood and bone marrow aspiration picture was AML to rule out erythroleukemia/AML – MRC. However, further evaluation revealed the following, Cytochemistry: myeloperoxidase positive: Immunophenotype: Myeloid markers: CD13, CD33, CD117 positive, erythroid marker: Gly A negative, B-cell markers: CD10, CD19 negative, T-cell markers: CD3 negative, Others: CD34 positive: Cytogenetics: No evidence of del (5q)or del (7q). So the final impression was AML with expanded erythropoiesis. Post-treatment peripheral smear is showing clearance of the erythroid cells and reduction in the total blast count (Figure 3).

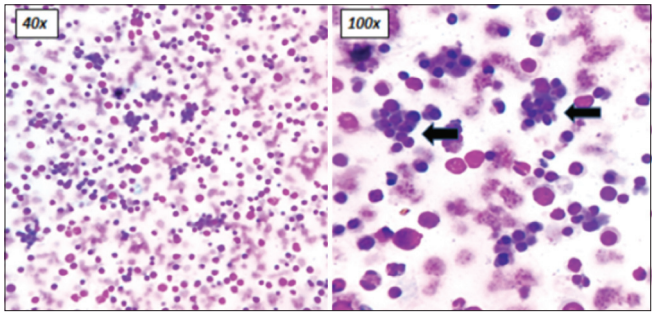

Figure 1: Peripheral smear showing erythroid predominance with leukocytosis with immature myeloid blast forms seen. Also seen are features of dyserythropoiesis like nuclear budding, irregular nuclear outline

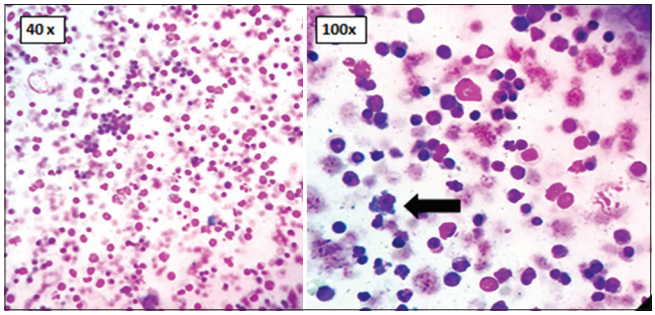

Figure 2: Hypercellular bone marrow aspirate smear with reversal of M:E ratio and increased blast forms >20%

DISCUSSION

According to the WHO classification 2008, AML with expanded erythropoiesis is classified as AML with MDS related changes (AML-MRC), AML-M6, MDS/AML, based on the blast or erythroid precursor count (Table 1). As the result of the predominance of the erythroid component, a slight difference in the blast count leads to this leukemic

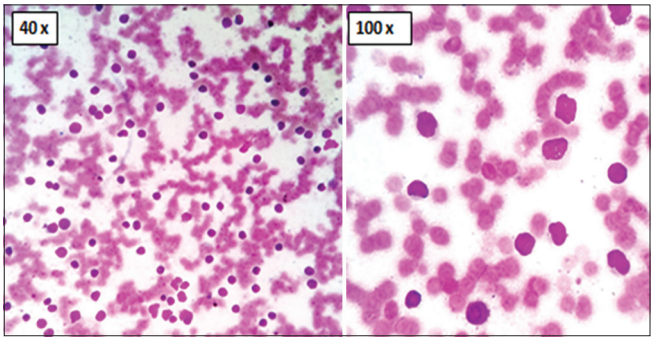

Figure 3: Post-treatment peripheral smear showing clearance of the erythroid cells and reduction in the total blast count

Table 1: Differential diagnosis of erythroid predominance[5]

Entity	Epidemiology and clinical features	Diagnostic features	Present case
Erythroleukemia	<5% of all the AML Predominantly in adults	≥50% erythroid precursors; ≥20% myeloblast of non-erythroid cells, dysplasia<50% of cells in<2 cell lines	<50% erythoid precursor cells
Pure erythroid leukaemia	Extremely rare Any age Profound anemia and circulating erythroblasts Aggressive disease	≥80% erythroblasts with no evidence of significant myeloblastic component PAS positivity	38% erythroblast Increased myeloblasts
MDS (RAEB)	Cytopenia Older age group	<20% blasts; dyserythropoiesis, MDS related cytogenetic abnormalities	No evidence of 5q and 7q del
AML-MRC	24-35% of all AML Mainly in elderly patients often presenting with severe pancytopenia	≥20% blasts; ≥50% dysplastic cells of 2 or 3 lineages; MDS-related cytogenetics, prior history of MDS or MDS/MPN	Blasts=53% <9% cells showing dyserythropiesis
t-AML	10-20% of all AML Any age group is affected	history of cytotoxic or radiation therapy Multiline age dysplasia is common	Not applicable
Non-neoplastic erythroid proliferations	Previous erythroid hyperplasia with left shift, hypersegmented neutrophils, giant metamyelocytes, giant platelets		
Megaloblastic anemia - erythropoietin treatment	Ineffective erythropiesis, dyserythropoiesis, multinucleation		
Congenital dyserythropiesis - medication and toxins	Clinical history, genetic studies History of methotrexate, benzene		

AML: Acute myeloid leukemia, MDS: Myelodysplastic syndrome, MRC: Myelodysplastic syndrome related changes

condition to be assigned a different category.[3] However, the significance of this particular entity is in the fact that they are associated with a better prognosis than other types of AML and these conditions are known to behave as an MDS rather than AML.[3,4] Initially, due to the increased erythropoietic cells in the peripheral smear as well as bone marrow aspirate along with myeloblasts,we thought it was a case of acute erythroid leukemia (AEL). Furthermore, the patient had a prior history of pancytopenia with increased erythroblast and now presenting with myeloblasts along with features of myelodysplasia, we thought we are dealing with a case of AML-MRC. However, immunophenotyping and cytogenetics studies revealed that there was no evidence of MDS or AEL and hence the diagnosis of "AML with expanded erythropoiesis." As a result of the predominance of erythroid component and increase in the total number of nucleated cells, a slight difference in the blast count leads to this leukemic condition to be assigned a different category.[4] These factors can lead to a diagnostic dilemma in cases of expanded erythropoiesis.

Also, Hasserjian *et al.* have suggested that AEL is a part of the continuum of MDS and AML with expanded erythropoiesis in which karyotype rather than an arbitrary blast cutoff is prognostically more relevant.[5]

CONCLUSION

Thus, in the case of "AML with expanded erythropoiesis" other parameters like cytogenetics, karyotype and degree of myelodysplasia might have a better basis than the percentage of erythroblasts and myeloblast for therapeutic decision.

ACKNOWLEDGMENT

Tata Memorial Hospital, Mumbai, Maharashtra, India.

REFERENCES

1. Mihova D, Zhang L. Acute erythroid leukemia - A review. North Am J Med Sci 2012;2:110-7.
2. Puumala SE, Ross JA, Aplenc R, Spector LG. Epidemiology of childhood acute myeloid leukemia. Pediatr Blood Cancer 2013;60:728-33.
3. Porwit A, Vardiman JW. Acute myeloid leukemia with expanded erythropoiesis. Haematologica 2011;96:1241-3.
4. Zuo Z, Medeiros LJ, Chen Z, Liu D, Bueso-Ramos CE, Luthra R, *et al*. Acute myeloid leukemia (AML)with erythroid predominance exhibits clinical and molecular characteristics that differ from other types of AML. PLoS One 2012;7:e41485.
5. Hasserjian RP, Zuo Z, Garcia C, Tang G, Kasyan A, Luthra R, *et al*. Acute erythroid leukemia: A reassessment using criteria refined in the 2008 WHO classification. Blood 2010;115:1985-92.

How to cite this article: Haria P, Majethia N, Margam S, Gadgil N, Kalgutkar A. Acute myleoid leukemia with expanded erythropoiesis: Diagnostic dilemma. Int J Sci Stud 2014;2(8)251-253.

Source of Support: Nil, **Conflict of Interest:** None declared.