

Role of Transrectal Ultrasound Scan in Patients with Fistula-in-ano: A Clinical Study

B R Sathya Krishna¹, Ramanjaneyulu Kantu²

¹Senior Consultant and Chief, Department of General Surgery, St. Martha's Hospital, Bengaluru, Karnataka, India, ²Post-graduate, Department of General Surgery, St. Martha's Hospital, Bengaluru, Karnataka, India

Abstract

Introduction: Anal fistulae are very common and have been studied extensively; some complex forms still continue to pose a difficult surgical problem. The aim of treatment for an anal fistula is to completely cure the fistula while preserving anal function and continence.

Materials and Methods: This is a prospective hospital-based study, comprising 30 patients who presented with fistula-in-ano to Department of general surgery, St. Martha's Hospital, Bengaluru.

Results: Of the 30 patients, who underwent transrectal ultrasound scan, fistulous tracts were correctly depicted by transrectal ultrasound scan in 26 patients and internal openings were depicted in 28 patients. All the patients underwent surgical intervention. Intraoperatively, all fistulous tracts and internal openings were identified in 26 and 24 patients, respectively. Intra-operative findings were correlated with those from the transrectal ultrasound scan. Of the 30 patients who underwent surgery, transrectal ultrasound scan accurately identified the presence as well as the correct location of the tract/tracts in 26 patients (86.66%) and the internal opening in 28 patients (93.3%). Transrectal ultrasonography had a sensitivity of 92.85% and 95.83% for identification of the tract and internal opening, respectively, and a positive predictive value of 96.29% and 82.14% for the tract and internal opening, respectively.

Conclusion: Transrectal ultrasound scan is a very valuable tool which gives an accurate road map of the fistulous tract/tracts, internal opening and external opening which is of paramount importance in successful management of fistula-in-ano. Transrectal ultrasound scan is a reliable, noninvasive, less expensive, investigative procedure which serves as a beacon for the surgeon intraoperatively to ensure complete cure and prevent recurrences.

Key words: Fistula-in-ano, Transrectal ultrasound scan, TRUS, Perianal abscess

INTRODUCTION

Fistula-in-ano is a chronic abnormal communication, usually lined to some extent by granulation tissue, which run outward from anorectal lumen (the internal opening) to an external opening on the skin of perineum or buttock (or rarely, in women, to the vagina).¹

Anal fistulae may be found in association with specific conditions such as Crohn's disease, tuberculosis,

lymphogranuloma venereum, actinomycosis, rectal duplication, foreign body, and malignancy.¹

Pathogenesis

The majority of perianal fistulas are of cryptoglandular origin. The cryptoglandular hypothesis states that perianal fistulas arise from anal canal glands, located at the level of the dentate line. The ducts of these glands flow into the crypts of Morgagni and drain into the anal canal.

If these glands become blocked, stasis occurs and infection develops. Because a substantial number of these glands branch out into the intersphincteric plane, the infection can pass the internal anal sphincter that serves as a barrier against bacterial contamination. From the intersphincteric plane, the infection may progress and extend in various ways. Patients usually present with an abscess. In about half of these patients, a fistula persists after drainage of the abscess.

Access this article online



www.ijss-sn.com

Month of Submission : 09-2016
Month of Peer Review : 10-2016
Month of Acceptance : 10-2016
Month of Publishing : 11-2016

Corresponding Author: Dr. Ramanjaneyulu Kantu, Room 12, Doctor's Quarters, St. Martha's Hospital, Opposite RBI, Nrupatunga Road, Bengaluru - 560 001, Karnataka, India. Phone: +91-9916031968. E-mail: anjanchow23@gmail.com

Anal glands provide free channels for infection to pass from the anal lumen deep into the sphincter muscles. Organisms entering by this route could set up acute inflammation in the longitudinal layer, which might then spread secondarily in almost any direction. If spread was downward in the longitudinal layer an acute perianal abscess would result; if it passed outward through the somatic muscles, it would reach the ischio-rectal space.

In the course of time, such an abscess would subside. It is quite likely that the anal glands, in common with many other glandular organs, can become the seat of chronic infection. Bacteria can reside and multiply in a gland which either is cystic or has an obstructed lumen. Being deep to the internal sphincter, the abscess will not readily discharge itself into the anal canal; the circular muscle coat of the bowel seems to be an effective barrier to infection. Once a chronic abscess has formed in this site infected material will continue to seep through any channel to the exterior. In fact, a fistula-in-ano is virtually a sinus secondary to a diseased anal gland, though the minute duct opening into an anal crypt makes it technically a fistula. This would fit in with the practical observation that about half the cases of anal fistula do not have a clinically detectable internal opening; in the remainder the overt internal opening is due to rupture of the intermuscular abscess through the internal sphincter into the anal canal. On this theory, then, fistula-in-ano is a granulation-tissue track which is kept open by an "infecting source" - That is, an abscess, deep to the internal sphincter, around a diseased anal gland. Knowing the anatomical site of the "infecting source," it should be possible to remove it and thereby allow the secondary track to heal. It must be emphasized at this point that the origin of a fistula is the abscess in the longitudinal layer; all other tracks and ramifications are secondary to this.²

Transrectal Ultrasonography (TRUS)

TRUS has been widely accepted as a popular imaging modality for evaluating the lower rectum, anal sphincters, and pelvic floor in patients with various anorectal diseases.³ It provides excellent visualization of the layers of the rectal wall and of the anatomy of the anal canal.

TRUS is an accurate tool for the staging of primary rectal cancer, especially for early stages (Figure 1).

Normal TRUS Anatomy of the Rectum and Anal Canal

The rectal wall is composed of five layers that can be clearly visualized by TRUS. The innermost hyperechoic line shows the interface of the balloon and the mucosal surface of the rectal wall.

The inner hypoechoic layer represents the mucosa and muscularis mucosa, followed by a slightly thicker hyperechoic submucosal layer.

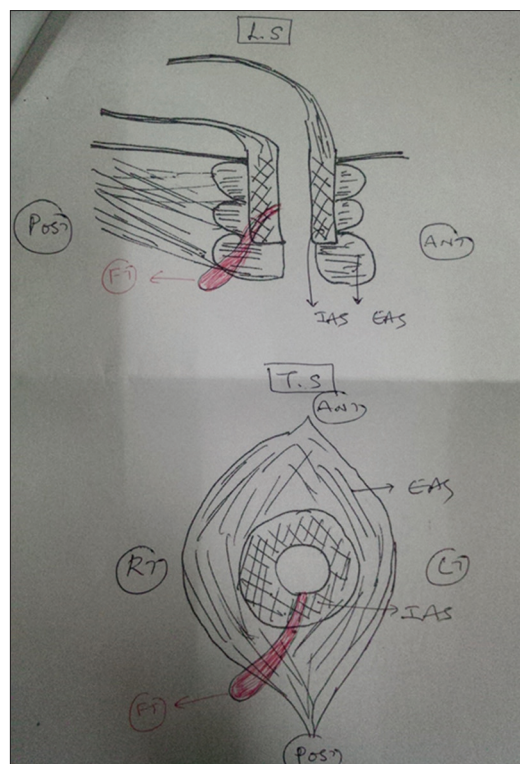


Figure 1: Diagrammatic representation of fistulous tract and internal opening by transrectal ultrasonography

The outer hypoechoic layer represents the muscularispropria, and the outermost hyperechoic layer corresponds to the perirectal fatty tissue.⁴

The anal canal is usually divided into three levels during the examination. The puborectalis muscle is easily seen and appears as a U-shaped echogenic band (sometimes described as a horseshoe sling) in the upper anal canal.

When retracting the probe, this hyperechoic band closes anteriorly and forms the external anal sphincter.

The internal anal sphincter displays a band of maximum thickness anteriorly in the middle anal canal, in combination with the external anal sphincter ring. The external anal sphincter is usually hyperechoic, broad, and lies immediately outside the internal anal sphincter.

Three-dimensional TRUS also provides anatomic details of perianal spaces that are located in the intersphincteric space between the internal and external anal sphincters: The pyramid-shaped ischioanal space surrounds the anal canal, and the supralelevator space is located superior to the levator ani muscle.

Perianal fistulas appear as hypoechoic tracts or focal soft tissue lesions within anal wall structures. Abscesses may contain internal gas or hyperechoic debris, and fistulas show a narrow and irregular path on TRUS. Depending

on the internal composition or stage of inflammation, the primary fistula tract appears as variable echogenic fluid with a thickened wall.

TRUS provides excellent imaging of the rectal wall layers and anal sphincter and therefore is excellent at visualizing intersphincteric fistulas and their relationship to the anal canal.⁴

Limitations of TRUS

Insufficient penetration of the ultrasound beam beyond the external anal sphincter limits the ability to visualize the region more distant from the anal canal, with the result that extensions from the primary tract may be missed.

One of the theoretical limitations of non-contrast TRUS is difficulty discriminating between an active tract and scar tissue since both tissues appear hypoechoic on noncontrast TRUS. The gas generated after H₂O₂ instillation makes the active tract hyperechoic. In this regard, contrasting with H₂O₂ could be more useful in patients with recurrent fistulae, which usually accompany previous operative scars.⁵

Aim

To study the role of transrectal ultrasound scan in patients with fistula-in-ano.

Objective

To measure the accuracy of transrectal ultrasound in detecting fistulous tracts and internal openings in pre-operative evaluation of fistula-in-ano.

MATERIALS AND METHODS

Source of Data

This study was conducted in the Department of Surgery, St. Martha's Hospital. The study group comprises patients with fistula-in-ano attending outpatient, inpatient Departments of Surgery.

Method of Collection of Data

A pro forma drafted for the study of all the patients with fistula-in-ano will be used.

Data collected will include:

1. Detailed history
2. Clinical examination findings
3. Routine and special investigations
4. Per-operative findings
5. Operative procedure.

Sample Size

30 patients studied over a period of 18-month from April 2014 to October 2015.

Parameters

Expected proportion = 0.80

Relative precision = 20

Confidence interval = 95.

Using online software N-master formula:

$$n = \left[\left(\frac{Z_{\alpha}}{2} + Z_{\beta} \right)^2 \rho(1 - \rho) \right] \div d^2$$

Z: Score at 95% confidence level (1.96)

P: Worst case percent

d: Margin of error (0.05%).

According to the previous studies online software formula indicates minimum sample size of 30.

Inclusion Criteria

All patients above the age of 18 years admitted with fistula-in-ano.

Exclusion Criteria

1. Patients not willing for transrectal ultrasonography.
2. Patients those who are not willing for surgery.

RESULTS

Frequency of Symptoms

Out of 30 patients in our study 6 Patients had accessory fistulous tracts and 24 patients had simple fistula-in-ano (Table 1 and Graph 1).

All 30 patients underwent TRUS. TRUS correctly detected all fistulous tracts in 3 patients out of 6 patients with accessory fistulous tracts. Accessory fistulous tracts were not detected by TRUS in 3 patients (Table 2 and Graph 2).

Of these 3 patients, 2 patients with suspicious complex fistula underwent MR-fistulography preoperatively, where accessory fistulous tracts were detected.

And in 1 patient accessory fistulous tracts were subsequently found intraoperatively.

In all 30 patients, main fistulous tracts were detected intraoperatively.

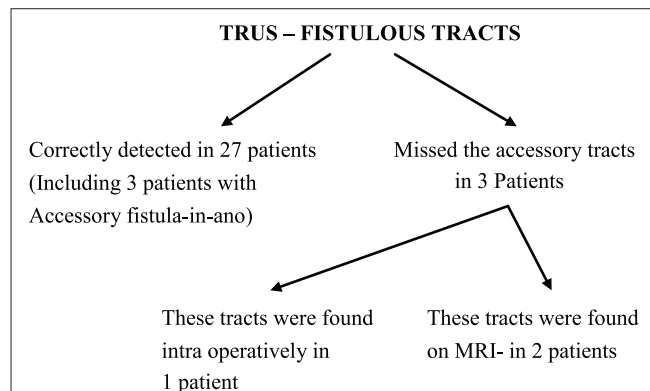
Table 1: Frequency of complex fistula-in-ano among the subjects in the study population

Complex fistula	Frequency (%)
Nil	24 (80)
Yes	6 (20)
Total	30 (100.0)

Table 2: Identification of fistulous tracts by TRUS

TRUS-fistulous tracts	Frequency (%)
Yes	27 (90.0)
No	3 (10.0)
Total	30 (100.0)

TRUS: Transrectal ultrasonography



Out of 30 patients in the study, 6 patients had accessory fistulous tracts. Of these 6 patients, accessory fistulous tracts were detected intraoperatively in 4 patients and accessory fistulous tracts were not detected in 2 patients (Table 3 and Graph 3).

Formulae Used To Calculate Accuracy⁶Sensitivity = $a/a+c$ = a (true positive)/ $a+c$ (true positive+false negative)

= Probability of being test positive when disease present.

Specificity = $d/b+d$ = d (true negative)/ $b+d$ (true negative+false positive)

= Probability of being test negative when disease absent.

PPV: = $a/a+b$ = a (true positive)/ $a+b$ (true positive+false positive)

= Probability (patient having disease when test is positive)

NPV: = $d/c+d$ = d (true negative)/ $c+d$ (false negative+true negative)

= Probability (patient not having disease when test is negative)

DISCUSSION

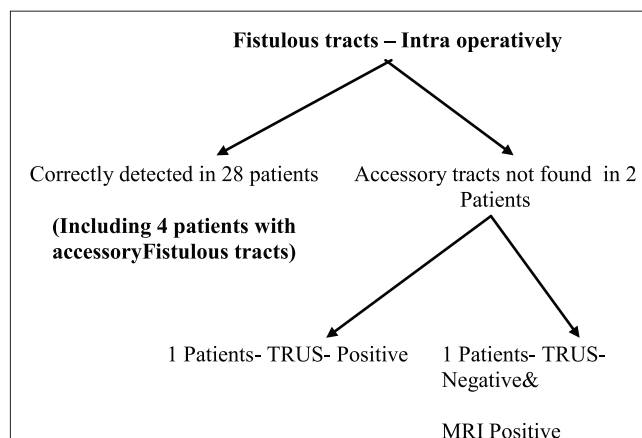
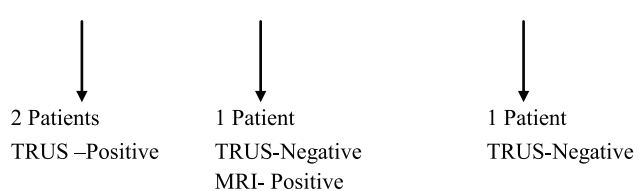
The aim of our study was to determine the accuracy of TRUS in identifying fistulous tracts and internal openings.

A total of 30 patients are included in the study.

The majority of the patients are in the age group of 18-40 years (57%) with male predominance. Male to female ratio of the present study is 5:1 (Table 4 and Graph 4).

Table 3: Identification of fistulous tracts intraoperatively

Intra-operative fistulous tracts	Frequency (%)
Yes	28 (93.33)
No	2 (6.66)
Total	30 (100.0)

**Intra op -Accessory fistulous tracts found in 4 patients****Table 4: Age and sex distribution of patients studied**

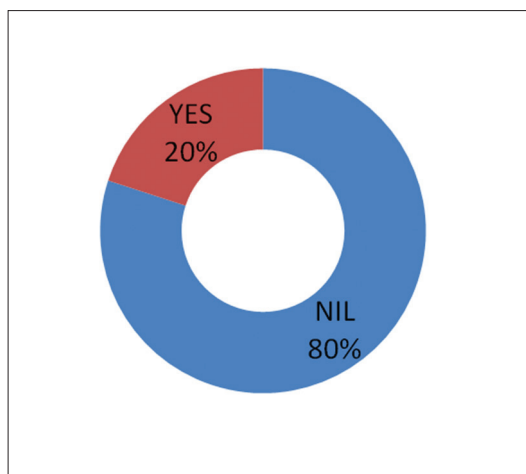
Sex	Total	
	Count	%
Male	25	83.3
Female	5	16.7
Total	30	100.0

Table 5: Frequency of pain among the subjects in the study population

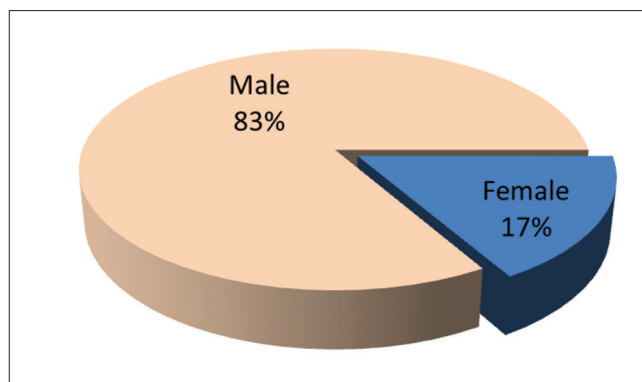
Pain	Frequency (%)
No	15 (50.0)
Yes	15 (50.0)
Total	30 (100.0)

Table 6: Frequency of discharge among the subjects in the study population

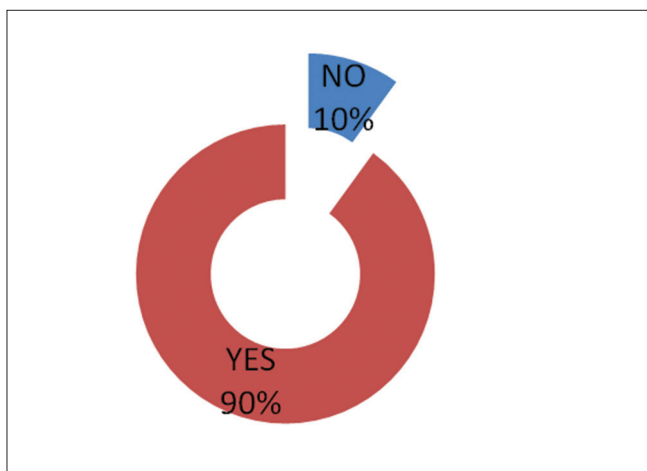
Discharge	Frequency (%)
Yes	28 (93.3)
No	2 (6.7)
Total	30 (100.0)



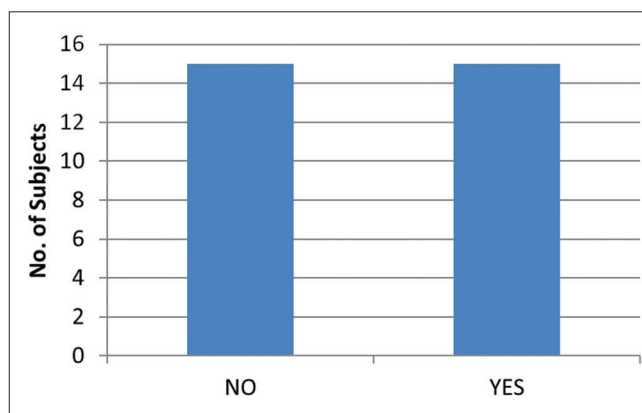
Graph 1: Frequency of complex fistula-in-ano among the subjects in the study population



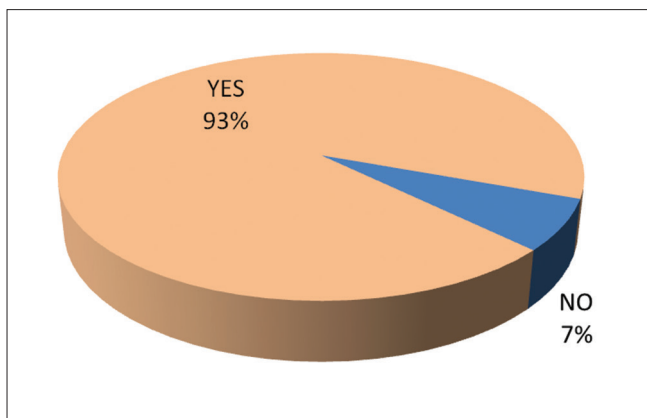
Graph 4: Sex distribution in the study population



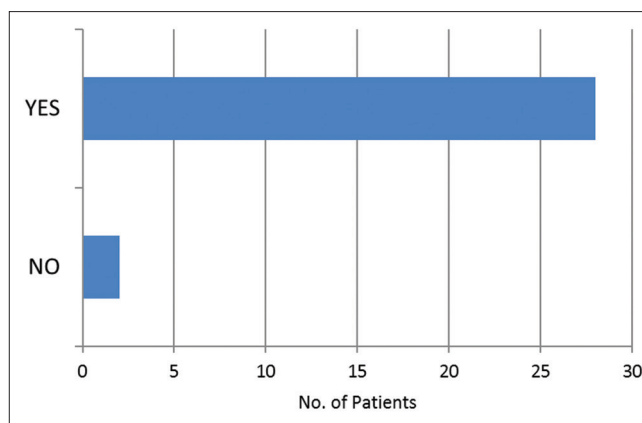
Graph 2: Frequency of identification of fistulous tracts by transrectal ultrasonography among the subjects in the study population



Graph 5: Frequency of pain among the subjects in the study population



Graph 3: Frequency of identification of fistulous tracts intra operatively among the subjects in the study population



Graph 6: Frequency of discharge from perianal region among the subjects in the study population

Table 7: Frequency of swelling in the perianal region among the subjects in the study population

Swelling	Frequency (%)
No	20 (66.7)
Yes	10 (33.3)
Total	30 (100.0)

Discharge from the external opening is the most common presenting complaint, with the frequency of 93.3%. Out of 30 patients 28 patients were presented

with discharge from external opening (Tables 5-8 and Graphs 5-8).

Table 8: Frequency of fever among the subjects in the study population

Fever	Frequency (%)
No	23 (76.7)
Yes	7 (23.3)
Total	30 (100.0)

Table 9: Frequency of past history of undergoing incision and drainage for perianal abscess among the subjects in the study population

Perianal abscess	Frequency (%)
Nil	19 (66)
Perianal abscess	10 (34)
Total	30 (100.0)

Table 10: Identification of external opening by physical examination

Pre-operative EO	Frequency (%)
Yes	30 (100.0)

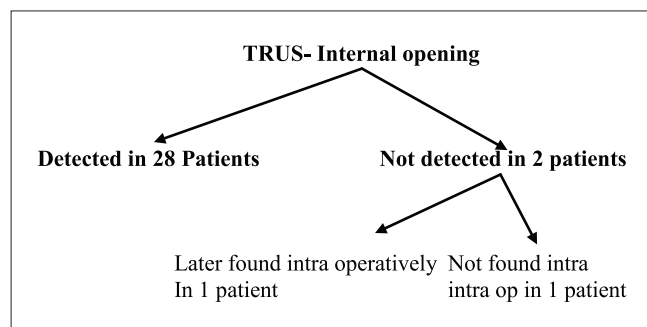
Table 11: Identification of internal opening by physical examination

Pre-operative IO	Frequency (%)
No	21 (70.0)
Yes	9 (30.0)
Total	30 (100.0)

Table 12: Identification of internal opening by TRUS

TRUS IO	Frequency (%)
Yes	28 (93.3)
No	2 (6.7)
Total	30 (100.0)

TRUS: Transrectal ultrasonography

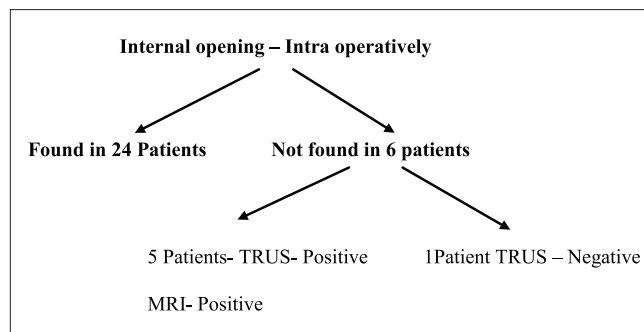


Out of 30 patients 10 patients had past history of undergoing incision and drainage for perianal abscess (Table 9 and Graph 9).

A study conducted by Lohsiriwat *et al.*, on Incidence and factors influencing the development of fistula-in-ano after

Table 13: Identification of internal opening intraoperatively

Intra-operative IO	Frequency (%)
Yes	24 (80.0)
No	6 (20.0)
Total	30 (100.0)

**Table 14: Calculating the accuracy of detecting internal opening by TRUS**

TRUS IO	Intra-operative IO		Total
	Yes	No	
Yes	23	5	28
No	1	1	2
Total	24	6	30

TRUS: Transrectal ultrasonography

	Value (%)	95% confidence interval
Sensitivity	95.83	78.88-99.89
Specificity	16.67	0.42-64.12
Positive predictive value	82.14	63.11-93.94
Negative predictive value	50.00	1.26-98.74

Table 15: Calculating the accuracy of TRUS in detecting fistulous-tract

TRUS-fistulous tracts	Intra OP fistulous tracts		Total
	Yes	No	
	Count	Count	Count
Yes	26	1	27
No	2	1	3
Total	28	2	30

TRUS: Transrectal ultrasonography

	Value (%)	95% confidence interval
Sensitivity	92.85	75.71-99.09
Specificity	50.00	0.84-90.57
Positive predictive value	96.29	75.71-99.09
Negative predictive value	33.33	0.84-90.57

incision and drainage of perianal abscesses showed that the incidence of fistula-in-ano following incision and drainage of perianal abscess was 31%. Patients aged under 40 years and non-diabetic patients appeared to have a higher risk

for fistula formation. Administration of perioperative antibiotics significantly reduced the rate of subsequent fistula formation.⁷

A similar retrospective cohort study conducted by Hamadani *et al.* showed that age younger than 40 years significantly increased risk of chronic anal fistula or recurrent anal sepsis after a first-time episode of perianal abscess. Patients with diabetes may have a decreased risk compared with nondiabetic patients. Gender, smoking history, perioperative antibiotic treatment, and HIV status were not risk factors for chronic anal fistula or recurrent anal sepsis.⁸

Preoperatively, all the patients underwent thorough physical examination and all of them were found to have external openings (Table 10).

Internal openings were detected in 9 patients on pre-operative per rectal examination (Table 11 and Graph 10).

A study conducted by Toyonaga *et al.*, on comparison of accuracy of physical examination and endoanal ultrasonography for pre-operative assessment in patients with acute and chronic anal fistula showed that the accuracy of endoanal ultrasonography was significantly higher than that of physical examination in detecting the primary tract (88.8% vs. 85.0%, $P = 0.0287$) and horseshoe extension (85.7% vs. 58.7%, $P < 0.0001$) and in localizing the internal opening (85.5% vs. 69.1%, $P < 0.0001$).⁹

All the patients underwent TRUS. All fistulous tracts were correctly depicted by TRUS in 26 patients and internal openings were depicted in 28 patients (Table 12 and Graph 11).

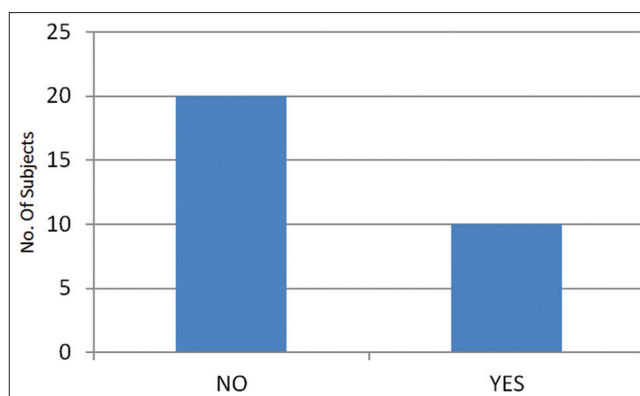
All the patients underwent surgical intervention.

Intraoperatively, all fistulous tracts and internal openings were identified in 26 and 24 patients, respectively (Table 13 and Graph 12).

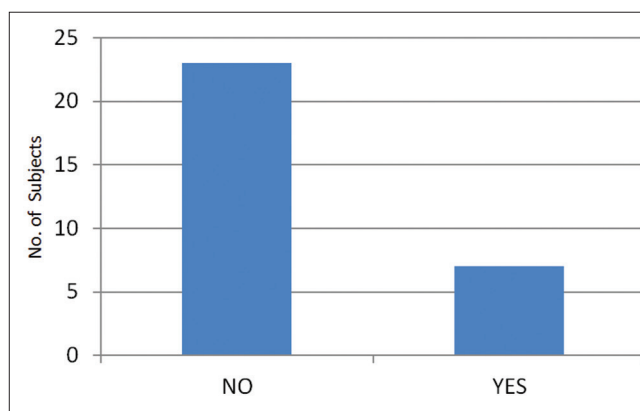
Intraoperative findings were correlated with those from the TRUS.

Of the 30 patients who underwent surgery, TRUS accurately identified the presence as well as the correct location of the tract/tracts in 26 patients (86.66%) and the internal opening in 28 patients (93.3%).

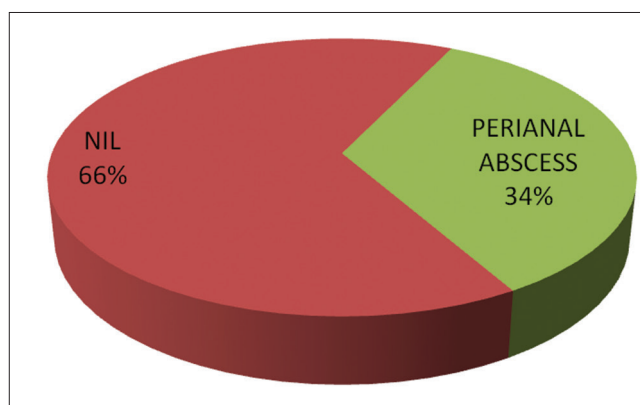
Similar study conducted by Bernstein *et al.*, on the use of endoanal ultrasonography in identifying fistula-in-ano showed that endoscopic ultrasound scan (EUS) accurately identified the presence or absence as well as the correct location of the tract in 24 patients (86%) and the internal opening in 24 patients (86%). The fistula tract was misinterpreted by EUS in 4 patients and the internal



Graph 7: Frequency of swelling in perianal region among the subjects in the study population



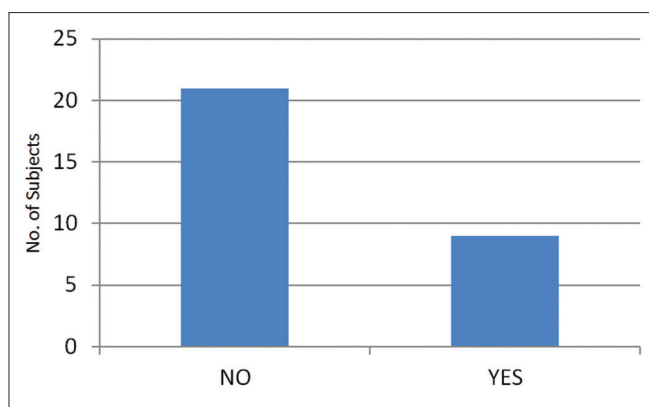
Graph 8: Frequency of fever among the subjects in the study population



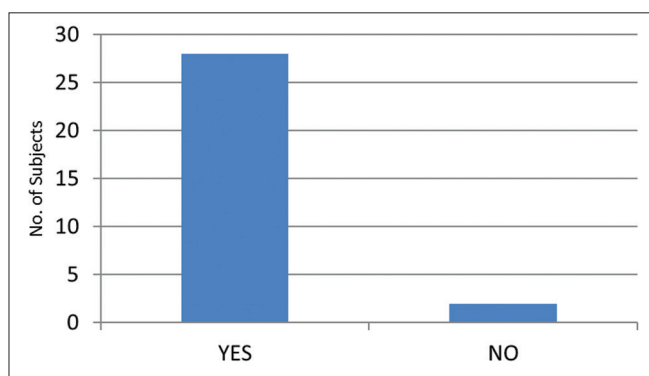
Graph 9: Frequency of past history of undergoing incision and drainage for perianal abscess among the subjects in the study population

opening in 4 patients overall. Endoanal ultrasonography had a sensitivity of 95% and 92% for identification of the tract and internal opening, respectively, and a positive predictive value of 88% and 92% for the tract and internal opening, respectively.¹⁰

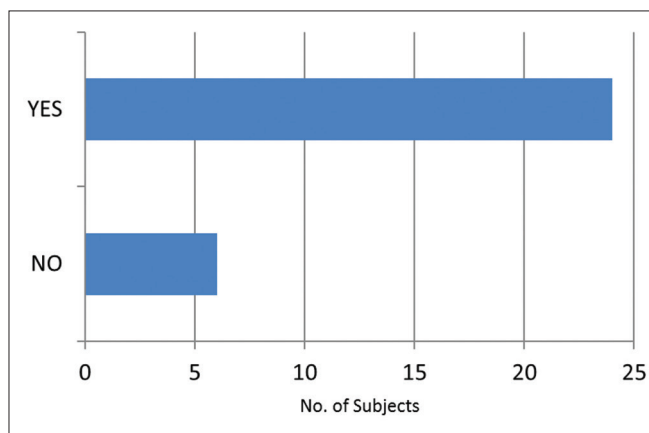
Our study conducted on role of TRUS in fistula-in-ano showed that TRUS had a sensitivity of 92.85% and 95.83% for identification of the tract and internal opening,



Graph 10: Frequency of identification of internal opening on pre-operative per rectal examination among the subjects in the study population



Graph 11: Frequency of identification of internal opening by transrectal ultrasonography among the subjects in the study population



Graph 12: Frequency of identification of internal opening intra-operatively among the subjects in the study population

respectively, and a positive predictive value of 96.29% and 82.14% for the tract and internal opening, respectively (Tables 14 and 15).

CONCLUSION

TRUS has an important role in the management of fistula-in-ano.

Adequate surgical management requires appropriate imaging to delineate anatomy and relationship of tracts to the sphincter complex.

Pre-operative TRUS can dictate the surgical procedure of choice and is an important determinant of outcome.

It may alert the surgeon to the presence of significant disease requiring specialist management given the associated risk of incontinence.

TRUS is a very valuable tool which gives an accurate road map of the fistulous tract/tracts, internal opening and external opening which is of paramount importance in successful management of fistula-in-ano.

Transrectal ultrasound scan is:

- Reliable
- Noninvasive
- Less expensive, investigative procedure which serves as a beacon for the surgeon intraoperatively to ensure complete cure and prevent recurrences.

REFERENCES

1. Williams N, O'Connell PR. Baily and Love Short Practices of Surg. 26th ed. Boca Raton, FL: CRC Press; 2013. p. 1259-60.
2. Parks AG. Pathogenesis and treatment of fistula-in-ano. Br Med J 1961;1:463-9.
3. Engin G. Endosonographic imaging of anorectal diseases. J Ultrasound Med 2006;25:57-73.
4. Kim MJ. Transrectal ultrasonography of anorectal diseases: Advantages and disadvantages. Ultrasonography 2015;34:19-31.
5. Kim Y, Park YJ. Three-dimensional endoanal ultrasonographic assessment of an anal fistula with and without H(2)O(2) enhancement. World J Gastroenterol 2009;15:4810-5.
6. Parikh R, Mathai A, Parikh S, Chandra Sekhar G, Thomas R. Understanding and using sensitivity, specificity and predictive values. Indian J Ophthalmol 2008;56:45-50.
7. Lohsiriwat V, Yodying H, Lohsiriwat D. Incidence and factors influencing the development of fistula-in-ano after incision and drainage of perianal abscesses. J Med Assoc Thai 2010;93:61-5.
8. Hamadani A, Haigh PI, Liu IL, Abbas MA. Who is at risk for developing chronic anal fistula or recurrent anal sepsis after initial perianal abscess? Dis Colon Rectum 2009;52:217-21.
9. Toyonaga T, Tanaka Y, Song JF, Katori R, Sogawa N, Kanyama H, et al. Comparison of accuracy of physical examination and endoanal ultrasonography for preoperative assessment in patients with acute and chronic anal fistula. Tech Coloproctol 2008;12:217-23.
10. Bernstein MA, Nougues JJ, Weiss EG, Wexner SD. The use of endoanal ultrasonography in identifying fistula-in-ano. Coloproctol 1997;19:72-6.

How to cite this article: Krishna BRS, Kantu R. Role of Transrectal Ultrasound Scan in Patients with Fistula-in-ano: A Clinical Study. Int J Sci Stud 2016;4(8):1-8.

Source of Support: Nil, **Conflict of Interest:** None declared.