

Dimorphism of Canine: A Diagnostic Value in Gender Identification - A Clinical Study

Prakash Chandra Jha¹, N C Sanghamesh², Abhijeet Alok³, Shivani Singh⁴, Braj Bushan Bharti⁵, Rakesh Raj⁶

¹Senior Resident, Department of Dentistry, Anugrah Narayan Magadh Medical College and Hospital, Gaya, Bihar, India, ²Reader, Department of Oral Medicine and Radiology, Kalinga Institute of Dental Sciences, Bhubaneswar, Orissa, India, ³Senior Lecturer, Department of Oral Medicine and Radiology, Sarjug Dental College and Hospital, Darbhanga, Bihar, India, ⁴Post-graduate Student, Department of Public Health Dentistry, Institute of Dental Sciences, Bareilly, Uttar Pradesh, India, ⁵Post-graduate Student, Department of Prosthodontics, B. R. Ambedkar Dental Hospital and College, Patna, Bihar, India, ⁶Ex-Lecturer, Buddha Institute of Dental Science and Hospital, Patna, Bihar, India

Abstract

Introduction: Forensic odontology plays a decisive role in establishing the sex of victims with bodies mutilated beyond recognition due to major mass disaster. Teeth are the most indestructible part after the death of all parts of the body. Teeth are readily accessible for examination and do not need special dissection. Hence, teeth provide excellent material in living and not living populations for anthropological, genetic, ontological, and forensic investigations. Among all the teeth, the canines are found to exhibit greatest sexual dimorphism. Permanent canines and their inter-arch widths are known to contribute to sex identification in identification through dimorphism.

Purpose: The purpose of present study was to assess whether dimorphism of permanent maxillary and mandibular canines, as well as inter-canine distance, play a role in establishing gender identification.

Materials and Methods: The present study involved 100 subjects, 50 male and 50 female patients. Mesiodistal widths of the four canines and interarch distance between the maxillary and mandibular canines were measured on the dental casts of each of the subjects. A mean value of the canine index was calculated for both genders. This value was used to calculate the standard maxillary and mandibular canine index.

Result: All measurements showed statistically significant sexual dimorphism. Inter canine arch width and mesiodistal crown widths of canine were less in female than male. **Conclusion:** Canine plays an important role in gender identification. This study establishes dimorphism of the canine as a diagnostic value in gender identification.

Key words: Arch width, Canines, Forensic odontology, Gender, Intercanine distance

INTRODUCTION

The identification of a dead body may be required in cases of sudden and unexpected death, fires, explosions, and railway or aircraft accidents, mutilated or hidden decomposed bodies.¹ Sex determination of skeletal remains is an important part of archeological and many medico-legal examinations, particularly where the bodies are damaged beyond recognition. Teeth are excellent material for anthropological, genetic,

and odontologic investigations in both living and dead population and are therefore of paramount importance in forensic practice. Forensic dentists can use this data to provide significant conclusions to medical examiners and detective.² This is because the unique traits and characteristics of teeth and jaws. The study of teeth reveals a lot concerning forensic medicine. In particular, it is useful in human identification. Forensic Odontology tells us a lot about the determination of age from various methods. In addition to the determination of age, sex can also be determined from the teeth. Determination of sex using skeletal remains presents a great problem to forensic experts, especially when only fragments of the body, are recovered. Forensic dentists can assist other experts to determine sex of the remains by using teeth and skull.³

Various features of teeth, like morphology, crown size, root lengths, etc., are characteristic for male and female

Access this article online



www.ijss-sn.com

Month of Submission : 09-2015
Month of Peer Review : 10-2015
Month of Acceptance : 11-2015
Month of Publishing : 11-2015

Corresponding Author: Dr. Prakash Chandra Jha, Department of Dentistry, Anugrah Narayan Magadh Medical College and Hospital, Gaya, Bihar, India. Phone: +91-9934014120. E-mail: drabhijeet786@gmail.com

sexes. There are also differences in the skull patterns. These will help a forensic odontologist to identify the sex.⁴ Very few studies have been carried out to know dimorphism of permanent maxillary and mandibular canines play a role in establishing gender identity. Hence, this study was carried out to establish dimorphism of permanent maxillary and mandibular canines, as well as intercanine distance play a role in establishing gender identity. It was also planned to investigate the effect of “gender factor” on the morphometry of maxillary and mandibular canines.

MATERIALS AND METHODS

The present study involved 100 subjects, 50 male and 50 female patients, ranging between 14 and 20 years of age, who came to the Department of Oral Medicine and Radiology were included in the study. Inclusion criteria of this study was healthy gingiva and periodontium, caries-free teeth, normal overjet and overbite, absence of spacing in anterior teeth, whereas exclusion criteria of study was presence of partially erupted teeth, patient with dental/occlusion abnormalities and teeth showing physiologic or pathologic wear and tear, patients with deleterious oral habits. Information was given to all the participants regarding the need and design of the study, and the need for undergoing a clinical examination and making an impression. Informed consent was taken from all the patients. The study was approved by the Ethical Committee.

Impressions of upper and lower arch make with the help of alginate to all the patients, then cast of the immersion made by the help of dental stone (Figures 1-5). Measurements of mesiodistal widths of the four canines and interarch distance between the maxillary and mandibular canines were made on the dental casts of each of the subjects with the help of Vernier caliper with a resolution of 0.1 mm and divider (Figures 6 and 7). The data were coded on Microsoft excel sheet and analyzed using SPSS statistical package version 17. Statistical analysis was done by student *t*-test.

RESULTS

It was observed that the mean mesiodistal dimension of right side maxillary canine were greater in males than females, i.e., 0.73 ± 0.07 in males and 0.54 ± 0.05 in females. Furthermore, the mean mesiodistal dimensions of left side maxillary canine were greater in males, i.e., 0.72 ± 0.07 in males and 0.54 ± 0.05 in females. Same results were observed of the right side mandibular mean mesiodistal dimension of canine 0.65 ± 0.06 in males and 0.50 ± 0.04 in females, whereas mean mesiodistal dimension of left side mandibular canine 0.66 ± 0.06 in males and 0.50 ± 0.05 in female, which were again greater in males than females.

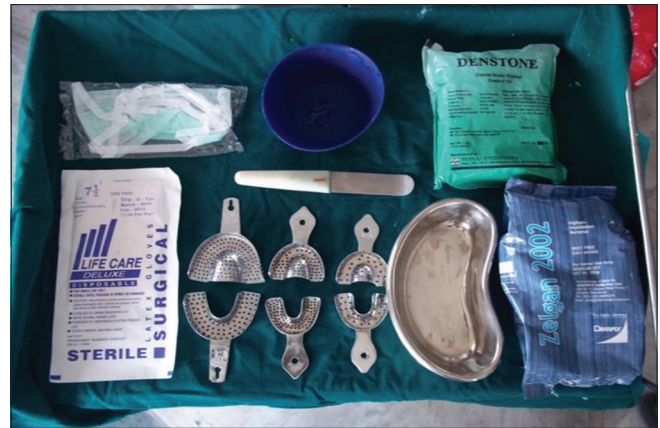

Figure 1: Armamentarium for examination, making impressions and obtaining study casts




Figure 2: Vernier caliper for measurements on the study casts

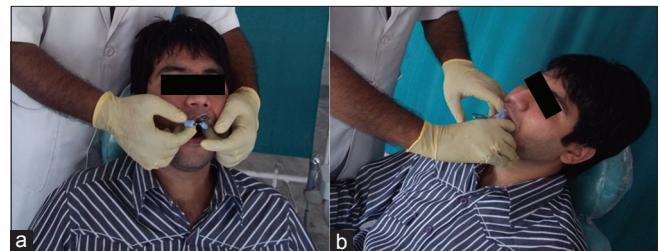

Figure 3: (a) Impression making for the maxillary arch, (b) impression making for the mandibular arch



Figure 4: Impression trays

However, mean intercanine distance in maxilla 3.38 ± 0.53 in males and 2.99 ± 0.16 in females, whereas mean intercanine distance in mandible 2.77 ± 0.26 in males and 2.48 ± 0.10 in females which were also greater in males than females. P value is highly significant $P < 0.001$ (Figure 8).

DISCUSSION

Identification of sex from adult human skeletal remains is the most reliable if the complete skeleton is available for analysis.^{5,6} A basic problems in physical and forensic anthropology is determination of the sex of incomplete and fragmentary skeletal remains.⁷ Teeth are the strongest structures in the human body and are known to resist postmortem destruction. They are usually retained in skeletal specimens and hence, can be used in sex differentiation.⁸

Canines are used because of their durability in the oral cavity. These are the least frequently extracted teeth because decreased incidence of caries and periodontal disease. Canines are reported to withstand extreme conditions and have been recovered from human remain even in air disasters and hurricanes.⁹⁻¹¹

This study was carried out to analyze the sexual dimorphism in the maxillary and mandibular canine and the intercanine arch width. In our study, we have selected the age group of 14-20 years of age because intercanine distance do not

increase after 12 years of age and after 20 years of age regressive alteration take place which were comparability with previous studies on canine indices.^{12,13}

The methods of measurement of canine width in the present study were done with a universal method and in agreement with a number of studies when the anatomic point of measurement on the tooth is considered.^{14,15} To obtain a statistically relevant interpretation with consideration to the study period, a sample size of 100 subjects comprising of 50 males and 50 females was decided which was in accordance to a study conducted by Boaz and Gupta.¹⁰

In this study, the statistical mean of maxillary right canine left canine and mandibular right and left canine of males were found to have larger mesiodistally than females. P value finding is high ($P < 0.001$), indicating a high sexual dimorphism. These results were consistent with the results of study conducted by Kaushal *et al.*⁹

In our study, mean intercanine distance in maxilla 3.38 ± 0.53 in males and 2.99 ± 0.16 in females, whereas mean intercanine distance in mandible 2.77 ± 0.26 in males and 2.48 ± 0.10 in females which were also greater in males than females. P value is highly significant $P < 0.001$. The results were coinciding with the results of study conducted by Rao *et al.*¹³

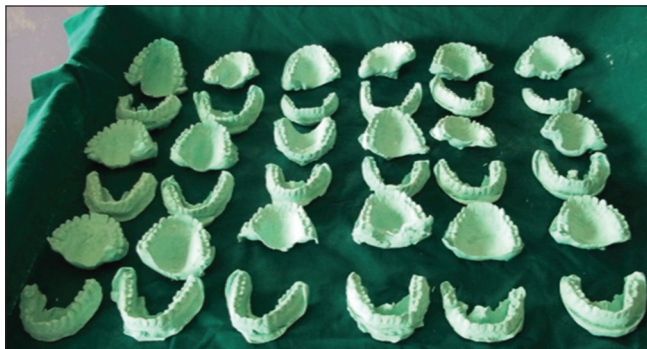


Figure 5: Casts

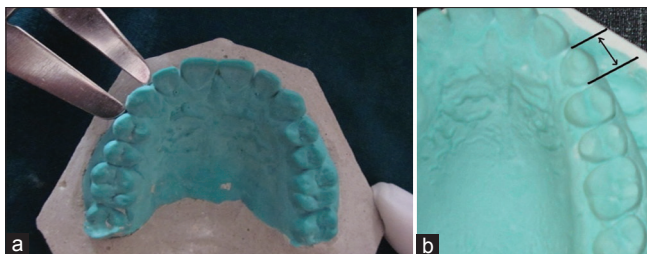


Figure 6: (a) Measurement of mesiodistal width of canines on study casts, (b) measurement of mesiodistal width of canines on study casts

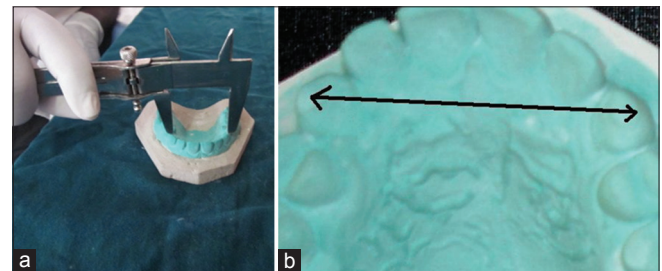


Figure 7: (a) Measurement of intercanine arch width on study casts, (b) measurement of intercanine arch width on study casts

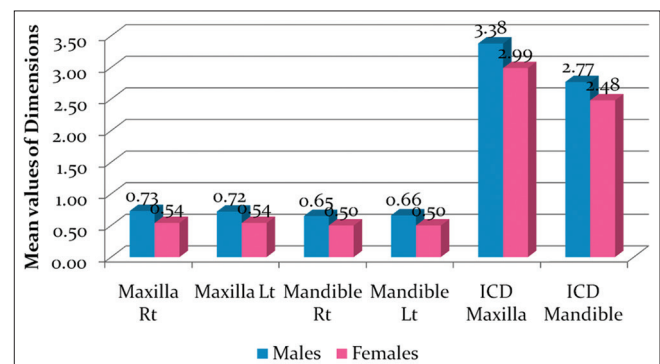


Figure 8: Comparison of various dimensions in different genders

Main drawback of our study was that the sample size was small. Further dimorphic studies of canine are advised with larger samples size of so that the incidence of sexual dimorphism of canine could be strongly established in future.

CONCLUSION

Forensic odontology is an emerging field which requires easy and inexpensive means of identification of persons from fragmented jaws and dental remains. In future, a database should be established of dental morphometric measurements to determine gender for anthropological, legal, and forensic purpose. Canine is a key tooth for gender identification and is diagnostic value in forensic odontology.

REFERENCES

- Hill IR, Howell RD, Jarmulowicz M. Identification in the Manchester air disaster. *Br Dent J* 1988;165:445-6.
- Sweet D. Why a dentist for identification? *Dent Clin North Am* 2001;45:237-51.
- Sopher IM. The dentist, the forensic pathologist, and the identification of human remains. *J Am Dent Assoc* 1972;85:1324-9.
- Sundick RI. Age and sex determination of subadult skeletons. *J Forensic Sci* 1977;22:141-4.
- Falsetti AB. Sex assessment from metacarpals of the human hand. *J Forensic Sci* 1995;40:774-6.
- Gopinath T, Ashima V. Variations in intercanine, interpremolar and intermolar width – a comparative pilot study between Indian and Chinese population. *J Pierre Fauchard Acad* 1992;6:109-14.
- Berrizbeitia EL. Sex determination with the head of the radius. *J Forensic Sci* 1989;34:1206-13.
- Acharya AB, Mainali S. Are dental indexes useful in sex assessment? *J Forensic Odontostomatol* 2008;26:53-9.
- Kaushal S, Patnaik VV, Agnihotri G. Sex determination in north Indians using mandibular canine index. *J Indian Assoc Forensic Med* 2004;26:45-9.
- Boaz K, Gupta C. Dimorphism in human maxillary and mandibular canines in establishment of gender. *J Forensic Dent Sci* 2009;1:42-4.
- Duraiswamy P, Tibdewal H, Patel K, Kumar S, Dhanni C, Kulkarni S. Sex determination using mandibular canine index in optimal-fluoride and high-fluoride areas. *J Forensic Dent Sci* 2009;1:99-103.
- Yadav S, Nagabhushana D, Rao BB, Mamatha GP. Mandibular canine index in establishing sex identity. *Indian J Dent Res* 2002;13:143-6.
- Rao NG, Rao NN, Pai ML, Kotian MS. Mandibular canine index – A clue for establishing sex identity. *Forensic Sci Int* 1989;42:249-54.
- Anderson DL, Thompson GW. Interrelationships and sex differences of dental and skeletal measurements. *J Dent Res* 1973;52:431-8.
- Saglam AM, Ozbaran HM, Saglam AA. A comparison of mesio-distal crown dimensions of the permanent teeth in subjects with and without fluorosis. *Eur J Orthod* 2004;26:279-81.

How to cite this article: Jha PC, Sanghamesh NC, Alok A, Singh S, Bharti BB, Raj R. Dimorphism of Canine: A Diagnostic Value in Gender Identification - A Clinical Study. *Int J Sci Stud* 2015;3(8):81-84.

Source of Support: Nil, **Conflict of Interest:** None declared.