Original Article

DOI: 10.17354/ijss/2015/526

Histopathological Study of Prostatic Diseases in Garhwal Region

Sachan Bhat[1], Sheela Chaudhri[2], Pawan Bhat[1], Deepa Hatwal[2]

[1]Assistant Professor, Department of Pathology, Vir Chander Singh Garhwali Government Medical Science & Research Institute, Pauri Garhwal, Uttarakhand, India, [2]Associate Professor, Department of Pathology, Vir Chander Singh Garhwali Government Medical Science & Research Institute, Pauri Garhwal, Uttarakhand, India

Abstract

Introduction: Prostatic pathology is one of the commonest disorders causing considerable morbidity and mortality in elderly male population. Benign prostatic hyperplasia (BPH), prostatitis and prostatic cancer are the most common pathological processes affecting prostate. As there has been very little study, if any, carried out on prostatic pathology in Garhwal region, hence we conducted this study on patterns of prostatic diseases based on histopathological specimens. This study can help us to determine various histopathological growth patterns of benign prostatic hyperplasia, age distribution of various prostatic lesions and grading and scoring of prostatic carcinoma according to Gleason system.

Purpose: To study the pattern and incidence of different prostatic disorders in Garhwal region.

Methods: A retrospective study, over a period of five years, was carried out on the material which included the histopathology slides and the tissue blocks and relevant clinical data was obtained from the department of pathology.

Results: BHP was the commonest encountered lesion seen in the prostate (92.6%) and was on many occasions associated with prostatitis. Fibromyoadenomatous pattern was seen to be the most commonest growth pattern of BHP. Prostatic adenocarcinoma was found in about 7.4% of all cases and majority of these cases were of high grade adenocarcinoma and were of Gleasons score 7-9.

Conclusion: In our study in Garhwal region, Benign prostatic hyperplasia came out to be the commonest prostatic disorder and prostatic adenocarcinoma was the commonest variant of prostatic cancer.

Key words: Benign prostatic hyperplasia, Prostate, Prostatitis, Prostatic adenocarcinoma

INTRODUCTION

Prostatic lesions have been on an increase over the past few decades due to higher life expectancy and an ever increasing population in the 6th, 7th, and 8th decades of life. Diseases of prostate caused significant morbidity and mortality in adult males throughout the world, though with varying incidence in various geographical areas. The prostate is affected by a variety of pathological processes, but the more frequent encountered are Benign hyperplasia prostate (BHP), prostatitis, and prostatic cancer. BHP is the most common urological disorder in males beyond 40 years age. The clinical incidence of this disease is only 8% during the 4th decade but it reaches 50% in the 5th decade and 75% in the 8th decade of life.[1] Advanced age and an intact androgen supply are the only undisputed risk factors for BHP.[2] Prostatic cancer is one of the most common malignancies affecting men worldwide, and in certain regions, even is the most common. In certain autopsy studies, the prevalence of the disease is approximately 30% in men older than 50 years, while foci of adenocarcinoma has been found in virtually all men older than 90 years.[3] Prostatic adenocarcinomas constitute more than 95% of total prostatic malignancies and hence is the most common variant of prostatic malignancies by a fair margin. Prostatitis is another common urinary tract associated problem for men younger than 50 years age

Access this article online

IJSS

www.ijss-sn.com

Month of Submission : 09-2015
Month of Peer Review : 10-2015
Month of Acceptance : 11-2015
Month of Publishing : 11-2015

Corresponding Author: Dr. Sachan Bhat, Department of Pathology, Vir Chander Singh Garhwali Government Medical Science & Research Institute, Srikot, Srinagar, Pauri Garhwal, Uttarakhand, India. E-mail: sachinbhat007@gmail.com

and third most common urinary tract problem for men older than 50 years age.[4] The aim of the current study was to determine the various histopathological patterns of the prostatic lesions, in our region, where very rarely such studies have been undertaken. Furthermore growth patterns of BHP and grading and scoring of prostatic adenocarcinomas according to Gleasons system was done.

MATERIALS AND METHODS

The present study was a hospital based retrospective study carried out in the Department of Pathology, Vir Chander Singh Garhwali Government Medical Science and Research Institute, Srinagar, Garhwal, Uttarakhand. The materials for the study included histopathology slides, and tissue blocks of all the prostatic specimens received between January 2010 and August 2015. The relevant clinical history and data was also taken from the Pathology Department files, and was present in all cases. The hematoxylin and eosin (H and E) stained slides were retrieved and the slides were reviewed using light microscope under various magnifications, and the various histopathological findings were noted. Fresh sections were taken from tissue blocks in some cases, wherever required, and were stained with H and E stain. The various lesions of prostate were noted down. The various morphological types of BHP were described according to classification given by Franks.[5] The tumors were classified according to WHO classification[6] and the histological grading of adenocarcinomas was done as per the Gleasons system.[7] Data were then analyzed using tables, figures and percentages.

OBSERVATIONS

A total of 92 prostatic lesions were recorded during the time period spanning from January 2010 to August 2015. All the relevant data including ages of patients were recorded. Out of the total of 92 prostatic specimens, 88 were prostectomy specimens while 4 were prostatic biopsy specimens. The prostectomy specimens were grossly gray-white to gray to tan in color, globular to nodular in appearance, and ranged in size from 2.5 to 13 cm in diameter. The consistency of these gross specimens varied from firm to hard. The cut sections of most of these specimens were homogenous, except two cases where there was well-defined growth within the gross specimen, which later on turned out to be prostatic carcinoma. The four prostatic biopsy specimens were narrow strips of gray-white tissue ranging in length from 0.5 to 1.5 cm. The histological features and the histopathological diagnosis of each case were also noted down. The prostatic lesions were broadly classified into BHP, prostatitis, prostatic intra-epithelial neoplasia and prostatic cancer. In our study, BHP was found out to be the most common lesion affecting 85 (92.4%) cases. Prostatitis was divided into acute, chronic and granulomatous types and many of these were seen in association with BHP or prostatic cancer. Chronic prostatitis was found out to be the most common inflammatory lesion, followed by chronic prostatitis and granulomatous prostatitis. Granulomatous prostatitis was seen in only one case and was associated with a case of BHP. Prostatic cancer was seen in 7 (7.6%) cases and all of these cases were of prostatic adenocarcinomas.

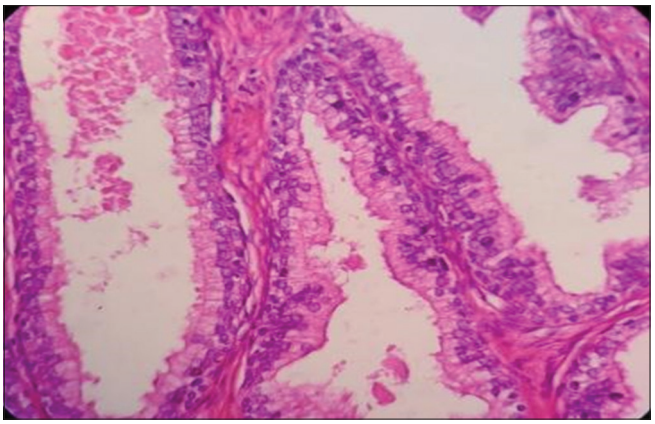

Figure 1: Typical bilayer of cells in a case of benign hyperplasia prostate (H and E stain, ×400)

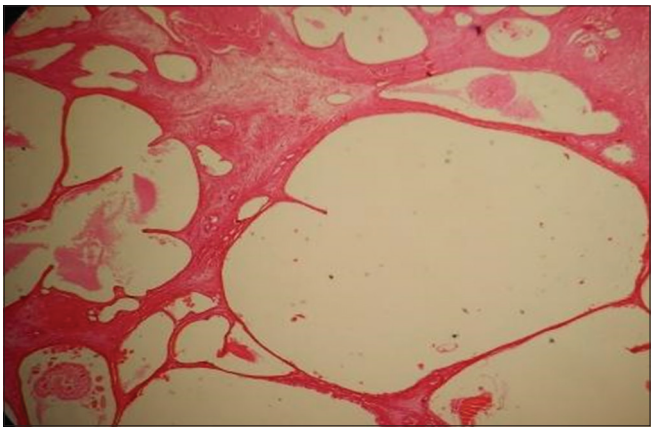

Figure 2: Cystic change in benign hyperplasia prostate (H and E stain, ×100)

Table 1: Distribution of BHP cases according to age groups

Age group (in years)	Number of BHP cases	Percentage
30-39	1	1.17
40-49	1	1.17
50-59	9	10.59
60-69	34	40
70-79	35	41.17
80-89	5	5.90
Total	85	100

BHP: Benign hyperplasia prostate

BHP

Microscopically BHP was seen characterized by the presence of glandular and stromal hyperplasia and the acini being lined by bilayer of cells (Figure 1). Corpora amylacea in acini, cystic changes (Figure 2), squamous metaplasia, transitional cell metaplasia and calcification were among the variably present associated features. Among the 85 BHP cases, the youngest patient was 37 years old and the oldest was 85 years old and the peak incidence was seen in 70-79 years age group. The detailed age distribution is given in Table 1.

On the basis of histological composition five types of BHP growth patterns are described, i.e., fibromyoadenomatous, fibroadenomatous, fibromuscular, muscular and stromal. In fibromyoadenomatous type, hyperplasia of glandular as well as stromal components was seen while only hyperplasia of glandular elements was seen in fibroadenomatous type. Fibromuscular type showed mainly stromal proliferation with very little glandular components. Stromal hyperplasia showed predominantly the presence of loose fibrous tissue having interspersed groups of spindle-shaped cells (Figure 3). Fibromyoadenomatous type was found to be the most common. The detailed distribution of these is given in Table 2.

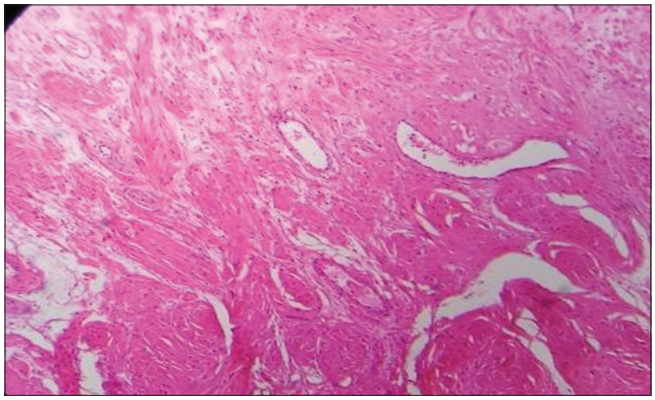

Figure 3: Stromal variant of benign hyperplasia prostate (H and E stain, ×100)

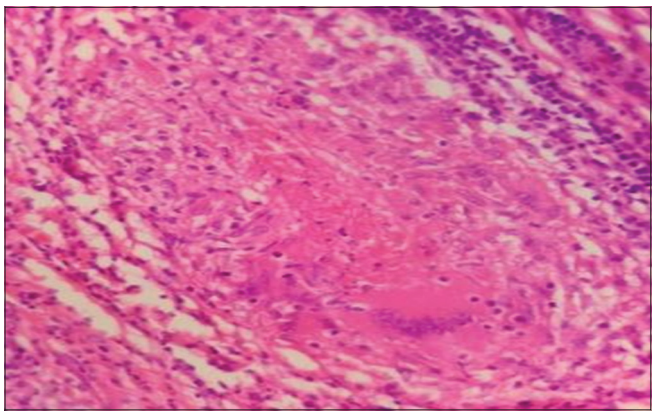

Figure 4: Granulomatous prostatitis (H and E stain, ×400)

Prostatitis

Inflammatory changes affecting prostate were divided, into acute, chronic and granulomatous, on the basis of inflammatory cells present. Prostatitis was seen associated with quite a few cases of BHP. Chronic prostatitis was seen in 32 (34.78%) and acute prostatitis was seen in 6 (6.52%) of prostatic biopsies. 2 (2.17%) cases of granulomatous prostatitis (Figure 4) were also noted. 2 prostatic biopsies were having an admixture of acute and chronic inflammatory cell infiltrations.

Prostatic Adenocarcinomas

In our study of 92 prostatic lesions, 7 cases (7.6%) were diagnosed as prostatic adenocarcinomas and among these cases the youngest patient was 58 years old and the oldest was 82 years old and the peak incidence was seen in 70-79 years age group. The detailed age distribution is given in Table 3.

All these cases were graded according to the Gleasons grading system which presently is the most favored microscopic grading system. Gleasons grading system is based on the extent of glandular differentiation and growth pattern of the tumor as seen in lower magnification, under light microscope. Five different patterns are described by

Table 2: Distribution of various growth patterns of BHP

Pattern of growth	Number of cases	Percentage
Fibromyoadenomatous	58	68.2
Fibroadenomatous	22	25.9
Fibromuscular	4	4.7
Stromal	1	1.2
Muscular	0	0
Total	85	100

BHP: Benign hyperplasia prostate

Table 3: Distribution of prostatic adenocarcinoma according to age groups

Age groups (years)	Number of cases of prostatic adenocarcinoma	Percentage
50-59	1	14.28
60-69	1	14.28
70-79	2	28.58
80-89	3	42.86
Total	7	100

Table 4: Depiction of adenocarcinomas according to Gleasons score

Gleasons score	4	5	6	7	8	9	10	Total
Number of cases	0	1	1	1	2	2	0	7
Percentage	0	14.28	14.28	14.28	28.58	28.58	0	100

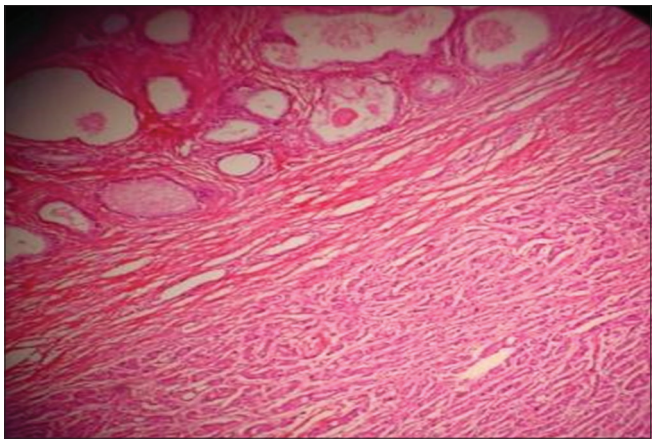

Figure 5: Features of benign hyperplasia prostate and prostatic adenocarcinoma in single focus (H and E stain, ×100)

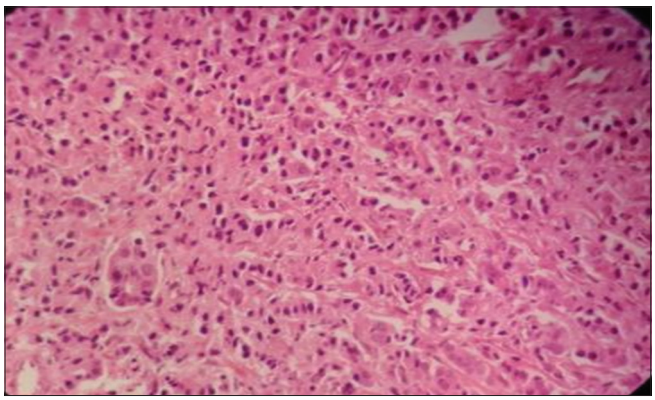

Figure 6: Prostatic adenocarcinoma (H and E stain, ×400)

this system. Both the primary (predominant) and secondary (second most prevalent) architectural patterns are identified and assigned a grade from 1 to 5, with 1 being the most differentiated and 5 being undifferentiated. The combined Gleason grades (Gleason score) range from 2 (1 + 1 = 2), which represents tumors uniformly composed of Gleason pattern 1 tumor, to 10 (5 + 5 = 10), which represents totally undifferentiated tumors. In our study, prostatic adenocarcinoma (Figures 5 and 6) with Gleasons score 8 and 9 were the most common with 2 cases each, and there was no tumor with Gleasons score 2, 3, 4, or 10. Table 4 depicts distribution of various cases of adenocarcinomas with reference to their Gleasons score.

DISCUSSION

Prostatic diseases cause a significant morbidity and mortality in elderly males. The pathological processes affecting the prostate gland with sufficient frequency to merit discussion are BHP, prostatitis and prostatic cancer. Of these three, BHP is the most common seen lesion. In the present study of 92 cases of prostatic lesions, 85 (92.4%) cases were diagnosed as BHP and 7 (7.6%) cases were diagnosed as of prostatic cancer. We observed that 92.3% of all prostatic lesions were of BHP, while 6.3% were of prostatic cancer. These findings are similar to the studies done by Jehoram *et al.*,[8] Bal *et al.*,[9] and Dawam *et al.*[10] whose studies found 93%, 87%, and 86% cases of BHP in their studies, respectively. However, studies by Mansoor[11] from Saudi Arabia showed lesser percentage of BHP cases and more cases of adenocarcinoma as compared to our studies and many Indian studies. In our study, BHP was seen most common affecting age group 70-79 years with 41.17% cases, followed by age group 60-69 years with 40 % cases. This finding is similar to the study done by Deshmukh *et al.*[12] and Shakya *et al.*[13] Both these studies also showed similar results, with nearly 80% of BHP cases affecting these two decades of life. The most common histological pattern of BHP was found out to be fibromyoadenomatous type with 58 (68.2%) cases, followed by fibroadenomatous with 22 (25.9%) cases. Deshmukh *et al.*[13] and Kim and Kim[14] in their studies found similar distribution of various histological patterns of BHP.

Chronic prostatitis was seen in 32 prostatic biopsies, and in the majority of cases was of mild intensity. Acute prostatitis and granulomatous prostatitis were seen in 6 and 2 cases, respectively. All these cases were seen associated either with BHP or prostatic adenocarcinoma. These findings are similar to most of the studies on prostatitis, like the study of Anim *et al.*[15] and Mohammed *et al.*,[16] which also found chronic prostatitis as the most common inflammatory lesion affecting prostate followed by acute and granulomatous prostatitis.

Prostate cancer is one of most common malignancies in the world, particularly significant among elderly males. More than 75% cases of all prostate cancers occur in males more than 60 years age. In our study Prostate cancer was found to be affecting 7 (7.6%) cases of all the 92 cases studied and all these 7 cases were of prostatic adenocarcinoma. These findings were in agreement with the studies of Subathra and Sangeetha,[17] Deshmukh *et al.*[13] and Jatav *et al.*[18] who also found 7.4%, 9% and 9.7% of all prostatic lesions as prostatic adenocarcinoma, respectively. These studies also found adenocarcinoma as the principal variant of prostatic cancer, constituting more than 90% of all prostatic cancer cases. Elem and Patil[19] in their studies found all prostatic malignancies to be of prostatic adenocarcinoma. We found in our study prostatic adenocarcinoma affecting later decades of life, with the youngest patient affected being 52 years of age. Maximum percentage of patients were seen in their 8th and 7th decade of life which was in close concordance with the studies of Gilliland and Key[20] and Matapurkar and Taneja.[21] In our study, we found 4 (56.16%) cases of adenocarcinoma with Gleason score of 8-9. Angurana[22] in her studies found 64.3% cases with

Gleasons score 6-10 which was in close agreement with our study. Whereas doing the Gleasons grading for 71 cases of prostatic adenocarcinomas, Albasri *et al*.[23] found Gleasons score of 5-7 as the commonest followed by Gleason score 8-10. Majority of the cases of prostatic adenocarcinoma were poorly differentiated in our study.

CONCLUSION

We found the pattern of prostatic diseases in Garhwal region, were similar to other regions of India and world. BHP was the most common encountered lesion seen in the prostate and was on many occasions associated with prostatitis. Fibromyoadenomatous pattern was seen to be the most common growth pattern of BHP. Prostatic adenocarcinoma was found in about 7% cases, and the majority of these cases were of high-grade adenocarcinoma and was of Gleasons score 7-9.

REFERENCES

1. Rosai J. Male reproductive system. In: Rosai and Ackerman's Surgical Pathology. 9th ed., Vol. 1. Missouri: Mosby; 2005. p. 1361-8.
2. Bostwick DG, Cooner WH, Denis L, Jones GW, Scardino PT, Murphy GP. The association of benign prostatic hyperplasia and cancer of the prostate. Cancer 1992;70 1 Suppl:291-301.
3. Syrigos KN, Karapanagiotou E, Harrington KJ. Prostate cancer in elderly. Anticancer res 2005; 4527-34.
4. Nickel JC. Prostatitis and related conditions, orchitis, and epididymitis. In: Wein AJ, Kavoussi LR, Norich AC, Partin AW, Peters CA, editors. Cambell-Walsh Urology. 10th ed. Philadelphia, PA: Saunders; 2012. p. 327-56.
5. Franks LM. Benign nodular hyperplasia of the prostate; a review. Ann R Coll Surg Engl 1953;14:92-106.
6. Mostofi FK, Sesterhenn I, Sobin LH. Histological typing of prostatic tumours. In: International Histological Classification of Tumours. Geneva: World Health Organization; 1980. p. 22.
7. Epstein JI, Allsbrook WC Jr, Amin MB, Egevad LL. ISUP Grading Committee. The 2005 International Society of Urological Pathology (ISUP) Consensus Conference on Gleason Grading of Prostatic Carcinoma. Am J Surg Pathol 2005;29:1228-42.
8. Jehoram TA, Sitara AS, Mohammed EB. Hyperplasic, premalignant and malignant lesions of the prostate gland. Hum Pathol 2005;36:480-5.
9. Bal MS, Kanwal S, Goyal AK, Singla N. Prostatic lesions in surgical biopsy specimens. JK Pract 2011;16:33-4.
10. Dawam D, Rafindadi AH, Kalayi GD. Benign prostatic hyperplasia and prostate carcinoma in native Africans. BJU Int 2000;85:1074-7.
11. Mansoor I. Pattern of prostatic diseases in Saudi Arabia. Int J Pathol 2003;2:2.
12. Deshmukh BD, Ramteerthakar NA, Sulhyan KR. Histopathological study of lesions of prostate - A five year study. Int J Health Sci Res 2014;4:1-9.
13. Shakya G, Malla S, Shakya KN. Salient and co-morbid features in benign prostatic hyperplasia: A histopathological study of the prostate. Kathmandu Univ Med J (KUMJ) 2003;1:104-9.
14. Kim KB, Kim KS. A histopathological observation on 48 cases of benign prostatic hypertrophy. Korean J Urol 1982;23:1127-31.
15. Anim JT, Ebrahim BH, Sathar SA. Benign disorders of the prostate: A histopathological study. Ann Saudi Med 1998;18:22-7.
16. Mohammed AZ, Nwana EJ, Anjorin AS. Histopathological pattern of prostatic diseases in Nigerians. Afr J Urol 2005;11:33-8.
17. Subathra K, Sangeetha N. histopathological study of prostatic lesions and assessment with AGNOR index. Int J Pharm Bio Sci 2014;5:B253-60.
18. Jatav J, Tomar KS, Pandit V, Iyenger S, Jain B. Characterization of prostatic lesions in surgically resected specimens. Indian J Appl Res 2015;5:444-6.
19. Elem B, Patil PS. Patterns of urothelial malignancies in Zambia. A hospital based histopathological study. Br J Urol 1991;67:37.
20. Gilliland FD, Key CR. Male genital cancers. Cancer 1995;75 1 Suppl:295-315.
21. Matapurkar BG, Taneja OP. Incidence of carcinoma prostate. A five year survey. Indian J Cancer 1969;6:172-83.
22. Angurana N. Pattern of prostate diseases - A histopathological study in Jammu. Int J Basic Appl Med Sci 2014;4:163-7.
23. Albasri A, El-Siddig A, Hussainy A, Mahrous M, Alhosaini AA, Alhujaily A. Histopathologic characterization of prostate diseases in Madinah, Saudi Arabia. Asian Pac J Cancer Prev 2014;15:4175-9.

How to cite this article: Bhat S, Chaudhri S, Bhat P, Hatwal D. Histopathological Study of Prostatic Diseases in Garhwal Region. Int J Sci Stud 2015;3(8):136-140.

Source of Support: Nil, **Conflict of Interest:** None declared.