

Comparative Study of Post-operative Complications in Third Molar Surgery with and without Sutures: A Prospective Study

Abdulhaseeb Quadri¹, Shireen Quadri², Tanveerahmed Khan³

¹Assistant Professor, Department of Oral and Maxillofacial Surgery, Subbaiah Institute of Dental Sciences, Purle, Shivamogga, Karnataka, India, ²Assistant Professor, Department of Physiology, SIMS, Shivamogga, Karnataka, India, ³Associate Professor, Department of Anatomy, SIMS, Shivamogga, Karnataka, India

Abstract

Objective and Background: The objective of this study is to evaluate the post-operative complication in third molar surgery with and without suture.

Materials and Methods: A total of 50 healthy subjects belonging to both the sexes in the age group 20-40 years with bilateral impacted third molar underwent surgical removal under local anesthesia in a single sitting. The post-operative pain was recorded on visual analog scale for 7 days, and swelling was measured on day 3, 5, and 7 with reference to four anatomical landmarks.

Results and Observations: Both the statistical analysis and clinical observation showed that both pain and swelling were more on the sutured side compared to sutureless side. However, there were some complications related to the socket left open to the oral cavity without suture.

Conclusion: The study concludes that post-operative complications such as pain and swelling were less without suture placement. The decision of placing sutures may depend on the category of the impacted tooth and patient compliance.

Key words: Post operative complication, Primary healing, Secondary healing, Third molar surgery

INTRODUCTION

Impaction is defined as a cessation of the tooth eruption caused by a clinical or radiographically detectable physical barrier in the eruption path or by an ectopic position.¹ The follicle of the third molar becomes apparent at the age of 6-7 years, and the most of the molar follicles can be diagnosed by the age of 8-9 years. The ages 14-16 years appear to be the latest for the radiographic appearance of the third molar after which the tooth is considered to be impacted or missing tooth.¹

The etiology of mandibular third molar impaction has focused on a number of factors including local

and systemic.² An impacted third molar is indicated for surgical extraction either due to as a prophylactic procedure or for the pathologic transformation of hard and soft tissue damage caused by the impacted tooth.² Various techniques are available for the surgical extraction of the impacted third molar, of which bur technique is considered to be one of the techniques with minimal patient discomfort in the removal of mandibular third molar under local anesthesia.³ Post-operative pain and swelling following surgical procedures is a matter of considerable consequence to most patients, and clinical strategies are aimed to reduce its incidence and severity.^{4,5} Factors contributing to the occurrence of pain and edema after third molar extraction are complex⁶ but are related to the inflammatory process that is initiated by surgical trauma. Injury to tissue during surgical procedure results in the release of chemical mediators of inflammation. More rarely, hemorrhage or sepsis may occur. Most surgeons agree that increased surgical time, trauma, and difficulty in tooth removal are important factors in post-operative complication.^{4,6} One of the factors most closely

Access this article online



www.ijss-sn.com

Month of Submission : 09-2016
Month of Peer Review : 10-2016
Month of Acceptance : 10-2016
Month of Publishing : 11-2017

Corresponding Author: Dr. Abdulhaseeb Quadri, Department of Oral and Maxillofacial Surgery, Subbaiah Institute of Dental Sciences, Purle, Shivamogga, Karnataka, India. E-mail: abdulhaseeb11@gmail.com

linked to intensity of post-operative pain and swelling is the type of healing of surgical wound.^{7,8} A clean surgically created wound that is approximated by sutures, staples, or tapes, the wound heals by the process termed primary healing. The major biological mechanism responsible for wound healing with primary closure is matrix deposition, which is needed to provide the disrupted tissue with new strength and integrity. The process of healing that takes place when the flap is not approximated is by secondary healing.

MATERIALS AND METHODS

This study was conducted at the Department of Oral and Maxillofacial Surgery, Subbaiah Dental College and Hospital, Shimoga. The patients, with bilaterally impacted mandibular third molars who required removal, either for prophylactic reasons or because of pain, participated in this study and have given their consent. Routine hematological investigation and radiographs-intraoral periapical radiographs orthopantomograph.

All the 50 patients who had bilateral impacted mandibular third molars were selected, and both the sides were surgically removed in a single sitting, primary closure was adapted on right quadrant and secondary closure on left quadrant. All the patients underwent surgical removal of bilaterally impacted mandibular third molar under local anesthesia. Inferior alveolar, lingual and long buccal nerve block was administered first on right side and next on left side.

The small “V” shaped incision was made with one point at the distobuccal line angle of the second molar. One distal limb, which follows the external oblique ridge, and anterior limb avoids the gingival sulcus of the second molar and extends downward to the mucogingival junction (Figure 1).

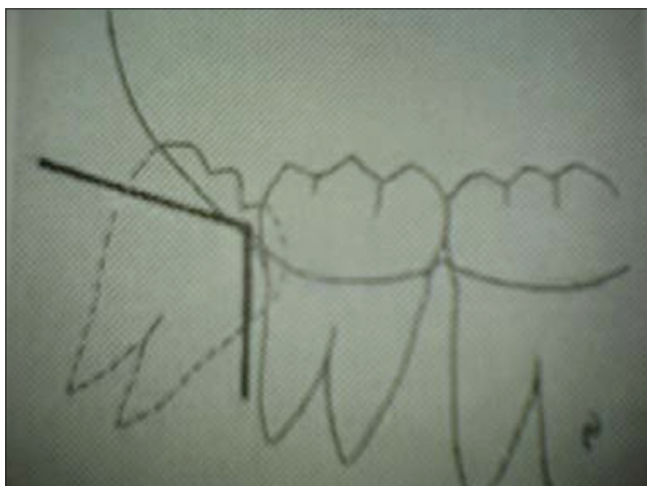

Figure 1: V-shape flap design

Mucoperiosteal flap was reflected and retracted with Austin’s retractor. Bone was removed with rose head bur and tapered fissure bur no. 702 adapting guttering technique. Constant irrigation using sterile isotonic saline solution was used to reduce the heat generated. The teeth were removed by odontectomy or into to. The wound was irrigated with sterile isotonic saline solution.

The flap was repositioned, and sutures were placed on the distal arm of the right quadrant for primary healing, using non-resorbable 3-0 black braided silk and over the left quadrant the mucoperiosteal flap was only repositioned and approximated and left open to the oral cavity. The entire procedure was completed in about 40-50 min. Postoperatively, all patients received amoxicillin 500 mg TID and diclofenac sodium 50 mg TID for 3 days. Patients were advised to use chlorhexidine mouthwash (0.12%) thrice daily postoperatively for 7 days postoperatively. The sutures were removed on the seventh post-operative day.

DISCUSSION

Surgical removal of impacted third molars is one of the most frequent procedures in Oral and Maxillofacial Surgery. The procedure is performed in following steps, diagnosis of the category of impacted tooth, anesthesia, raising of mucoperiosteal flap, bone removal by guttering, tooth removal and closure of socket. Suturing of the surgical wound is one of them that facilitate uneventful healing of the socket. Over a period of time, surgical procedures have been modified to minimize common intraoperative and post-operative complications such as bleeding, pain, swelling and alveolar osteitis. The purpose of placing suture is to achieve an intimate contact of gingival tissue around second molar, control of hemorrhage, to avoid food lodgment, wound dehiscence and to prevent infection of socket.⁷⁻⁹

The extent of swelling and the severity of pain are the chief indicators of patients comfort during the post-operative period after third molar removal.^{4,5} Factors affecting pain and swelling are mainly attributed to the flap design operative trauma, type of wound healing and individual response to the surgical trauma.^{4,5,9} When there is an inflammatory reaction, there will be collection of inflammatory fluids within the tissue spaces, which leads to diffuse swelling in the affected area. This may also aggravate the pain and cause trismus, by its pressure effect within the tissue spaces post-operative complications most commonly seen after third molar removal are pain, swelling, trismus and infection (alveolar osteitis) may be related to the surgical technique, difficulty in tooth removal and wound closure procedure. Literature shows the use of either suture

or sutureless techniques that lead to a primary intention healing or secondary intention.^{9,10}

Other factors affecting pain and swelling are individual pain tolerance, body response, and type of wound healing.^{11,12} Hence, there may be a chance of error to occur when case and control are in different individuals. But in this study, each case of similar impaction was selected, both case and control extraction site were in the same individual, performed at the single appointment and operated by one operating surgeon. The surgical procedure for removal of 38 followed 48, where one socket was closed primarily with sutures, and the other was left open to the oral cavity. In this study, we tried to manage the problem of accumulation of inflammatory fluid in tissue space by facilitating constant drainage using “V” shaped incision.

This provided adequate soft tissue reflection. The incision was smaller than that described by syndrome. During the healing phase in the posterior region of the dental arch, the anatomy of the ramus, tuberosity, gingival, and buccal mucosa will fall passively together, if this incision is used and the mucoperiosteal flap could be approximated without any sutures. Wait and Cherala in 2006¹³ studied the post-operative complications with “V” shaped incision. The study shows a result of a decreased incidence of post-operative complications such as pain, swelling, trismus with the secondary type of wound healing.

This study determined secondary healing to be comfortable for patients with regard to two parameters-swelling and pain. They were evaluated with visual analog scale (VAS), which is considered to be an efficacious tool to evaluate clinical parameters that influence the subjective experience of an individual such as pain. VAS scale a reliable method as proposed by Henrikson *et al.* measurement taken with reference to anatomical landmarks and swelling (Figure 2) was analyzed by measurement taken with reference to anatomical landmarks. According to our study the feedback from the patients and clinical reviews, almost all of them experienced more swelling and pain on sutured side. When they were reviewed on the 3rd day postoperatively, swelling was more obvious on the sutured side and relatively less on the side where sutures were not placed. The severity of swelling pain on the sutured side postoperatively was maximum on the 3rd day most of the patients, reduced on the 5th day and was almost normal on the 7th day in most of the post-operative day. Secondary closure technique facilitated escape of inflammatory fluid and allows escape of food debris from socket and removed chemical mediators may be the reason for comparatively less significant pain and swelling that was noticed.

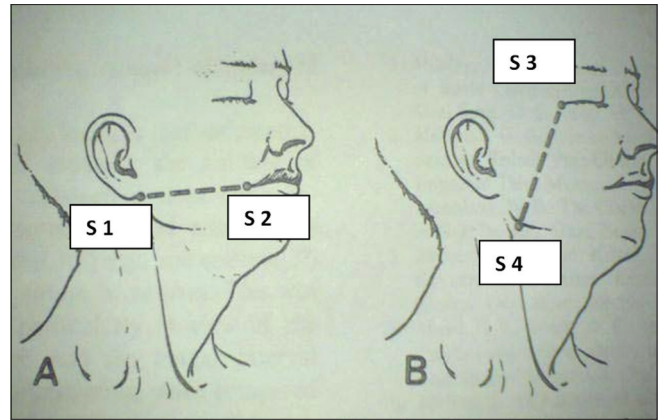


Figure 2: Swelling measurement reference points. S1 - ear lobule, S2 - corner of the mouth, S3 - lateral canthus of the eye, S4 - angle of the mandible

RESULTS

In this study of 50 patients with bilateral impacted tooth, 31 male 19 female participated. According to statistical analysis, the mean value for pain immediately after 6 h in group 1 (with suture) was 4.88, group 2 (without suture) 4.98. The mean values on group 1 side on day 1 - 4.28, day 2 - 3.60, day 3 - 2.94, day 4 - 2.38, day 5 - 1.82, day 6 - 1.42, and day 7 - 1.20; mean values in group 2 (without suture) day 1 - 3.96, day 2 - 2.48, day 3 - 2.30, day 4 - 1.64, day 5 - 0.70, day 6 - 0.22, and day 7 - 0.10. These values give an inference that the amount of pain experienced by the patient on group 1 was less for immediate 6-8 h compared to group 2, but during subsequent days pain was more on group 1 than group 2. Mean values for swelling in group 1 on day 3-11.7840, day 5-3920, day 7-10.9780 and group 2 on day 3-11.400, day 5-11.0920, day 7-8580. Discomfort of swelling was less in group 2 compared to group 1. Complications like postoperative sensitivity to thermal changes in 3 cases were noted. Bilateral mandibular nerve block was administered which was acceptable; all these patients maintained fairly good oral hygiene and chlorhexidine rinse was advised even then 6 patients had to suffer from food accumulation in the wound in secondary healing technique.

CONCLUSION

These results are in agreement with many of those reported in literature. Since this study is a single operator study, a multi-operator study is needed for a clear guidance of wound closure. Further studies are needed to assess long-term post-operative complication like periodontal defects and sensitivity in relation to the second molar. The results obtained in this study enable us to conclude that, in cases of equal intraoperative difficulty, open healing of surgical wound after removal

of impacted third molars produces less postoperative swelling and pain than that occurs with closed healing by hermetically sealed socket.

REFERENCES

1. Anderson JO. Text Book and Color Atlas of Tooth Impaction. Copenhagen: Elsevier Science Health Science Division; 1997.
2. Lopes V, Mumenya R, Harris C. Third molar surgery: An audit of the indications for surgery, post-operative complaints and patient satisfaction. *Br J Oral Maxillofac Surg* 1995;33:33-55.
3. Howe, GL. *Minor Oral Surgery*. 3rd ed. Bristol: John Wright & Sons; 1985.
4. Grossi GB, Maiorana C, Garramone RA, Borgonovo A, Creminelli L, Santoro F. Assessing postoperative discomfort after third molar surgery: A prospective study. *J Oral Maxillofac Surg* 2007; 65:901-17.
5. Rood JP, Yates C, Buchanan M. Post-operative swelling and trismus after mandibular third molar removal with the lingual split bone technique. *Int J Oral Surg* 1979;8:31-5.
6. Buri CH, Seldin EB. Types, frequencies and risk factors for complications after 3rd molar extractions. *J Oral Maxillofac Surg* 2003;61:1379-89.
7. Dubois DD, Pizer ME. Comparison of primary and secondary closure technique after removal of impacted mandibular third molars. *J Oral Maxillofac Surg* 1982;42:631-4.
8. Pasaquolini D, Cocero N, Castelle A. Primary and secondary closure of surgical wound after removal of impacted mandibular 3rd molar; a comparative study. *J Oral Maxillofac Surg* 2005;34:52-7.
9. Laskin DM. *Text Book of Oral and Maxillofacial Surgery*. Philadelphia: WB Saunders; 2013.
10. Chiapasco M, De Cicco L, Marrone G. Side effects and complications associated with third molar surgery. *Oral Surg Oral Med Oral Pathol* 1993;76:412-20.
11. Al-Khateeb TL, el-Marsafi AI, Butler NP. The relationship between the indications for the surgical removal of impacted 9.third molars and the incidence of alveolar osteitis. *J Oral Maxillofac Surg* 1991;49:141-5.
12. Krekanov L. Alvelitis after operative removal of 3rd molar in the mandible. *Int J Oral Surg* 1981;10:173-9.
13. Waite PD, Cherala S. Surgical outcome of suture-less surgery in 366 impacted third molar patients. *J Oral Maxillofac Surg* 2006;64:669-73.

How to cite this article: Quadri A, Quadri S, Khan T. Comparative Study of Post-operative Complications in Third Molar Surgery with and without Sutures: A Prospective Study. *Int J Sci Stud* 2016;4(8):168-171.

Source of Support: Nil, **Conflict of Interest:** None declared.