

Periumbilical Incision Versus Intraumbilical Incision for Laparoscopic Appendectomy: A Randomized Comparative Study

Kabir Rajkhowa¹, Mituban Gogoi¹, Ishanku Baruah²

¹Associate Professor, Department of Surgery, Assam Medical College and Hospital, Dibrugarh, Assam, India, ²Registrar, Department of Surgery, Assam Medical College and Hospital, Dibrugarh, Assam, India

Abstract

Introduction: The periumbilical (PU) incision is more commonly used for single incision laparoscopic surgery than the intraumbilical (IU) incision. Till now, no study on Indian population has compared the adverse outcomes of PU and IU incisions on the post-operative outcome in patients. We observed the wound complication rates of patients undergoing appendectomy according to the types of laparoscopic surgical approach.

Materials and Methods: A randomized prospective observational study was conducted on 320 patients presenting for laparoscopic appendectomy. 155 patients in group IU were operated with the IU incision and 165 patients in group PU were operated with the PU incision. We compared the post-operative outcomes according to the type of laparoscopic incision.

Results: In both the groups operation time, post-operative hospital stay and post-operative analgesic requirement were similar. Two cases (1.2%) in the IU group IU and five cases (3%) in the PU group PU developed wound infections. The umbilical complications rate was comparable ($P > 0.05$).

Conclusion: The IU incision being relatively easier to perform and has better cosmetic results and seems to be a safe and feasible alternative for the PU incision for single port laparoscopic appendectomy.

Key words: Intraumbilical incision, Periumbilical incision, Single port laparoscopy

INTRODUCTION

Laparoscopic surgery has become increasingly popular with the various fields of general surgery.¹⁻³ The creation of pneumoperitoneum requires an periumbilical (PU) incision or intraumbilical (IU) incision to introduce the needle into the abdomen. The PU incision is a commonly used method for the initial approach of the laparoscope into the abdomen.^{4,5} It is often U-shaped placed below or above the umbilicus and it cuts through the skin, the subcutaneous fat, and the fascia. In contrast for the IU

incision a vertical linear incision dividing the skin and fascia are needed to reach abdominal cavity. Since for IU incision less fascial tissue needs to be separated so it is easier to perform, less traumatic and has gained popularity for use in the single incision laparoscopic surgery, which has been proven to be a feasible alternative for conventional laparoscopic surgery with better cosmetic merit.^{6,7} The umbilicus has long been considered as a store house of bacteria contributing to post-operative abdominal port wound infection for laparoscopic surgery.⁵ There are no studies which has compared the complication rates of the IU and PU incisions for single port laparoscopic appendectomy. We hypothesized that with adequate cleaning and preparation of the umbilical ring it becomes devoid of its excess bacterial flora like the skin surrounding the umbilicus after cleaning and preparation and that the wound infection rate will show no difference. To test our hypothesis, we designed a randomized prospective study to compare the post-operative wound complication rates

Access this article online



www.ijss-sn.com

Month of Submission : 09-2016
Month of Peer Review : 10-2016
Month of Acceptance : 10-2016
Month of Publishing : 11-2016

Corresponding Author: Dr. Kabir Rajkhowa, Department of Surgery, Assam Medical College and Hospital, Barbari, Dibrugarh – 781 032, Assam, India. Phone: +91-9849312139. E-mail: drkabirrajkhowa123

of patients treated with laparoscopic appendectomy using the IU and the PU approach.

MATERIALS AND METHODS

After institutional ethical clearance and departmental permission, this prospective observational study was conducted concurrently in the various medical colleges of Assam, among the patients presenting for laparoscopic appendectomy by a total of 12 surgeons from January 2012 to December 2015. The patients age, weight, and other relevant demographic data were recorded patients having severe systemic disease were excluded from the study group. The patients were familiarized with the study procedure and consent was obtained from all patients. A total of 343 patients were enrolled into this study who presented for elective and emergency appendectomy (Figure 1). 23 patients were excluded due to demand for open surgery and due to associated severe systemic disease. A total of 320 patients were observed after exclusion. Patients were then assigned to the group IU or the group PU based computerized randomization.

Outcome variables studied were wound complication rate, duration of hospital stay and amount of tramadol

consumption on post-operative day 1. All complications were recorded and reviewed. Post-operative umbilical complications included any cases of wound infection and/or hematoma formation.⁸Wound infection was defined as a state of localized erythema, edema or warmth accompanied by subjective pain, with or without purulent discharge.⁸ Any case of internal organ injury related with the insertion of the umbilical trocar were recorded. All patients received antibiotics intravenously at induction of anesthesia as per hospital protocol. In group IU, the umbilicus was cleaned thoroughly preoperatively with cotton swabs, using alcohol. Intraoperative routine manual cleaning was also performed in both the Groups IU and PU. After cleaning the umbilicus intraoperatively, skin preparation was done in both the groups using 10% betadine. In group IU, a midline incision was made inside the umbilicus. With slight retraction of the skin on both sides of the umbilicus using tissue forceps the fascia lying below the umbilicus was visualized and with further dissection the peritoneal cavity was easily entered. Whereas in group PU, a U-shaped incision below the umbilicus was made. The subcutaneous fat was dissected, and the exposed fascia was opened using electrocoagulation. After opening of the fascia, either direct trocar insertion or insertion after insufflation with a Veress needle was done. We used an 11 mm trocar for

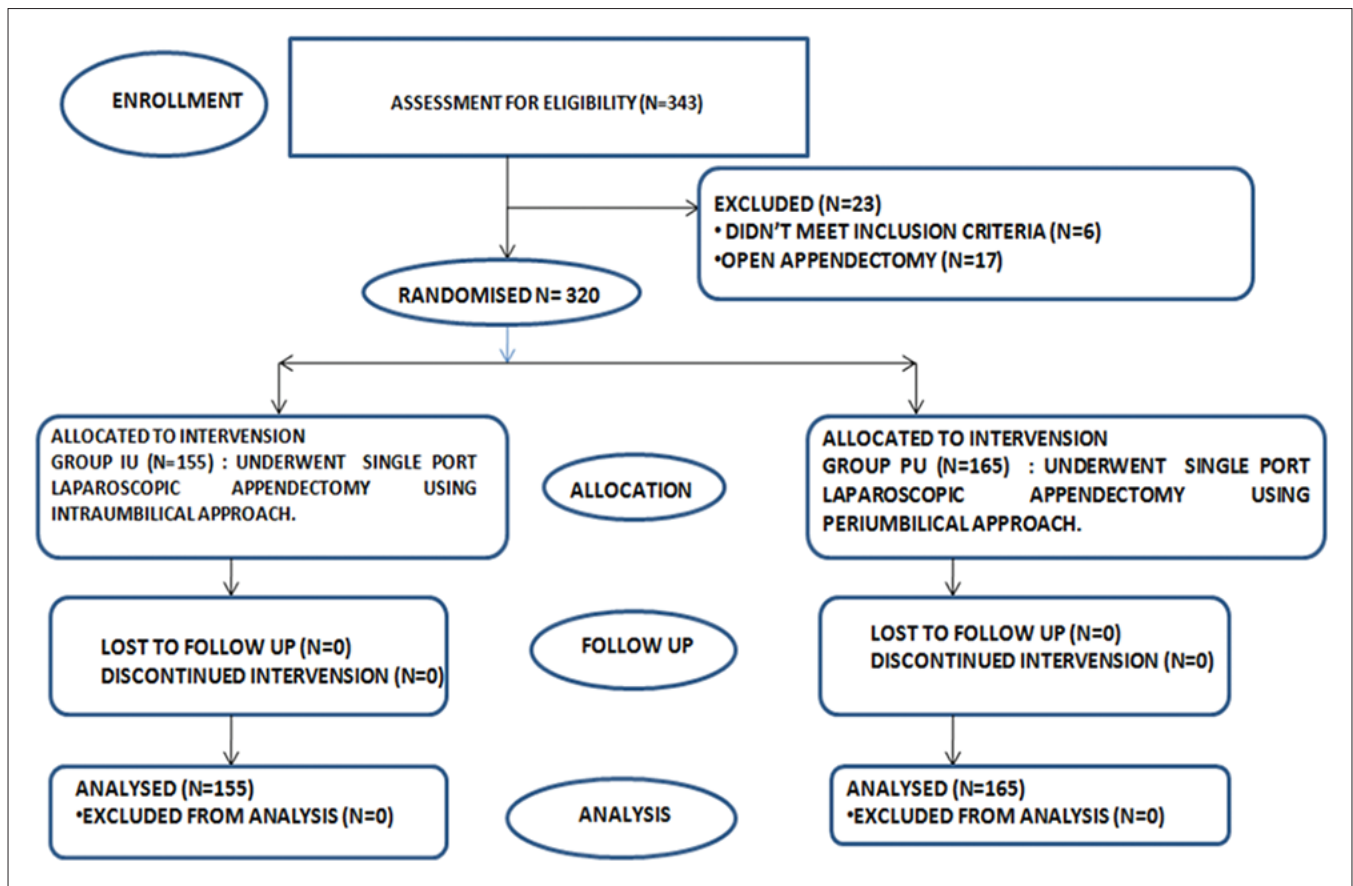


Figure 1: Consort flow diagram

the umbilical port. Laparoscopic appendectomy using conventional technique was done. To avoid contamination of the fascia or skin, the appendix was retrieved from the peritoneal cavity within a Lap-bag through the umbilical port in all of our study patients. Postsurgery in group IU, a single full layer suture at the midpoint using absorbable suture material (Vicryl, Ethicon Inc., Somerville, NJ, USA) was used for wound closure, without the need for any additional sutures for the subcutaneous fat or skin. A piece of rounded dry gauze was placed in the umbilicus and adhesive bandage was applied. In group PU, after appendectomy wound closure was done in a layers, with separate closure for the fascia, the subcutaneous fat, and the skin. An abdominal drain was placed through a separate pelvic incision if required in both the groups. For post-operative pain control opioid analgesic Tramadol 50 mg slow IV was given to patient on request and repeated if necessary. Post-operative injection tramadol consumption was recorded up to the first 24 h. Postoperatively, the patients were administered two or more further doses of antibiotics. Patients were observed in surgical ward postoperatively and every 24 hourly wound dressing was done to observe for any signs of wound infection. Patients were discharged as per hospital protocol and asked to come for review at the outpatient department after 7 days or immediately if they had any wound discharge. The study was done as a pilot study hence sample size calculation was not done. The data obtained from these patients was analyzed using SPSS version 21.0. The data were tested for normality and compared using appropriate statistical tests. Any P value > 0.05 was considered statistically significant.

RESULTS

In our study, the IU incision was used for 155 patients and the PU incision was used for 165 patients for laparoscopic appendectomy. There was no statistically significant difference in the demographic parameters of the patients in both groups (Table 1).

The mean age of the IU group was 48.35 years, and the mean age of the PU group was 46.6 years. The IU group consisted of 98 males (63.2%) and 57 females (36.8%), and the PU group consisted of 102 males (61.8%) and 63 females (38.2%). The mean body mass index of the IU and PU groups was 24.65 kg/m² and 23.89 kg/m², respectively. Their operation time between the two groups (64.52 min for IU vs. 63.78 min for PU) was comparable (Table 2).

Duration of post-operative hospital stay was 5 days in both the IU and PU groups. The mean post-operative tramadol consumption was 220 mg in the IU group and 228 mg in the PU group. There were 2 cases of umbilical

Table 1: Demographic parameters between the IU and PU groups

Variable	IU group (n=155)	PU group (n=165)	P
Age (years)	48.35±6.75	46.63±8.25	0.39 (t)
Sex ratio (male/female)	98/57	102/63	0.35 (c)
Body mass index (kg/m ²)	24.65±3.23	23.89±4.53	0.08 (t)
Operation time (min)	64.52±8.5	63.78±5.34	0.38 (t)
Systemic disease	68	72	

PU: Periumbilical, IU: Intraumbilical

Table 2: Post-operative outcomes in both IU and PU groups

Variable	IU group (n=155)	PU group (n=165)	P
Duration of hospital stay (days)	5	5	1 (C)
Postoperative tramadol consumption (mg)	220±35	228±45	0.07 (t)
Wound infection (%)	2 (1.3%)	5 (3%)	0.32 (C)
Major organ injury (%)	0	0	-

PU: Periumbilical, IU: Intraumbilical

infection in the IU group (01.3%) compared with 5 cases of umbilical infection in the PU group (3%), with no statistical significance ($P = 0.32$). There were no incidences of internal organ injury caused by trocar insertion in any group.

DISCUSSION

The search for better surgical cosmetic results led to the invention of laparoscopic key hole surgery. Laparoscopy used for appendectomy has significantly increased with the introduction of single port laparoscopic surgery.⁵ This method left virtually no scar after surgery.⁵ Similarly, Vidal *et al.*⁹ used a single-incision laparoscopic surgery performed with a suprapubic approach which left no apparently visible scar due to the pubic hair. In spite of these newer advances the PU incision for laparoscopy is still being widely used in our country. Lee *et al.*¹⁰ reported that single incision laparoscopic appendectomy performed with an IU incision had lower incidence of complications compared to open appendectomy and that infection rates were actually lower in the single incision group. Based on this observation, we compared laparoscopic single port appendectomy using the IU and PU approaches for our study, to observe which approach gave better postoperative results. In our study, the wound complication rates of the PU and IU approach did not show any significant difference. Wound infection was observed for 2(1.3%) patients in the IU group and 5(3%) patients in the PU group. All the patients were followed up at the outpatient clinic 7 days after

discharge. Of the 5 patients in the PU group, 3 patients had experienced mild serous wound discharge and 2 patients had dehiscence of the wound postoperatively, requiring suturing under local anesthesia. All our study patients had complete healing of the laparoscopy wound within 30 days. The lower incidence of complication observed in the IU incision could be because in this approach the subcutaneous layer of the abdomen is not penetrated, hence there is a less potential for seroma or hematoma formation, which mainly leads to postoperative wound infection. The PU incision on the other hand leaves an obvious scar close to the umbilicus, where healing may not be always take place perfectly.⁸ For the IU incision, the entire incision is contained within the umbilical ring which itself contains many skin folds making the scar virtually invisible.⁸ The IU incision is easy to perform as the fascia lies directly beneath the umbilical skin with virtually no subcutaneous fat hence the peritoneal cavity is entered can entered with minimal dissection. Second, the close proximity of the layers also allows for a much faster closure of an IU wound. In most of our patients, a single full layer suture was sufficient for port closure. In comparison, the PU incision needed a more laborious process of closure, meaning the fascia, the subcutaneous fat, and the skin all had to be separately closed. In the case of an obese patient with a thick layer of subcutaneous fat, the opening and closure of the PU trocar site is often quite difficult.^{8,11} In contrast by using the IU approach and with lateral retraction of the skin on both sides of the umbilicus, the umbilical ring is easily exposed in even obese patients.¹¹ All types of laparoscopic surgeries may benefit from applying the IU incision.^{8,11} This study was somewhat limited in that it was a prospective study, and we did not evaluate the incidence of incisional hernia which may occur in our patients after few years. Effects of systemic disease on the wound healing, such as perioperative glycemic status and body oxygen levels, were not assessed.

CONCLUSION

The IU incision is a safe and feasible alternative for the PU incision that can be easily performed with better cosmetic results. Our results have shown that despite the widespread belief that an IU incision will cause more wound infection actual wound complication rates are lower compared with PU incision.

REFERENCES

1. Sauerland S, Jaschinski T, Neugebauer EA. Laparoscopic versus open surgery for suspected appendicitis. *Cochrane Database Syst Rev* 2010;10:CD001546.
2. Holder-Murray J, Zoccali M, Hurst RD, Umanskiy K, Rubin M, Fichera A. Totally laparoscopic total proctocolectomy: A safe alternative to open surgery in inflammatory bowel disease. *Inflamm Bowel Dis* 2012;18:863-8.
3. Pearce NW, Di Fabio F, Teng MJ, Syed S, Primrose JN, Abu Hilal M. Laparoscopic right hepatectomy: A challenging, but feasible, safe and efficient procedure. *Am J Surg* 2011;202:e52-8.
4. Zollinger RM, Ellison EC, Zollinger RM. *Zollinger's Atlas of Surgical Operations*. 9th ed. New York: McGraw-Hill Medical; 2011.
5. Chow A, Purkayastha S, Nehme J, Darzi LA, Paraskeva P. Single incision laparoscopic surgery for appendectomy: A retrospective comparative analysis. *Surg Endosc* 2010;24:2567-74.
6. Kim HJ, Lee JI, Lee YS, Lee IK, Park JH, Lee SK, *et al.* Single-port transumbilical laparoscopic appendectomy: 43 consecutive cases. *Surg Endosc* 2010;24:2765-9.
7. Piskun G, Rajpal S. Transumbilical laparoscopic cholecystectomy utilizes no incisions outside the umbilicus. *J Laparoendosc Adv Surg Tech A* 1999;9:361-4.
8. Lee JS, Hong TH, Kim JG. A comparison of the periumbilical incision and the intraumbilical incision in laparoscopic appendectomy. *J Korean Surg Soc* 2012;83:360-6.
9. Vidal O, Ginestà C, Valentini M, Martí J, Benarroch G, García-Valdecas Suprapubic single-incision laparoscopic appendectomy: A nonvisible-scar surgical option. *Surg Endosc* 2011;25:1019-23.
10. Lee SY, Lee HM, Hsieh CS, Chuang JH. Transumbilical laparoscopic appendectomy for acute appendicitis: A reliable one-port procedure. *Surg Endosc* 2011;25:1115-20.
11. Iranmanesh P, Morel P, Inan I, Hagen M. Choosing the cosmetically superior laparoscopic access to the abdomen: The importance of the umbilicus. *Surg Endosc* 2011;25:2578-85.

How to cite this article: Rajkhowa K, Gogoi M, Baruah I. Periumbilical Incision Versus Intraumbilical Incision for Laparoscopic Appendectomy: A Randomized Comparative Study. *Int J Sci Stud* 2016;4(8):172-175.

Source of Support: Nil, **Conflict of Interest:** None declared.