Review Article

Print ISSN: 2321-6379
Online ISSN: 2321-595X
DOI: 10.17354/ijss/2016/604

Skeletal Dysplasias: Clinico-radiological Review

Sadineni Raghu Teja[1], Bhavyachand Manne[2], Boppana Durga Mahita[3]

[1]Seniour Resident, Department of Radiology, Dr Pinnamaneni Siddhartha Institute of Medicall Sciences & Research Foundation, Vijayawada, Andhra Pradesh, India, [2]Consultant Orthopaedician, VIRRD Hospital, Dwaraka Tirumala, Andhra Pradesh, India, [3]Consultant Paediatrician, Rainbow Hospitals, Vijayawada, Andhra Pradesh, India

Abstract

Skeletal dysplasias constitute a broad group of hereditary disorders with abnormal growth and malformations of cartilage and bone. There is a varied spectrum of clinical severity ranging from mildly effected short stature to lethal forms. They begin during early stages of fetal development and evolve throughout life. Clinical features and radiologic assessment are crucial for narrowing the differentials of this broad group of disorders. However, molecular analysis plays the definitive role for confirmation of diagnosis. A multidisciplinary team of specialists, including radiologists, pediatricians, genetic specialists, orthopedicians, and psychiatrists, is required for management of these disorders. In this article, we describe the features of common skeletal dysplasias, illustrate cases with clinical and radiological parameters for assessment, and discuss the differentiating findings for diagnosis and management.

Key words: Achondroplasia, Mucopolysaccharidosis, Osteochondrodysplasia, Osteogenesis imperfecta, Skeletal dysplasia

INTRODUCTION

Skeletal dysplasias are a group of heterogeneous conditions with abnormalities of the skeleton, predominantly involving abnormalities of bone shape, size, and density, which manifest as abnormalities of the limbs, chest, or skull.[1] The classification of skeletal dysplasias was initially on the basis of clinical – radiologic – pathological features for over the past 30 years; however, in recent times, there has been a change with predominant role of molecular abnormality associated with many of these conditions with a genetic defect.[2] International nomenclature of constitutional-intrinsic bone disease was in use from 1977 which has undergone various modifications in 1983, 1997, and 2001.[3] The major addition in 2001 was the inclusion of genetic dysostoses-osteochondrodysplasias.[3] The original five categories have been expanded to 32 groups which thus constitute a wide variety of disorders.

Since both bone and cartilage are affected in this group of disorders, they are also called osteochondrodysplasias.

Access this article online

www.ijss-sn.com

Month of Submission : 09-2016
Month of Peer Review : 10-2016
Month of Acceptance : 10-2016
Month of Publishing : 11-2016

Osteodysplasias include disorders of altered bone density with proportionate short stature, whereas chondrodysplasias may cause deformations and malformations with short trunk or short limb short stature.[4]

DISCUSSION

Individually, the skeletal dysplasias are rare, but collectively their birth incidence is 1/5000 approximately.[5] Many of them have autosomal dominant inheritance except enzyme deficiency. There are six entities represent 50 per million or approximately 40% of all skeletal dysplasias, which include osteogenesis imperfecta (OI), multiple epiphyseal dysplasia, spondyloepiphyseal dysplasia, achondroplasia (AC), pseudoachondroplasia (PseudoAC), and metaphyseal chondrodysplasia (MC).[6]

Dysplasia is a more diffuse abnormal growth of bones – either cartilaginous or osseous components, whereas dysostosis is an abnormal ossification of specific bones – individually or in combination.

When considering differential diagnosis of these disorders, the presence of proportionate or disproportionate short stature should be assessed. The body proportions are important clues to an exact diagnosis (Table 1).

Rubin[8] has proposed a dynamic classification of bone dysplasias where they are classified based on the location

Corresponding Author: Dr. Raghu Teja Sadineni, 503, Aruna Residency, Netaji Street, Patamatalanka, Vijayawada - 520 010, Andhra Pradesh. Phone: +91-9885939298. E-mail: sadineniraghu@gmail.com

Table 1: Molecular-pathogenetic classification of osteochondrodysplasias[7]

Gene and protein	Clinical phenotype
Defects in structural proteins	
Collagen:	
COL1	Osteogenesis imperfecta
COL2	Achondrogenesis type II
	Hypochondrogenesis
	Spondyloepiphyseal dysplasia (SED) congenital
	Spondyloepimetaphyseal dysplasia
	Kniest dysplasia
	Stickler syndrome I
COL9	Multiple epiphyseal dysplasia (MED) type 2
COL10	Metaphyseal dysplasia (Schmid type)
COL11	Stickler syndrome II
	Otospondylomegaepiphyseal dysplasia
COMP	Pseudoachondroplasia
	Multiple epiphyseal dysplasia type 1
Matrillin-3 (MATN-3)	Multiple epiphyseal dysplasia type 3
Perlecan	Schwartz-Jampel type-1,2
Defects in metabolic pathways.	
Diastrophic dysplasia sulfate transporter (DTDST)	Achondrogenesis 1B
	Athelosteogenesis II
	Diastrophic dysplasia
	Recessive MED
Arylsulfatase E	X-linked chondrodysplasia punctata
ANKH (Pyrophosphate transporter)	Craniometaphyseal dysplasia
CIC7	Severe osteopetrosis
Carboanhydrase II	Osteopetrosis with renal tubular acidosis
Defects in degradation of macromolecules	
Lysosomal enzymes	Mucopolysaccharidoses
	Mucolipidosis
Cathepsin K	Pyknodysostosis
Sedlin	X-linked SED tarda
Defects in growth factors and receptors	
Fibroblast growth factor receptor 1, 2	Craniosynostosis
Fibroblast growth factor receptor 3	Achondroplasia
	Hypochondroplasia
	Thanatophoric dysplasia I, II
PTH receptor	Jansen type metaphyseal dysplasia
Fibroblast growth factor receptor 23	Autosomal dominant hypophosphatemic rickets
PEX proteinase	X linked hypophosphatemic rickets
GNAS1	Pseudohypoparathyroidism
ROR-2	Robinow, brachydactyly type B
Defects in transcription factors	
SOX9	Campomelic dysplasia
GI13	Greig cephalopolysyndactyly
TRPS1	Trichorhinophalangeal dysplasia 1-3
TWIST	Saethre-Chotzen
CBFA-1	Cleidocranial dysplasia
SHOX	Leri-Weill syndrome

SED: Spondyloepiphyseal dysplasia, MED: Multiple epiphyseal dysplasia, DTDST: Diastrophic dysplasia sulfate transporter

within the bone and the underlying pathologic abnormality (Table 2).

When patients are suspected of dysplasias, short stature needs to be assessed as either proportionate or disproportionate. Disproportionate dwarfism due to short limb is further classified as rhizomelic (proximal portion), mesomelic (central portion), or acromelic (distal portion). Generally, radiological examination of three body regions, particularly hand anteroposterior (AP), pelvis with hips AP, and lateral view of lumbar spine, will give a good indication of extent of skeletal involvement and the likely diagnosis.

A brief description of important and common individual dysplasias is presented.

OI

OI is a heterogeneous group of congenital genetic disorder of collagen type 1 formation involving connective tissues and bones. Clinically, hydrocephalus, kyphoscoliosis, blue sclera, dental fragility, and hearing loss (otosclerosis) may be seen. Radiological features including osteoporosis, fragile bones that fracture easily, Wormian bones, codfish vertebral bodies, protrusion acetabuli, and elongated lumbar pedicles may be seen (Figure 1).

They are classified into following types:

- Mild: Type I (autosomal dominant with variable penetrance)
- Perinatal lethal: Type II (autosomal recessive)
- Progressive deforming: Type III (mostly sporadic)
- Types IV to VIII are variable in severity and uncommon.

AC Group

This group mainly includes thanatophoric dysplasia, AC, hypochondroplasia, PseudoAC (Table 3, Figures 2 and 3).

- Thanatophoric dysplasia - Most common lethal bone dysplasia after OI II.
  - Type I - Marked underdevelopment of skeleton, telephone handle femur.
  - Type II - Cloverleaf skull a distinctive feature, limb shortening milder, and bowing is not a feature.
- AC - Most common non-lethal skeletal dysplasia. Most cases present at birth. Rhizomelia, bullet-

Table 2: Dynamic classification of skeletal dysplasias[8]

Epiphyseal dysplasias	Epiphyseal hypoplasias	Failure of articular cartilage; spondylo-epiphyseal dysplasia Failure of ossification of center; multiple epiphyseal dysplasia
	Epiphyseal hyperplasia	Excess of articular cartilage; dysplasia epiphysealis hemimelica
Physeal dysplasias	Cartilage hypoplasias	Failure of proliferating cartilage; achondroplasia Failure of hypertrophic cartilage; metaphyseal dysostosis
	Cartilage hyperplasias	excess of proliferation cartilage; hyperchondroplasia excess of hypertrophic cartilage; enchondromatosis
Metaphyseal dysplasias	Metaphyseal hypoplasias	Failure to form primary spongiosa; hypophosphatasia Failure to absorb primary spongiosa; osteopetrosis Failure to absorb secondary spongiosa; craniometaphyseal dysplasia
	Metaphyseal hyperplasias	Excessive spongiosa; hereditary multiple exostosis
Diaphyseal dysplasias	Diaphyseal hypoplasias	Failure of periosteal bone formation; osteogenesis imperfecta Failure of endosteal bone formation; idiopathic osteoporosis
	Diaphyseal hyperplasias	Excessive periosteal bone formation; progressive diaphyseal dysplasia Excessive endosteal bone formation; hyperphosphatemia

Table 3: comparison between achondroplasia group

Body part	Achondroplasia	Hypochondroplasia	Pseudoachondroplasia
Skull and facial bones	Enlarged calvaria, shortened skull base, frontal bossing, midface hypoplasia	Normal	Normal
Spine (interpedicular distance)	Progressive reduction	Narrowing	Normal

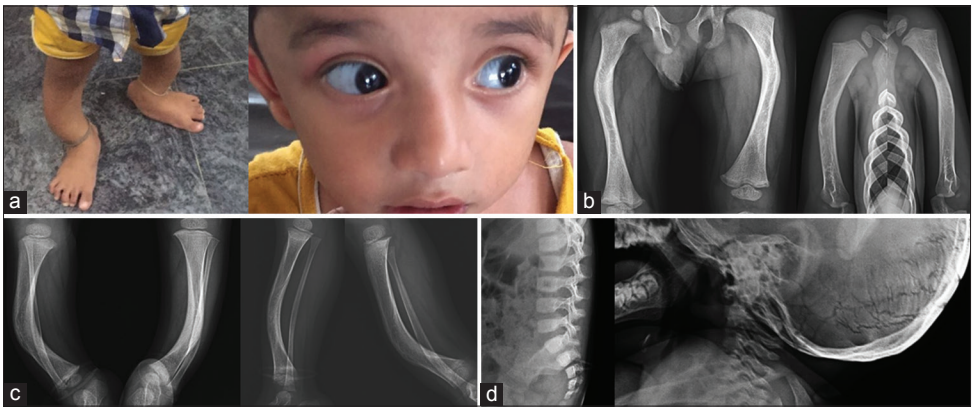

Figure 1: Clinical picture of a male child showing deformed lower limb with bowing deformity (a). Blue sclera of the eyes (a) is shown in child of osteogenesis imperfecta. Radiographs of the same child showing bowing deformities of long bones of both upper and lower limbs (b) due to multiple fractures. Lateral radiograph of lumbar spine shows elongated pedicles (c). Lateral radiograph of the lower skull shows Wormian bones (d)

shaped vertebra, thoracolumbar kyphosis, shortened pedicles, posterior vertebral scalloping, tombstone iliac wings (small and squared), progressive reduction in interpedicular distance, champagne glass pelvis, enlarged calvaria with shortened skull base, frontal bossing, and midface hypoplasia are seen.

- Hypochondroplasia - Very common disorder. Difficult to distinguish severe hypochondroplasia from mild AC. Interpeduncular narrowing in lumbar spine, brachydactyly, fibular overgrowth are seen; however, the skull is normal.
- PseudoAC - Children at 2-3 years present with delay in walking, Features similar to AC, except for normal interpedicular distance and normal facial and skull bones.

Mucopolysaccharidosis (MPS) Group

It is a heterogeneous group of inheritable lysosomal storage diseases. Undegradable glycosaminoglycans lead to progressive damage to tissues. They present early in childhood. Clinical features include short stature with coarse facial appearance, mental retardation, corneal opacities, joint contractures, hepatosplenomegaly, and cardiovascular problems.

Radiological features common to most of the subtypes include oval- or hook-shaped vertebral bodies, osteoporosis, abnormal configuration of pelvis with overconstriction of iliac blades and wide flaring of iliac wings, shortened tubular bones, and dysplastic changes in proximal femoral epiphysis.

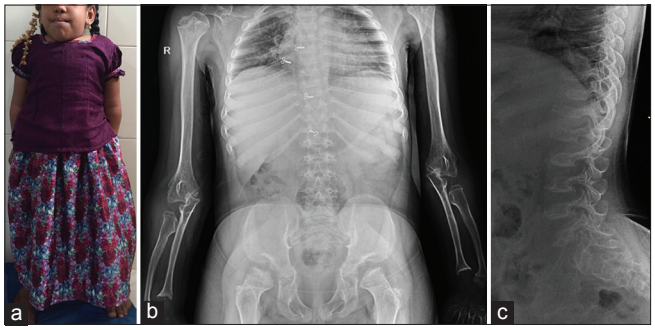

Figure 2: (a-c) Rhizomelic shortening with spine changes and pelvic bone changes in a child of achondroplasia

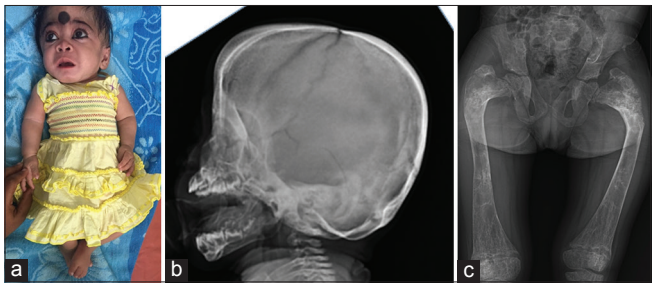

Figure 3: (a-c) Skull and pelvic bone changes in a child of achondroplasia

There are various subtypes of MPS group (Table 4).

Differentiation between types is mainly upon laboratory analysis particularly urine analysis, leukocytes, and fibroblastic cultures though radiographic features may help in narrowing the differentials (Figures 4 and 5, Table 5).

MC

It is characterized by dwarfing and improper mineralization of the shafts of bones in the metaphyseal region. They are of various types which include Jansen type, Schmid type, Spahr-Hartmann type, and McKusick type (Figure 6 and Table 6).

Osteopetrosis

It is characterized by failure of bone resorption due to a deficiency of osteoclasts. It is of two types, congenita (autosomal dominant) or tarda (autosomal recessive). Clinical features may be non-specific, and few include bleeding, anemia, failure to thrive, cranial nerve, and optic nerve palsies. Often, it remains clinically silent and detected as an incidental finding. Radiologically, there is increased density of bone, os-in-os (bone within a bone) appearance (Figure 7).

Fibrous Dysplasia

It is a benign fibro-osseous pathologic entity of undetermined etiology. It is characterized by expanding fibro-osseous tissue in interior of affected bones and is predominantly a lesion of growing skeleton. It may be

Table 4: Classification of MPS

MPS I	MPS IH: Hurler's syndrome MPS IS: Scheie's syndrome MPS IH-S: Hurler-Scheie syndrome
MPS II	Hunter's syndrome
MPS III	Sanfilippo syndrome
MPS IV	Morquio-Brailsford
MPS VI	Maroteaux-Lamy syndrome
MPS VII	Sly syndrome
MPS IX	Natowicz syndrome

MPS: Mucopolysaccharidosis

Table 5: Difference between the common MPS types, Hurlers disease (IH) and Morquio-Brailsford disease (IV)

Hurlers disease (IH)	Morquio-Brailsford disease (IV)
J-shaped sella	No J-shaped sella
Oar-shaped ribs	No oar-shaped ribs
Inferior beaking of vertebrae	Central beaking of vertebrae
Tapering of ileum	No tapering of ileum
Proximal metacarpal pointing	Proximal metacarpal rounding

MPS: Mucopolysaccharidosis

mono-ostotic or polyostotic. It may be asymptomatic and present incidentally or with endocrine dysfunction, almost any bone may be affected, most commonly femur, tibia, humerus, rib or facial bone. Radiograph may show typical ground glass appearance of lesions, cortex may be thinned by endosteal erosions, but there is always a thin shell of cortex (Figure 8 and Table 7).

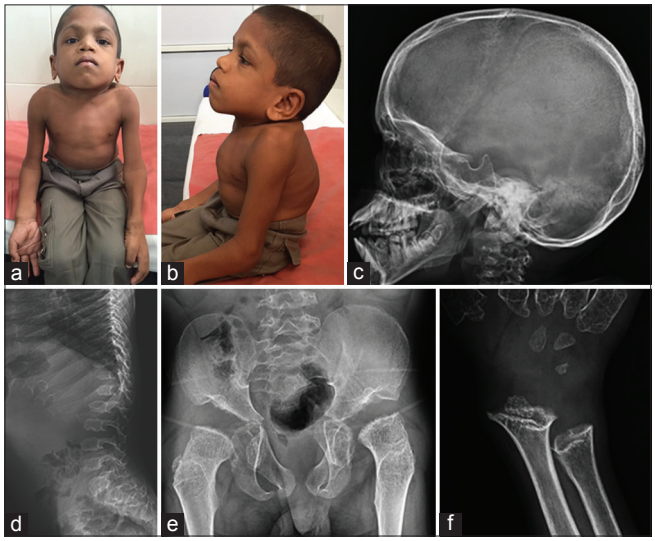

Figure 4: (a-f) A 9-year-old child diagnosed as mucopolysaccharidoses possibly Hurlers syndrome shows kyphoscoliosis, short trunk dwarfism, barrel-shaped thorax, large head. Radiographs of the same child, lateral view of dorsolumbar spine shows inferior end plate beaking and oar-shaped ribs, pelvis AP view shows abnormal configuration of pelvis with overconstriction of iliac blades and wide flaring of iliac wings with dysplastic changes in proximal femoral epiphyses, lateral skull radiograph showing elongated J-shaped sella, and wrist radiograph shows proximal pointing metacarpals and angulated radius and ulna

Antenatal Evaluation

Despite recent advances in imaging, fetal skeletal dysplasias are difficult to diagnose *in utero*. There are various factors that lead to difficulty in intrauterine diagnosis, which include large number of skeletal dysplasias and their

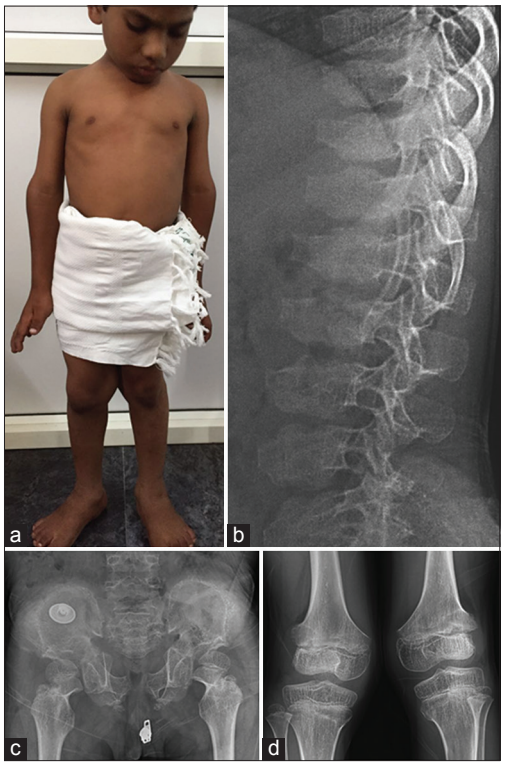

Figure 5: (a-d) Clinical picture of a child with mucopolysaccharidosis shows bowing short-trunk dwarfism; characteristic posture with knock knees. Lateral radiograph of spine shows central beaking, femoral epiphyseal changes, and metaphyseal changes at knee

Table 6: Differences between main types of metaphyseal chondrodysplasias

Jansen's type	Schmid's type	McKusick type
Mental retardation	excessive lumbar lordosis with severe thigh and leg bowing, genu varum	Cartilage-hair dysplasia
Wide eyes with monkey like stance	wrist swelling, elbow contractures	Atlantoaxial instability
Ostebulbous metaphyseal expansion of long bones	Splaying, irregularity and cupping of the metaphysis (similar to rickets)	Ankle deformity due to fibular overgrowth

Table 7: Differences between few common and important osteochondrodysplasias

Body part	Hurlers syndrome (MPS)	Thanatophoric dwarfism	Achondroplasia	Osteogenesis imperfecta
Skull	Enlarged J-shaped sella	Clover leaf skull, Kleeblattschädel	Enlarged calvaria, narrow foramen magnum, vertical straight sinus	Basilar impression, Wormian bones
Thorax	Oar-shaped ribs	Long narrow thorax	Shortened ribs	Short thick beaded ribs
Spine	Inferior beaking	Platyspondyly	Spinal canal stenosis, decreased interpedicular distance	Osteoporotic biconcave vertebra
Limbs	Pointing metacarpals	Telephone handle femur	Rhizomelia, champagne glass pelvis, inverted v configuration	Multiple fractures, bowing of long bones, zebra stripe sign

MPS: Mucopolysaccharidosis

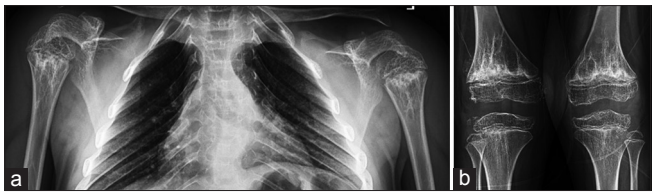

Figure 6: (a and b) Radiographs of a child showing irregular frayed and splayed metaphysis with serrated margins predominantly effecting humerus and femurs

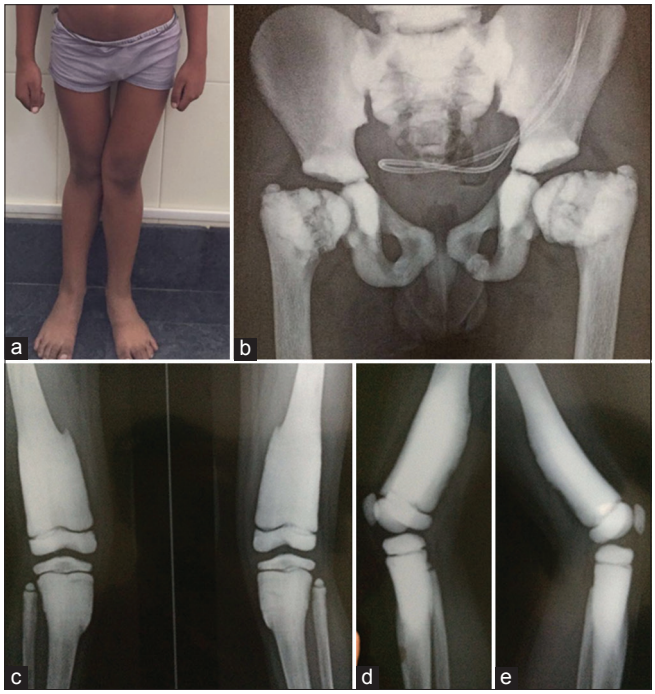

Figure 7: (a-e) Clinical picture shows knock knee appearance seen in a case of osteopetrosis. Radiograph of pelvis with femurs shows diffuse or multifocal bone sclerosis with bone in bone appearance. Radiographs of knee show genu valgum, club-shaped bones, and flask-shaped femoral metaphyses

phenotypic variability with overlapping features, inability of ultrasonography to provide an integrated view, and variability in the time at which findings manifest in some skeletal dysplasias.[9] The diagnosis of dysplasias in a fetus is important for many reasons. It provides the parents with an opportunity to consider pregnancy termination and also provides information regarding inheritance patterns (Figure 9).

There are various treatment options for children born with skeletal dysplasias depending on severity and type. Few patients may benefit from drugs that increase mineralization, whereas others may require surgical correction, prosthetic restorations, and length heightening operations.[5]

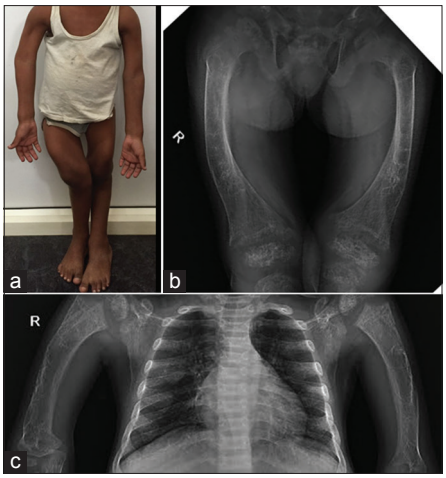

Figure 8: (a, b and c) Deformities of bilateral upper and lower limbs with radiograph showing ground-glass appearance of fibrous dysplasia

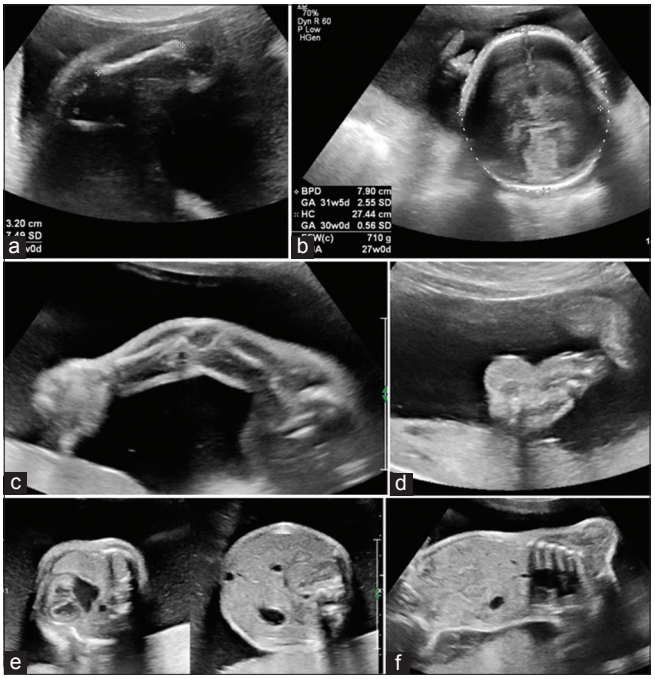

Figure 9: (a-f) Ultrasound images of a fetus of approximately 25-26 weeks show short femur corresponding to 20 weeks, large head corresponding to 27 weeks, rhizomelic shortening of upper limb, club foot, and narrow thorax when compared to abdomen. All these features are sonological features suggestive of skeletal dysplasias

CONCLUSION

Clinical manifestations and radiological investigations are crucial for the differential diagnosis in skeletal dysplasias. Systematic approach of findings helps in narrowing the differentials, and laboratory analysis may further the confirmation in few disorders. They require

management by a multidisciplinary team of specialists, including radiologists, pediatricians, genetic specialists, orthopedicians, and psychiatrists.

REFERENCES

1. Rimon DL, Lachman RS. The chondrodysplasias. In: Emery AE, Rimon DL, editors. Emery and Rimoin's Principles and Practice of Medical Genetics. New York, NY: Churchill Livingstone; 1983. p. 703-33.
2. Savarirayan R, Rimoin DL. The skeletal dysplasias. Best Pract Res Clin Endocrinol Metab 2002;16:547-60.
3. Hall CM. International nosology and classification of constitutional disorders of bone (2001). Am J Med Genet 2002;113:65-77.
4. Andersen PE Jr, Hauge M. Congenital generalised bone dysplasias: A clinical, radiological, and epidemiological survey. J Med Genet 1989;26:37-44.
5. Tüysüz B. A new concept of skeletal dysplasias. Turk J Pediatr 2004;46:197-203.
6. Wynne-Davies R, Gormley J. The prevalence of skeletal dysplasias. An estimate of their minimum frequency and the number of patients requiring orthopaedic care. J Bone Joint Surg Br 1985;67:133-7.
7. Superti-Furga A, Bonafé L, Rimoin DL. Molecular-pathogenetic classification of genetic disorders of the skeleton. Am J Med Genet 2001;106:282-93.
8. Rubin P. The Dynamic Classification of Bone Dysplasias. Chicago: Year Book Medical Publishers, Inc.; 1964.
9. Dighe M, Fligner C, Cheng E, Warren B, Dubinsky T. Fetal skeletal dysplasia: An approach to diagnosis with illustrative cases. Radiographics 2008;28:1061-77.

How to cite this article: Teja SR, Manne B, Mahita BD. Skeletal Dysplasias – Clinico-radiological Review. Int J Sci Stud 2016;4(8):223-229.

Source of Support: Nil, **Conflict of Interest:** None declared.