

# Use of Lateral Cephalometric Analysis in Diagnosing Craniofacial Features in Papillon-Lefevre Syndrome

Abhishek Soni

Senior Lecturer, Department of Oral Medicine & Radiology, Modern Dental College and Research Center, Indore, Madhya Pradesh, India

## Abstract

Knowledge of facial structure is important as an oral physician as our goal is to achieve ideal facial profile with esthetic harmony. Therefore, the understanding of the hard and soft tissue structures is necessary in planning proper management of the patients. This clinical case report of Papillon-Lefevre syndrome is an attempt to illustrate the advantage of specific cephalometric findings for assessing the hard and soft tissue variables in this group of patients that could be significant for diagnosis and proper treatment planning in establishing the esthetic and functional oral rehabilitation of patients affected with this syndrome.

**Key words:** Bone, Cephalometric analysis, Cephalometry, Craniofacial, Dental, Papillon-Lefevre disease, Radiography

## INTRODUCTION

Papillon-Lefevre syndrome (PLS) is an autosomal recessive disorder characterized by palmoplantar hyperkeratosis and rapidly progressive periodontitis, leading to premature loss of both deciduous and permanent teeth.<sup>1,2</sup> Literature often covers the etiological aspect, clinical manifestations, and management options in these patients, but little was found describing specific craniofacial findings and their role in the management of such patients. This article reports a clinical case of PLS laying emphasis on the use of specific cephalometric findings, both for skeletal and soft tissue variables, in diagnosing the significant craniofacial features and to justify their role in the evidence-based management of the patient with this syndrome.

## CASE REPORT

A 20-year-old male patient had reported to the outpatient department, complaining of esthetic problems and

difficulty in eating due to multiple missing teeth since childhood. Clinical history revealed that patient had an early loss of primary teeth followed by sequential loss of permanent teeth due to excessive mobility by the age of 12-13 years. The patient also gave a history of thickening and scaling of the skin of palms and soles since childhood, which aggravates during the monsoon season. Past medical history was noncontributory. Parents were not of consanguineous marriage, and other family members including siblings were apparently normal.

Extraoral examination revealed that patient had an average facial height with competent lips. Lower lip appears to be everted with deep mentolabial sulcus. Upper lip appears to be retruded. Cutaneous manifestation showed well-demarcated, thickened, dry, and scaly keratotic plaques on the dorsal surface of palms, which undergo crustations, cracking, and deep fissuring. Similar keratotic plaques had also been seen on the feet and the ankle. Ocular examination revealed no abnormality. Intraoral examination revealed partially edentulous maxillary and mandibular arches with interarch distance of 1.2 cm. The gingiva around the teeth was inflamed and swollen while the oral mucosa covering the edentulous area appeared normal (Figure 1). Based on history and clinical examination, a provisional diagnosis of PLS was made.

A panoramic radiograph was obtained which revealed generalized loss of alveolar bone and variable loss of

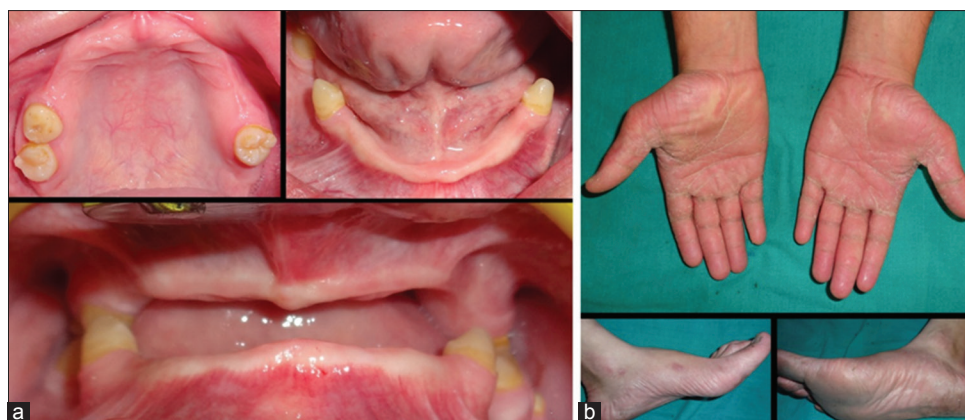
Access this article online



www.ijss-sn.com

Month of Submission : 08-2017  
Month of Peer Review : 09-2017  
Month of Acceptance : 10-2017  
Month of Publishing : 10-2017

**Corresponding Author:** Abhishek Soni, 263-Balaji Villa, Shivom Estate, Station Road, Dewas - 455 001, Madhya Pradesh, India.  
Phone: +91-9827511672/9340477983. Tel.: 07272-224403. E-mail: drabhishek\_soni@rediffmail.com

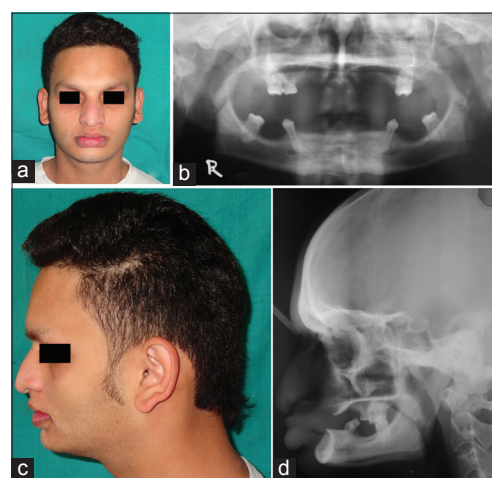


**Figure 1: A photograph of the patient diagnosed with Papillon-Lefevre syndrome: (a) Intraoral picture showing partially edentulous maxillary and mandibular arches with decreased interincisal distance; (b) cutaneous features showing hyperkeratotic plaques on the palms and feet**

bone support around all the present teeth. To assess the craniofacial features in detail, a lateral cephalometric analysis was advised which showed reduced lower facial height with low Frankfort mandibular plane angle (FMA =  $10^{\circ}$ ). SNA angle and ANB angle appears to be reduced suggestive of the retrognathic maxilla, leading to skeletal Class III profile. NAPog (angle of convexity) measurement showed skeletal concavity reconfirming the Class III skeletal relationship. There was a compensatory increase in the soft tissue thickness noted. Alteration in the soft tissues was evident for upper lip position; it was more retrusive, and nasolabial angle (NLA) was found to be more acute (Figure 2). The lateral skull radiograph showed no evidence of intracranial calcification. Routine laboratory investigations were within normal limits. A microbiologic examination by polymerase chain reaction analysis was normal.

Initially, the patient was kept on amoxicillin (500 mg TDS) and metronidazole (400 mg TDS) for 3 weeks and was advised chlorhexidine mouthwash (0.2%) 2-3 times daily. This was followed by oral prophylaxis and complete oral rehabilitation. Complete oral rehabilitation was planned with implant-supported prosthesis. For implant placement analysis, cone-beam computed tomography was advised which revealed generalized bone loss in the maxilla and variable amount of bone loss in mandible with knife-edge alveolar ridge in the anterior region (Figure 3). Due to inadequate bone height in maxilla and mandible for implant placement and unwilling of patient to undergo for zygomatic implant treatment, prosthetic rehabilitation was planned by giving telescopic crown attached with the denture base (Figure 4). Consultation of a dermatologist was taken for the evaluation of cutaneous manifestations.

On follow-up evaluation, after every 6 months for 3 years, the planned oral rehabilitation treatment was found to be

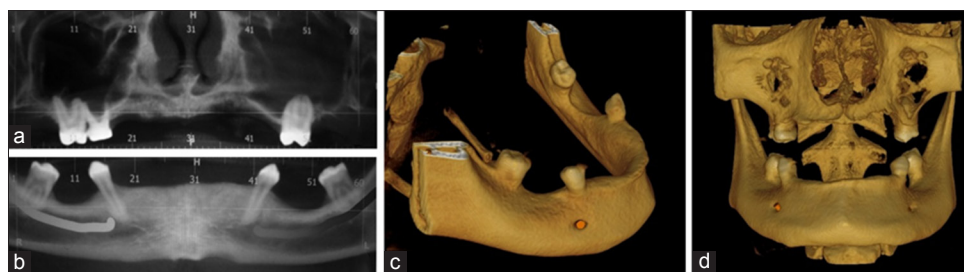


**Figure 2: (a) Pre-treatment facial view showing average facial height; (b) pre-treatment panoramic radiograph showing severe loss of alveolar bone; (c) pre-treatment lateral profile view showing retruded upper lip, everted lower lip, and deep mentolabial sulcus; (d) pre-treatment lateral cephalograms showing Class III skeletal relationship, reduced value for upper anterior face height/lower anterior face height, reduced Frankfort mandibular plane angle, SNA and ANB angle, skeletal concavity as evident by NAPog measurement, reduced nasolabial angle, and deep mentolabial sulcus**

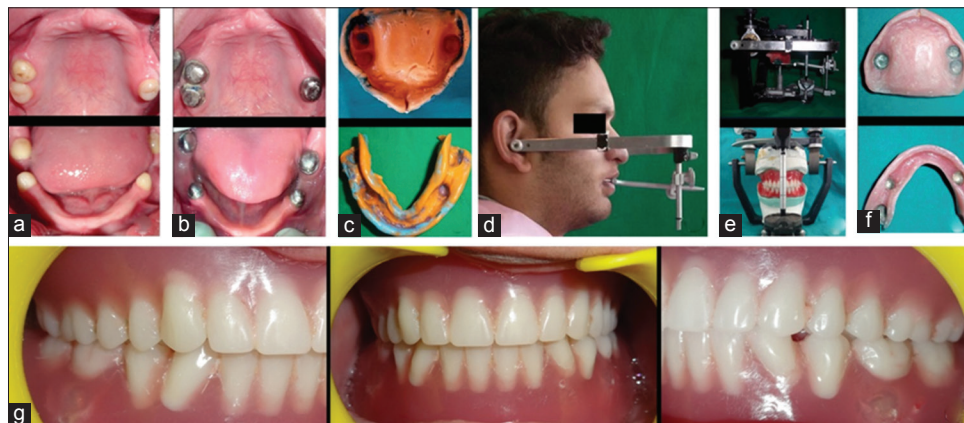
successful, and the patient facial profile was in good esthetic and functional harmony (Figures 5 and 6).

## DISCUSSION

Early diagnosis and management of PLS are quite challenging to the clinicians. The major determinants for the successful rehabilitation of the PLS patients are an early institution of well-planned treatment and compliance with prevention program. A multidisciplinary approach in managing such patient can improve the prognosis and quality of life of the affected individuals.



**Figure 3** (a) Cone-beam computed tomography image showing generalized bone loss in maxilla; (b) variable amount of bone loss is evident in and around the teeth in mandible; (c) 3D reconstruction image of mandible showing knife-edge alveolar ridge in the anterior region; (d) 3D volumetric reconstruction image of maxilla and mandible



**Figure 4:** Photograph of the Papillon-Lefevre syndrome patient showing step-by-step complete oral rehabilitation procedure: (a) Preparation of teeth to receive metal copings; (b) primary metal copings; (c) border molding was done with low fusing impression compound in the maxillary arch and with rubber-based putty material in the mandibular arch and final impression was made with the elastomeric impression material; (d) maxillomandibular record was taken using face-bow; (e) transfer of the face-bow record on the articulator; (f) final prosthesis with the secondary copings placed in the denture; (g) intraoral post-operative view after denture placement with the right and left posterior side occlusion

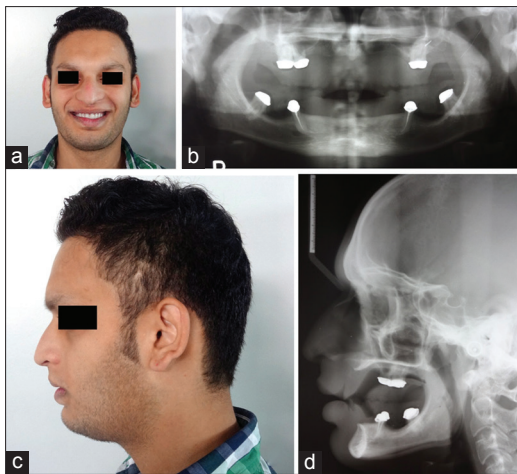
Early loss of the maxillary deciduous dentition is common in patients with PLS.<sup>3</sup> Premature loss of either the deciduous or the permanent teeth will cause loss of alveolar bone in both the vertical and horizontal dimensions.<sup>4</sup> Bindayel *et al.*,<sup>4</sup> in their study analyzed lateral cephalograms of eight PLS patients for both hard- and soft-tissue variables and revealed significantly altered values for FMA, ANB, SNA, NAPog (angle of convexity), and nasolabial (NLA) angle. They suggested that many patients with PLS develop a Class III relationship. This is in agreement with the study by Al-Khenaizan,<sup>5</sup> which also reported that patients with PLS have the characteristics of skeletal Class III malocclusion. In the present case also, the patient has a Class III skeletal profile.

Class III skeletal relationship in PLS patient is mainly attributed to retrognathic and hypoplastic maxilla rather than prognathic mandible. This has been revealed by the measurement of SNA and ANB angle.<sup>4</sup> SNA angle is the angle formed by the intersection of S.N. Plane and a line joining nasion and point A, which indicates the relative anteroposterior positioning of the maxilla in relation to the cranial base. A larger than normal value indicates

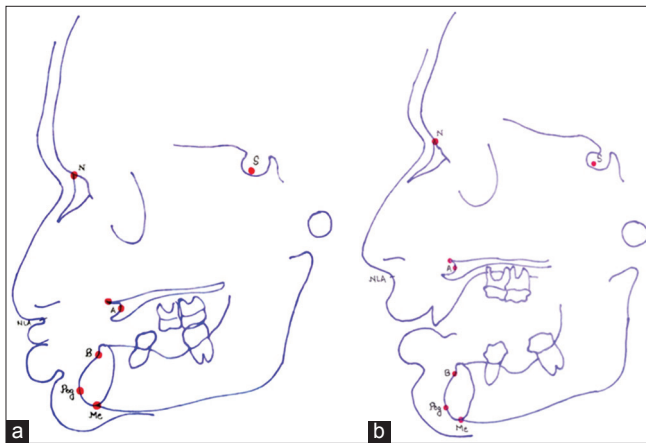
that the maxilla is prognathic (Class II) while the smaller value is suggestive of the retrognathic maxilla (Class III). ANB angle is formed by the intersection of lines joining nasion to point A and nasion to point B, which denotes the relative position of the maxilla and mandible to each other. An increase in this angle is indicative of Class II skeletal tendency while an angle that is less than normal or a negative angle is suggestive of a skeletal Class III relationship.<sup>6</sup> In our case, SNA and ANB angle is found to be reduced, suggestive of Class III skeletal relationship.

PLS patients also showed decreased lower facial height, mainly because of posterior (clockwise) inclination of the maxilla. This is evident by the ratio of upper anterior face height (UAFH) to the lower anterior face height (LAFH).<sup>4</sup> UAFH is the linear measurement from nasion to anterior nasal spine, while LAFH is the linear measurement from anterior nasal spine to menton.<sup>6</sup> The ratio of UAFH to LAFH is more significant than the individual measurement of UAFH and LAFH because UAFH varies with the superior-inferior dimension of the size of an adult skull while the ratio of UAFH/LAFH indicates the balance of facial proportions. UAFH/LAFH ratio <0.8 indicates





**Figure 5: (a) Post-treatment facial view; (b) post-treatment panoramic radiograph; (c) post-treatment lateral profile view; (d) post-treatment lateral cephalograms. All showing improvement in the facial esthetics and functional rehabilitation of patient**



**Figure 6: Tracing of relevant cephalometric landmarks: (a) Pre-treatment cephalometric tracing; (b) post-treatment cephalometric tracing. Landmarks depicted on cephalometric tracing – N: Nasion; Point A; Point B; Pog: Pogonion; Me: Menton; NLA: Nasolabial angle; SNA angle: Intersection of S-N plane and a line joining nasion and point A; ANB angle: Intersection of lines joining nasion to point A and nasion to point B; upper anterior face height (UAFH) - linear measurement from nasion to anterior nasal spine (N-ANS); lower anterior face height (LAFH) - linear measurement from anterior nasal spine to menton (ANS-Me); angle of convexity (NAPog) - intersection of a line from nasion to point A and a line from point A to pogonion; nasolabial angle (NLA) - formed between the lower border of the nose and a line connecting the intersection of nose and upper lip with the tip of the lip (labrale superius)**

a greater LAFH, or longer LAFH, while UAFH/LAFH ratio  $>0.8$  indicates a smaller LAFH or shorter LAFH. Due to decreased lower facial height, the FMA angle is also reduced.

Another parameter to be assessed is the angle of convexity, which reveals the convexity or concavity of the skeletal

profile. It is formed by the intersection of a line from nasion to point A and a line from point A to pogonion (NAPog). A positive angle or an increased angle suggests a prominent maxillary denture base relative to the mandible. A decreased angle of convexity or a negative angle is indicative of a prognathic profile.<sup>7</sup> In our case, NAPog measurement showed skeletal concavity reconfirming the Class III skeletal relationship. Due to this, the mandibular incisors, if present, tend to be retroclined as a dental compensation for maxillary retrognathism.<sup>4</sup>

Soft tissue evaluation should be taken into consideration in such patients during treatment planning.<sup>8,9</sup> A frequently used soft tissue parameter is the NLA.<sup>10</sup> The NLA is representative of soft tissue profile and remains an excellent clinical and cephalometric parameter to reveal the anteroposterior position of the maxilla and skeletal malocclusions.<sup>11</sup> NLA is the angle formed between the lower border of the nose and a line connecting the intersection of the nose and upper lip with the tip of the lip (labrale superius). Increased NLA reflects a maxillary retrusion or retroclined maxillary anterior and decreased NLA reflects a prognathic maxilla or proclined upper anteriors.<sup>12</sup> It has been suggested that a relatively small NLA adds to the Class III characteristics of affected patients.<sup>4</sup> Another soft tissue parameter is the evaluation of mentolabial sulcus, which represents the concavity below the lower lip.<sup>12</sup> In our case, NLA was found to be more acute indicating maxillary retrusion with deep mentolabial sulcus.

Early diagnosis and well-planned treatment protocol of Class III malocclusion is recommended for PLS patients to achieve normal maxillary growth, to prevent traumatic occlusion of the anterior teeth, and to improve the patient's facial profile.<sup>13</sup> Orthodontic correction is a documented approach in the literature for early correction of mild skeletal Class III discrepancy.<sup>14,15</sup> Moreover, this typically requires stable and healthy dental and periodontal tissues. For those with PLS, rapid periodontal breakdown could result in loss of some of the dentition. However, the literature shows that that orthodontic treatment combined with an antibiotic regimen can successfully control the periodontal signs of PLS and result in the maintenance of a healthy dentition.<sup>16-19</sup> In our case also, the patient was initially kept on prophylactic antibiotics followed by complete oral prophylaxis.

Furthermore, implant therapy has proved to be successful in these patients.<sup>20</sup> Dental implants offered better stability and retention of prosthesis, improved comfort and masticatory efficiency, and also the improved esthetics. According to Dhanrajani,<sup>1</sup> the use of implants in patients with severe periodontitis has been reported, and the results indicate that periodontally compromised patients can be

successfully treated with implants. However, in the present case, because of the severity of the skeletal discrepancies and the unavailability of adequate bone height and also, the strict regimen required to maintain a healthy dentition, orthognathic surgery followed by zygomatic implant might be a treatment alternative for this patient. However, as patient was not willing for such surgical intervention, prosthetic oral rehabilitation with telescopic crown attached with the denture base was planned.

Continuous monitoring and frequent recall appointments have shown to minimize the further periodontal deterioration.

## CONCLUSION

In summary, it appears reasonable to conclude that a stepwise management protocol should be followed in patient with PLS to prevent further bone loss and to maintain the structural integrity of orofacial musculature. Cephalometric analysis is proven to be a valid diagnostic option with significant clinical benefits in treatment planning of patient with PLS; this not only improves the esthetics but also help in functional oral rehabilitation of the patient. We hope that this clinical case study may serve as a guide for further future case studies with larger representative sample to confirm our findings and to justify an evidence-based management protocol.

## REFERENCES

1. Dhanrajani PJ. Papillon-Lefevre syndrome: Clinical presentation and a brief review. *Oral Surg Oral Med Oral Pathol Oral Radiol Endod* 2009;108:e1-7.
2. Shah J, Goel S. Papillon-Lefevre syndrome: Two case reports. *Indian J Dent Res* 2007;18:210-3.
3. Hart TC, Shapira L. Papillon-lefèvre syndrome. *Periodontol* 2000;6:88-100.
4. Bindayel NA, Ullbro C, Suri L, Al-Farra E. Cephalometric findings in patients with Papillon-Lefèvre syndrome. *Am J Orthod Dentofacial Orthop* 2008;134:138-44.
5. Al-Khenaizan S. Papillon-lefèvre syndrome: The response to acitretin. *Int J Dermatol* 2002;41:938-41.
6. Rossi M, Stuani MB, Silva LA. Cephalometric evaluation of vertical and anteroposterior changes associated with the use of bonded rapid maxillary expansion appliance. *Dent Press J Orthod* 2010;15:62-70.
7. Bhalajhi SI. Cephalometrics. In: Bhalajhi SI, editor. *Orthodontics-The Art and Science*. 4<sup>th</sup> ed. New Delhi: Arya Publishers; 2009. p. 167.
8. Tweed CH. Indications for the extraction of teeth in orthodontic procedure. *Am J Orthod Oral Surg* 1944;42:22-45.
9. Umale VV, Singh K, Azam A, Bhardwaj M, Kulshrestha R. Evaluation of nasal proportions in adults with class I and class II skeletal patterns: A cephalometric study. *J Orthod Sci* 2017;6:41-6.
10. Holdaway RA. A soft-tissue cephalometric analysis and its use in orthodontic treatment planning. Part I. *Am J Orthod* 1983;84:1-28.
11. Elias AC. The importance of the nasolabial angle in the diagnosis and treatment of malocclusions. *Int J Orthod* 1980;18:7-12.
12. Bhalajhi SI. Orthodontic diagnosis. In: Bhalajhi SI, editor. *Orthodontics: The Art and Science*. 4<sup>th</sup> ed. New Delhi: Arya Publishers; 2009. p. 141.
13. AlSarheed MA, Al-Sehaibany FS. Combined orthodontic and periodontic treatment in a child with papillon lefèvre syndrome. *Saudi Med J* 2015;36:987-92.
14. Ngan PW, Hagg U, Yiu C, Wei SH. Treatment response and long-term dent facial adaptations to maxillary expansion and protraction. *Semin Orthod* 1997;3:255-64.
15. Franchi L, Baccetti T, McNamara JA. Postpubertal assessment of treatment timing for maxillary expansion and protraction therapy followed by fixed appliances. *Am J Orthod Dentofacial Orthop* 2004;126:555-68.
16. Wiebe CB, Häkkinen L, Putnins EE, Walsh P, Larjava HS. Successful periodontal maintenance of a case with papillon-lefèvre syndrome: 12-year follow-up and review of the literature. *J Periodontol* 2001;72:824-30.
17. Pacheco JJ, Coelho C, Salazar F, Contreras A, Slots J, Velazco CH. Treatment of papillon-lefèvre syndrome periodontitis. *J Clin Periodontol* 2002;29:370-4.
18. Toygar HU, Kircelli C, Firat E, Guzeldemir E. Combined therapy in a patient with papillon-lefèvre syndrome: A 13-year follow-up. *J Periodontol* 2007;78:1819-24.
19. Lux CJ, Kugel B, Komposch G, Pohl S, Eickholz P. Orthodontic treatment in a patient with papillon-lefèvre syndrome. *J Periodontol* 2005;76:642-50.
20. Ullbro C, Crossner CG, Lundgren T, Ståhlblad PA, Renvert S. Osseointegrated implants in a patient with papillon-lefèvre syndrome. A 4 1/2-year follow up. *J Clin Periodontol* 2000;27:951-4.

**How to cite this article:** Soni A. Use of Lateral Cephalometric Analysis in Diagnosing Craniofacial Features in Papillon-Lefevre Syndrome. *Int J Sci Stud* 2017;5(7):121-125.

**Source of Support:** Nil, **Conflict of Interest:** None declared.