

Bilateral Symmetrical Areolar Vitiligo: A Case Report

Anji Reddy Kallam

Director & Plastic Surgeon, Department of Plastic Surgery, Alluri Sita Rama Raju Academy of Medical Sciences, Eluru, Andhra Pradesh, India

Abstract

Vitiligo of the areolar region of the breast is an uncommon compared to other parts of the body such as face, hands, and feet; whereas isolated vitiligo of bilateral areolae, without any other associated lesions in the body is even more uncommon. This patient was treated medically, but there was no improvement; instead the depigmentation progressed and involved whole of the areolae on either side or nipple on the right side. This problem can be managed surgically by deepithelialization of areolar skin keeping the dermal element and applying thin split skin graft over the raw area. We report the successful use of this technique in a 30-year-old woman with bilateral areolar vitiligo. Since this is a rare presentation and was successfully managed, we want to report this case.

Key words: Deepithelialization, Micrografting, Nipple and areola, Split skin grafting, Vitiligo

INTRODUCTION

Vitiligo is a relatively common pigmentary disorder affecting any part of the body occurring all over the world. It has no regional or racial predilection. Occurs in 0.5-2% of the population and both sexes are equally affected. This depigmentary disease has significant socio-economic problem apart from physical and cosmetic appearance.

It has a familial tendency and runs in families.¹ The most common sites that are affected are around the eyes (periorbital), around the mouth (perioral), hands and feet.

Even though the exact etiopathogenesis is still not conclusive several theories and hypothesis are offered to explain the defective melanin production. (1) Auto immune² and cytotoxic hypothesis resulting in melanocyte dysfunction, (2) neural hypothesis-Neurochemical mediator destroys melanin production, (3) oxidant-antioxidant mechanism.³ An intermediate or metabolic product of melanin synthesis results in melanocyte destruction, and (4) Intrinsic defect of melanocyte differentiation which impedes melanin production⁴. In spite of the all

hypothesis put forward the exact cause for depigmentation is not established and the combination of factors may be responsible for the cause of vitiligo.

The classification of the lesions is important and has therapeutic and prognostic significance.⁵

The most accepted classification is based on the distribution of the lesions

1. Localized vitiligo-focal, segmental and mucosal
2. Generalized vitiligo-acrofacial, vulgaris, and mixed
3. Universal vitiligo-complete depigmentation often associated with endocrinal dysfunction.

Body hair in vitiliginous macules may be depigmented and even after treatment there will not be return of pigmentation in the hair.

Areolar vitiligo can be segmental affecting one or both areolae including the nipple. The depigmentation starts as patches and spread centrifugally from center to the periphery. The lesions are rarely solitary, and they give good prognosis with surgical treatment.

CASE REPORT

A 30-year-old married female having a child presented with a history of depigmentation of both areolae (Figure 1), which started 9 years back and progressively involved whole of areola on either side. The nipple on the right side

Access this article online



www.ijss-sn.com

Month of Submission : 08-2015
Month of Peer Review : 09-2015
Month of Acceptance : 10-2015
Month of Publishing : 10-2015

Corresponding Author: Dr. Anji Reddy Kallam, Department of Plastic Surgery, Alluri Sita Rama Raju Academy of Medical Sciences, Malkapuram, Eluru - 534 005, West Godavari District, Andhra Pradesh, India. Phone: +91-9652570679. E-mail: reddykanji@gmail.com

is also depigmented. No history of any other complaints of itching, nipple discharge and pain. The rest of the breasts on either side are normal clinically. Her father is having Vitiligo patches on the legs. The patient had Homeo treatment for the last 5 years without any improvement. She also had treatment by Dermatologist without any benefit.

We performed surgery on both areolae (Figure 2). The epidermal layer of the skin of the areolae was carefully dissected and excised on either side (Figure 3a and b) and

the resultant defect (Figure 4a and b) was covered by thin split skin graft harvested from posterior aspect of the thigh (Figure 5a and b) and pressure dressing was applied. Primary dressing was done on the 5th post-operative day and the graft had taken up completely on either side and was discharged. She was on follow-up regularly, and there was no recurrence of the disease even after 3 months (Figure 6). Patient and the family are very happy at the outcome of the operation. However, we advised her to come for follow-up regularly at least for 1 year. The donor area healed well with normal pigmentation (Figure 7). The

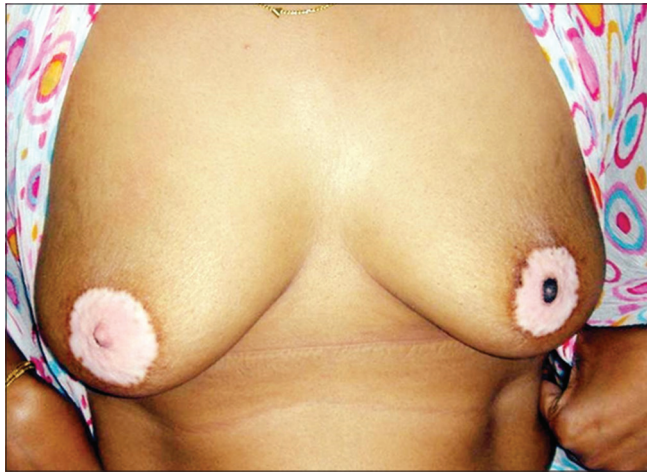

Figure 1: Pre-operative

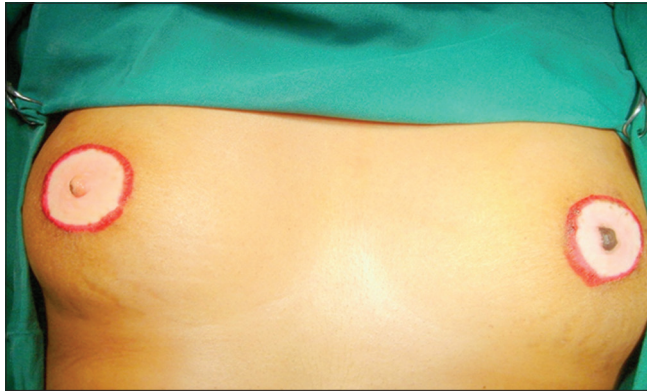


Figure 2: Pre-operative

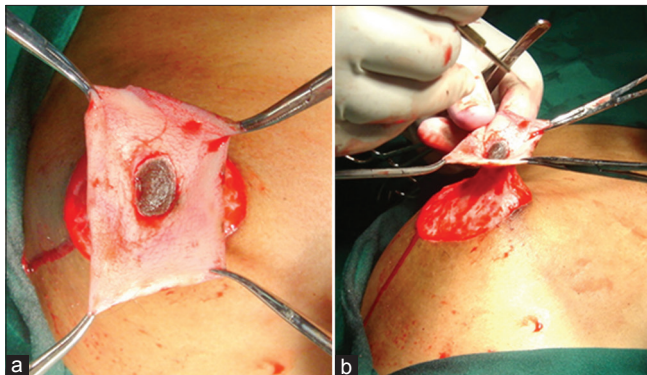


Figure 3: (a) De-epithelialization, (b) Pre-operative-deepithelialization

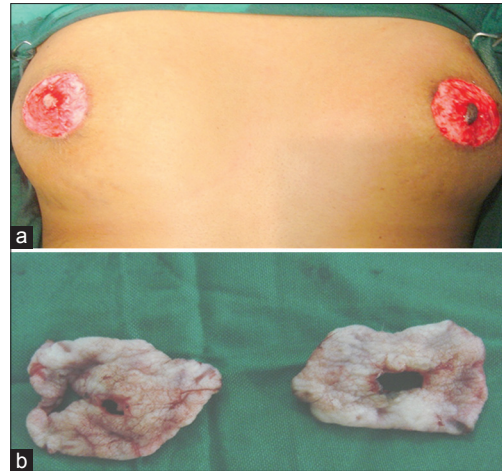


Figure 4: (a) After excision of lesions both sides, (b) excised specimen both sides

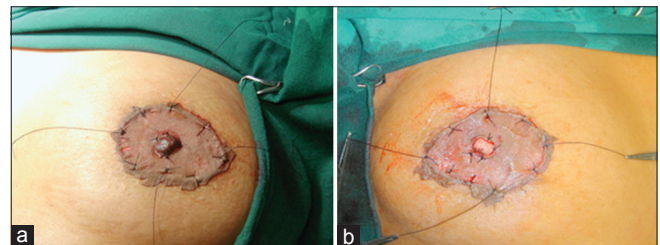


Figure 5: (a) Skin grafting right, (b) skin grafting left

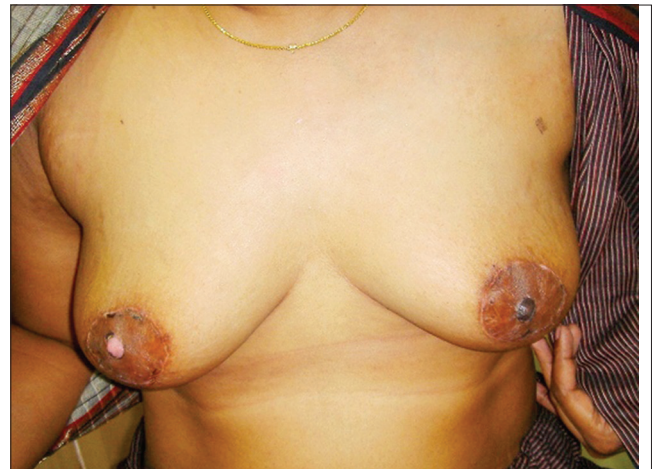


Figure 6: Post-operative - 3 months

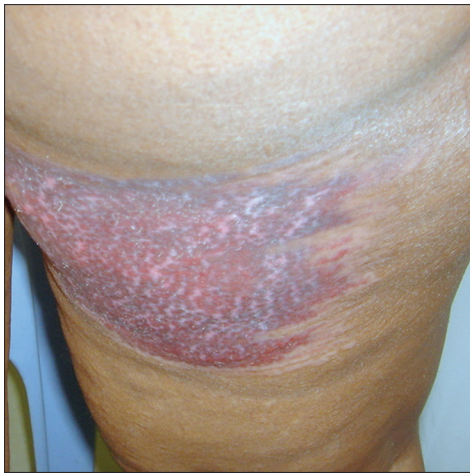

Figure 7: Healed donor area-thigh

excised areolar skin was sent to the pathology department for histopathological examination.

Histopathology

“Sections studied from the depigmented bits of both the samples show total loss of melanocytes at the dermoepidermal junction-consistent with Vitiligo.”

DISCUSSION

Vitiligo is a skin disorder that has more social than medical significance, particularly in dark-skinned people, since it is familial in the majority of cases. Due to retarded melanin formation, there is a loss of pigmentation. The social problems can be so severe that this particular patient was divorced due to this problem after the birth of a child even though she does not have any other lesions on the exposed portion of the body.^{6,7}

Vitiligo of isolated areolar region is uncommon, and in this case bilateral symmetrical involvement is extremely unusual.

In vitiligo, surgical therapies must be considered in localized lesions only after proper medical therapy and the lesion is stationary and no more progressive. This patient also used medical treatment, including homeo medicines, but without improvement. Surgical techniques are appropriate only for selected patients who have vitiligo that has been stable over the last 3 years. The various surgical modalities available for treatment of vitiligo are blister grafting, Pinch

grafting, autologous melanocyte transplantation⁸ and surgical tattooing.

In our patient, we performed deepithelialization of both areolae sparing the nipple, and not disturbing the ductal system and thin split skin grafting⁹ was done which yielded good result. The donor site of the graft also healed well with good pigmentation and Koebner phenomenon was not seen.¹⁰ We are presenting this case because of its rarity and highly satisfactory result, even though we have to follow the patient for a long-term result.

CONCLUSION

In this presentation, we reviewed the various aspects of vitiligo briefly and presented a case with isolated involvement of both areolae without any other lesions and successfully treated with excision of epidermal layers of affected areolae and replacement with thin split skin grafting which gave very good result when followed after 3 months.

REFERENCES

1. Pajvani U, Ahmad N, Wiley A, Levy RM, Kundu R, Mancini AJ, *et al.* The relationship between family medical history and childhood vitiligo. *J Am Acad Dermatol* 2006;55:238-44.
2. Le Poole IC, Luiten RM. Autoimmune etiology of generalized vitiligo. *Curr Dir Autoimmun* 2008;10:227-43.
3. Sravani PV, Babu NK, Gopal KV, Rao GR, Rao AR, Moorthy B, *et al.* Determination of oxidative stress in vitiligo by measuring superoxide dismutase and catalase levels in vitiliginous and non-vitiliginous skin. *Indian J Dermatol Venereol Leprol* 2009;75:268-71.
4. van den Wijngaard RM, Aten J, Scheepmaker A, Le Poole IC, Tigges AJ, Westerhof W, *et al.* Expression and modulation of apoptosis regulatory molecules in human melanocytes: Significance in vitiligo. *Br J Dermatol* 2000;143:573-81.
5. Ezzedine K, Diallo A, Léauté-Labrèze C, Mossalayi D, Gauthier Y, Bouchet S, *et al.* Multivariate analysis of factors associated with early-onset segmental and nonsegmental vitiligo: A prospective observational study of 213 patients. *Br J Dermatol* 2011;165:44-9.
6. Falabella R. Treatment of localized vitiligo by autologous minigrafting. *Arch Dermatol* 1988;124:1649-55.
7. Boersma BR, Westerhof W, Bos JD. Repigmentation in vitiligo vulgaris by autologous minigrafting: Results in nineteen patients. *J Am Acad Dermatol* 1995;33:990-5.
8. Lerner AB, Halaban R, Klaus SN, Moellmann GE. Transplantation of human melanocytes. *J Invest Dermatol* 1987;89:219-24.
9. Njoo MD, Westerhof W, Bos JD, Bossuyt PM. A systematic review of autologous transplantation methods in vitiligo. *Arch Dermatol* 1998;134:1543-9.
10. Hatchome N, Kato T, Tagami H. Therapeutic success of epidermal grafting in generalized vitiligo is limited by the Koebner phenomenon. *J Am Acad Dermatol* 1990;22:87-91.

How to cite this article: Kallam AR. Bilateral Symmetrical Areolar Vitiligo: A Case Report. *Int J Sci Stud* 2015;3(7):273-275.

Source of Support: Nil, **Conflict of Interest:** None declared.