Original Article

DOI: 10.17354/ijss/2015/442

Role of Oral Prophylaxis with the Use of Erich Arch Bars: A Randomized Controlled Trial

Parveen Akhter Lone[1], Mohan Singh[2], Varun Salgotra[3], Harpreet Singh Johar[4]

[1]Associate Professor, Department of Oral & Maxillofacial Surgery, Indira Gandhi Government Dental College, Jammu, Jammu and Kashmir, India, [2]Medical Superintendent Government Dental Hospital, Indira Gandhi Government Dental College, Jammu, Jammu and Kashmir, India, [3]Registrar, Department of Oral & Maxillofacial Surgery, Indira Gandhi Government Dental College, Jammu, Jammu and Kashmir, India, [4]House Surgeon, Department of Oral & Maxillofacial Surgery, Indira Gandhi Government Dental College, Jammu, Jammu and Kashmir, India

Abstract

Introduction: In the management of maxillofacial fractures intermaxillary fixation (IMF) is the basic and fundamental principle. Various commonly used techniques for IMF include arch bars and various dental wirings. The aim is to report gingival inflammatory changes after applying arch bars and reversal of inflammatory changes after removal of arch bars.

Materials and Methods: Patients were divided into two groups, Group A and Group B depending on the treatment plan indicated. In Group A, 50 patients were treated with closed reduction and IMF was kept for 4-6 weeks. In Group B, 50 patients treated with open reduction and internal fixation on Champy's line of osteosynthesis under general anesthesia and the arch bar was kept for 10 days. Half of the subjects of each group received the oral prophylaxis at the time of arch bar removal (Group A1 and Group B1). The patients were examined for injury to gums and cheek, avulsion of teeth and wire injuries to the operator and assistant including needle stick injuries, perforation of gloves, fetid odor, coated tongue, iatrogenic injury to adjacent teeth, orthodontic movement of teeth, ischemic necrosis of the periodontium and mucosa, oral hygiene index simplified, Papillary bleeding index, and Russel periodontal index.

Results: Orthodontic tooth movement, iatrogenic injury to adjacent teeth and ischemic necrosis of the periodontium and mucosa was reported with no statistical significant difference between groups and subgroups. There was a statistical significant difference in oral hygiene index-simplified, papillary bleeding index and Russel periodontal index between the patients in Group A1 and A2 and also between Group B1 and B2.

Conclusion: As per the observations of this study all the patients with arch bars suffer from gingival and periodontal injuries, so it is recommended that oral prophylaxis after removal of arch bar should always be done for early recovery of gingival and periodontal recovery.

Key words: Erich arch bar, Gingival inflammation, Maxillofacial injuries, Oral prophylaxis

INTRODUCTION

The principles of management of fractures of hard tissues are reduction, fixation, and immobilization of the bony fragments. Mandibular fractures can be treated by closed reduction (intermaxillary fixation [IMF]) and open reduction (osteosynthesis with or without IMF). IMF can be achieved by eyelets, arch bars, and glimmers wiring, etc. Arch bars have been used widely for management of maxillomandibular injuries since World War 1.[1,2] Carl[3] in Germany and Gilmer[4] in the United States used ordinary round bar which was ligated to teeth with bass ligation wires. Blair and Ivy[5] modified and flattened one side about 2 mm in width for better adaptation to dental arches for greater stability, little has changed since the introduction of arch bars. Application of arch bars with circumdental wiring is the most preferred method for IMF. Wire is passed around the teeth for fixation of arch bars. This causes gingival and periodontal injuries, difficulty in maintaining the oral hygiene, threat to percutaneous injury to operator or assistant by wire ends, mucosal ulcerations orthodontic movement of anterior teeth if mot adapted properly, high chances of serological transfer of pathogens like hepatitis

Access this article online

IJSS

www.ijss-sn.com

Month of Submission : 08-2015
Month of Peer Review : 09-2015
Month of Acceptance : 10-2015
Month of Publishing : 10-2015

Corresponding Author: Dr. Parveen Akhter Lone, Department of Oral & Maxillofacial Surgery, Indira Gandhi Government Dental College, Amphalla, Jammu, Jammu and Kashmir, India. Phone: +91-9419203131. E-mail: parveen.lone@yahoo.com

B virus, hepatitis C virus, and HIV.[6,7] The introduction of bone plating has reduced the prolonged periods of IMF. However, there is need of temporary IMF intraoperatively to assist reduction of fracture with teeth in occlusion and post-operatively to correct minor occlusal discrepancies. So, we decided to conduct a study at our tertiary care institute to note the incidences of iatrogenic injuries and complications/problem associated with the Erich arch bar and to evaluate the need of oral prophylaxis after the arch bar removal.

MATERIALS AND METHODS

The study group consisted of 100 patients of trauma with history of RTA, fall, violence, etc., having fracture mandible and dentoalveolar region who reported to the Department of Oral and Maxillofacial Surgery, Indira Gandhi Government Dental College, Jammu and required IMF as part of treatment plan. After taking informed consent, clinical and radiographic examination of the patients was done and treatment plan formulated. Patients were divided into two groups, Group A and Group B depending on the treatment plan indicated. In Group A, 50 patients were treated with closed reduction and IMF was kept for 4-6 weeks. In Group B, 50 patients treated with Open Reduction and Internal Fixation on Champy's line of osteosynthesis under general anesthesia, and arch bar was kept for 10 days. Randomly, half of the subjects of both the groups received the oral prophylaxis at the time of arch bar removal (Group A1 and Group B1) while in the other half no oral prophylaxis was advised (Group A2 and Group B2). The Erich Arch bars were placed using circumdental wiring and removed by a single team of operator and assistant who were blinded of the groups (Figure 1). The patients were examined for injury to gums and cheek, avulsion of teeth during arch bar placement and wire injuries to the operator and assistant including needle stick injuries, perforation of gloves at the time of arch bar placement. On the day of arch bar removal fetid odor, coated tongue, iatrogenic injury to adjacent teeth, orthodontic movement of teeth, ischemic necrosis of the periodontium and mucosa, wire injuries to the operator and assistant were noted (Figures 2 and 3). Oral hygiene index simplified (OHI-S),[8] papillary bleeding index[9] and Russel periodontal index[10,11] was evaluated on 15th day, post arch bar removal (Figure 4).

RESULTS

Of the 100 patients treated 82 were males and road traffic accidents was the most common cause of fractures. The mean age of the patients was 29.2 years, and the most common fracture site was parasymphysis followed by angle and condyle. There was no statistical significant difference in both the groups and subgroups based on

Figure 1: Erich arch bar placement

Figure 2: Gingival laceration after arch bar removal

Figure 3: Periodontal inflammation after arch bar removal

Figure 4: 15th day after arch bar removal

age, gender, etiology or site of the fracture. Almost all the patients in both group and subgroups had injuries to gums and cheeks during the arch bar placement (Table 1 and Graph 1). One patient in Group A1 had an avulsion of teeth which was implanted back into the socket and after 3 months Root canal treatment was done. The needle stick injury to operator and/or assistant was reported in 2 patients in Group A1, 4 patients in Group A2, 2 patients in Group B1 and 3 patients in Group B2 (Table 2 and Graph 2). The glove perforation of operator and/or assistant was reported in the remaining patients during arch bar placement. No needle stick injury was reported during arch bar removal. 100% of the patients in Group A1 and A2, and 92% in Group B1, and 96% in Group B2 reported coated tongue. The halitosis was reported 80% and 82% in Group A1 and A2, respectively, and 72% and 64% in Group B1 and B2, respectively (Table 3 and Graphs 3-5). Orthodontic tooth movement, iatrogenic injury to adjacent teeth and Ischemic necrosis of the periodontium and mucosa was also reported with no statistical significant difference between groups and subgroups. There was a statistical significant difference in OHI-S, papillary bleeding index and Russel periodontal index between the patients in Group A1 and A2 and also between Group B1 and B2. The patients whose oral prophylaxis were done at the time of arch bar removal reported better OHI-S, papillary bleeding index, and periodontal index in both Group A and Group B.

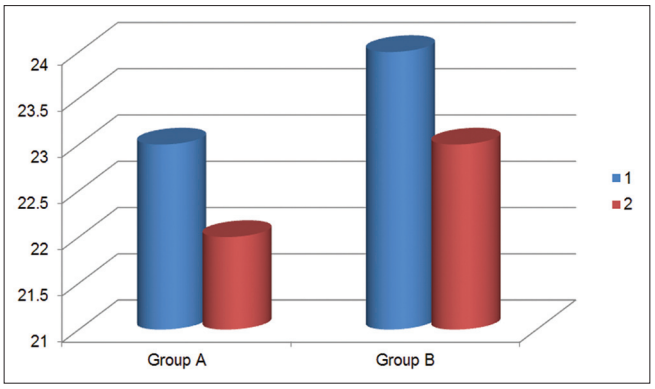

Graph 1: Injury to gums and cheek

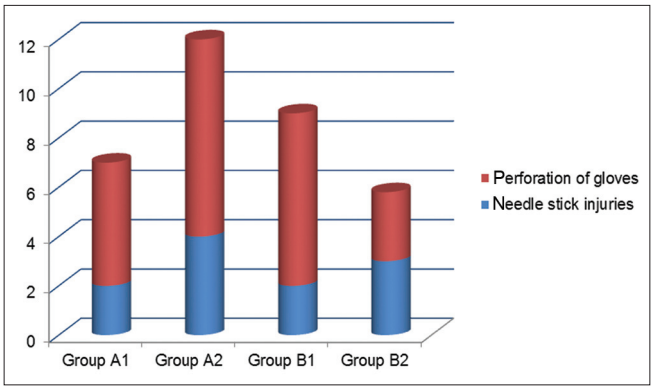

Graph 2: Needle stick injury to operator and/or operator, perforation of gloves

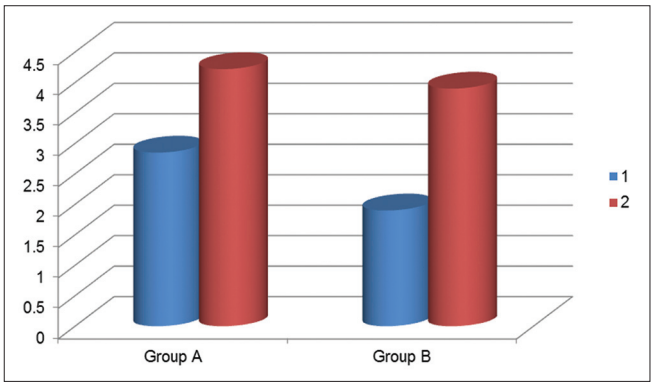

Graph 3: Oral hygiene index - simplified

Table 1: Arch bar placement

Injury to gums and cheeks	Avulsion of teeth	Wire injuries to the operator and assistant, perforation of gloves
Group A		
1		
23	1	7
2		
22	0	12
Group B		
1		
24	0	9
2		
23	0	8

Table 2: Day of arch bar removal

Fetid odor	Coated tongue	Iatrogenic injury to adjacent teeth	Orthodontic movement of teeth	Ischemic necrosis of the periodontium and mucosa	Wire injuries, perforation of gloves
Group A					
1					
20	25	3	3	2	3
2					
21	25	1	2	3	0
Group B					
1					
18	23	0	1	1	1
2					
16	24	1	0	3	1

Table 3: 15 days post arch bar removal

Oral hygiene - OHI-S	Gingival bleeding - papillary bleeding index	Gingival inflammation and periodontal disease - periodontal index (Russel)
Group A		
1		
71.25/25=2.85	48/25=1.92	78/25=3.12
2		
105.5/25=4.22	65/25=2.6	113/25=4.52
Group B		
1		
47.5/25=1.9	27/25=1.08	46/25=1.84
2		
97.5/25=3.9	45/25=1.8	81/25=3.24

OHI-S: Oral hygiene index simplified

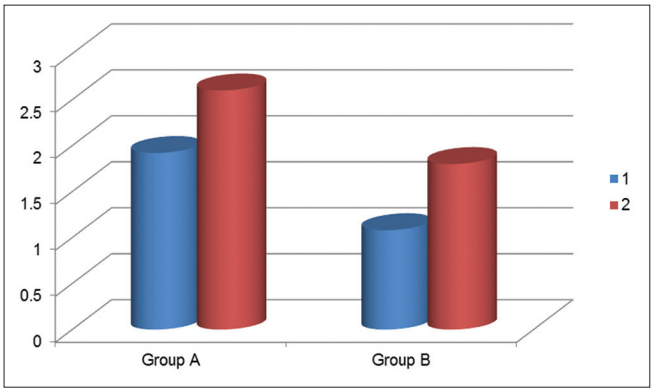

Graph 4: Papillary bleeding index

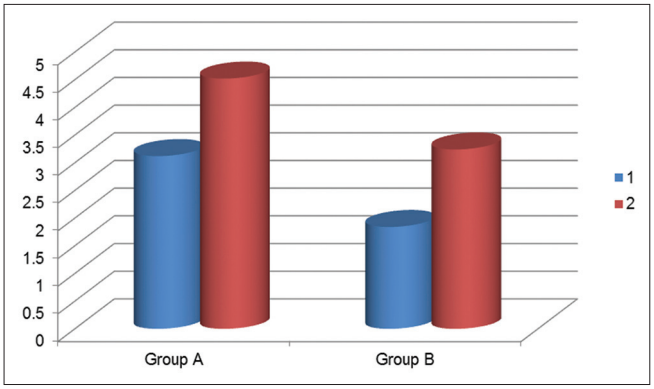

Graph 5: Russel periodontal index

DISCUSSION

The management of maxillofacial injuries remains one of the most demanding and rewarding aspect of surgery because the patients with maxillofacial injuries not only suffer from physical agony but slight disfigurement can become an emotional distress for his whole life.[1] The main goals in successfully treating mandibular fractures include reduction, fixation and immobilization and achieving proper dental occlusion. It is also important to use techniques that reduce the percutaneous transmission of blood-borne diseases, maintain proper oral hygiene in order to reduce gingival and periodontal diseases, prevent injuries to adjacent and supporting structures, reduce operating time, and hospital costs.[2,12,13] The treatment of maxillofacial fractures involve different methods from bandages and splinting to methods of open reduction and internal fixation, requiring control of the dental occlusion with the help of IMF with the traditional methods.[2] Various methods have been used for IMF in the management of mandibular fractures. The most common technique is to use eyelets or arch bars. The Erich arch bars have been used mainstay in management of maxilla mandibular fractures since World War 1.[1]

The most common and trusted method for mandibular fracture is the application of Erich arch bar for IMF with the help of circumdental wiring, yet circumdental wiring has its own shortcomings. Nevertheless, it has following disadvantages: wires have to pass below the gingival margin to guarantee stability, chances of gingival injury are more and compromises the health of periodontium, rounded wire edges collects food debris and causes gingival inflammation and difficulty in maintaining oral hygiene result in fetid breath.[1]

Most of our patient had injuries to gums and cheeks during the arch bar placement. During arch bar placement, optimum tension, and stable placement is a difficult task, breakage of wires during and after placement of wire is not uncommon which encounter instability of appliances. Passing of dental wires in patient with reduced mouth opening was also difficult. While passing of the wires and manipulating the fracture fragments, there was incidences of accidental pricking of the wire end to the hands of the operator or the assistant, and perforation of gloves. The most common site for perforation of gloves is the non-dominant hand. The similar finding were also reported in other studies.[14,15] The rounded wire edges collected food debris and caused gingival inflammation and there was difficulty in maintaining oral hygiene which result in fetid breath and coated tongue. Few patients also reported the orthodontic tooth movement. The ill-fitting of Erich arch bar and over tightening of wires caused orthodontic movement of anterior teeth. Ischemic necrosis of the periodontium and mucosa and injury to adjacent teeth was possibly caused by the tension of the wire and the pressure inserted on the gums. There was also an avulsion of tooth because of application of inadvertently excessive force on the mobile tooth. Recent studies have reported needle-stick injuries, the high plaque index, periodontal damage, and movement of the teeth in lateral and extrusive direction.[2,16-20]

In our study, the patients in who oral prophylaxis was advised after the arch bar placement reported better oral

hygiene. The patients reported better scores of OHI-S, papillary bleeding index and Russel periodontal index in both Group A and Group B in which oral prophylaxis have been performed. No previous study has evaluated the oral hygiene and periodontal health indices with Erich arch bar placement and the role of use of oral prophylaxis in improving the oral hygiene of the patient. During the period of IMF, there was difficulty in maintaining the oral hygiene, which resulted in coated tongue, fetid odor, calculus and debris deposition which has detrimental effect on the periodontium. The oral prophylaxis at the time arch bar removal of seems to reverse or reduce these effects. However, we did not evaluate the pre-operative OHI-S, periodontal index or papillary bleeding index, the damage to periodontium/degradation of oral health with the placement of Erich arch bar could not be assessed.

CONCLUSION

As per the observations of this study all the patients with arch bars suffer from gingival and periodontal injuries, so it is recommended that oral prophylaxis after removal of arch bar should always be done for early recovery of gingival and periodontal recovery. However, further studies are required in which pre-operative evaluation and their comparison with final periodontal health can be made to correctly assess the periodontal damage with the arch bar placement.

REFERENCES

1. Chandan S, Ramanojam S. Comparative evaluation of the resin bonded arch bar versus conventional Erich arch bar for intermaxillary fixation. J Maxillofac Oral Surg 2010;9:231-5.
2. Nandini GD, Balakrishna R, Rao J. Self-tapping screws v/s. erich arch bar for inter maxillary fixation: A comparative clinical study in the treatment of mandibular fractures. J Maxillofac Oral Surg 2011;10:127-31.
3. Carl S. Deutsch monatsh. Zahnheilkd 1889;7:381.
4. Gilmer TL. Lecturers in oral surgery. Chicago: ???; 1901.
5. Blaire VP, Ivy RH. Essential of Oral Surgery. 4th ed. St. Louis: Mosby Co.; 1951. p. 171.
6. Gooch BF, Siew C, Cleveland JL, Gruninger SE, Lockwood SA, Joy ED. Occupational blood exposure and HIV infection among oral and maxillofacial surgeons. Oral Surg Oral Med Oral Pathol Oral Radiol Endod 1998;85:128-34.
7. Yamada T, Sumi Y, Okazaki Y, Ueda M. A new inter-maxillary fixation method using adhesive cast splints for avoiding skin puncture. Aust Dent J 1998;43:167-9.
8. Greene JC, Vermillion JR. The simplified oral hygiene index. J Am Dent Assoc 1964;68:7-13.
9. Saxer UP, Miihlemann HR. Motivation und aufklh lrung. Schweiz Monatsschr Zahnheilkd 1975;85:905-19.
10. Russell AL. A system of classification and scoring for prevalence surveys of periodontal disease. J Dent Res 1956;35:350-9.
11. Russell AL. The periodontal index. J Pedodontol 1967;38:586-91.
12. Vartanian AJ, Alvi A. Bone-screw mandible fixation: An intraoperative alternative to arch bars. Otolaryngol Head Neck Surg 2000;123:718-21.
13. Gordon KF, Reed JM, Anand VK. Results of intraoral cortical bone screw fixation technique for mandibular fractures. Otolaryngol Head Neck Surg 1995;113:248-52.
14. Gaujac C, Ceccheti MM, Yonezaki F, Garcia IR Jr, Peres MP. Comparative analysis of 2 techniques of double-gloving protection during arch bar placement for inter-maxillary fixation. J Oral Maxillofac Surg 2007;65:1922-5.
15. Pieper SP, Schimmele SR, Johnson JA, Harper JL. A prospective study of the efficacy of various gloving techniques in the application of Erich arch bars. J Oral Maxillofac Surg 1995;53:1174-6.
16. Falci SG, Douglas-de-Oliveira DW, Stella PE, Santos CR. Is the Erich arch bar the best intermaxillary fixation method in maxillofacial fractures? A systematic review. Med Oral Patol Oral Cir Bucal 2015;20:e494-9.
17. Ghazali N, Benlidayi ME, Abizadeh N, Bentley RP. Leonard buttons: A reliable method of intraoperative intermaxillary fixation in bilateral mandibular fractures. J Oral Maxillofac Surg 2012;70:1131-8.
18. Rai A, Datarkar A, Borle RM. Are maxillomandibular fixation screws a better option than Erich arch bars in achieving maxillomandibular fixation? A randomized clinical study. J Oral Maxillofac Surg 2011;69:3015-8.
19. Ayoub AF, Rowson J. Comparative assessment of two methods used for interdental immobilization. J Craniomaxillofac Surg 2003;31:159-61.
20. Park KN, Oh SM, Lee CY, Kim JY, Yang BE. Design and application of hybrid maxillomandibular fixation for facial bone fractures. J Craniofac Surg 2013;24:1801-5.

How to cite this article: Lone PA, Singh M, Salgotra V, Johar HS. Role of Oral Prophylaxis with the Use of Erich Arch Bars: A Randomized Controlled Trial. Int J Sci Stud 2015;3(7):18-22.

Source of Support: Nil, **Conflict of Interest:** None declared.