Original Article

DOI: 10.17354/ijss/2015/443

# Role of Penile Color Doppler in the Evaluation of Erectile Dysfunction

**Suresh A[1], Abishek Balachandran[2], N Indira[3], H V Ramprakash[3]**

[1]Associate Professor, Department of Radiology, Vydehi Institute of Medical Sciences and Research Centre, Bengaluru, Karnataka, India, [2]Assistant Professor, Department of Radiology, Vydehi Institute of Medical Sciences and Research Centre, Bengaluru, Karnataka, India, [3]Professor, Department of Radiology, Vydehi Institute of Medical Sciences and Research Centre, Bengaluru, Karnataka, India

## Abstract

**Background:** Color duplex Doppler is a non-invasive tool of evaluation of the vascular mechanism of erectile dysfunction (ED). It can be used to determine the integrity of the vascular mechanism and to differentiate between arterial and venous insufficiency.

**Materials and Methods:** An observational study was conducted at the Department of Radiology Vydehi Medical College and Research Center from June 05, 2013 to September 02, 2015. A total of 33 consecutive patients presenting with symptoms of ED and undergoing penile color Doppler evaluation with the injection of 2 ml of paperavine were included in this prospective study.

**Results:** The baseline diameter of the vessels at pre-injection was <1 mm in 46% of the patients, the majority of the patients 52% showed a baseline diameter of 1-1.5 mm. Post-injection of paperavine the peak increase in the diameter of the vessels in 43% of the patients showed an increase of <1.5 mm. However, 52% of the patients showed an increase between 1.5 and 2.5 mm. The average peak diameter was 1.71 mm and the $P < 0.001$, which was significant. 46% patients with low peak systolic velocity (PSV) values (<25 cm/s) in the cavernosal artery were considered to have arterial insufficiency, 9% (3) of the patients had an end-diastolic velocity of >5 cm/s had normal arterial function, that is, normal PSV. Adequate arterial inflow, a short duration erection, with the persistent antegrade flow of >5 cm/s throughout all phases suggestive of venous leak. 42% of the patients studied where found to be functional where no cause could be ascertained.

**Conclusion:** When arterial insufficiency is found, patients can be considered to have systemic arteriovascular disease. On the other hand, veno-occlusive dysfunction is not correlated with systemic arterial vascular problems. In conclusion, investigating of ED by color duplex Doppler is not time-consuming and may help establish an accurate diagnosis of vascular causes of impotence.

**Key words:** Color, Doppler, Erectile dysfunction, Papaverine, Ultrasonography

## INTRODUCTION

Erectile dysfunction (ED) is a common health problem which affects men of various age groups; it affects both young and middle-aged men. Color duplex Doppler is a non-invasive tool of evaluation of the vascular mechanism of ED which can result from psychogenic, endocrinologic, neurogenic, pharmacologic, and vasogenic causes. Color duplex Doppler can be used to determine the integrity of the vascular mechanism and to differentiate between arterial and venous insufficiency.

Access this article online

IJSS

www.ijss-sn.com

Month of Submission : 08-2015
Month of Peer Review : 09-2015
Month of Acceptance : 10-2015
Month of Publishing : 10-2015

Penile erection is a complex phenomenon, which includes coordinated interaction of the arterial, venous sinusoidal and nervous systems. The penile erectile tissue, specifically the cavernous smooth musculature and the smooth muscles of the arteriolar and arterial walls, plays a key role in the erectile process.[1] A defect or incoordination in any of these systems may result in ED. ED is defined as the consistent inability to generate or maintain an erection of sufficient rigidity for sexual intercourse. Around 10% of men aged 40-70 years have complete, 17.1% have mild, and 25.2% have moderate amount of ED.[2]

ED is closely linked to the general state of both physical and psychological wellness. Among the major risk

**Corresponding Author:** Dr. Abishek Balachandran, No. 16 Nidhin Nest, Ravi Prakash Nagar, Konena Agrahara Hal, Bengaluru - 560 017, Karnataka, India. Phone: +91-9940162227. E-mail: drabishek@gmail.com

factors are heart disease, arterial hypertension, diabetes, hyperlipidemia, as well as sedentary lifestyle, smoking and alcohol abuse.[3] Sexual dysfunction is common in patients with alcohol dependence. Heavy drinking proportionately increases the risk.[4]

The normal chain of events leading to penile erection begins with psychological factors that lead to transmission of parasympathetic impulses to the penis. The walls of the sinusoids and arterioles of the corpora cavernosa relax, which leads to an increased inflow of blood via the cavernosal artery. With filling of the sinusoidal spaces, corporal veno-occlusive mechanism works. The emissary veins exiting the corpora are passively compressed against the fibrous tunica albuginea following which rigid penile erection is achieved and maintained. Detumescence occurs due to contraction of trabecular smooth muscle in the corpora cavernosa after neurological stimulation.[2,3]

ED is caused by the interruption in the chain of events including psychogenic, neurogenic, arteriogenic, and venogenic causes. Often more than one cause is combined. Establishing a specific cause is important particularly in young men because of the frequency of correctable vascular abnormalities. Pure arteriogenic impotence accounts for about 30% of cases, and isolated venogenic impotence is found in about 15%. Often ED is caused by a combination of arteriogenic and venogenic causes. Occasionally, organic impotence is caused by morphological abnormalities of the penis such as peyronies disease (PD).[5]

Organic etiologies include vascular, neurogenic, PD, medication side effects and endocrinologic sources. Vascular causes are commonly due to focal arterial occlusive disease.[6]

The cavernosal arteries are the primary source of blood flow to the corpora cavernosa; the dorsal arteries supply blood to the skin and glans of the penis. The cavernosal arteries are connected by multiple anastomotic channels to the dorsal arteries. Arteriography with selective internal iliac angiography is considered the gold standard in the evaluation of arteriogenic impotence. However, this technique is invasive and therefore not suitable as a screening examination.[5] The use of Doppler ultrasound in the assessment of the penile vasculature was first described in 1985.[7]

Penile color Doppler sonography is a valuable method for evaluating ED and it has become the first line diagnostic tool in diagnosing vasculogenic impotence.[8] This method requires intracorporeal injection of a vasoactive substance such as papaverine hydrochloride or prostaglandin E1, however, there are some concerns about the safety of this method due to the intracorporeal pharmacological injection, which may cause priapism as a complication, histological changes and functional impairment resulting in penile fibrosis.[9]

In 1982 during a vascular reconstructive procedure, Ronald Virag noted that an infusion of papaverine into the hypogastric artery produced an erection. In 1983, a dramatic demonstration of the efficacy of penile self-injection was offered by Brindley, who injected himself.[10,11] Virag *et al.* showed that precise Doppler sampling and blood velocity measurements of the deep cavernosal arteries could be performed before and after intracavernosal injection of vasodilating agents and 75% increase in vessel diameter is good indication of normal arterial flow into the cavernosal artery.[5,12]

Commonly many investigators use 2 ml solution of 60 mg of papavarine into either the right or left corpus cavernosum.[13,14] The investigators concluded that a peak systolic velocity (PSV) of >25 cm/s was normal.[5,15,16] The parameters that indicate the presence of arterial disease are a subnormal response to vasoactive agents, a diameter of <60% increase in the cavernosal artery, and a PSV of the cavernosal arteries <25 cm/s. In the presence of normal arterial function, Doppler findings suggestive of an abnormal venous leak are persistent end-diastolic velocity (EDV) of the cavernosal artery >5 cm/s and demonstration of flow in the deep dorsal vein. The development of Diastolic flow reversal after an injection has been found to be a reliable indicator of venous competence.[5]

## MATERIALS AND METHODS

An observational study was conducted at the Department of Radiology, Vydehi medical college and research center from July 05, 2013 to September 02, 2015. Informed consent was obtained from all patients prior to participation. A total of 33 consecutive patients presenting with symptoms of ED and undergoing penile color Doppler evaluation with the injection of 2 ml of paperavine were included in this prospective study.

### Exclusion Criteria

Patients with heart diseases, known case of PD and patients with history of drug allergy were excluded from the study.

A gray scale ultrasound was performed in transverse and the longitudinal sections to see any plaque or any other abnormality. A brief history of the patient was taken with adequate privacy and in a quiet environment to allay patient anxiety as much as possible. The study was performed

by one of two experienced radiologists. All studies were performed on a Philips HD7 ultrasound machine with L12-3 broadband linear array high-frequency transducer (12-13 MHz frequency range) was used. Doppler was performed with the patient supine and the penis in the anatomical position, lying on the anterior abdominal wall. The following protocol for penile Doppler US was followed. Factors such as accurate gate placement, sampling and angle correction were optimized for consistent and reproducible results. Cavernosal artery spectral waveform was measured at the base of the penis as angle correction is optimal, and the velocities are highest here.

Intracavernosal injection of 2 ml of paperavine with a 28 G needle under ultrasound guidance and aseptic precautions close to the base of the penis was done and massaged in. The peak systolic and EDV measurements were obtained in the right cavernosal artery at 5 min intervals for a total of 30 min. The systolic velocity of <25 cm/s was used as the threshold for arterial insufficiency. An EDV of >5 cm/s was used to predict venous incompetence (Figures 1,2). Erection was graded at a 10 min as follows: 1 - no erection; 2 - slight tumescence; 3 - full volume without rigidity; 4 - incomplete rigidity but sufficient for sexual intercourse; and 5 - full erection with unbending rigidity.[10,17]

## RESULT AND DISCUSSION

An observational study was carried out at the Department of Radiology in Vydehi Institute of Medical Sciences and Research Centre, Bengaluru, Karnataka, India. The statistical analysis was carried out using the IBM SPSS version 22 (SPSS Inc., Armonk, NY, USA).

In this study, the 23 patients (69.7%) were referred for penile Doppler investigation from the Department of Urology - U, 7 (21.2%) patients from Department of Psychiatry – Pand, 3 (9.1%) patients from the Department of General Medicine - M respectively (Graph 1). The age distribution of the patients studied was from 18 to 58 years, majority of the patients studied were in the 3rd decade (Graph 2). 23 (70%) patients out of a total of 33 patients were married (Graph 3). Age distribution of patients studied (Table 1).

Personal habits of 33 patients studied showed a significant 73% of the patients were smokers (Graph 4), a study by Austoni *et al.* showed a dose - and duration-response relationship between smoking and erectile dysfunction.[18] Another population-based cross-sectional study of 1580 participants study by Chew *et al.* compared non-smokers, former smokers and smoker and found smokers to have significantly higher odds of ED.[19] A study by Wu *et al.* of 2686 Chinese men revealed smokers who smoked ≥20 cigarettes daily had a significantly increased risk of ED than never smokers the study also revealed heavy smoking might cause ED and that the duration of the habit increases the risk of ED.[20] Furthermore, our study highlights the potential interaction of smoking with ED.

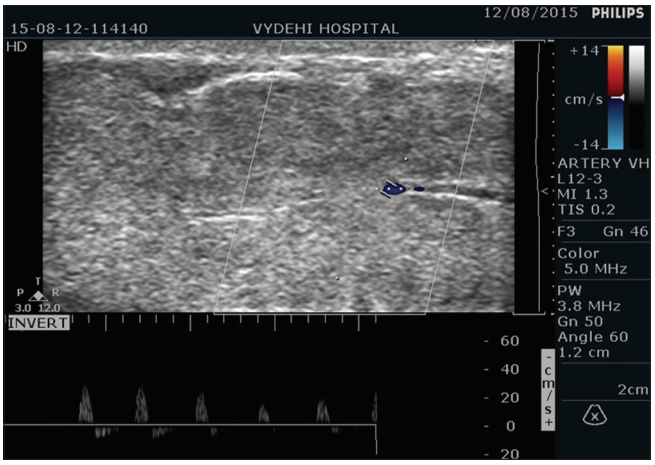


**Figure 1: Normal peak systolic velocity of >35 cm/s with end diastolic flow reversal, suggesting normal study**

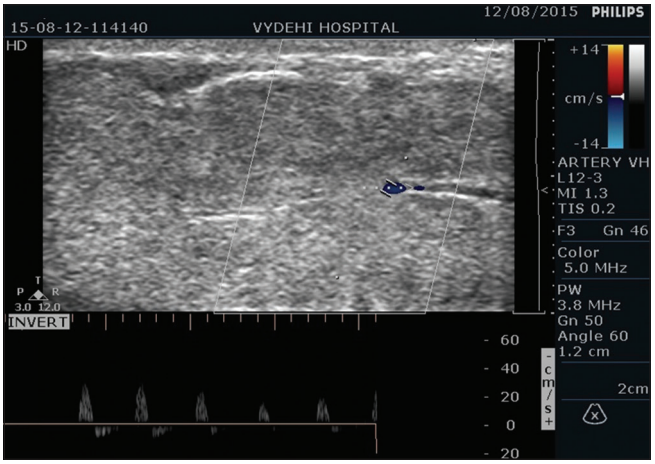


**Figure 2: Normal peak systolic velocity of >35 cm/s with end diastolic flow reversal, suggesting normal study**

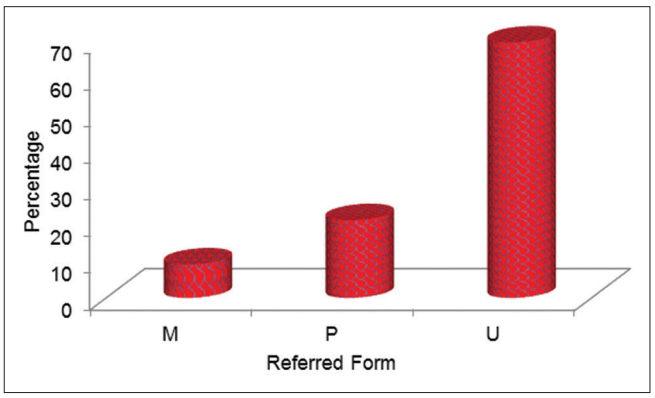


**Graph 1: Patients referred from various dept.'s**

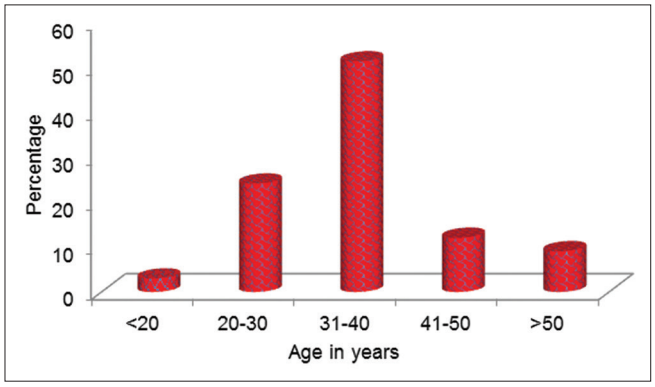


**Graph 2: Age distribution of patients studied**

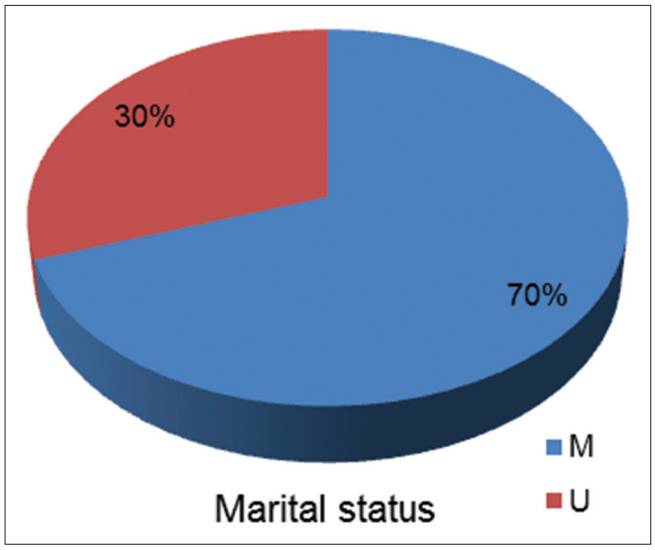


**Graph 3: Marital status of patients studied**

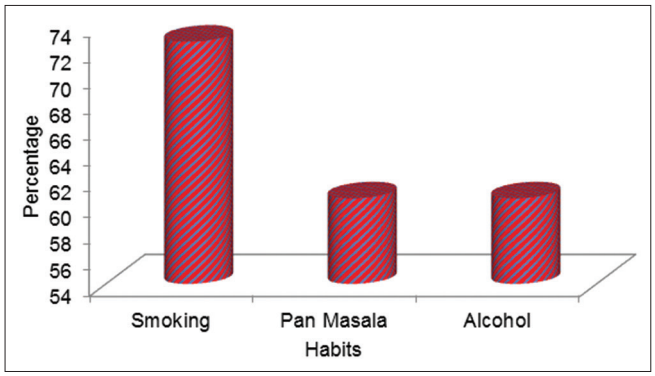


**Graph 4: Personal habits of patients studied**

## Table 1: Age distribution of patients studied

| Age in years | Number of patients | Percentage |
|---|---|---|
| <20 | 1 | 3.0 |
| 20-30 | 8 | 24.2 |
| 31-40 | 17 | 51.5 |
| 41-50 | 4 | 12.1 |
| >50 | 3 | 9.1 |
| Total | 33 | 100.0 |

Mean±SD: 36.12±8.41, SD: Standard deviation

A significant 61% of patients were found to have a history of alcohol intake. A study by Dachille *et al.* demonstrated a significant relationship between alcohol consumption and ED (Table 2).

60% of the patients had a history of consumption of pan masala, a recent animal experimental study by Nigam and Venkatakrishna-Bhatt on the effect of blended tobacco products on the reproductive system of mice showed a significant adverse effects on the reproductive system.[21] There are no studies on humans correlating consumption of pan masala with ED. In the present study, we found majority of patients who were addicted to pan masala developed ED in due course of time.

Only 6 (19%) patients had a history of hypertension, none of the patients studied had a history of diabetes mellitus. In the second Princeton consensus, Jackson *et al.* concluded that a man with ED and no cardiac symptoms is a patient with cardiac (or vascular) disease until proven otherwise.[22]

The base-line diameter of the vessels at 0 min post-injection was <1 mm in 46% of the patients studied, the majority of the patients 52% showed a baseline diameter of 1-1.5 mm. One patient had a baseline diameter of more than 1.5 mm. Post-injection of paperavine the peak increase in the diameter of the vessels in 43% of the patients showed an increase of <1.5 mm. However, 52% of the patients showed an increase between 1.5 and 2.5 mm. Two patients showed an increase more than 2.5 mm (Table 3). The average peak diameter was 1.71 mm and the $P < 0.001$which was significant (Table 4). A study by

## Table 2: Relationship between alcohol consumption and ED

| | Number of patients (*n*=33) | Percentage |
|---|---|---|
| Smoking | 24 | 72.7 |
| Pan masala | 20 | 60.6 |
| Alcohol | 20 | 60.6 |

## Table 3: The base-line diameter of the vessels immediately after injection of paperavine

| | Number of patients (*n*=33) | Percentage |
|---|---|---|
| Base line diameter of vessel (mm) | | |
| <1 | 15 | 45.5 |
| 1-1.5 | 17 | 51.5 |
| >1.5 | 1 | 3.0 |
| Increase in diameter after injection (mm) | | |
| <1.5 | 14 | 42.4 |
| 1.5-2.5 | 17 | 51.5 |
| >2.5 | 2 | 6.1 |

Base line diameter of vessel (mm)/increase in diameter after injection (mm)

Acharya and Vasu showed the post-injection mean diameter was 1.0 mm,[23] however, our study found a mean increase of 1.7 mm (Graph 4).

In our study, the PSV was graded as Grade I: <25 cm/s, Grade II: 25-30 cm/s, and Grade III: >30 cm/s. The EDV was graded as <5.0 cm/s and above >5.0 cm/s (Table 5). In our study, we used the PSV as the reference standard to diagnose arteriogenic impotence. In our study, 46% patients with low PSV values (<25 cm/s) in the cavernosal artery were considered to have arterial insufficiency (Figures 3-10). We found that reversal of flow in is a clue to the diagnosis of arteriogenic impotence. However, in case of patients with PSV values of more than 30 cm/s, this finding contributed little to the diagnosis of arteriogenic impotence (Table 6).

In men with veno-occlusive disorder, the usual criterion for diagnosing veno-occlusive dysfunction has been an EDV >5 cm/s.[16,23] Again, various threshold EDV values have been suggested between 5 and 7 cm/s as diagnostic of venous incompetence.[24-26] However, such threshold values for EDV can be misleading if arterial insufficiency is present. This observation was not confirmed in all studies, and there is a poor correlation of color Doppler ultrasound findings and veno-occlusive dysfunction when diagnosis was made. In our study, 9% (3) of the patients had an EDV of >5 cm/s had a normal arterial function, that is, normal PSV (Graph 9). Adequate arterial inflow, a short duration erection, with the persistent antegrade flow of >5

**Table 4: Peak increase in the diameter of the vessels post-injection of paperavine**

| Variables | Baseline | After injection | Difference | *t* value | *P* value |
|---|---|---|---|---|---|
| Diameter of vessel (mm) | 1.05±0.33 | 1.71±0.55 | 0.65 | 11.033 | <0.001** |

Base line diameter of vessel (mm)/increase in diameter after injection (mm), ** $P \leq 0.01$

**Table 5: Grading of PSV**

| | Number of patients (*n*=33) | Percentage |
|---|---|---|
| Max PSV cm/s | | |
| <25 | 15 | 45.5 |
| 25-30 | 1 | 3.1 |
| >30 | 17 | 51.5 |
| Max EDV cm/s | | |
| <5.0 | 30 | 90.9 |
| >5.0 | 3 | 9.1 |

Max PSV cm/s, Max EDV cm/s, PSV: Peak systolic velocity, EDV: End-diastolic velocity

**Table 6: Total cases of arterial insufficiency and venous insufficiency**

| Insufficiency | Number of patients (*n*=33) | Percentage |
|---|---|---|
| Arterial insufficiency | 16 | 48.5 |
| Venous insufficiency | 2 | 6.1 |

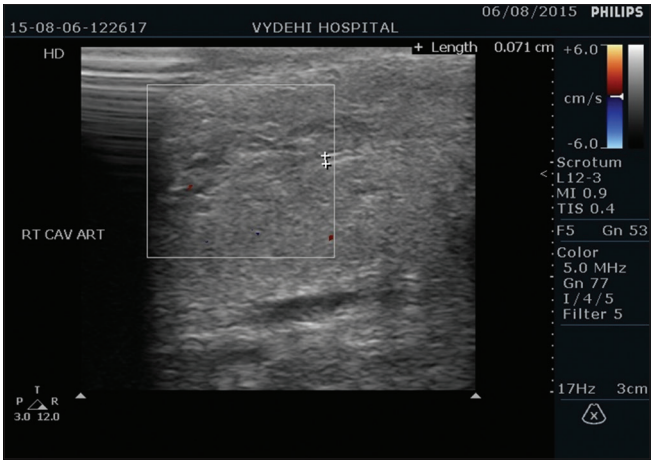


**Figure 3: Pre-injection calipers showing the baseline diameter of vessels**

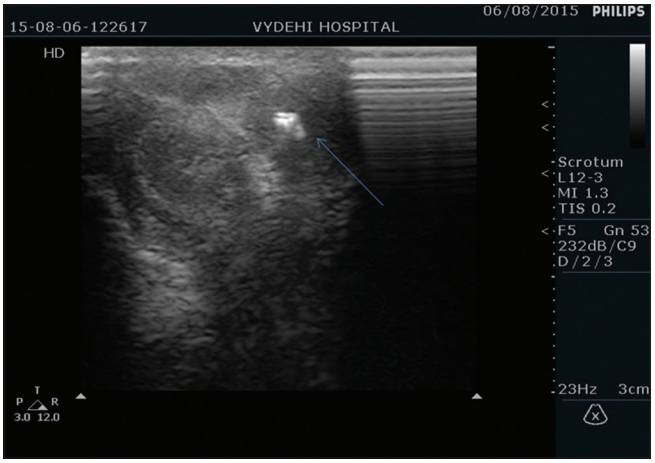


**Figure 4: Arrow showing the intracaversonal injection of papavarine**

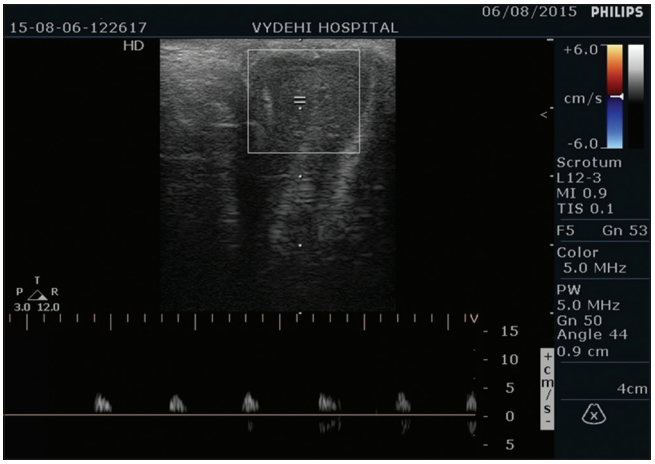


**Figure 5: Doppler evaluation in demumiscent srtage showing monophasic waves with low peak systolic velocity of <5 cm/s.**

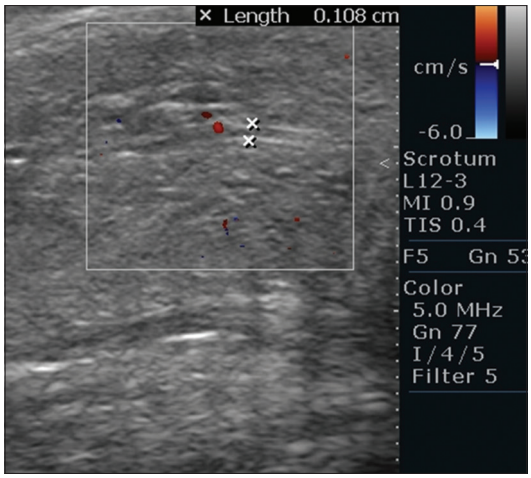


**Figure 6: Post-intracavernosal injection of papaverine, calipers revealing increase in diameter of intracavernosal vessel**

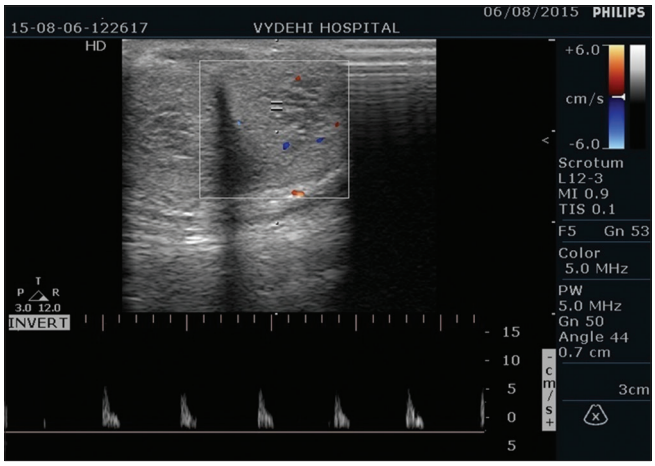


**Figure 7: Post-injection showing monophasic waves with low peak systolic velocity of 5 cm/s with minimal diastolic flow**

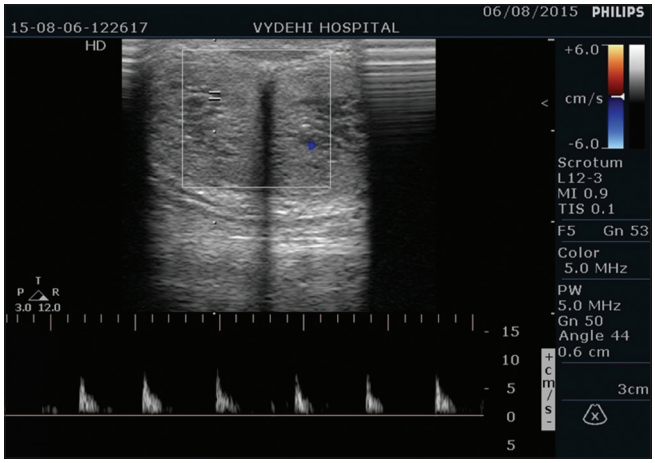


**Figure 8: 10 m post-injection showing low peak systolic velocity of 10 cm/s with diastolic flow of <5 cm/s**

cm/s (angle corrected) throughout all phases suggestive of venous leak (Figures 11-19). In 42% of the patients studied

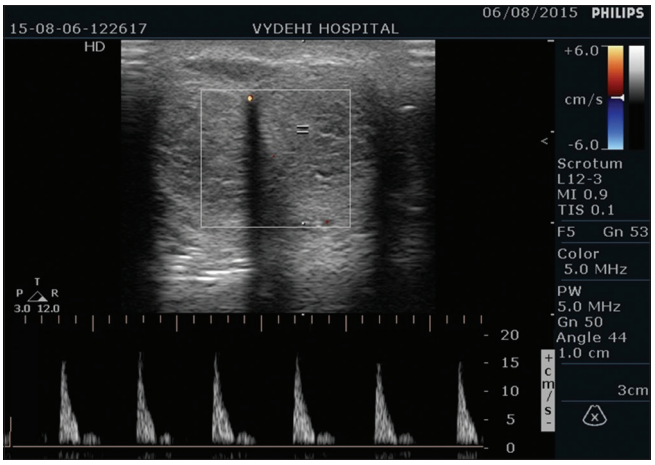


**Figure 9: 15 m post-injection showing low peak systolic velocity of 15 cm/s with diastolic flow of <5 cm/s**

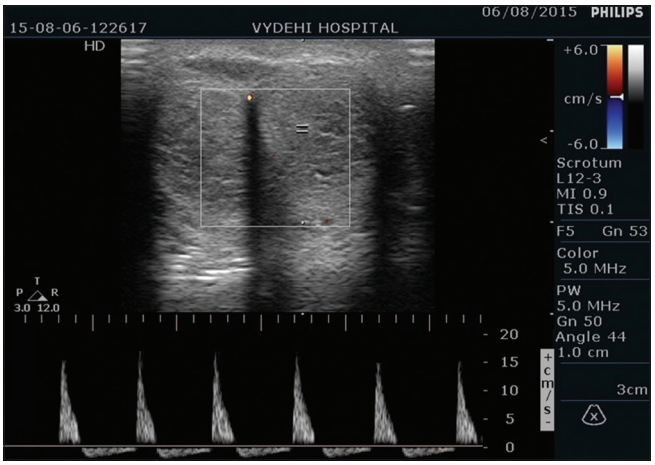


**Figure 10: 25 M post-injection showing low peak systolic velocity of 15 cm/s with diastolic flow reversal. Interpretation: This patient the study revealed no significant increase in the diameter of cavernosal vessel following papaverine injection and following papaverine injection the maximum peak systolic velocity remained <15 cm/s with diastolic flow reversal, suggesting arterial insufficiency**

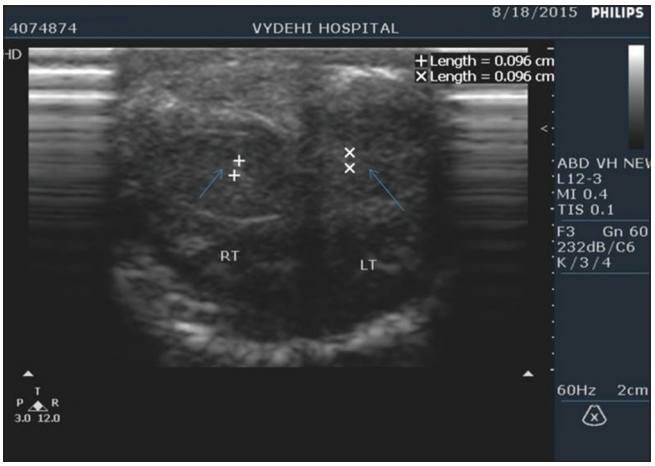


**Figure 11: Baseline arrows indicating right and left corpus cavernosa**

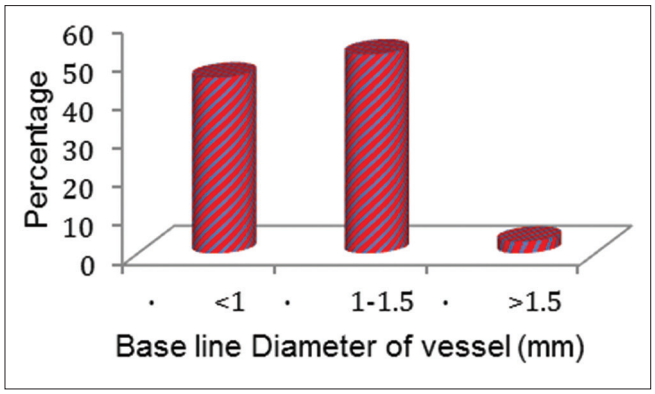


**Graph 5: Percentage increase in diameter of the cavernosal arteries after injection of papaverine**

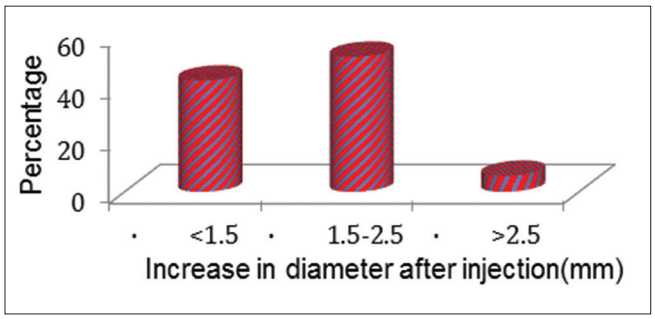


**Graph 6: Pre-injection baseline diameter of the cavernosal arteries studied**

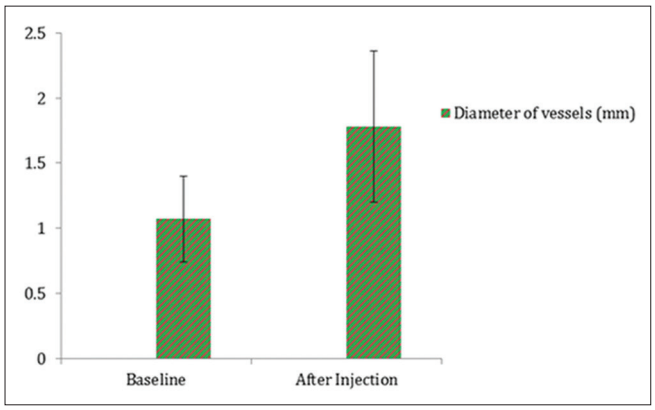


**Graph 7: Base line diameter of cavernosal arteries before and after injection of papaverine**

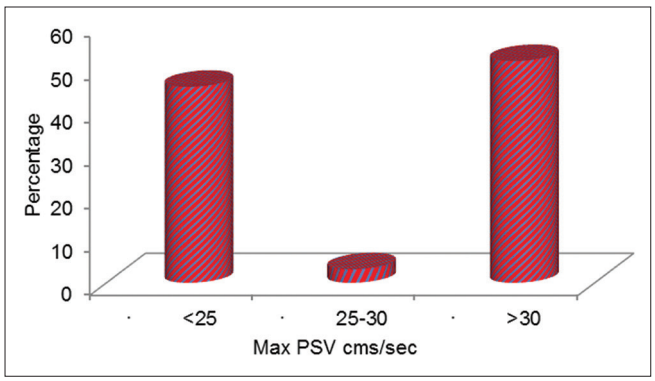


**Graph 8: Percentage of Max PSV recorded**

the vasculogenic cause could not be identified and where found to be functional (Graphs 5-8,10,11) (Table 7).

Base line diameter of the vessel at the time of injection was 1.05 ± 0.33 mm with an increase in diameter after injection to 1.71 ± 0.55 mm, The *P* value obtained was <0.001 which was statically significant.

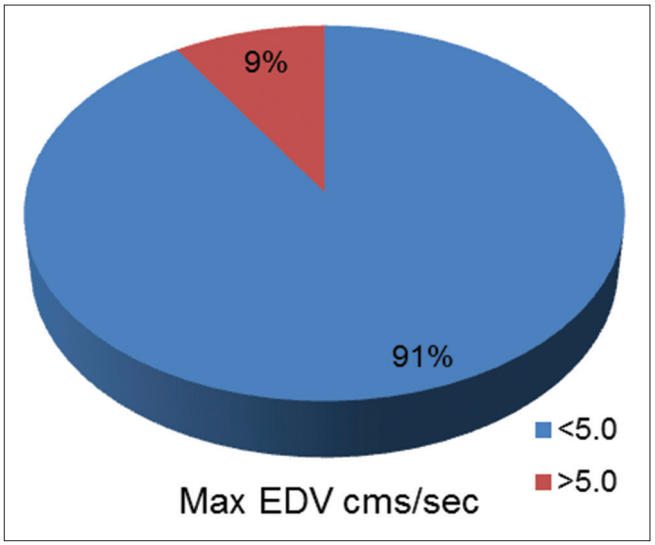


**Graph 9: Percentage of patients with venous insufficiency**

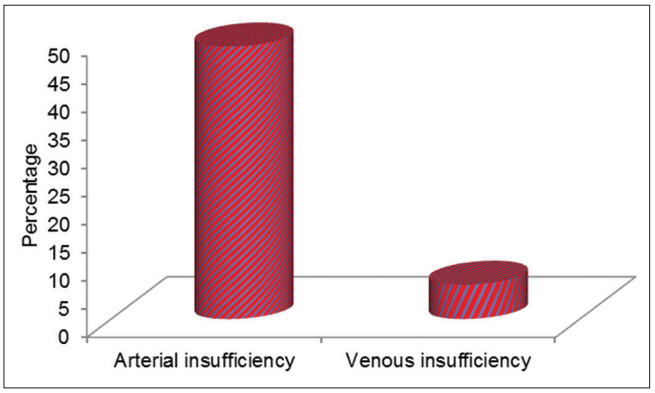


**Graph 10: Percentage of patients with arterial and venous insufficiency**

**Table 7: Number of patients with functional insufficiency**

| Functional | Number of patients | Percentage |
|---|---|---|
| Nil | 19 | 57.6 |
| Yes | 14 | 42.4 |
| Total | 33 | 100.0 |

**Table 8: Number of patients with complications**

| Complications | Number of patients | Percentage |
|---|---|---|
| Nil | 31 | 93.9 |
| Priapiasm | 2 | 6.1 |
| Total | 33 | 100.0 |

45% (15) of the patients had a Max PSV <25 cm/s were considered to have arterial insufficiency (Graph 10), 52% (17) of the patients had a Max PSV >30 cm/s were considered normal (Graph 11).

Complication of priapism was found in 2 patients (Table 8). 18% of the patients studied had hypertension, 30 out of 33 patients had a history of mixed diet.

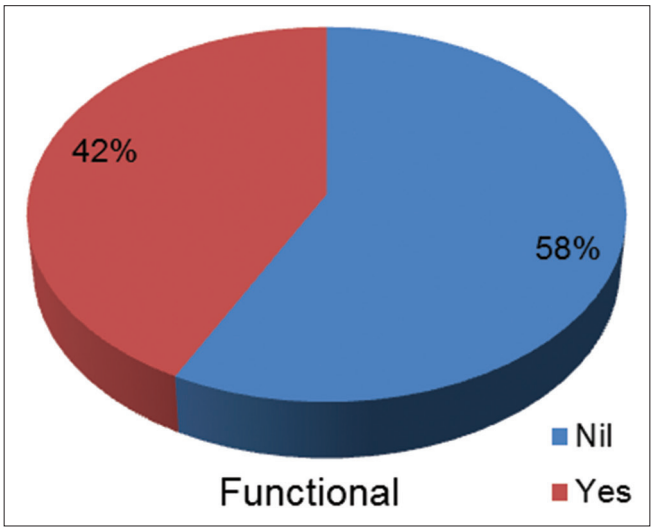


**Graph 11: Percentage of patients with functional and vasculogenic causes of ED**

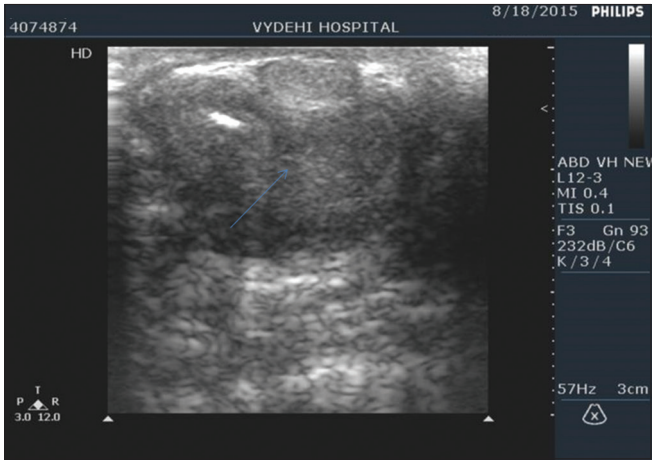


**Figure 12: After injection arrow indicating intracavernosal injection of papaverine**

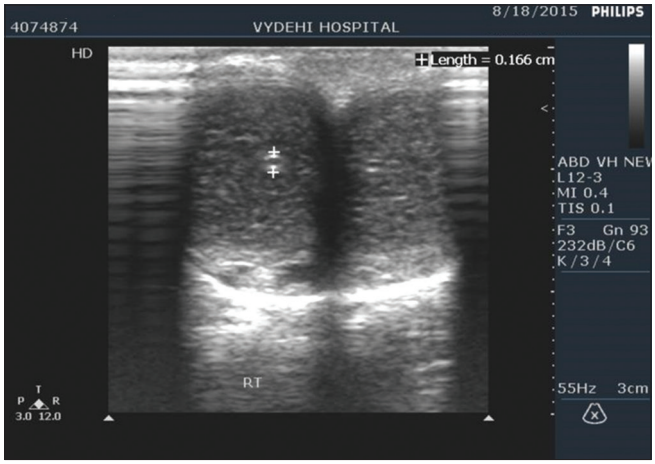


**Figure 13: After injection, the calipers showing increase in diameter of cavernosal artery**

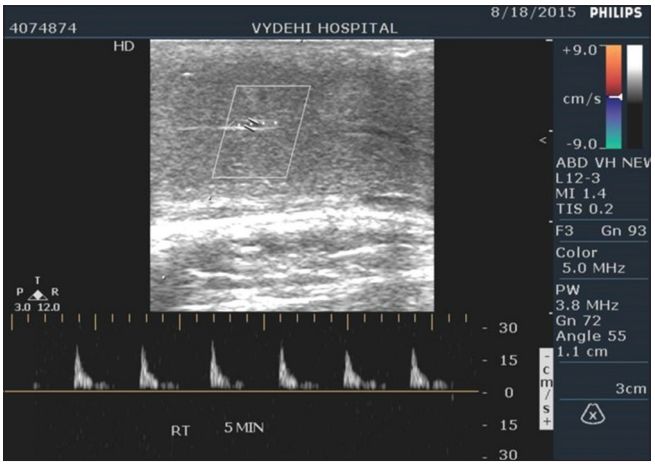


**Figure 14: 5 min post-injection**

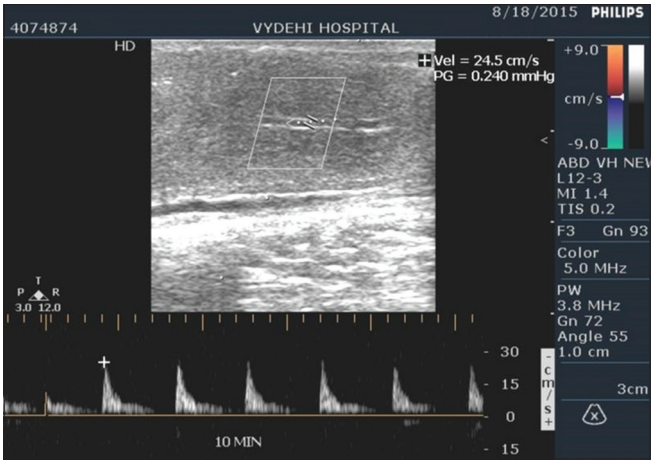


**Figure 15: 10 min post-injection**

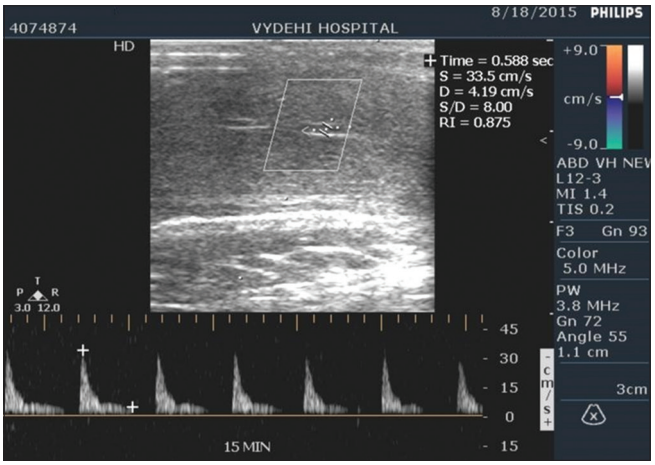


**Figure 16: 15 min post-injection**

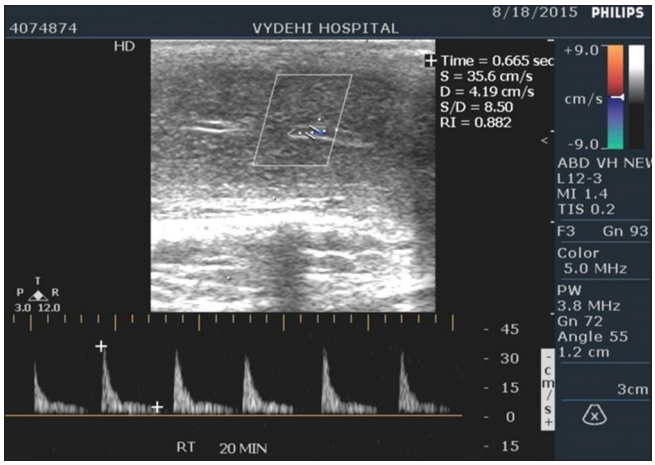


**Figure 17: 20 min post-injection normal peak systolic velocity >35 cm/s is with continuous diastolic flow of >5 cm/s with no diastolic reversal**

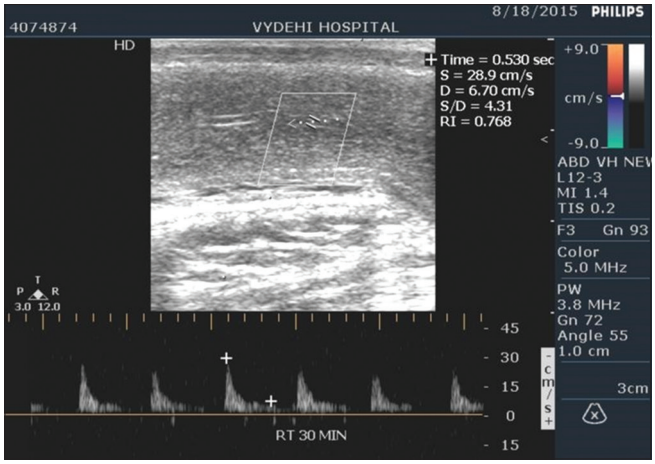


**Figure 18: 30 min. Reduced peak systolic velocity with continuous diastolic flow of >5 cm/s with no diastolic reversal suggesting venous insufficiency. Interpretation of Figures 11-18: There is a normal increase in the baseline diameter of the vessel post-papaverine injection with normal peak systolic velocities more than 35 cm/s with continuous end diastolic velocity of more than 5 cm/s with no diastolic reversal. Suggesting venous insufficiency**

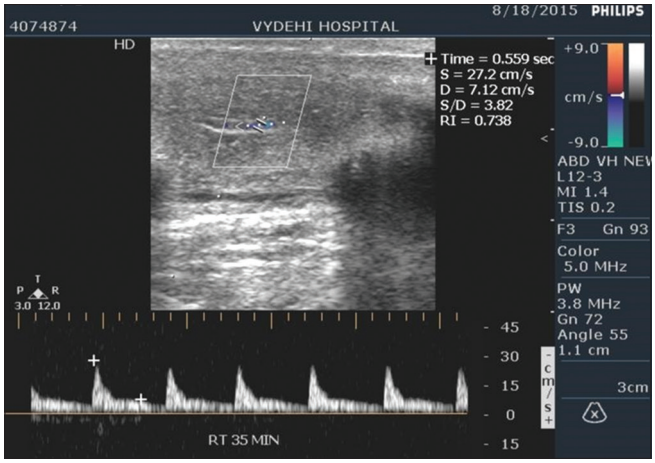


**Figure 19: 35 min**

### Complications

94% of the patient studied did not show any complications (Table 8); however, 2 cases out 33 patients showed priapism our findings are similar to a study by Kilic *et al.* where complication of priapism were noted in 18 of the 672 patients studied.[13] The two patients who developed priapism were during the initial part of the study further in the due course of our study to prevent delayed priapism we routinely injected 2 ml of 1:10000 dilution of phenylepinephrine intracavernosally. Both the cases of priapism did not show any arterial or venous insufficiency.

## CONCLUSION

When arterial insufficiency is found, patients can be considered to have systemic arteriovascular disease. On the other hand, veno-occlusive dysfunction is not correlated with systemic arterial vascular problems. In conclusion, investigating the hemodynamics and direction of flow in the cavernosal artery by color duplex Doppler for ED is not time-consuming and may help establish an accurate diagnosis of vascular causes of impotence.

## REFERENCES

1. Dean RC, Lue TF. Physiology of penile erection and pathophysiology of erectile dysfunction. Urol Clin North Am 2005;32:379-95, v.
2. Levine LA. Erectile dysfunction: A review of a common problem in rapid evolution. Prim Care Update Ob Gyns 2000;7:124-129.
3. Efremov EA, Kasatonova EV, Mel'nik JI. Use of sildenafil citrate for treatment of erectile dysfunction of various etiology. Urologiia 2015:117-8, 120-1.
4. Arackal BS, Benegal V. Prevalence of sexual dysfunction in male subjects with alcohol dependence. Indian J Psychiatry 2007;49:109-12.
5. Clifford A, Toppo J. Role of penile color doppler in the evaluation of erectile dysfunction. Indian J Radiol Imaging 2006;16:891-6.
6. Ludwig W, Phillips M. Organic causes of erectile dysfunction in men under 40. Urol Int 2014;92:1-6.
7. Lue TF, Hricak H, Marich KW, Tanagho EA. Vasculogenic impotence evaluated by high-resolution ultrasonography and pulsed Doppler spectrum analysis. Radiology 1985;155:777-81.
8. Meuleman EJ, Diemont WL. Investigation of erectile dysfunction. Diagnostic testing for vascular factors in erectile dysfunction. Urol Clin North Am 1995;22:803-19.
9. Shamloul R, Ghanem HM, Salem A, Kamel II, Mousa AA. The value of penile duplex in the prediction of intracavernous drug-induced priapism. Int J Impot Res 2004;16:78-9.
10. Bari V, Ahmed MN, Rafique MZ, Ashraf K, Memon WA, Usman MU. Evaluation of erectile dysfunction with color Doppler sonography. J Pak Med Assoc 2006;56:258-61.
11. Glina S, Virag R, Luis Rhoden E, Sharlip ID. Intracavernous injection of papaverine for erectile failure. J Sex Med 2010;7:1331-5.
12. Virag R, Frydman D, Legman M, Virag H. Intracavernous injection of papaverine as a diagnostic and therapeutic method in erectile failure. Angiology 1984;35:79-87.
13. Kilic M, Serefoglu EC, Ozdemir AT, Balbay MD. The actual incidence of papaverine-induced priapism in patients with erectile dysfunction following penile colour Doppler ultrasonography. Andrologia 2010;42:1-4.
14. Lue TF, Mueller SC, Jow YR, Hwang TI. Functional evaluation of penile arteries with duplex ultrasound in vasodilator-induced erection. Urol Clin North Am 1989;16:799-807.

15. Yavas US, Calisir C, Kaya T, Degirmenci NA. A sign of arteriogenic insufficiency on penile Doppler sonography: Retrograde flow in penile cavernosal-spongiosal communications. J Ultrasound Med 2007;26:1643-8.
16. Golijanin D, Singer E, Davis R, Bhatt S, Seftel A, Dogra V. Doppler evaluation of erectile dysfunction - part 1. Int J Impot Res 2007;19:37-42.
17. Porst H. Duplex ultrasound of the penis. Value of a new diagnostic procedure based on over 1,000 patients. Urologe A 1993;32:242-9.
18. Austoni E, Mirone V, Parazzini F, Fasolo CB, Turchi P, Pescatori ES, *et al*. Smoking as a risk factor for erectile dysfunction: Data from the andrology prevention weeks 2001-2002 a study of the Italian Society of Andrology (S.I.A.). Eur Urol 2005;48:810-7.
19. Chew KK, Bremner A, Stuckey B, Earle C, Jamrozik K. Is the relationship between cigarette smoking and male erectile dysfunction independent of cardiovascular disease? Findings from a population-based cross-sectional study. J Sex Med 2009;6:222-31.
20. Wu C, Zhang H, Gao Y, Tan A, Yang X, Lu Z, *et al*. The association of smoking and erectile dysfunction: Results from the fangchenggang area male health and examination survey (FAMHES). J Androl 2012;33:59-65.
21. Nigam SK, Venkatakrishna-Bhatt H. Analysis and toxicity of plain (PMP) and blended (PMT) Indian pan masala (PM). Eurasian J Med 2013;45:21-33.
22. Jackson G, Rosen RC, Kloner RA, Kostis JB. The second Princeton consensus on sexual dysfunction and cardiac risk: New guidelines for sexual medicine. J Sex Med 2006;3:28-36.
23. Acharya D, Vasu CK. Penile Doppler evaluation of erectile dysfunct. J Evol Med Dent Sci 2014;3:7102-7.
24. Patel U, Amin Z, Friedman E, Vale J, Kirby RW, Lees WR. Colour flow and spectral Doppler imaging after papaverine-induced penile erection in 220 impotent men: Study of temporal patterns and the importance of repeated sampling, velocity asymmetry and vascular anomalies. Clin Radiol 1993;48:18-24.
25. Benson CB, Aruny JE, Vickers MA Jr. Correlation of duplex sonography with arteriography in patients with erectile dysfunction. AJR Am J Roentgenol 1993;160:71-3.
26. Collins JP, Lewandowski BJ. Experience with intracorporeal injection of papaverine and duplex ultrasound scanning for assessment of arteriogenic impotence. Br J Urol 1987;59:84-8.

**How to cite this article:** Suresh A, Balachandran A, Indira N, Ramprakash HV. Role of Penile Color Doppler in the Evaluation of Erectile Dysfunction. Int J Sci Stud 2015;3(7):23-32.

**Source of Support:** Nil, **Conflict of Interest:** None declared.