Print ISSN: 2321-6379
Online ISSN: 2321-595X
DOI: 10.17354/ijss/2017/504

Original Article

Morphometric Analysis of Tentorial Incisura and its Clinical Implications

K Rajaraajan[1], R Pragadhees[1], SS Sathish Prabu[2], S Pradeep[2]

[1]Assistant Professor, Department of Neurosurgery, Madurai Medical College & Government Rajaji Hospital, Madurai, Tamil Nadu, India, [2]Resident, Department of Neurosurgery, Madurai Medical College & Government Rajaji Hospital, Madurai, Tamil Nadu, India

Abstract

Introduction: Tentorial incisura is important due to transtentorial herniation, a terminal pathophysiological event in various neurosurgical conditions. With advent of modern neuroradiological methods lacuna in understanding of herniation syndromes is being gradually filled.

Aim: To analyze anatomical variation, classy types and their clinical relevance and interpretation on neuroradiological imaging.

Materials and Methods: Total 100 magnetic resonance images (MRI) of brain were analyzed using RadiAnt DiCom viewer. Statistical methods used descriptive analysis, Pearson correlation, significant two-tailed test, student *t*-test, and analysis of variance.

Results: Notch length is typed into three, maximum notch width into three. By combination, the tentorial incisura is typed into nine types. Correlation between parameters and statistical significance is interpreted.

Conclusion: Morphometry classification and relative smaller dimensions of anatomical structures and relationships in Indian population have been elucidated. Various manifestations of herniation syndromes explained. Pre-operative MRI morphometric analysis has been highlighted.

Key words: Magnetic resonance images, Morphometric analysis, Tentorial incisura

INTRODUCTION

The tentorial incisura is an anatomical structure that carries with it tremendous clinical and pathological importance in the field of neurosurgery. The incisura is surrounded by a myriad of vital structures that mandates exercising utmost caution during the course of the performance of various complicated neurosurgical procedures in that region.

The phenomenon of transtentorial herniation that was first described by Meyer[1] in the year 1920 is a terminal pathophysiological occurrence in various neurosurgical conditions ranging from traumatic brain injury to brain tumor progression.[2] However, for want of advancement in modern neuroradiological imaging techniques, there remained a lacuna in our understanding of Herniation syndromes.[3]

With the advent of modern imaging methods, this void is being gradually filled by our ever-growing understanding of the neuroanatomical aspects of the tentorial incisura.[4] The tentorial incisura has numerous anatomical variations which contribute to and influence the rapidity of onset and progression of herniation irrespective of the underlying cause. Numerous morphometric studies have been conducted on various aspects of the brain, however, studies regarding the anatomical variations of the tentorial incisura are very limited, and the available studies have been conducted in cadavers in the sixties.[5,6]

In this study, normal anatomical variations in the dimensions of the tentorial notch and position of the brainstem in relation to the tentorial hiatus are measured and analyzed using currently available magnetic resonance imaging (MRI) techniques. These factors are likely to have immense bearing on the progression and outcome of traumatic brain injury and other neurosurgical causes of herniation syndromes. These also carry implications during

Access this article online

www.ijss-sn.com

Month of Submission : 08-2017
Month of Peer Review : 09-2017
Month of Acceptance : 10-2017
Month of Publishing : 10-2017

Corresponding Author: Dr. R Pragadhees, Department of Neurosurgery, Government Rajaji Hospital, Madurai, Tamil Nadu, India. Phone: +91-9952410203. E-mail: pragadhees_r@yahoo.com

micro neurosurgical approaches while attempting to deal with lesions in the vicinity of the hiatus.

The tentorial hiatus is a complex void that varies greatly in size and shape among individuals. Although it can be simply described as the free edge of the tentorium cerebelli, it is much more complex than what meets the eye. The reason behind this complexity is primarily its three-dimensional anatomy with lack of blood vessels in its edges and occurrence of occasional calcification. Hence, visualization and quantification of this structure remained a challenge for neurosurgeons and neuroanatomists for decades.

With the advent of modern imaging modalities, this elusive process has become more within reach and thus enhancing our knowledge of this structure. In-depth understanding and characterization of the hiatus and induction of a practical and simple classification of it may help explain patterns of herniations, susceptibility of the oculomotor nerve to compression and pathomechanics of concussion and inertial injuries of the brain.

With the entry of powerful operating microscopes into the field of neurosurgery, a new era has been ushered into this field which has made earlier impossible and untouchable lesions of the brain within the reach of the neurosurgeon with minimal retraction of the normal brain and at times with negation of the very need for touching the normal brain parenchyma. By doing so, the risk and complications associated with cranial surgery can be greatly minimized and altogether avoided at times.

Morphometric data allows for precise and foolproof pre-operative planning of location of the lesion and trajectory toward the lesion which provides the least transgression of normal tissue. This is of paramount importance in reducing operative morbidity and much dreaded but fraught mortality associated with neurosurgery since time immemorial.

Aim of the Study

1. To analyze the anatomical variations of the tentorial incisura[7]
2. To classify the various types of tentorial incisura
3. To elucidate the clinical relevance of these variations
4. To establish an anatomical basis for interpretation of the tentorial hiatus on radiological imaging.

MATERIALS AND METHODS

Study Group

Our study group consisted of 100 patients aged between 18 and 60 years undergoing MRI of the brain *per se* in the absence of organic lesions of the brain or as part of the screening of the brain in cases of spinal pathology or non-central nervous system pathology, either as an in-patient or as an out-patient. Hence, any patient who during the process of imaging was found to harbor an intracranial pathology such as an intracranial space-occupying lesion was excluded from the study.

Method Used

MRI in axial, sagittal and coronal sections were selected and analyzed using RadiAnt DiCom Viewer which is versatile open source software available for common usage. Parameters measurement (Figures 1-4) in millimeters.

1. Anterior notch width (ANW): The width of the tentorial hiatus in the axial plane measured through the posterior aspect of dorsum sellae
2. Maximum notch width (MNW): Maximum width of the notch in the axial plane
3. Notch length (NL): Distance between superoposterior edge of Dorsum Sellae in a median plane to the apex of the notch
4. Posterior tentorial length (PTL): Shortest distance between the apex of the notch and the confluence of sinuses
5. Apico tectal distance (AT): Distance from the tectum in the median plane to a perpendicular line dropped from the apex of the notch to the cerebellum
6. Inter-pedunculoclival distance (IC): Distance between

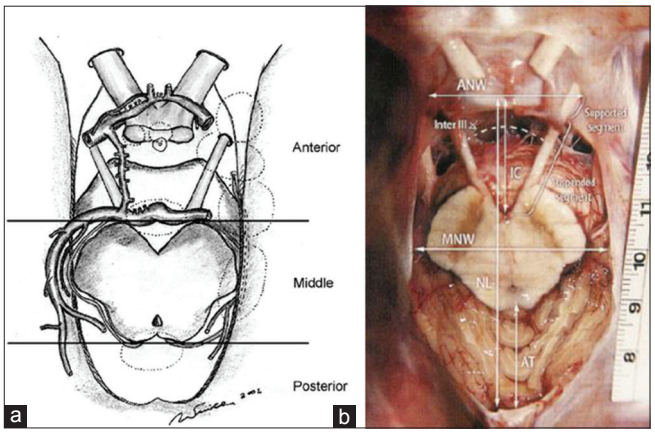

Figure 1: (a and b) Tentorial incisura

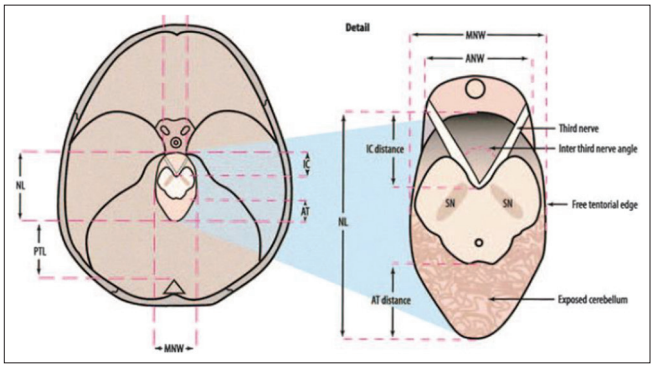

Figure 2: Tentorial incisura measurements

the interpeduncular fossa to the superoposterior edge of the Dorsum Sellae
7. Cephalic index (CI): (Calvarial breadth/anteroposterior calvarial length) ×100.

Statistical Methods

In this study, the following statistical methods were utilized. They are:
1. Descriptive analysis
2. Pearson correlation
3. Significant two-tailed test
4. Student *t*-test
5. Analysis of variance.

OBSERVATIONS AND RESULTS

In our study, a total of 100 patients were analyzed taking measurements at various pre-defined levels. The raw data were tabulated.

Descriptive Analysis (Table 1)

Correlation (Table 2)

To ascertain the correlation between the various data sets we used the Pearson Correlation technique (*r* value) and obtained the corresponding *P*-value using significant two-tailed test. The following statistically significant correlations were observed.

There was a significant ($P < 0.05$) positive correlation between ANW and MNW, MNW and NL, AT and IC, AT and AP, AT and BR, PTL and BR. There was a significant negative correlation ($P = <0.05$) between ANW and AT. There was a highly significant correlation ($P < 0.01$) between MNW and IC, NL and AT, NL and IC, NL and AP, NL and BR, NL and AT, PTL and Anteroposterior length of skull. Age was not statistically correlated with any of the Dimensions measured.

Student *t*-test (Tables 3 and 4)

ANOVA

Analysis of variance with age as dependent variable showed that ANW ($P = 0.003$) and MNW ($P = 0.002$).

None of the factors had a statistically significant dependence on age.

Taking into consideration all the above statistical methods, the dimensions of the tentorial hiatus are classified as follows.

NL is short <48.7 mm ($n = 24$), midrange 48.7–55.1 mm ($n = 51$), and long >55.1 mm ($n = 25$). MNW is narrow <27.6 mm ($n = 22$), midrange 27.6–31.2 mm ($n = 54$), and wide >31.2 mm ($n = 24$). Matrix distribution was done to classify the Tentorial Hiatus (Table 5 and Figure 5).

Classification of Tentorial Notch (Table 6)

In our study, a total of 100 patients were analyzed taking measurements at various pre-defined levels. The raw data

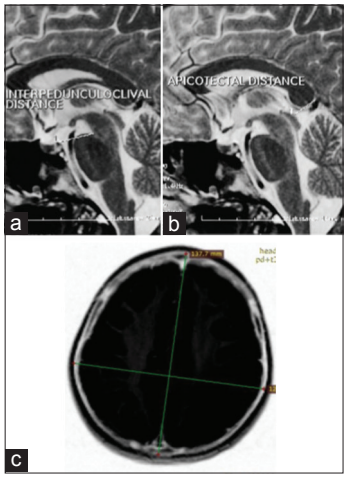

Figure 3: Measurements in MRI

Table 1: Descriptive analysis

Method	Age	ANW	MNW	NL	AT	IC	PTL	AP	BR	CI
Valid	100	100	100	100	100	100	100	100	100	100
Missing	0	0	0	0	0	0	0	0	0	0
Mean	36.99	17.113	29.373	52.248	17.637	16.817	53.391	174.354	144.034	83.2685
Standard error of mean	1.06444	0.40285	0.34878	0.50638	0.38838	0.35326	0.67496	1.60434	1.01762	0.96341
Median	36.5	16.15	29.35	52.8	17.55	16.7	53.9	176.5	143.8	81.3679
Mode	47	14.40[a]	29.10[a]	55	15.6	17.9	49.70[a]	178	146.00[a]	77.44[a]
Standard deviation	10.6443	4.02845	3.48781	5.06376	3.88378	3.53259	6.74959	16.04343	10.17617	9.6347
Variance	113.303	16.228	12.165	25.642	15.084	12.479	45.557	257.392	103.554	92.815
Range	40	19.1	17.2	29.3	21.7	20.2	44.6	88.7	75.6	61.21
Minimum	19	10.9	21	36.7	4.5	7.6	25.7	109.4	111.9	68.59
Maximum	59	30	38.2	66	26.2	27.8	70.3	198.1	187.5	129.8
Percentiles 25	28	14.4	27.625	48.775	15.6	14.1	50.125	171.25	138.4	78.3917
Percentiles 50	36.5	16.15	29.35	52.8	17.55	16.7	53.9	176.5	143.8	81.3679
Percentiles 75	47	18.2	31.2	55.15	20.6	18.675	57.6	183.1	148.15	84.4282

[a]Multiple modes exist. The smallest value is shown, MNW: Maximum notch width, NL: Notch length, PTL: Posterior tentorial length, ANW: Anterior notch width, AT: Apico tectal, CI: Cephalic index

Table 2: Pearson correlation and significant two-tailed test

		ANW								
MNW	PC	0.239*								
	Sig.	0.017	MNW							
NL	PC	−0.03	0.249*							
	Sig.	0.746	0.013	NL						
AT	PC	−0.207*	0.033	0.641**						
	Sig.	0.039	0.743	0	AT					
IC	PC	−0.08	0.268**	0.392**	0.237*					
	Sig.	0.408	0.007	0	0.018	IC				
PTL	PC	−0.04	0.148	0.099	−0.02	−0.063				
	Sig.	0.714	0.142	0.328	0.884	0.533	PTL			
AP	PC	−0.18	0.128	0.353**	0.241*	−0.104	0.296**			
	Sig.	0.07	0.205	0	0.016	0.303	0.003	AP		
BR	PC	−0.15	0.156	0.394**	0.234*	0.064	0.213*	0.299**		
	Sig.	0.135	0.121	0	0.019	0.526	0.033	0.003	BR	
CI	PC	0.042	−0.01	−0.063	−0.07	0.149	−0.11	−0.750**	0.390**	
	Sig.	0.677	0.927	0.53	0.513	0.14	0.266	0	0	CI
AGE	PC	−0.13	−0.01	0.059	0.021	−0.188	0.131	0.149	0.214*	0.012
	Sig.	0.189	0.903	0.561	0.833	0.061	0.194	0.14	0.033	0.908

PC: Pearson correlation, *Correlation is significant at the 0.05 level (two-tailed), **Correlation is significant at the 0.01 level (two-tailed), Sig: Significant two-tailed test, MNW: Maximum notch width, NL: Notch length, PTL: Posterior tentorial length, ANW: Anterior notch width, AT: Apico tectal, CI: Cephalic index

Table 3: 95% confidence interval of the difference

Parameter	Lower	Upper
ANW	16.3137	17.9123
MNW	28.6809	30.0651
NL	51.2432	53.2528
AT	16.8664	18.4076
IC	16.1161	17.5179
PTL	52.0517	54.7303
AP	171.1706	177.5374
BR	142.0148	146.0532
CI	81.3569	85.1801

MNW: Maximum notch width, NL: Notch length, PTL: Posterior tentorial length, ANW: Anterior notch width, AT: Apico tectal, CI: Cephalic index

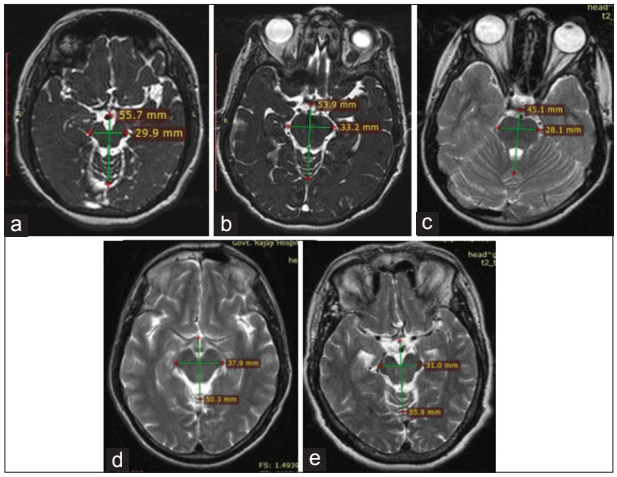

Figure 4: Tentorial incisura. (a) mid maximum notch width (MNW) and long notch length (NL), (b) mid MNW and mid NL, (c) mid MNW and short NL, (d) wide MNW and mid NL, (e) mid MNW and long NL

Table 4: ANOVA

Parameter	Sum of square	df	Mean square	F	Significant
ANW					
B/G	812.331	31	26.204	2.243	0.003
W/G	794.282	68	11.681		
Total	1606.613	99			
MNW					
B/G	624.297	31	20.139	2.361	0.002
W/G	580.02	68	8.53		
Total	1204.317	99			
NL					
B/G	749.066	31	24.163	0.918	0.594
W/G	1789.463	68	26.316		
Total	2538.53	99			
AT					
B/G	521.671	31	16.828	1.178	0.283
W/G	971.622	68	14.289		
Total	1493.293	99			
IC					
B/G	437.723	31	14.12	1.204	0.259
W/G	797.718	68	11.731		
Total	1235.441	99			
PTL					
B/G	1652.368	31	53.302	1.268	0.206
W/G	2857.774	68	42.026		
Total	4510.142	99			
AP					
B/G	6512.598	31	210.08	0.753	0.806
W/G	18969.19	68	278.96		
Total	25481.79	99			
BR					
B/G	3623.846	31	116.9	1.199	0.263
W/G	6628.038	68	97.471		
Total	10251.88	99			
CI					
B/G	4132.831	31	133.32	1.793	0.023
W/G	5055.89	68	74.351		
Total	9188.721	99			

MNW: Maximum notch width, NL: Notch length, PTL: Posterior tentorial length, ANW: Anterior notch width, AT: Apico tectal, CI: Cephalic index

Table 5: Classification of tentorial notch

Classification		NL		
	n=100	Short	Midrange	Long
MNW	Narrow	Small (9)	Narrow (10)	Mixed (3)
	Midrange	Short (11)	Typical (29)	Long (14)
	Wide	Mixed (4)	Wide (12)	Large (8)

MNW: Maximum notch width, NL: Notch length

Table 6: Classification of tentorial notch

Classification		
Wide notch	MNW (wide)	NL (mid)
Narrow notch	MNW (narrow)	NL (mid)
Long notch	MNW (mid)	NL (long)
Short notch	MNW (mid)	NL (short)
Typical notch	MNW (mid)	NL (mid)
Large notch	MNW (wide)	NL (long)
Small notch	MNW (narrow)	NL (short)
Mixed notch 1	MNW (wide)	NL (short)
Mixed notch 2	MNW (narrow)	NL (long)

MNW: Maximum notch width, NL: Notch length

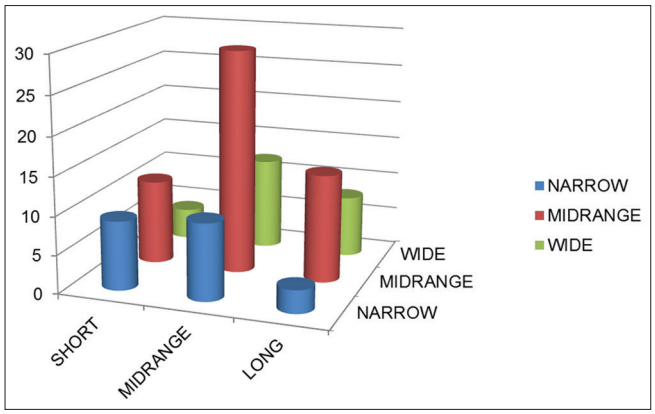

Figure 5: Types of tentorial incisura

were tabulated. Tentorial incisura can be broadly classified into nine anatomical variations.

DISCUSSION

As early as the year 1958, before the advancement of magnetic resonance and other imaging technology, Sunderland and colleagues categorized the tentorial notch into two types - broad and narrow.[6] In the same line, Adler and Milhorat classified it into eight types based on cadaveric studies.[8]

Klintworth *et al.* put forth the concept that the tentorium and its opening are highly variable in respect to their size, shape, dimensions, and orientation in various animal species.[9] There are even a few animals in the world in which such a structure is classically absent. These include fishes, reptiles, and amphibious animals. In another subset, the tent is incomplete in the sense that it does not reach the midline at all, such as morphology is seen in guinea pigs and rodents.

Only in higher mammals such as humans and primates, the tent forms a thick membrane partitioning the superiorly located cerebral hemispheres and the inferiorly located cerebellar hemispheres. The opening of the tentorium, namely, the tentorial Hiatus or notch or incisura, surrounds the midbrain structures.

When studies on the phylogeny and development of the tent were conducted, it was inferred that this is a structure that emerged later during eons of evolution. It was first found as symmetrical dural folds on either side of the midbrain in the cerebro-cerebellar fissure. As time went by, the falx cerebri descended down to meet the tentorium at more and more points, carrying with it the formation of a straight sinus. As species evolved, the length of the straight sinus increased and so did the dimensions of the hiatus.

Similar studies in Indian population are few and far between. Even western studies of the same have been conducted in cadaveric samples. Live *in vivo* studies are limited if not almost non-existent.

It is a generally accepted fact that the morphological features of the population of the west correlate poorly with that of the Asian population. Western individuals have a much larger head with a greater CI with larger structural features compared to people of the East, especially the Indian and other Asian population.

During the process of brain herniation due to various causes, there occurs gross anatomical distortion of tissue as they come down through the tentorial aperture. This produces highly localizing signs and clinical features in the patient. The features found in pathological specimen include.

1. Medial displacement of the temporal lobe or the part in question
2. Medial displacement of the brainstem structures
3. Grooving of the brainstem
4. Descent of the hippocampal gyrus
5. Compression of the ipsilateral oculomotor nerve
6. Characteristic Duret hemorrhages into the brainstem.

Although the above-enlisted features are a generalization of the incidence occurring during herniation, these are not all found in the same patient or among different patients undergoing this moribund potentially fatal pathological process. The reason for this difference in manifestations of the same process in different individuals is unclear.

This also fails to explain the incidental occurrence of the neurosurgically famed false localizing signs. All the above paradoxes can be explained due to the anatomical variations in the tentorial notch in individuals of the same species, in our case human beings.

It has been proven that longer and wider incisura have a greater amount of cerebellar tissue exposed when compared to those that are narrow and shorter. Small apertures logically expose lesser amount of brain tissue. This exposure variability in relation to the dimensions of the notch has viable implications in regard to the propensity of occurrence of herniation syndromes, be it descending or ascending herniations.

During the postmortem examination of the human brain, it is customary to obtain the specimen by the division of the falx cerebri and the tentorium, so as to enable mobilization and delivery of the brain.[10] This invariably causes unavoidable distortion of the normal anatomy. This compounds the already present changes inherent to a dead brain specimen.

This anatomical distortion can be circumvented by studying the brain in its natural live state in humans using the now freely available MRI techniques. It is much easier to see the anatomical landmarks and to make accurate *in situ* measurements of the various dimensions of interest without causing undue morbidity to the patient. However, the only limiting factor in a country like ours is the availability of MRI equipment, the running costs involved, the time consumption for image acquisition and the patient-borne cost factor.

All the parameters looked for by the authors of various cadaveric studies can be sought and easily quantified. Based on these, the position of the brainstem and type of incisura can be identified. This measurement can also be used to calculate and plan the trajectory during neurosurgical operations in the brain especially in lesions in and around the tentorial hiatus. Such proper planning can avoid unnecessary morbidity and even mortality during performing complicated microneurosurgical procedures.[11,12]

CONCLUSION

The following conclusions can be drawn from this study.

A morphometry based classification of the tentorial hiatus has been formulated. Various dimensions of the region of the tent have been measured in a representative subset of South Indian population. Anatomical make up of our population with that of the population represented in Western studies are compared. Relatively smaller dimensions of anatomic structures and relations in Indian population have been elucidated. The reason for variable manifestations of herniation syndromes can be explained.

In this study, ANW correlates positively with MNW. MNW correlates positively with NL. AT distance, NL and interpeduncular-clival distance are significantly correlated. There is no significant correlation between age, CI and the hiatus dimensions.

The value of radiology based morphometric analysis in pre-operative neurosurgical planning has been highlighted.

ACKNOWLEDGMENT

We thank with gratitude Professor Dr. S. Revwathy Kailairajan. M.D., D.G.O.DNB, Former Dean and Professor Dr. M.R. Vairamuthuraja. M.D, Former Dean, Government Rajaji Hospital and Madurai Medical College, Madurai, for permitting us to utilize the clinical materials of this hospital. We are gratefully indebted to Professor Dr. N. Muthukumar. M.Ch, Department of Neurosurgery, for the invaluable guidance and advice rendered in the study. We also sincerely acknowledge the guidance and support given by Professor Dr. R. Veerapandian. M.S., M.Ch and Professor Dr. J. Srisaravanan. M.S., M.Ch in enabling us to go through and complete this study. We sincerely acknowledge Professor Dr. Sumathi. M.D., DMRD, Head of the Department of Radiology, for permitting us to utilize the resources of her department. We also immensely thankful to all the Assistant Professors of the Department of Neurosurgery, for their guidance in completion of the study. We also express our heartfelt gratitude to the technical staff of the Department of Radiology, for their support and helping hand in the conduct of the study. We also express our gratitude to Mr. S. Pandi. M.Sc., Assistant Professor of Statistics, Madurai Medical College, for his invaluable help toward completion of the study.

REFERENCES

1. Meyer A. Herniation of the brain. Arch Neurol Psychiatry 1920;4:387-400.
2. Munro D, Sisson WR Jr. The recognition and treatment of incisures herniation caused by craniocerebral injuries. Trans Am Neurol Assoc 1950;75:62-5.
3. Ardeshiri A, Ardeshiri A, Wenger E, Holtmannspötter M, Winkler PA. Surgery of the anterior part of the frontal lobe andofthe central region: Normative orphometric data based on magnetic resonance imaging. Neurosurg Rev 2006;29:313-20.
4. Bakay L, Lee JC, Lee GC, Peng JR. Experimental cerebral concussion. Part 1: An electron microscopic study. J Neurosurg 1977;47:525-31.
5. Corsellis JA. Individual variation in the size of the tentorial opening. J Neurol Neurosurg Psychiatry 1958;21:279-83.
6. Sunderland S. The tentorial notch and complications produced by herniations of the brain through that aperture. Br J Surg 1958;45:422-38.
7. Windle WF, Groat RA, Fox CA. Experimental structural alterations in the brain during and after concussion. Surg Gynecol Obstet 1944;79:561-72.

8. Adler DE, Milhorat T. The tentorial notch: Anatomical variation, morphometric analysis, and classification in 100 human autopsy. J Neurosurg 2002;96:1103-12.
9. Klintworth GK. The ontogeny and growth of the human tentorium cerebelli. Anat Rec 1968;160:635-45.
10. Bull JW. Tentorium cerebelli. Proc R Soc Med 1969;62:1301-10.
11. Nguyen JP, Djindjian M, Brugières P, Badiane S, Melon E, Poirier J. Anatomy-computerized tomography correlations in transtentorial brain herniation. J Neuroradiol 1989;16:181-96.
12. Reich JB, Sierra J, Camp W. Magnetic resonance imaging measurements and clinaical changes accompanying trans tentorial and foramen magnum brain herniation. Ann Neurol 1993;33 159-70.

How to cite this article: Rajaraajan K, Pragadhees R, Prabu SSS, Pradeep S. Morphometric Analysis of Tentorial Incisura and its Clinical Implications. Int J Sci Stud 2017;5(7):98-104.

Source of Support: Nil, **Conflict of Interest:** None declared.