

Scrotal Calcinosis - An Etiological Dilemma: A Prospective Study

Sheela Chaudhari¹, Sachan Bhat², Deepa Hatwal¹, Pawan Bhat², Neha Batra²

¹Associate Professor, Department of Pathology, Veera Chandra Singh Garhwali Government Medical Science & Research Institute, Srikot, Srinagar, Pauri Garhwal, Uttarakhand, India, ²Assistant Professor, Department of Pathology, Veera Chandra Singh Garhwali Government Medical Science & Research Institute, Srikot, Srinagar, Pauri Garhwal, Uttarakhand, India

Abstract

Introduction: Scrotal calcinosis is a rare benign condition of scrotal skin with disputed etiology. It is characterized by single or multiple calcified nodules on a scrotal skin. It should be investigated and confirmed to rule out any malignancy of testis. Fine-needle aspiration cytology is difficult due to calcification. Hence, the only way to confirm is histopathology of excised nodule.

Purpose: Purpose of this study was to establish an etiology of scrotal calcinosis.

Methods: This is a prospective study over a period of 3-year. The total of 20 patients were analyzed clinically, biochemically, and histopathologically.

Result: The total 20 cases of scrotal calcinosis were analyzed, no metabolic, or biochemical abnormalities were found in any of the patient. All cases histopathologically confirmed to be idiopathic in origin.

Conclusion: We conclude that scrotal calcinosis is more likely an idiopathic process. Though it is a rare benign disease, such patients should be thoroughly investigated to rule out any hidden pathology.

Key words: Idiopathic, Relapsing, Scrotal nodule, Scrotal calcinosis

INTRODUCTION

Scrotal calcinosis is a rare benign disorder of a scrotal skin. This is characterized by single to multiple painless calcified intradermal nodules of varying size. It was first described by Lewinsky in 1883 as a subgroup of calcinosis cutis. It occurs usually at 20-40 years of age.¹ The condition is mostly asymptomatic, but sometimes patient have complains of heaviness in scrotum, discharge and itching.² There is no systemic metabolic disorder. Histological examination reveals extensive deposition of calcium in the dermis. Which may be surrounded by inflammatory cells, histiocytes, and giant cells³ sometimes a cyst wall is also visible.⁴ The exact pathogenesis of scrotal calcinosis is not known. Different authors have given

different opinion which includes dystrophic calcification of epidermal cyst,⁴ eccrine duct millia,⁵ or dartoic muscle,⁶ and calcification secondary to minor trauma of the scrotum.⁷ The most studies showed normal serum levels of calcium, phosphorus, and blood sugar. Although this condition is benign, it needs to be differentiated from other benign conditions of the scrotum namely epidermal inclusion cyst, steatocystoma. Definitive diagnosis is based on histology.

MATERIALS AND METHODS

This is a prospective study of scrotal calcinosis carried out at the department of pathology, government medical college Srikot, Srinagar, Pauri Garhwal, Uttarakhand over a period of 3-year (February 2012-March 2015). All the patients of the scrotal nodules visited in surgical outpatient department were examined clinically, biochemically, and histologically. Only histologically confirmed cases were included in the study. Sample of histopathology was also collected from the surgeries done outside. A total of 20 patients were examined during this period patients of all ages were included in the study. Investigations of patients

Access this article online



www.ijss-sn.com

Month of Submission : 08-2015
Month of Peer Review : 09-2015
Month of Acceptance : 10-2015
Month of Publishing : 10-2015

Corresponding Author: Dr. Sheela Chaudhari, Department of Pathology, Veera Chandra Singh Garhwali Government Medical Science & Research Institute, Srikot, Srinagar, Pauri Garhwal, Uttarakhand, India. Phone: +91-9412085721. E-mail: drncsuk@yahoo.com

included complete blood count, serum and urinary calcium, phosphorus, fasting, and post-prandial blood sugar levels. Histopathology was done in all cases. Histopathological slides were stained with hematoxylin and eosin stain.

RESULT

The age of patients ranged from 18 to 70 years (Table 1) with maximum number of patients in the 3rd and 4th decade. The most common symptom was scrotal nodules (Table 2). No aspiration cytology was done. Biochemical findings were within normal limits. No metabolic abnormality was detected. All specimens of scrotal nodules received for histopathology grossly showed multiple nodules covered with skin (Figure 1a), cut surface showed whitish areas (Figure 1b). Histopathology of all patients scrotal nodule revealed calcified basophilic structure at places separated by fibrous connective tissue (Figure 2a and b) and surrounded by mononuclear inflammatory cells and foreign body giant cells (Figure 3). No cystic structure or capsule was in the slide. On the bases of these features scrotal calcinosis was labeled as idiopathic condition.

DISCUSSION

Idiopathic Scrotal calcinosis is a benign condition characterized with calcified deposits surrounded by granulomatous reaction of a foreign body type.^{4,8} Clinically, it appears as varying size nodules, solitary or multiple, yellow, hard in consistency. Idiopathic Scrotal calcinosis occurs in the absence of the tissue injury or systemic metabolic disorder. No causative factor has been identifiable. In general, these nodules grow slowly throughout the years and increase in number.

Scrotal calcinosis though commonly seen in the 3rd and 4th decade of life, but also reported in adult and pediatric

age groups between 9 and 85 years.⁹ In our study, common age group was the 3rd and 4th decade which correlates with literature. Scrotal calcinosis is more common among dark colored race. The most common presentation is scrotal nodule, which do not cause major symptoms. In our study also scrotal nodule was most common complain. The patient usually visits doctor because of cosmetic concern. A few patients may have pruritis, ulceration, and chalky discharge. Clinically, it can be confuse with calcified oncocercoma.¹⁰

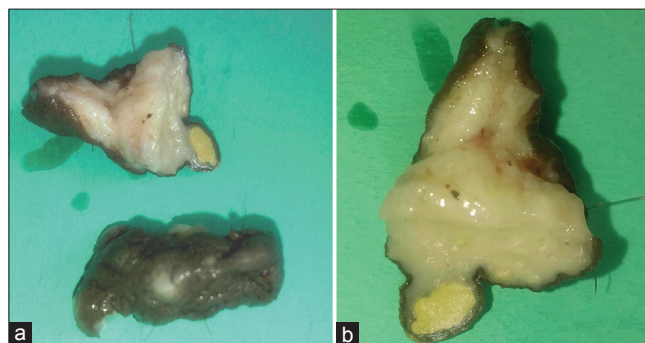


Figure 1: (a) Gross-skin covered scrotal nodule, (b) cut surface showing whitish areas

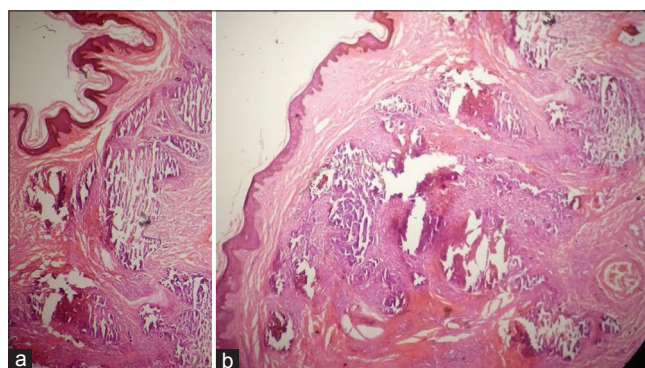


Figure 2: Photomicrograph showing calcified nodules in dermis. (a) H and E, x10, (b) H and E, x40

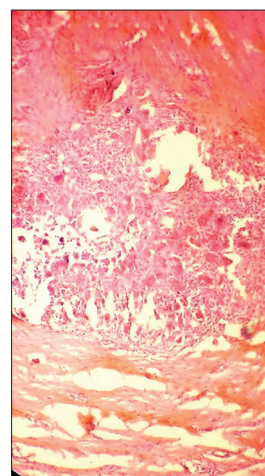


Figure 3: Photomicrograph showing giant cell and inflammatory cell (H and E x100)

Table 1: Age distribution

Age group	Age in years
0-20	01
21-40	15
41-60	02
61-80	02

Table 2: Clinical features

Clinical presentation	Number of patients	Percentage
Symptomless	04	20
Scrotal nodule	15	75
Pruritis	03	15
Chalky white	01	05
Ulceration	None	-

Solitary neurofibroma, ancient schwannomas, steatoma. Histological examination is necessary to differentiate scrotal calcinosis from these lesions.

Pathogenesis of scrotal calcinosis is controversial in this study all the biochemical investigations were within normal limits. These rules out the possibility of metastatic calcification. Hence, this calcification may result due to the presence of pathological lesion (dystrophic calcification) or occur in the absence of a known underlying pathology (idiopathic calcification). On histological examination of our 20 cases, we found calcified basophilic deposits with foreign body giant cell reaction all around (100%), minimal to florid monocyctic, histiocytic inflammatory infiltrate around deposits. Deposits of calcium were separated by fibrous tissue; keratin was not found admixed with these deposits. No cyst or cyst wall was found in any of our case. This indicates towards idiopathic etiology of scrotal calcinosis.¹¹ Idiopathic etiology was first established by Shapiro *et al.* in 1970 in his study of 35 cases. All immunohistochemical and histopathological studies demonstrate that scrotal calainosis is idiopathic.¹² Some literatures show presence of cyst wall of stratified squamous epithelium.¹³

Recurrence after surgery is not usual in scrotal calcinosis. However, some authors^{14,15} have reported recurrence in scrotal calcinosis. In our case, there was no recurrence until 9 months to 3 years of surgery. The good esthetic result was obtained.

CONCLUSION

Idiopathic scrotal calcinosis is a benign mass with a debatable pathogenesis. Surgical excision is the treatment of

choice, which is required also from an aesthetic perspective. The peak incidence is in the 3rd and 4th decade which is same as for testicular tumors which has good prognosis if detected early. This makes necessity to investigate all the patients with scrotal nodules.

REFERENCES

1. Dubey S, Sharma R, Maheshwari V. Scrotal calcinosis: Idiopathic or dystrophic? Dermatol Online J 2010;16:5.
2. Parlakgumus A, Canpolat ET, Caliskan K, Colakoglu T, Yildirim S, Ezer A, *et al.* Scrotal calcinosis due to resorption of cyst walls: A case report. J Med Case Rep 2008;2:375.
3. Shapiro L, Platt N, Torres-Rodríguez VM. Idiopathic calcinosis of the scrotum. Arch Dermatol 1970;102:199-204.
4. Swinehart JM, Golitz LE. Scrotal calcinosis. Dystrophic calcification of epidermoid cysts. Arch Dermatol 1982;118:985-8.
5. Dare AJ, Axelsen RA. Scrotal calcinosis: Origin from dystrophic calcification of eccrine duct milia. J Cutan Pathol 1988;15:142-9.
6. King DT, Brozman S, Hirose FM, Gillespie LM. Idiopathic calcinosis of scrotum. Urology 1979;14:92-4.
7. Feinstein A, Kahana M, Schewach-Millet M, Levy A. Idiopathic calcinosis and vitiligo of the scrotum. J Am Acad Dermatol 1984;11:519-20.
8. Ozgenel GY, Kahveci R, Filiz G, Ozcan M. Idiopathic scrotal calcinosis. Ann Plast Surg 2002;48:453-4.
9. Song DH, Lee KH, Kang WH. Idiopathic calcinosis of the scrotum: Histopathologic observations of fifty-one nodules. J Am Acad Dermatol 1988;19:1095-101.
10. Browne SG. Calcinosis circumscripta of the scrotal wall: The etiological role of *Onchocerca volvulus*. Br J Dermatol 1962;74:136-40.
11. Bhatnagar A, Verma V, Purohit V. Idiopathic polypoidal scrotal calcinosis leading to delay in diagnosis of testicular tumor. Niger J Surg Sci 2014;24:23-7.
12. Khallouk A, Yazami OE, Mellas S, Tazi MF, El Fassi J, Farih MH. Idiopathic scrotal calcinosis: A non-elucidated pathogenesis and its surgical treatment. Rev Urol 2011;13:95-7.
13. Yahya H, Rafindadi AH. Idiopathic scrotal calcinosis: A report of four cases and review of the literature. Int J Dermatol 2005;44:206-9.
14. Saad AG, Zaatari GS. Scrotal calcinosis: Is it idiopathic? Urology 2001;57:365.
15. Salvarci A, Altinay S. Relapsing idiopathic scrotal calcinosis. J Pak Med Assoc 2013;63:1433-4.

How to cite this article: Chaudhari S, Bhat S, Hatwal D, Bhat P, Batra N. Scrotal Calcinosis - An Etiological Dilemma: A Prospective Study. Int J Sci Stud 2015;3(7):186-188.

Source of Support: Nil, **Conflict of Interest:** None declared.