

# An Analysis of Colonoscopy Findings in a Tertiary Care Hospital

H N Dinesh<sup>1</sup>, H B Shashidhar<sup>2</sup>, Vishnu Prasad<sup>3</sup>

<sup>1</sup>Associate Professor, Department of General Surgery, Mysore Medical College and Research Institute, Mysore, Karnataka, India, <sup>2</sup>Associate Professor, Department of Pathology, Mysore Medical College and Research Institute, Mysore, Karnataka, India, <sup>3</sup>Post-graduate, Department of General Surgery, Mysore Medical College and Research Institute, Mysore, Karnataka, India

## Abstract

**Background:** Around one-fourth of the patients that come to the surgical outpatient department have lower gastrointestinal (GI) symptoms and most of them are not properly evaluated. Colonoscopy is a risk-free simple modality in which the lower GI tract can be visualized until the terminal ileum. It also has the added advantage that certain procedures can be done such as biopsy and polypectomy.

**Methods:** This was a retrospective study. Data on patients who underwent colonoscopy from March 2012 to March 2015 was evaluated; data were collected from the endoscopy register.

**Results:** About 580 patients who underwent colonoscopy during the 3-year period were evaluated. 86% of the patients tolerated the procedure under local anesthesia. Cecum could be reached in the majority (72%) of the patients. The most common indication was found out to be bleeding per rectum (37.9%). Hemorrhoids were the most common lesion found on endoscopy (23%). Most of the pathology was localized to the rectum and anal canal (34.8%). Carcinoma was proven histopathologically in 43 patients out of which 41 had adenocarcinoma, mostly arising from the rectosigmoid area. Polypectomy was successfully done in 20 patients with only one patient having rebleeding after the procedure.

**Conclusion:** Colonoscopy is a safe and effective procedure for diagnosing lower GI symptoms and should be an integral part of management.

**Key words:** Bleeding per rectum, Carcinoma, Chronic diarrhea, Colonoscopy, Polypectomy

## INTRODUCTION

Colonoscopy or coloscopy is the endoscopic examination of the large bowel and the distal part of the small bowel with a fiber optic camera on a flexible tube passed through the anus.<sup>1</sup> It can provide a visual diagnosis (e.g., ulceration, polyps) and grants the opportunity for biopsy or removal of suspected colorectal cancer lesions.

Conditions that warrant colonoscopies include lower gastrointestinal (GI) hemorrhage, unexplained changes in bowel habit and suspicion of malignancy.<sup>2</sup> Colonoscopies are

often used to diagnose colon cancer but are also frequently used to diagnose inflammatory bowel disease. In older patients (sometimes even younger ones) an unexplained drop in hematocrit is an indication for colonoscopy, usually along with an esophagogastroduodenoscopy, even if no obvious blood has been seen in the feces.

Fecal occult blood is a quick test which can be done to test for microscopic traces of blood in the stool. A positive test is almost always an indication to do a colonoscopy.<sup>3</sup> In most cases the positive result is just due to hemorrhoids; however, it can also be due to diverticulosis, inflammatory bowel disease (Crohn's disease, ulcerative colitis), colon cancer, or polyps. Polypectomy has become a routine part of colonoscopy, allowing for quick and simple removal of polyps without invasive surgery.<sup>4</sup>

Hundreds of patients every year undergo colonoscopy in K. R. Hospital for various indications. No data was available correlating the clinical features with the colonoscopic

### Access this article online



www.ijss-sn.com

Month of Submission : 08-0000  
Month of Peer Review : 09-0000  
Month of Acceptance : 10-0000  
Month of Publishing : 10-0000

**Corresponding Author:** Dr. Vishnu Prasad, #50, "Sree Krishna," 1<sup>st</sup> Main Road, Yadavagiri - 570 002, Mysore, Karnataka.  
Phone: +91-9845508147. E-mail: its\_me\_vishnu@yahoo.co.in

findings. Hence, this study was done to analyze the role of colonoscopy in diagnosing lesions in patients who presented with lower GI symptoms.

## MATERIALS AND METHODS

It was a retrospective study carried out from March 2012 to March 2015 in K. R. Hospital, Mysore. K. R. Hospital is a tertiary care hospital located in the heart of Mysore, Karnataka. It serves mostly lower socioeconomic status patients.

### Patients and Exclusion

A total of 620 patients underwent colonoscopy from March 2012 to March 2015. Data on patients who underwent the procedure was collected from the registry. Informed consent was taken from each patient, and ethical clearance was obtained from the ethics committee of Mysore medical college and research institute. All patients in which the colonoscopy was abandoned because of inadequate bowel preparation were excluded from the study. Patients who underwent repeat colonoscopies were excluded. Finally, the patients who could not tolerate the procedure because of the pain were excluded subsequently.

### Data Recording and Statistics

Data were obtained from the colonoscopy register maintained in the endoscopy room. Recorded information included demographic data (age, sex), indication for colonoscopy, preparation used for bowel lavage, type of anesthesia used, endoscopic findings, extent reached, procedure done, and histopathology (if done).

Biopsies were done at the discretion of the endoscopist. The pathological examination was done by an expert pathologist. The data were analyzed and reported in the form of tables and graphs.

## RESULTS

A total of 620 patients underwent colonoscopy over the 3-year period. Data were collected from 580 patients after excluding the rest using the exclusion criteria.

### Patient Characteristics

384 patients (65.51%) were male, 196 (33.79%) female (Graph 1). Age ranged from 16 to 84 years with mean  $43 \pm 15$ . Bleeding per rectum was the most common indication (37.9%). The second most common indication was chronic diarrhea (17%) followed by clinical suspicion of irritable bowel syndrome (13.7%). The various indications for which colonoscopy was done is mentioned in Table 1. 500 patients underwent colonoscopy under local anesthesia with monitoring of pulse and oxygen saturation. Rest 80 patients (age group 16-24) needed sedation with

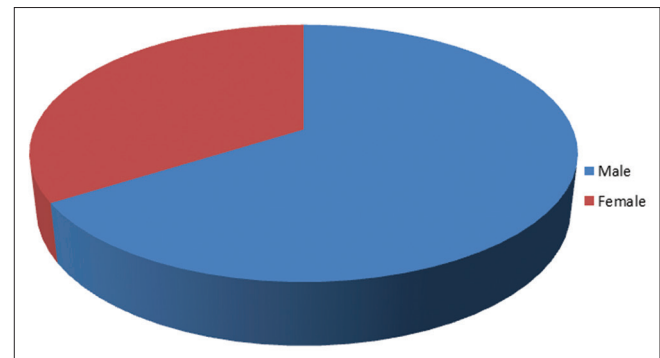
monitoring which was decided beforehand. All patients were prepared with a 1 day prior low roughage diet, laxative at night, and polyethylene glycol bowel purgative.

### Colonoscopy Findings

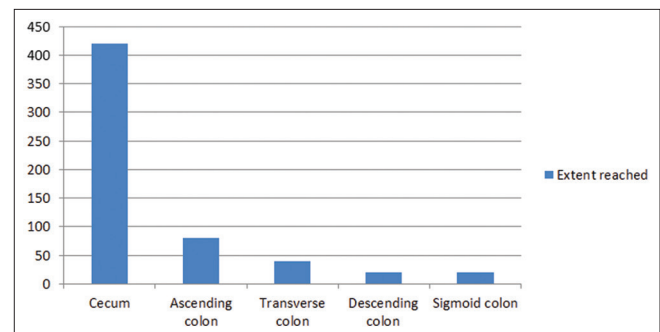
Colonoscopy was done until the cecum in 420 patients (72.4%). In 3.4% of the patients the scopy was done only until the sigmoid colon. The extent reached has been shown in Graph 2. Hemorrhoids was the most common finding in endoscopy (23.1%) followed by polyp (14.4%). 25% of the patients had a normal study. The various lesions found have been tabulated (Table 2). Colonoscopic picture of polyps is shown in Figures 2 and 3. Most of the lesions were found to be in the Rectum and anal canal (34.8%) followed by sigmoid colon (86%). Cecum had 18.75% of lesions. The location of the lesions and the relative frequency has been tabulated (Table 3). 164 lesions were sent for histopathology (excluding polyps),

**Table 1: Indications for colonoscopy**

Indications	n (%)
Per rectal bleeding	144 (24.8)
Irritable bowel syndrome	100 (17.2)
Alteration of bowel habits	87 (15)
Anaemia for evaluation	86 (14.82)
Chronic diarrhoea	79 (13.62)
Pain	44 (7.58)
Constipation	24 (4.13)
Mass lesion	16 (2.75)
Total	580 (100)



**Graph 1: Sex ratio**



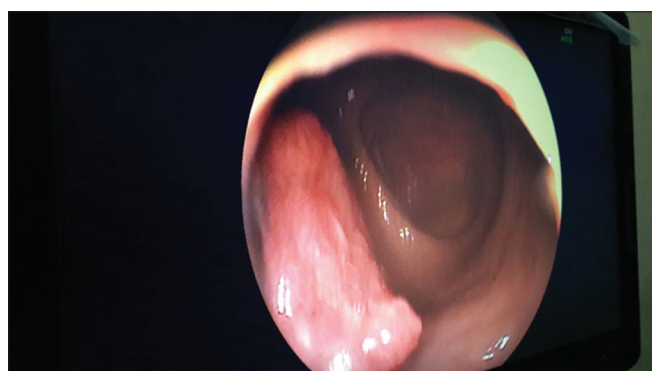
**Graph 2: Extend reached**

and 41 lesions turned out to be carcinoma. 39 lesions were adenocarcinoma (95.1%), one melanoma, and

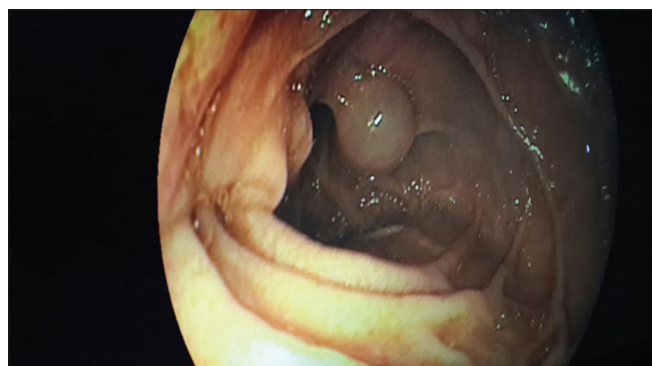
**Table 2: Findings in colonoscopy**

Findings	n (%)
Haemorrhoids	134 (23.1)
Polyp	84 (14.4)
Non-specific colitis	74 (12.75)
Ileocecal TB	63 (10.86)
Carcinoma	41 (7.06)
Ulcerative colitis	20 (3.44)
Miscellaneous (diverticulum, stricture, increased hyperemia)	15 (2.58)
Normal	149 (25.68)
Total	580 (100)

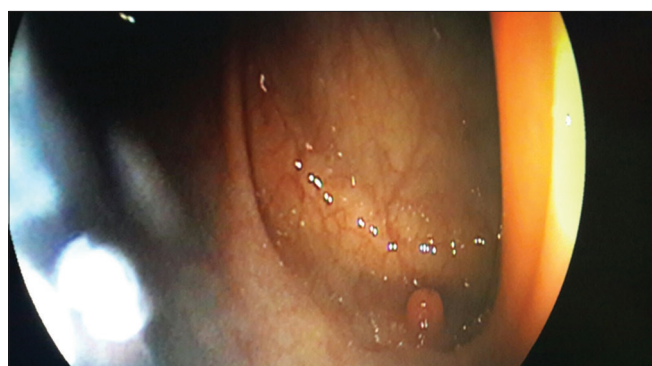TB: Tuberculosis



**Figure 1: Proliferative growth in sigmoid colon**



**Figure 2: Polyp descending colon**



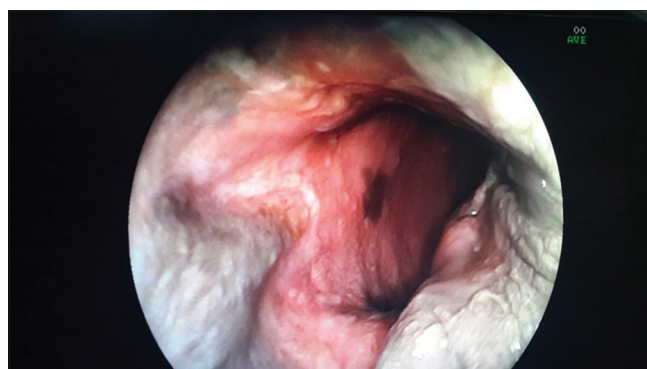
**Figure 3: Polyp transverse colon**

one squamous cell carcinoma. Colonoscopy picture of growth in the sigmoid colon is shown in figure and anal canal melanoma is shown in Figures 4 and 5. Carcinoma was found mostly in the rectum (18 patients), followed by sigmoid colon (Figure 1) (8). The histopathological

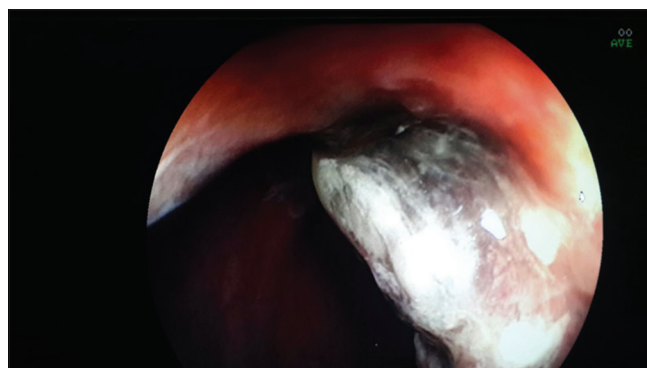
**Table 3: Pathological site of lesion**

Site of lesion	n (%)
Rectum and anal canal	145 (34.8)
Sigmoid colon	86 (20.67)
Cecum	78 (18.75)
Descending colon	45 (10.8)
Ascending colon	40 (9.61)
Transverse colon	22 (5.28)
Total	416 (100)

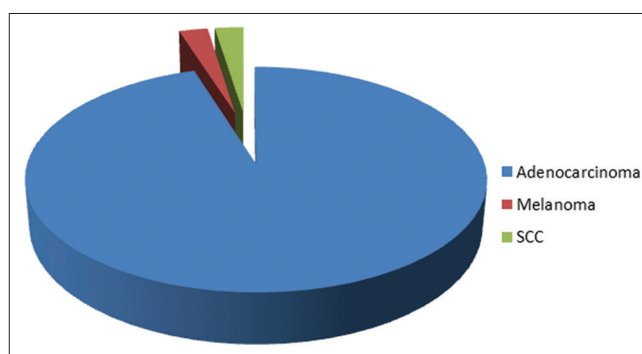
164 patients had normal study



**Figure 4: Anorectal melanoma**



**Figure 5: Anorectal melanoma (2<sup>nd</sup> pic)**



**Graph 3: Histopathology**



picture has been demonstrated in Graph 3. Polypectomy was done in 20 patients and histopathology of polyp showed hyperplastic polyp in 10 patients, villous in five, tubular in 4 and tubulovillous in one patient. One patient had recurrent bleeding after polypectomy which stopped with conservative management. Coming to individual indications, most common cause identified in bleeding per rectum patients was hemorrhoids; 92 patients (63.8%) followed by polyp (27.7%). Carcinoma accounted for 4 cases of bleeding. Patients with irritable bowel syndrome and altered bowel habits had normal study in 64.1% of the cases. Most common lesion identified was non-specific colitis (16%) followed by tuberculosis (TB) (9%). Cause of anemia was found out to be hemorrhoids in 48.8% of the patients. In patients with chronic diarrhea the most common finding was non-specific colitis (40.2%) followed by ulcerative colitis in 4 patients.

## DISCUSSION

Colonoscopy is an established procedure in the work up and screening of patients with lower GI symptoms.<sup>5-7</sup> The demand for colonoscopy has been increasing over the years given the relative safety and the low complication rate associated with the procedure.<sup>8-10</sup>

The American cancer society recommends, starting at the age of 50 years, for both men and women that they undergo a flexible sigmoidoscopy every 5 years or a colonoscopy every 10 years.<sup>11</sup> People with a family history of colon cancer are often first screened during their teenage years. Among people who have had an initial colonoscopy that found no polyps, the risk of developing colorectal cancer within 5 years is extremely low. Therefore, there is no need for those people to have another colonoscopy sooner than 5 years after the first screening.<sup>12,13</sup> Colonoscopy screening prevents approximately two-thirds of the deaths due to colorectal cancers on the left side of the colon, and is not associated with a significant reduction in deaths from right-sided disease.<sup>1</sup>

Colonoscopy is similar to sigmoidoscopy the difference being related to which parts of the colon each can examine. A colonoscopy allows an examination of the entire colon (1200-1500 mm in length). A sigmoidoscopy allows an examination of the distal portion (about 600 mm) of the colon, which may be sufficient because benefits to cancer survival of colonoscopy have been limited to the detection of lesions in the distal portion of the colon.<sup>2,3</sup>

Five in 1000 people who have a colonoscopy have a serious complication.<sup>14</sup> Perforation of the colon occurs at a rate of about 1 in 1000 procedures, and death at a rate of 1 in 3300

to 1 in 333000; therefore, in some low-risk populations, screening in the absence of symptoms would not outweigh the risks of the procedure. In a 2006 study of colonoscopies done from 1994 to 2002, Levin *et al.*, found serious complications occurred in 5.0 of 1000 colonoscopies,<sup>14</sup> comprising 0.8 in 1000 colonoscopies without biopsy or polypectomy, and a rate of 7.0/1000 for colonoscopies with biopsy or polypectomy; although McDonnell and Loura criticize this rate as being unacceptably high.<sup>15</sup> During colonoscopies where a polyp is removed (a polypectomy), the risk of complications has been higher, although still very uncommon, at about 2.3%.<sup>16</sup> One of the most serious complications that may arise after colonoscopy is the postpolypectomy syndrome. This syndrome occurs due to potential burns to the bowel wall when the polyp is removed. It is, however, a very rare complication and as a result patients may experience fever and abdominal pain. The condition is treated with intravenous fluids and antibiotics while the patient is recommended to rest.

This study highlights several features observed on colonoscopy. The male:female ratio is inconsistency with other studies.<sup>17</sup> It has been observed that there are more indications in men than women for undergoing colonoscopy. Age wise it has been seen that colonoscopy has been done more for adult patients (mean age 45) which is not consistent with other studies where the younger population was involved.<sup>17</sup>

The indications that were evaluated were similar to what other studies revealed with the most common indication in our study being bleeding per rectum with a yield of 72%.<sup>18</sup> Hemorrhoids were the most common cause found for such bleeding and is consistent with the review of the literature.<sup>19</sup>

Cecum was the extent reached in 72% which is similar to other studies.<sup>20</sup> Most of the lesions were limited to the rectum and anal canal, the reason being that hemorrhoids was the most common lesion found in the study.

Colorectal cancer was identified in 41 patients after histopathological examination. That is a significant percentage as compared to other studies.<sup>21</sup> The increased incidence of carcinoma in our study could be attributed to the increased mean age of patients and also considering the fact that K. R. hospital mainly tenders to the lower socioeconomic population. Most patients come at a late stage where carcinoma is advanced. One single case of anal canal melanoma was also identified but most other carcinomas where adenocarcinoma, mostly arising from the rectum or the sigmoid colon. In patients who came with evaluation of chronic anemia right-sided colonic cancer was found out to be more, as anemia is usually the presentation of right-sided colonic tumors.

Patients who came with mass per abdomen had a more of TB picture, which was confirmed by histopathology. Carcinoma was identified only in a few patients. This highlights the need for early colonoscopy in patients especially in the elderly where early carcinoma can be diagnosed.

The limitations of the study included lack of facility to do colonoscopy under sedation in all the cases, hence many patients were excluded because they couldn't tolerate the pain and the study were hence abandoned and was referred elsewhere. Furthermore, around two surgeons did the colonoscopy; hence there could have been observer bias and bias in taking decision for biopsy.

## CONCLUSION

Colonoscopy forms an important modality in the workup for a patient presenting with lower GI symptoms. As seen in our study the yield is significant with only a few cases having a normal study. Case selection and stratification of patients based on the need can further increase the yield. It is a simple procedure, can be done under local anesthesia or under mild sedation. Records can be kept to see how the lesions react to further therapy. Added advantage of colonoscopy is that therapeutic procedures like polypectomy, removal of foreign body can be done with minimal risk. It was also a safe study as proven in our study with minimal complications and post study pain.

## REFERENCES

1. Baxter NN, Goldwasser MA, Paszat LF, Saskin R, Urbach DR, Rabeneck L. Association of colonoscopy and death from colorectal cancer. *Ann Intern Med* 2009;150:1-8.
2. Singh H, Nugent Z, Mahmud SM, Demers AA, Bernstein CN. Surgical resection of hepatic metastases from colorectal cancer: A systematic review of published studies. *Am J Gastroenterol* 2010;105:663-73.
3. Brenner H, Hoffmeister M, Arndt V, Stegmaier C, Altenhofen L, Haug U. Protection from right- and left-sided colorectal neoplasms after colonoscopy: Population-based study. *J Natl Cancer Inst* 2010;102:89-95.
4. Atkin WS, Edwards R, Kralj-Hans I, Wooldrage K, Hart AR, Northover JM, *et al.* Once-only flexible sigmoidoscopy screening in prevention of colorectal cancer: A multicentre randomised controlled trial. *Lancet* 2010;375:1624-33.
5. Berkowitz I, Kaplan M. Indications for colonoscopy. An analysis based on indications and diagnostic yield. *S Afr Med J* 1993;83:245-8.
6. Future requirements for colonoscopy in Britain. Report by the Endoscopy Section Committee of the British Society of Gastroenterology. *Gut* 1987;28:772-5.
7. Linda L, Manning Dimmitt DO, Steven G, Goerge R, Wilson MD. Diagnosis of gastrointestinal bleeding in adults. *J Am Acad Fam Physicians* 2005;71:1339-46.
8. Al-Nakib B, Radhakrishnan S, Jacob GS, Al-Liddawi H, Al-Ruwaihi A. Inflammatory bowel disease in Kuwait. *Am J Gastroenterol* 1984;79:191-4.
9. Wolff WI. Colonoscopy: History and development. *Am J Gastroenterol* 1989;84:1017-25.
10. Gane EJ, Lane MR. Colonoscopy in unexplained lower gastrointestinal bleeding. *N Z Med J* 1992;105:31-3.
11. American Cancer Society Guidelines for the Early Detection of Cancer. <http://www.cancer.org/healthy/findcancerearly/cancerscreeningguidelines/american-cancer-society-guidelines-for-the-early-detection-of-cancer>.
12. Imperiale TF, Glowinski EA, Lin-Cooper C, Larkin GN, Rogge JD, Ransohoff DF. Five-year risk of colorectal neoplasia after negative screening colonoscopy. *N Engl J Med* 2008;359:1218-24.
13. No Need to Repeat Colonoscopy until 5 Years after First Screening. News wise. Available from: <http://www.newswise.com/articles/no-need-to-repeat-colonoscopy-until-5-years-after-first-screening>. [Last accessed on 2008 Sep 17].
14. Levin TR, Zhao W, Conell C, Shapiro JA, Schulman J, *et al.* Complications of colonoscopy in an integrated health care delivery system. *Ann Intern Med* 2006;145:880-6.
15. McDonnell WM, Loura F. Complications of colonoscopy. *Ann Intern Med* 2007;147:212-3.
16. Colonoscopy Risks. <http://ibderohns.about.com/od/colonoscopy/p/colonoscopy.htm>. [Last retrieved on 2010 Nov 02].
17. Katon RM. Experimental control of gastrointestinal hemorrhage via the endoscope: A new era dawns. *Gastroenterology* 1976;70:272-7.
18. Rex DK. Colonoscopy. *Gastrointest Endosc Clin N Am* 2000;10:135-60.
19. Isbister WH. Colonoscopy – A ten year Wellington experience. *N Z Med J* 1987;100:74-7.
20. Al-Shamali MA, Kalaoui M, Hasan F, Khajah A, Siddique I, Al-Nakeeb B. Colonoscopy: Evaluating indications and diagnostic yield. *Ann Saudi Med* 2001;21:304-7.
21. Segal WN, Greenberg PD, Rockey DC, Cello JP, McQuaid KR. The outpatient evaluation of hematochezia. *Am J Gastroenterol* 1998;93:179-82.

**How to cite this article:** Dinesh HN, Shashidhar HB, Prasad V. An Analysis of Colonoscopy Findings in a Tertiary Care Hospital. *Int J Sci Stud* 2015;3(7):212-216.

**Source of Support:** Nil, **Conflict of Interest:** None declared.