

# Evaluation of Diode Laser in the Treatment of Fibroepithelial Polyp: A Case Report

Nitin Agarwal<sup>1</sup>,  
Devika Singh<sup>2</sup>,  
Siddharth Saurabh<sup>3</sup>,  
Sunita Srivastava<sup>4</sup>,  
Ankit Saha<sup>2</sup>,  
Debanti Giri<sup>2,5</sup>

<sup>1</sup>Professor and Head, Department of Oral Medicine and Radiology, Sardar Patel Post-graduate Institute of Dental and Medical Sciences, Lucknow, Uttar Pradesh, India, <sup>2</sup>Post-graduate Student, Department of Oral Medicine and Radiology, Sardar Patel Post Graduate Institute of Dental and Medical Sciences, Lucknow, Uttar Pradesh, India, <sup>3</sup>Senior Lecturer, Department of Oral Medicine and Radiology, RKDF Dental Collage, Bhopal, Madhya Pradesh, India, <sup>4</sup>Senior Lecturer, Department of Oral Medicine and Radiology, Sardar Patel Post Graduate Institute of Dental and Medical Sciences, Lucknow, Uttar Pradesh, India, <sup>5</sup>Post-graduate Student, Department of Oral Medicine and Radiology, Sardar Patel Post-graduate Institute of Dental and Medical Sciences, Lucknow, Uttar Pradesh, India

**Corresponding Author:** Dr. Nitin Agarwal, Department of Oral Medicine & Radiology, Sardar Patel Post Graduate Institute of Dental and Medical Sciences, Rae Bareilly Road, Lucknow, Uttar Pradesh, India. E-mail: nitinmds@yahoo.com

## Abstract

Laser first came into light in 1960 and has been used extensively in various fields of medicine. Since its invention, it has been experimented with in dental field and varying results have been seen, but now, with the advancements in the use of lasers, its utility is being recognized in the dentistry as well. Lasers are widely used for a number of procedures like cavity preparation, scaling and root planning, surgical procedures like excision of soft tissue growths etc. Improved healing, hemostasis and sutureless excisions are some of the many advantages of laser over conventional treatment modalities. It is because of these advantages that laser is becoming more and more popular as a treatment option in various aspects of dentistry. We hereby present a case report, where we have used diode laser for surgical management of a fibroepithelial polyp, because of its many advantages over conventional methods. Fibroepithelial polyp is most commonly seen at the site of trauma in mouth or in other areas of body. This polyp is usually not harmful and does not grow in size. However, at times, these tags may need to be surgically excised for aesthetic and functional purposes or for the fear of malignancy.

**Keywords:** Diode laser, Fibroepithelial polyp, Surgical excision

## INTRODUCTION

Chronic and recurrent tissue irritation causes excessive tissue response resulting in reactive lesions that are clinically and histopathologically categorized as non-neoplastic swellings. Some of the common examples are pyogenic granuloma, fibrous epulis, peripheral giant cell granuloma, fibroepithelial polyp, peripheral ossifying fibroma, giant cell fibroma, pregnancy epulis, and commonly manifest in the gingival.<sup>1,2</sup> Almost all lesions in the oral cavity that are called fibromas are not true neoplasms but are mere fibrous overgrowths caused by chronic irritation. Many authors therefore prefer the term fibroepithelial polyp or fibrous hyperplasia for these type of lesions.<sup>3</sup> There are many treatment modalities that can be used for these hyperplastic tissues such as the conventional scalpel excision, electrical surgery and the recently recognized laser surgery. Diode lasers is very

commonly used in a variety of surgical procedures and has many advantages such as reduced scar formation, less pain and bleeding, and reduced chances of infection.<sup>4</sup> Lasers have been used in medicine and dentistry since early 1960s (Husein 2006). Laser, or light amplification by stimulated emission of radiation, is a device that generates a high-intensity parallel beam of monochromatic electromagnetic radiation. There are different types of lasers that are currently being used in dentistry depending on their wavelength range and their absorption. Carbon dioxide (CO<sub>2</sub>), erbium-Yttrium-aluminum-garnet (YAG) lasers are absorbed by water because of which there is minimal penetration responsible for fast heating, with effective removal of soft and hard tissue. CO<sub>2</sub> lasers are mainly used as laser scalpels for the excision of tumors from soft tissues.<sup>5</sup> Laser wavelengths such as neodymium: YAG CO<sub>2</sub>, and diodes have also been used successfully for various procedures.<sup>6</sup>

We are thus presenting a case report evaluating the efficacy of diode laser in the surgical management of fibroepithelial polyp with excellent and satisfactory result without any report of recurrence or need for a separate histopathological examination.

## CASE REPORT

A 34-years-old male patient reported with the chief complaint of swelling in the left cheek region since 2 years, which was initially small in size but has gradually increased to attain its present size. There was no associated pain or secondary changes seen. The patient did not give any significant past medical and dental history.

On inspection a swelling measuring approximately 2 cm in diameter was seen on the left buccal mucosa irt 36 and 26. The swelling was pedunculated, the superficial mucosa and the surrounding area was normal (Figure 1).

On palpation, the swelling was non-tender, mobile, firm in consistency with well-defined margins.

Diode laser of 980 nm wavelength was used for the surgical excision. The laser was used in continuous mode at 2 W (Figure 2). The polyp was surgically excised using laser (Figure 3). A slight char tissue at the base of the wound was seen, this char acts a bio protective plug that has prevented bleeding and also helps to prevent infection in such wounds (Figure 4). The absence of bleeding was the most evident feature of this wound. The borders were rolled out and these borders flattened out later. The biopsy confirmed the case to be that of fibroepithelial hyperalsia (Figure 5).

The patient was recalled for follow-up after 7 days. On the 7<sup>th</sup> day follow-up, granulation tissue was seen which was sign of secondary healing (Figure 6). After 1 month, complete resolution of the lesion was seen (Figure 7).

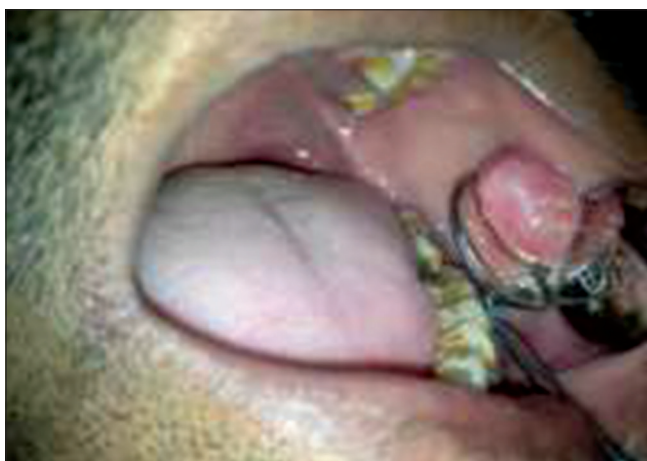

Figure 1: Fibroepithelial polyp irt left buccal mucosa

## DISCUSSION

The most common group of oral mucosal pathologies include benign neoplasm and hyperplastic fibro-epidermal tumorous lesions. The etiologies include long-term irritation, occlusal trauma, ill-fitting prosthetic appliances and habitual cheek biting. They are usually asymptomatic and in most of the cases, they remain unchanged for many years. Clinically, these reactive lesions often present diagnostic challenges to the diagnostician because they imitate various groups of pathological process. Although they are clinically similar, they differ in their histopathological features. They are often termed as “epulides” if they remain confined only to the gingiva. Almost all the fibromas of the oral cavity are not true neoplasms, but mere fibrous overgrowths caused by chronic irritation.<sup>7</sup> Many authors therefore prefer the term fibroepithelial polyp or fibrous hyperplasia for these type of lesions. Cooke named all such swellings of the mucosal surface as “polyp” (fibro epithelial polyp), with maximum




Figure 2: Laser settings

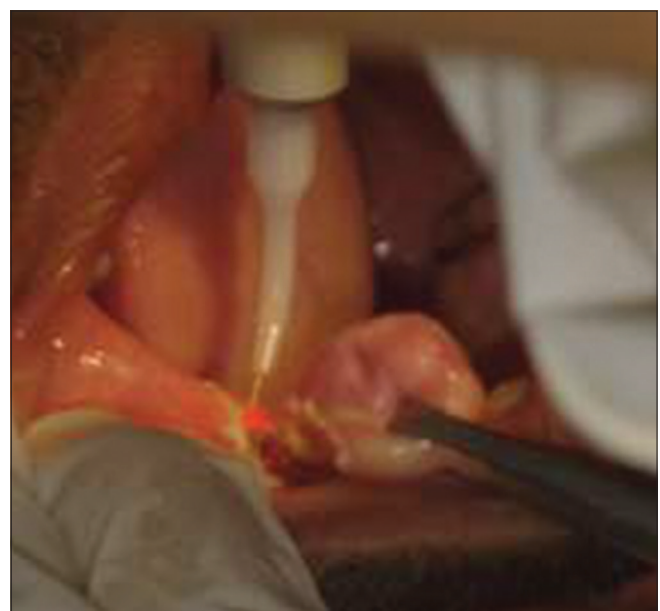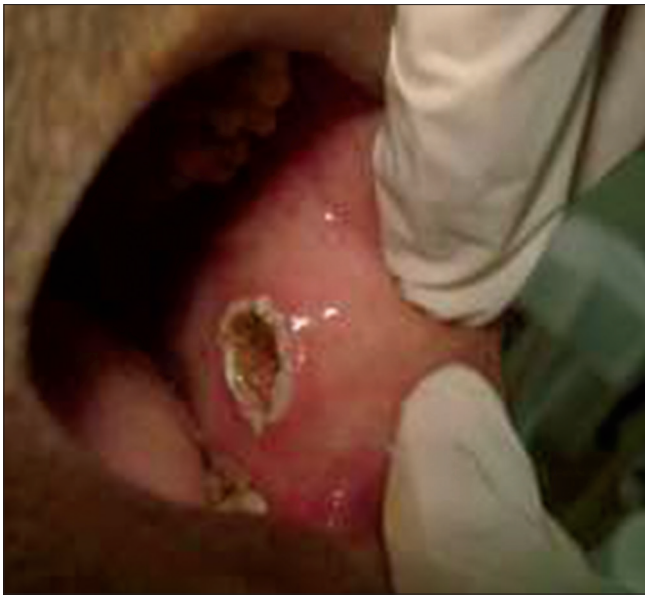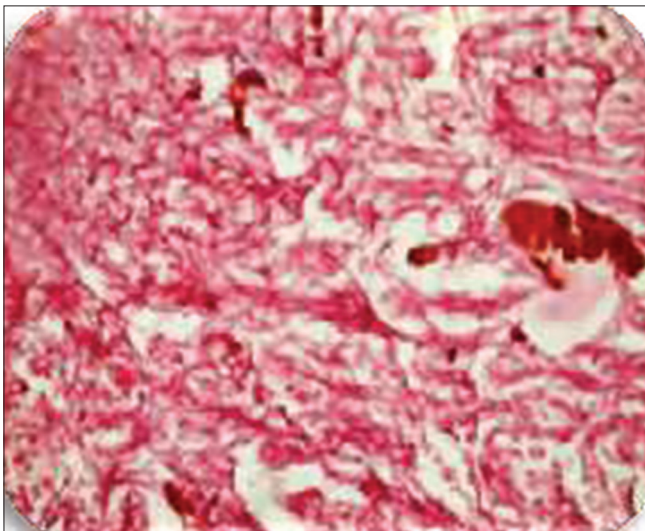


Figure 3: Surgical excision of fibroepithelial polyp using diode laser





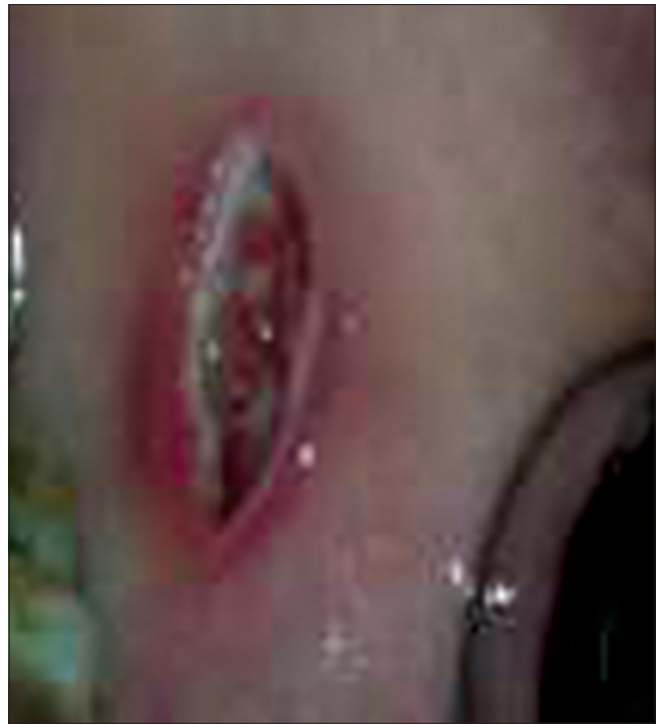**Figure 4: Post surgery carbonization present at the base of the wound**



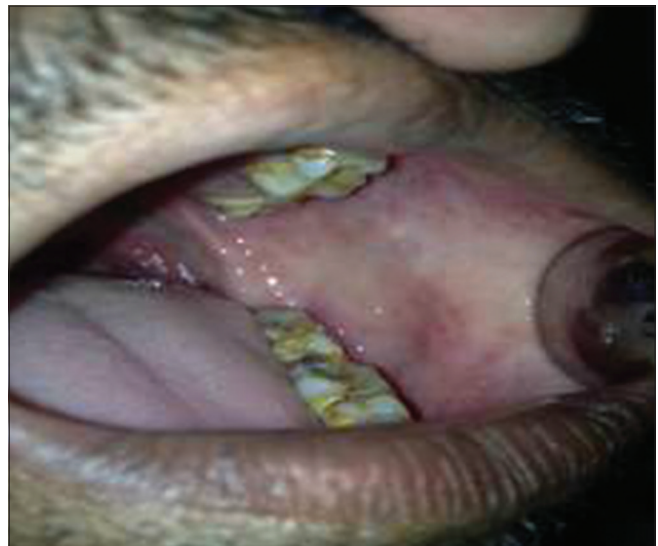**Figure 5: Histopathological slide showing bundles of collagen formation and moderately cellular connective tissue confirming the diagnosis of fibroepithelial polyp**

number of lesions occurring long the line of occlusion.<sup>8</sup> Histological features include a focal sub-epithelial mass of fibrous connective tissue which contains interlacing or parallel bundles of collagen, with occasional vascular channel and inflammatory infiltrate. The fibroblast are narrow, elongated and relatively few. Recurrence rate of such lesions is very low.<sup>9</sup>

There are many different kinds of treatment modalities that may be followed for management of these hyperplastic tissues, such as scalpel excision, electrical surgery. In most cases where conventional surgery is done, complications such as intraoperative bleeding, difficulties in wound



**Figure 6: Seven day follow-up showing healthy granulation tissue at the floor of the wound**



**Figure 7: One month follow-up showing complete healing of the wound**

healing and maintenance of sterility during surgery are very commonly seen. With the recent advancements and developments in the field of lasers diode lasers has become the choice of treatment for excision of such benign tissue growths. Diode lasers have been used in a variety of soft tissue surgical procedures mainly because of its ability to decontaminate and bactericidal property which is responsible for lesser pain and swelling and post-operative analgesia. Other advantages includes reduced scar formation and lesser bleeding which provides a bloodless

field thus allowing the surgeon to get a better view of the field of operation.

As a result of improved healing and hemostasis, intraoral laser wounds can often be left without sutures, healing by secondary intention which is the most effective healing method when the wound involves multiple layers of mucosa.

In the present case we evaluated the advantages of diode laser for the treatment of fibro epithelial polyp, where the results that we obtained were excellent. The patient did not report recurrence of the tissue growth thereby eliminating the need for another histopathological examination.

## CONCLUSION

Diagnosis of such reactive hyperplastic gingival lesion is based on formulation of a correct differential diagnosis to allow accurate evaluation and management of these lesions. These lesions must be clinically and histologically differentiated from precancerous, developmental and neoplastic lesions. Laser is often used as a successful treatment modality for obtaining biopsy specimens. The application of lasers as a substitute of soft tissue surgeries is also gaining more and more recognition. Laser treatments

have been shown to be superior over conventional mechanical approaches because of its ability to easily ablate, decontaminate and better hemostasis, as well as less surgical and post-operative pain in soft tissue management.

## REFERENCES

1. Shafer WG, Hine MK, Levy BM. Benign and malignant tumors of oral cavity. In: Rajendran R, Shivapathasundaram B, editors. *Shafer's Textbook of Oral Pathology*. 5<sup>th</sup> ed. New Delhi: Elsevier; 2007. p. 178-80.
2. Regezi JA, Sciubba JJ. Connective tissue lesions. *Oral Pathology: Clinical Pathologic Correlations*. 5<sup>th</sup> ed. St. Louis: Saunders, Elsevier; 2008. p. 155-78.
3. Prasanna JS, Sehrawat S. Fibroepithelial hyperplasia: Rare, self-limiting condition – Two case reports. *J Adv Oral Res* 2011;2:63-70.
4. Asnaashari M, Azari-Marhaba S, Alirezaei S, Asnaashari N. Clinical application of 810 nm diode laser to remove gingival hyperplastic lesion. *J Lasers Med Sci* 2013;4:96-8.
5. Bhandari R, Singla K, Sandhu SV, Malhotra A, Kaur H, Pannu AK. Soft tissue application of lasers: A review. *Int J Dent Res* 2014;2:16-9.
6. Desai S, Jesse J. Analysis of soft tissue healing after Er, Cr: YSGG laser treatment. *clinical techniques in dentistry. Contemp Esthet Restor Pract* 2005;34-5. Available from: <http://www.dyadent.com.ec/downloads/biolasedownloads/Tejidos%20Blandos%20Waterlase.pdf>. [Last accessed 2014 Jan 15]
7. Tyldesley WR. Oral medicine for the dental practitioner 7. Inflammatory overgrowths and neoplasms. *Br Dent J* 1974;136:111-6.
8. Cooke BE. The fibrous epulis & the fibro epithelial polyp: Their histogenesis & natural history. *Br Dent J* 1952;93:305-9.
9. Shamim T, Varghese VI, Shameena PM, Sudha S. A retrospective analysis of gingival biopsied lesions in South Indian population: 2001-2006. *Med Oral Patol Oral Cir Bucal* 2008;13:E414-8.

**How to cite this article:** Agarwal N, Singh D, Saurabh S, Srivastava S, Saha A, Giri D. Evaluation of Diode Laser in the Treatment of Fibroepithelial Polyp: A Case Report. *Int J Sci Stud* 2014;2(6):134-137.

**Source of Support:** Nil, **Conflict of Interest:** None declared.