Case Report

DOI: 10.17354/ijss/2015/427

Peripheral Ossifying Fibroma of the Posterior Maxilla: A Rare Case Report

P Rajesh Raj[1], Esha Nausheen[1], Nadah Najeeb Rawther[1], Jittin James[2]

[1]Post-graduate Student, Department of Oral Medicine and Radiology, Mar Baselios Dental College, Ko thamangalam, Kerala, [2]Senior Lecturer, Department of Prosthodontics, Mar Baselios Dental College, Kothamangalam, Kerala

Abstract

Arriving at a correct diagnosis of lesions with the similar clinical presentation is a tricky business. Localized gingival overgrowths, one of the most common encountered lesions in the oral cavity, has to be studied carefully to differentiate between pyogenic granuloma, irritation fibroma, peripheral central giant cell granuloma, and peripheral ossifying fibroma (POF). POF is a reactive lesion of the oral cavity which has been described under various names like cement-ossifying fibroma (OF), peripheral cemental OF, occurs in about 9% of all gingival growths, usually seen in anterior maxilla followed by anterior mandible and is more prevalent in females. Etiological factors include chronic irritation or trauma due to faulty restorations, ill-fitting dentures and calculus. This is a case presentation of POF seen in the posterior maxilla of a 13-year-old female patient. Surgical excision followed by histopathological confirmation was done to arrive at the diagnosis.

Key words: Bone neoplasm, Fibroma, Ossifying fibroma, Pyogenic granuloma, Swelling

INTRODUCTION

Fibromas are benign tumors that are composed of fibrous or connective tissue. Peripheral ossifying fibroma (POF) accounts for about 3.1% of all oral cavity tumors and about 9.6% of gingival overgrowths.[1-3]

Ossifying fibroma (OF) is classified as a benign bone neoplasm. It is considered to be a type of fibro-osseous lesion. It consists of highly cellular and fibrous components along with varying amounts of calcified tissue that resembles bone, cementum or both. In 1968, Hamner *et al.* analyzed 249 cases of fibro-osseous jaw lesions of periodontal membrane origin and classified them. In 1973, Waldron and Giansanti reported 65 cases and concluded that this group of lesions was best described as lesions arising from cells in the periodontal ligament.[4,5]

There are two types of OFs: The central type and peripheral type. The central type is believed to originate from the endosteum and periodontal ligament around the root apex and subsequently causes expansion of the medullary cavity.[1] The peripheral type on the other hand arises from the periodontal soft tissue around the interdental papilla.[6]

OFs are generally seen in the second and third decade of life.[7] There is a definite predilection for the maxilla in the oral cavity and females are generally affected 2-4 times more than their male counterparts.[8] The etiology is unclear.[9] Irritation of the tissue due to ill-fitting dentures, dental plaque, calculus, masticatory forces, faulty restoration, and trauma are proposed to be the initiating factors.[7] The mineralized portion could have origination from the periosteal cells or periodontal ligament.[1]

POF appears clinically as a soft pedunculated/sessile nodular mass, pink or red in color which may or may not be ulcerated. POF is believed to be clinically and histopathologically similar to a pyogenic granuloma, but it undergoes fibrous maturation and subsequent calcification.[1] Racial predominance has been reported where 71% of whites against 31% blacks were affected.

CASE REPORT

A 13-year-old female patient reported to the Department of Oral Medicine and Radiology with the chief complaint

Access this article online

www.ijss-sn.com

Month of Submission : 07-2015
Month of Peer Review : 08-2015
Month of Acceptance : 08-2015
Month of Publishing : 09-2015

Corresponding Author: Dr. Esha Nausheen, Department of Oral Medicine and Radiology, Mar Baselios Dental College, Kothamangalam, Ernakulam, Kerala. Phone: +91-9895541308. E-mail: eshamadhu83@gmail.com

of a swelling of the gum in the upper left back tooth region since 2 months. The patient was apparently well when she noticed the swelling 2 months ago.

The swelling was gradual in onset, small in size initially and gradually increased to the present size. The growth was continuous in nature without any periods of remission or exacerbations. The swelling was associated with a gradual and continuous pain which was localized, throbbing type and mild in intensity, which aggravated on brushing. Bleeding from the swelling was also noticed while brushing. Her past medical and dental histories were non-contributory.

On intraoral examination (Figure 1), an oval shaped pedunculated swelling of size 1.8 cm × 1.2 cm with an irregular surface was seen arising from the marginal gingival of 27 extending anteroposteriorly from middle third of palatal aspect of 27-1 cm distally. The overlying mucosa was erythematous with no ulceration. On palpation, all inspectory findings were confirmed. The swelling was firm in consistency at the center and soft toward the periphery. The swelling was tender, and bleeding was noticed on palpation.

On the basis of history and clinical examination, we arrived at a provisional diagnosis of pyogenic granuloma. Clinically, the differential diagnosis of POF, traumatic fibroma, and peripheral giant cell granuloma were considered.

Radiographic and histological investigations were then carried out. The intra-oral periapical radiograph (Figure 2) and orthopantomography (Figure 3) of 27 regions revealed flecks of radio-opacity in the area distal to 27.

Following radiographic investigations, the radiographic diagnosis was decided as POF.

After routine blood examination, excision biopsy (Figure 4) was done under local anesthesia along with curettage of the periodontal ligament and periosteum to reduce the chances of recurrence.

The histopathological picture Figures 5 and 6 shows an ulcerated keratinized stratified squamous surface epithelium in association with a cellular connective tissue exhibiting spindle-shaped and stellate-shaped cells and collagen fibers, exhibiting numerous globular, hematoxiphillic calcified masses within the connective tissue. In many foci lamellated bone formation can be seen with osteocytes within osteocytic lacunae within the connective tissue.

Correlating the clinical and investigative findings a final diagnosis of the lesion was established as POF. The patient was kept under follow-up (Figure 7).

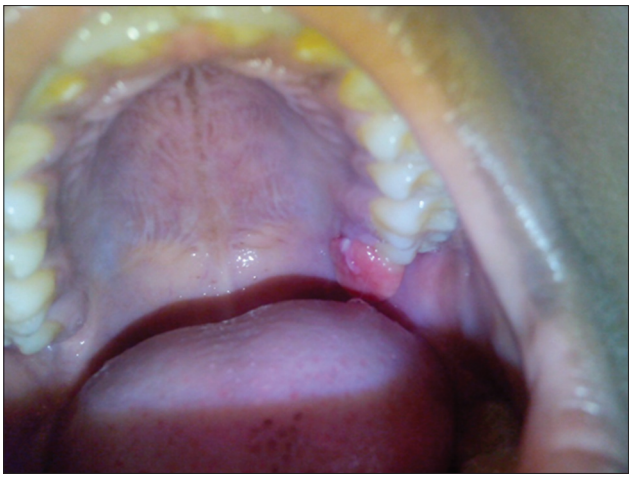

Figure 1: Intraoral picture of the lesion

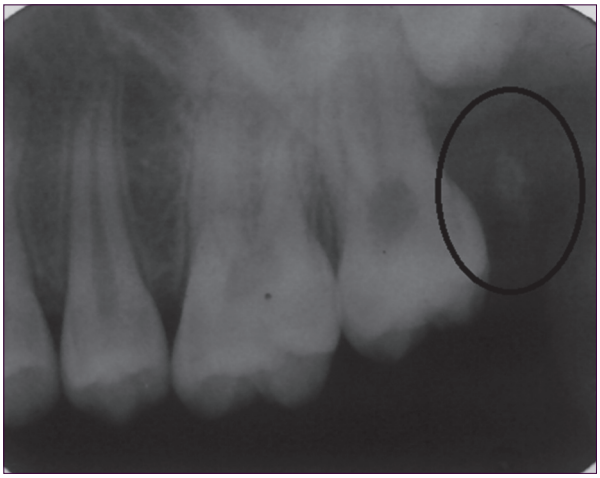

Figure 2: Intraoral periapical radiograph showing calcified flecks distal to 27

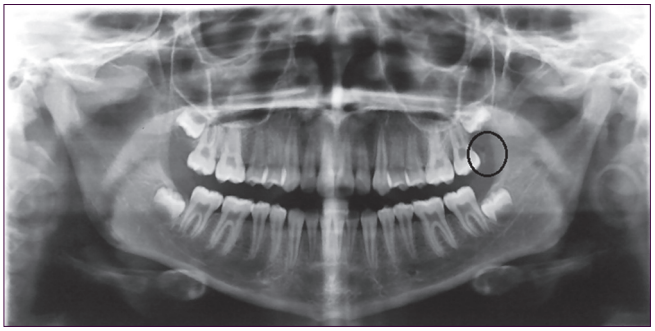

Figure 3: Orthopantomography showing calcified mass distal to 27

DISCUSSION

WHO defines POF as a demarcated or rarely encapsulated neoplasm consisting of fibrous connective tissue containing varying amounts of mineralized material resembling bone or cementum.[8]

Figure 4: The excised mass of size 1.8 cm × 1.2 cm

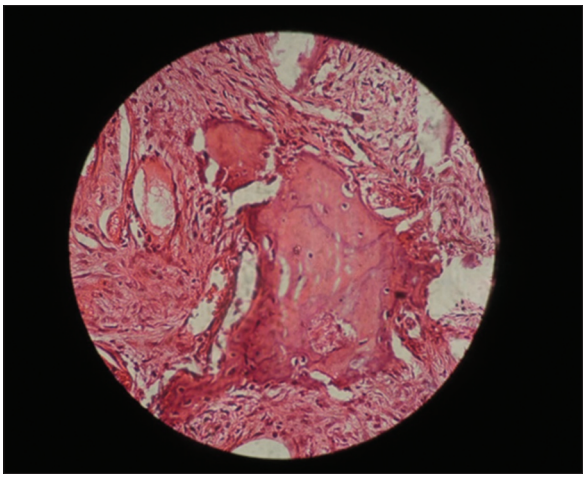

Figure 6: Histopathological picture under ×40

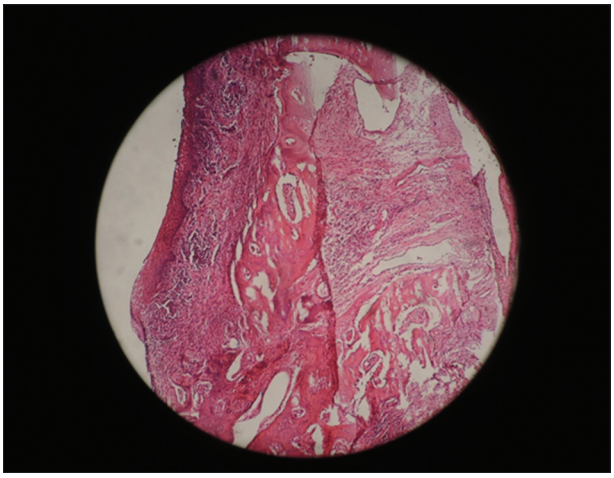

Figure 5: Histopathological picture under ×10

Figure 7: Follow-up image after 6 months

POF has been described under various names such as epulis, calcifying cementoblastic granuloma, peripheral cementifying fibroma, and peripheral fibroma with cementogenesis, peripheral cement-OF, ossifying fibroepithelial polyp, and peripheral fibroma with osteogenesis.[5,7,9] Menzel first described OF in 1872, but Montgomery assigned a name to it only in 1927. The term POF was coined by Eversol and Robin.[2,7]

Etiopathogenesis of POF has been uncertain though origin from the cells of the periodontal ligament has been suggested. This could be because of occurrence of POF exclusively in the interdental papilla; presence of oxytalan fibers in the mineralized matrix;[1,5] age distribution of the lesion is inversely proportional to the number of teeth lost and the histological picture related to the fibro cellular component is similar to the lesions arising from the gingival.[5]

POF is a fairly common lesion, comprising nearly 1-3% of oral gingival growths. Clinically, the POF presents as an exophytic, smooth surfaced, pink or red nodular mass that is sessile. These features are consistent with the findings in our case. Approximately, 60% of POFs occur in females with predilection for maxilla, and more than 50% of all cases occur in the incisor-cuspid region.[2,8] However, in our case the lesion was seen in the posterior maxilla which is unusual. Hormones seem to play a role in the progress of the lesions accounting for the female predilection.[6]

Clinically differential diagnosis for gingival growths includes fibroma, peripheral giant cell granuloma, pyogenic granuloma, peripheral odontogenic fibroma, and POF.[2,8] A confirmatory diagnosis of POF is made by histopathologic evaluation of biopsy specimens. The following features are usually observed during the microscopic examination; intact or ulcerated stratified squamous surface epithelium; benign fibrous connective tissue with varying numbers of fibroblasts; sparse to profuse endothelial proliferation; mineralized material consisting of mature, lamellar or woven osteoid, cementum-like

material or dystrophic calcifications; and acute or chronic inflammatory cells in lesions.[4]

Surgical excision is the preferred choice of treatment for POF. In addition, any identifiable irritant such as an ill-fitting dental appliance and faulty restoration should be corrected.[9]

The recurrence rate for POF has been reported to vary between 8.9% and 20%.[6] It could be because of incomplete removal during surgery, repeated injury or persistence of the local irritants. It is important to remove lesion completely including the periosteum and periodontal ligament along with the possible cause, to bring down the chances of recurrence.[10,11]

CONCLUSION

POF is benign, slowly progressive reactive lesion which is difficult to differentiate with other reactive lesions of the oral cavity. The lesion is usually seen in the anterior maxilla, but the presence of this lesion in the posterior maxilla makes this case a rare entity. Histopathologic confirmation is mandatory. Complete surgical excision down to the periosteum is the preferred treatment. As the recurrence rate is high (8-20%) close post-operative follow-up is required.[6]

REFERENCES

1. Yadav A, Mishra MB. Peripheral cemento ossifying fibroma of mandible: A case report. Indian J Stomatol 2011;26:193-6.
2. Mishra MB, Bhishen KA, Mishra S. Peripheral ossifying fibroma. J Oral Maxillofac Pathol 2011;15:65-8.
3. Verma E, Chakki AB, Nagaral SC, Ganji KK. Peripheral cemento-ossifying fibroma: Case series literature review. Case Rep Dent 2013;2013:930870.
4. Waldron CA, Giansanti JS. Benign fibro-osseous lesions of the jaw: A clinical-radiologic review of sixty-five cases. Oral Surg Oral Med Oral Pathol 1973; 35: 340-350.
5. García de Marcos JA, García de Marcos MJ, Arroyo Rodríguez S, Chiarri Rodrigo J, Poblet E. Peripheral ossifying fibroma: A clinical and immunohistochemical study of four cases. J Oral Sci 2010;52:95-9.
6. Barot VJ, Chandran S, Vishnoi SL. Peripheral ossifying fibroma: A case report. J Indian Soc Periodontol 2013;17:819-22.
7. Chaudhary A, Panat SR. Sangamath: Peripheral ossifying fibroma: A case report. J Dent Sci Oral Rehabil 2011;???:20-1.
8. Rao KV, Tanuja P, Reddy MN. Peripheral ossifying fibroma: A case report. Int J Case Rep Images 2012;32:11-4.
9. Nazareth B, Arya H, Ansari S, Arora R. Peripheral ossifying fibroma – A clinical report. Int J Odontostomat 2011;54:153-6.
10. Chhina S, Gakhar A, Mavi S, Kalra S. Peripheral ossifying fibroma: A case report & review of literature. IJSS Case Rep Rev 2015;1:61-4.
11. Jain A, Deepa D. Recurrence of peripheral ossifying fibroma: A case report. People J Sci Res 2010;3:23-5.

How to cite this article: Raj PR, Nausheen E, Rawther NN, James J. Peripheral Ossifying Fibroma of the Posterior Maxilla: A Rare Case Report. Int J Sci Stud 2015;3(6):217-220.

Source of Support: Nil, **Conflict of Interest:** None declared.