Case Report

DOI: 10.17354/ijss/2015/429

Stone in the Scrotum: Scrotal Calcinosis Cutis: A Rare Case Report

Manoananth Arivazhagan[1], Srinidhi Manjunath[2], Kanakapura Srinivasamurthy Bala Subrahmaniya[3], Basavaraju Nanjaiah[1]

[1]Post-graduate, Department of General Surgery, Mysore Medical College and Research Institute, Mysore, Karnataka, India, [2]Senior Resident, Department of General Surgery, Mysore Medical College and Research institute, Mysore, Karnataka, India, [3]Associate Professor, Department of General Surgery, Mysore Medical College and Research Institute, Mysore, Karnataka, India

Abstract

Scrotal calcinosis is a rare benign disorder involving scrotal skin resulting from deposition of calcium within the dermis. It was first described by Lewinskey in 1883. Deposition of calcium in the skin, subcutaneous tissue, muscles, and visceral organs is known as calcinosis and it more commonly involves skin and it is called calcinosis cutis. It usually presents as slow growing asymptomatic multiple hard to firm nodules. Pathogenesis is still under debate as to whether the calcification is dystrophic or idiopathic. Excision is the treatment of choice followed by primary closure or scrotal reconstruction using split-thickness skin graft. Recurrence is rare. In this article, we report a case of idiopathic scrotal calcinosis cutis which was treated by primary excision at our institute. We have also reviewed the relevant literature.

Key words: Calcifications, Calcinosis, Dermis, Scrotum, Skin diseases

INTRODUCTION

Idiopathic scrotal calcinosis is a rare benign condition with painless slow growing nodular masses within the dermis of the scrotal skin. It was first described by Lewinskey in 1883.[1-3] Deposition of calcium in the skin, subcutaneous tissue, muscles, and visceral organs is known as calcinosis, and it more common involves skin and it is called calcinosis cutis. There are four types of calcinosis cutis based on their etiology such as dystrophic, metastatic, iatrogenic, and idiopathic.[1] Age group is 20-40 years.[4-6] Various theories on pathogenesis have been proposed by authors favoring idiopathic and dystrophic calcification. In dystrophic calcification, calcification occurs as a consequence of pre-existing condition such as an epidermal cyst, etc. and when there is no evidence of pre-existing pathology it is termed as idiopathic scrotal calcinosis. Metastatic calcifications are usually generalized and due to metabolic changes such as hypercalcemia and hyperphosphatemia as in end-stage renal diseases and hyperparathyroidism and dermatomysositis.[7,8] Pabuccuogh *et al.* proposed degeneration and necrosis of dartos muscle as the reason for calcification which is supported by King *et al.*, Fischer *et al.*, Armjo *et al.*, and Kelten *et al.*[7] Ito *et al.* described scrotal calcinosis is consequence of excessive discharge and accumulation of material debris in lumina of eccrine epithelial cyst using immunohistochemistry which showed slight positivity for antibodies to sulfated mucopolysaccharides.[4] Shapiro *et al.* 14 case series proposed scrotal calcinosis is idiopathic as there is no epithelial lining around calcium deposition, keratin remnants, granulomatous reaction and, inflammation infiltrates which is supported by Shal *et al.*, Parlakgumus *et al.*, Anureet *et al.*, Wright *et al.*, Karaca *et al.*, and Dombale *et al.*[1-3,8] Fukaya *et al.* and Ueds *et al.* mentioned role of mast cell in formation of calcification.[7,9] Dini *et al.* proposed the term "idiopathic" can be used if the cause is not known[7] as in our case. In our case, we are reporting a case of idiopathic scrotal calcinosis evidenced by the lack of inflammatory and

Access this article online

IJSS

www.ijss-sn.com

Month of Submission : 07-2015
Month of Peer Review : 08-2015
Month of Acceptance : 08-2015
Month of Publishing : 09-2015

Corresponding Author: Dr. Manoananth Arivazhagan, #219, PGs and Interns Hostel For Men, Mysore Medical College and Research Institute, Irwin Road, Mysore - 570 001, Karnataka, India. E-mail: ananth.mano88@gmail.com

epithelial cells. In this article, we have also elaborated the available literature on scrotal calcinosis.

CASE REPORT

A 45-year-old diabetic male patient presented with painless multiple swelling in the scrotum for 8 years which gradually progressed over the years. He neither gave any history suggestive of metabolic disorder, hormonal derangement, sexually transmitted diseases, nor trauma. On examination, multiple yellowish, firm nodules present in the scrotal skin with no ulceration or discharge.(Figure 1) The patient's blood picture, blood sugar, serum calcium, phosphate, parathyroid hormone, calcitonin, and vitamin D levels are within normal limits. (Figure 2) Excision of the nodules from the scrotal skin was done. Grossly excised specimen is about 4 cm × 3 cm ×2 cm and chalky white areas were seen below the skin on cut section. (Figure 3) Microscopic picture shows epidermis and dermis with multiple foci of calcium deposits in the subcutaneous tissue with no malignancy or inflammatory cells seen. (Figure 4)

Figure 1: Pre-operative picture

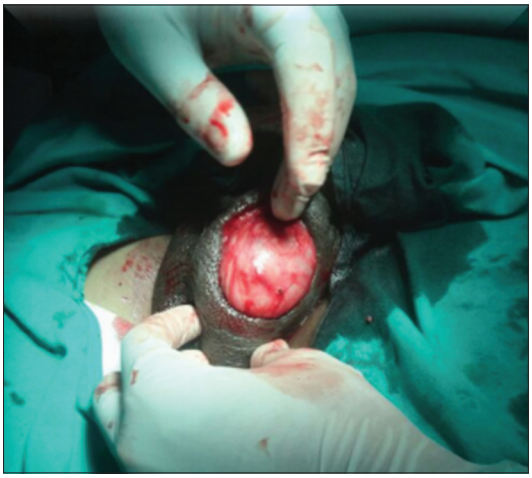

Figure 2: Post-excision skin gap

DISCUSSION

Idiopathic scrotal calcinosis is a rare benign condition with painless slow growing nodular masses within the dermis of the scrotal skin.[1,2] Incidence of the disease is not known.[1] It was first described by Lewinskey in 1883.[1-3] Deposition of calcium in the skin, subcutaneous tissue, muscles, and visceral organs is known as calcinosis, and it more commonly involves skin and it is called calcinosis cutis. There are four types of calcinosis cutis based on their etiology such as dystrophic, metastatic, iatrogenic, and idiopathic.[1]

Scrotal calcinosis is usually asymptomatic but occasionally causes heaviness, itching, ulceration, and chalky white

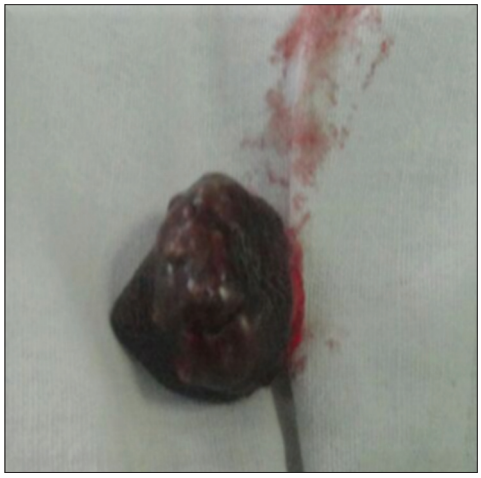

Figure 3: Excised specimen

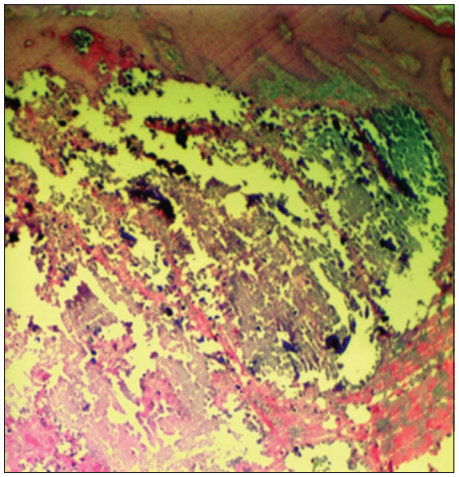

Figure 4: Epidermis and dermis with multiple foci of calcium deposits in the subcutaneous tissue with no malignancy or inflammatory cells seen

exudative discharge.[2,4-6,8] The patient mainly comes for cosmetic reasons.[8] Age group is 20-40 years, youngest and oldest reported are 9 and 85 years, respectively.[2,4-6] Initially, it resembles the color of scrotal skin later it changes into yellow, and duration is about 10 years ranging from 3 months to 46 years.[8]

Microscopic picture shows amorphous basophilic calcium deposits within dermis surrounded by lymphocytic infiltration, histiocytes, and hyalinization.[2,6-8] Histological picture shows muscle, epithelial cells, and foreign body granuloma during early stage and it shows only calcification in the advanced stage.[2]

The pathogenesis is still in the debate, various theories have been proposed by authors favoring idiopathic and dystrophic calcification. In dystrophic calcification, there must be a local favoring condition such as pre-existing epidermal cyst, eccrine duct milia, eccrine epithelial cyst, degenerated dartos muscle, and connective tissue disorders such as scleroderma, systemic lupus erythromatous, dermatomysositis, and minor trauma. Squamous cell epithelial lining may present, and patient has normal serum calcium and phosphorus levels.[1]

Song *et al.* described spectrum of changes takes place in scrotal calcinosis as mild to moderate inflammation of epidermal cyst is followed by mononuclear cell infiltration and foreign body granuloma formation and lastly resorption of cyst wall and keratin remnants leaving calcium deposits only[8,9] which is supported by Swinhart *et al.*, Akosa *et al.*, Saad *et al.*, Dubey *et al.*, Parlakgumus *et al.*, and Dini and Colatraneschi *et al.*[2,6,8]

Pabuccuogh *et al.* proposed degeneration and necrosis of dartos muscle as the reason for calcification which is supported by King *et al.*, Fischer *et al.*, Armjo *et al.,* and Kelten *et al.*[7] Ito *et al.* described scrotal calcinosis is consequence of excessive discharge and accumulation of material debris in lumina of eccrine epithelial cyst using immunohistochemistry which showed slight positivity for antibodies to sulfated mucopolysaccharides.[4]

Dare and Axelson *et al.* supported scrotal calcinosis arising from pre-existing eccrine milia using immnunohistochemistry which showed antibodies to carcinoembryonic antigen.[6] Carson *et al.* described sequences following minor trauma and invasion of nanobacteria and formation of calcium apatite crystals.[6] Veress and Feinstein *et al.* favored minor trauma following which calcification occur.[10]

Metastatic calcifications are usually generalized and due to metabolic changes such as hypercalcemia and hyperphosphatemia as in end-stage renal diseases hyperparathyroidism and dermatomysositis involving visceral organs and joints.[8,11,12] Pallavi *et al.* reported as case of scrotal calcinosis due to normocalcemic hyperparathyroidism which doesn't need parathyroidectomy unless symptomatic.[11]

Shapiro *et al.* 14 case series proposed scrotal calcinosis is idiopathic as there is no epithelial lining around calcium deposition, keratin remnants, granulomatous reaction, and inflammation infiltrates which is supported by Shal *et al.*, Parlakgumus *et al.*, Anureet *et al.*, Wright *et al.*, Karaca *et al.*, and Dombale *et al.*[1-3,8] Fukaya *et al.* and Ueds *et al.* mentioned role of mast cell in formation of calcification.[7,9] Dini *et al.* proposed the term "idiopathic" can be used if the cause is not known[7] as in our case. Idiopathic and dystrophic calcifications are usually involves one general area (calcinosis circumscripta). The iatrogenic calcifications mainly occur at the site of invasive procedure due to tissue damage.[12]

Differential diagnosis are teratoma, gonadoblastomas, leydig cell tumors, calcified onchocercoma, neurofibroma, ancient schwannomas, steatomas, lipomas, fibromas, and scrotal calcinosis may also be due to chronic epididymitis, calcified appendix testis, appendix epididymis, and sperm granuloma due to sperm extravasation and hematoma.[4,8]

Diagnosis is confirmed by biopsy. If swelling is <4 mm, pinch and punch excision is advised.[8] Surgery is the treatment of choice.[4,8] If it is massive, subtotal excision of the scrotal wall is preferred. If it is extensively involved, excision followed by complex scrotal reconstruction using meshed split thickness skin graft as the scrotal skin is rugged.[8] Recurrence is very low mainly due to microscopic foci of calcification left over.[8]

CONCLUSION

Idiopathic scrotal calcinosis cutis is a rare benign lesion. Metabolic and hormonal work-up is required to rule out other causes. Irrespective of the etiology, surgical excision is required both for confirming the diagnosis as well as for treatment. Scrotal calcinosis must be included in the differential diagnosis of cutaneous swellings in the scrotal region.

REFERENCES

1. Dombale VD, Basarkod SI, Kotabagi HB, Farheen U. Extensive idiopathic scrotal calcinosis: A case report. J Clin Diagn Res 2012 Suppl 1 6:478-9.
2. Anureet K, Rimpi B, Manas M, Jasbir S. Idiopathic calcinosis of scrotum; A rare scrotal skin disorder. J Adv Res Biol Sci 2011;3:113-4.
3. Shah V, Shet T. Scrotal calcinosis results from calcification of cysts derived from hair follicles: A series of 20 cases evaluating the spectrum of changes resulting in scrotal calcinosis. Am J Dermatopathol 2007;29:172-5.
4. Parlakgumus A, Canpolat ET, Caliskan K, Colakoglu T, Yildirim S, Ezer A,

et al. Scrotal calcinosis due to resorption of cyst walls: A case report. J Med Case Rep 2008;2:375.
5. Celik O, Ipekci T, Kazimoglu H. Idiopathic scrotal calcinosis. Saudi Med J 2013;34:1294-5.
6. Tela UM, Ibrahim MB. Scrotal calcinosis: A case report and review of pathogenesis and surgical management. Case Rep Urol 2012;2012:Article ID: 475246, 3.
7. Kelten EC, Akbulut M, Çolakoglu N, Bayramoglu H, Duzcan SE. Scrotal calcinosis: Is it idiopathic or dystrophic? Aegean Pathol J 2005;2:4-7.
8. Kiremitci S, Yüksel S, Anafarta K, Tulunay Ö. Scrotal calcinosis: A case report and review of literature. Ankara Üniv Tıp Fak Mecmuasi 2011;64:46-51.
9. Ibrahim M, Ibrahim GK, Mohammad MA, Aji1 SA, Umar AB, Nurlan AN, *et al.* Calcinosis of the scrotum in children: Report of two cases and review of the literatur. Arch Int Surg 2013;3:142-6.
10. Suha B, Uluocak N, Köseoğlu RD, Erdemir F, Sezer E. Idiopathic scrotal calcinosis: A rare scrotal skin disorder. Ankara Üniv Tıp Fak Mecmuasi 2005;58:20-2.
11. Pallavi R, Bautista JE, Lam K. Scrotal calcinosis in normocalcemic primary hyperparathyroidism. Available from: http://www.consultantlive.com. [2015 aug 14].
12. Scheinfeld NS. Skin disorders in older adults: Manifestations of endocrine and metabolic diseases. Consultant 360 2012;52:144-53.

How to cite this article: Manoananth AB, Srinidhi M, Balasubrahmaniya KS, Basavaraju N. Stone in the Scrotum: Scrotal Calcinosis Cutis: A Rare Case Report. Int J Sci Stud 2015;3(6):226-229.

Source of Support: Nil, **Conflict of Interest:** None declared.