

# Versatility and Modifications of the Cross-finger Flap in Hand Reconstruction

G Karthikeyan<sup>1</sup>, Gopi Renganathan<sup>2</sup>, R Subashini<sup>3</sup>

<sup>1</sup>Associate Professor, Department of Burns, Plastic and Reconstructive Surgery, Government Kilpauk Medical College and Hospital, Kilpauk, Chennai, Tamil Nadu, India, <sup>2</sup>Associate Professor, Department of Plastic and Reconstructive Surgery, Armed Forces Medical College, Pune, Maharashtra, India, <sup>3</sup>Consultant Plastic Surgeon, ICAPS, SRM Institute of Medical Sciences, Vadapalani, Chennai, Tamil Nadu, India

## Abstract

One of the most common soft-tissue defects encountered in hand surgery is the soft-tissue defect on the volar aspect of the finger. There are many reconstructive options for such a defect. Starting from full-thickness grafts, which may not be very reliable in providing a stable skin cover, to microvascular flaps such as arterialized venous flap, superficial palmar branch of the radial artery flap, posterior interosseous perforator flap, and ulnar artery perforator free flap, groin flap, venous flap, and toe pulp transfers exist. Need for expertise, inherent technical problems, and unpredictability of survival of these flaps have restricted the use of these microvascular flaps in reconstruction of such defects on the fingers. In such situations, the cross-finger flap still remains as the workhorse flap. The cross-finger flap is an established method of reconstruction of defects on the volar aspect of the fingers. The reason it became popular was because of the technical ease and safety in the harvest and reliability of the flap. However, defects on the finger were not confined only to the volar aspect. Dorsal defects, defects on the stump of the fingers, and defects on the radial and ulnar borders of the fingers were encountered frequently in hand surgery. Furthermore, the adjoining finger was always not available for the harvest of the cross-finger flap. In an effort to make the flap suitable for cover of many different sites of defects on the fingers, many modifications have been made. The modifications included changes in the donor finger, changes in the technique, and changes in the design. This review paper analyzes the different uses of the flap and the modifications made in the technique.

**Key words:** Cross-finger flap, Distally based cross-finger flap, Jumping cross-finger flap, Multiple cross-finger flaps, Proximally based cross-finger flap, Reverse dermis cross-finger flap

## INTRODUCTION

The cross-finger flap<sup>1,2</sup> was first described by Gurdinin 1950 and Pangman in 1951. They originally described it for soft-tissue cover for defects on the volar aspects of single fingers either at the middle phalangeal level or the terminal phalangeal levels. A very robust and safe flap, the cross-finger flap,<sup>3</sup> however, cannot be used in certain situations the way it was originally described. Hence, modifications in the flap were necessary<sup>4</sup> to cover different types of defects on the fingers. These modifications have been classified according to the alterations in

design, alterations in technique, and alterations in the donor's finger. We present our experience and make an algorithm for the different modifications and their indications.

## MATERIALS AND METHODS

At the Institute for Research and Rehabilitation of Hand, and Department of Plastic Surgery at Government Stanley Hospital, Chennai, from May 2011 to April 2012, all the patients who had a cross-finger flap were included in the study. A total number of 153 patients had a cross-finger flap done. Of these, 94 patients underwent a classical cross-finger flap, and 59 were modifications of the classically done cross-finger flap.

The 59 patients who had modifications of the cross-finger flap were analyzed, according to the type of flap done and the modification involved.

### Access this article online



www.ijss-sn.com

Month of Submission : 07-2017  
Month of Peer Review : 08-2017  
Month of Acceptance : 09-2017  
Month of Publishing : 09-2017

**Corresponding Author:** Dr. G Karthikeyan, Flat No 2075, Appaswamy "Banyan House", 471, M.K.N. Road, HUDCO Colony Layout, Alandur, Chennai - 600 016, Tamil Nadu, India. Phone: +91-9841130686. E-mail: gkhandsurgery@gmail.com

## RESULTS

There were a total of 47 males and 12 females. Age group analysis (Figure 1) showed that most of the patients were in the age group of 20-40 years, which is the productive age group and typically the group of patients getting injured in industrial injuries. The youngest patient was 2 years of age, a child who had injuries on the thumb when she touched a domestic motor machine in her house. The oldest in the group was a 75-year-old male who had an injury in a kitchen mixie machine.

The cause of the injury was analyzed (Figure 2) in these 59 patients. The most common cause was occupational injury (occurring in 35.5%), but there was almost an equal number of patients with injuries on the finger following road traffic accidents (30.5%). Household injuries formed the third largest group with 13.6%. Other causes included electrical injuries, defects following removal of benign lesions, and defects following release of skin contractures.

Analysis of the size of the modified cross-finger flaps (Figure 3) done in the 59 patients, it was found that the size ranged from 1.8 cm to 6 cm. The maximum number of patients had flaps ranging from 2 to 4 cm size.

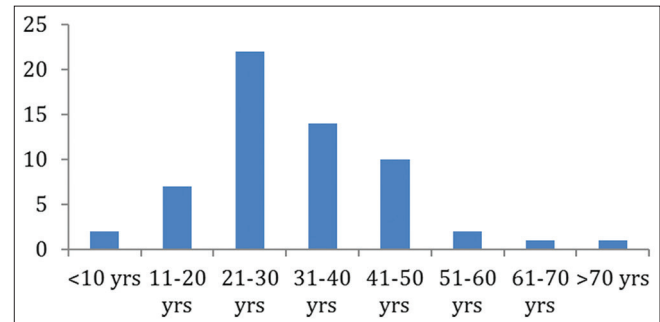
The most common site of soft-tissue defect requiring a modified cross-finger flap was analyzed (Figure 4). The most common site was the dorsum of the finger (56.9%). There were some volar defects too (21.6%), requiring some modification of the cross-finger flap. The other sites of the defects were on the ulnar side of the fingers, radial side of the fingers and stumps.

Table 1 showing the various modifications of the cross-finger flap in the study.

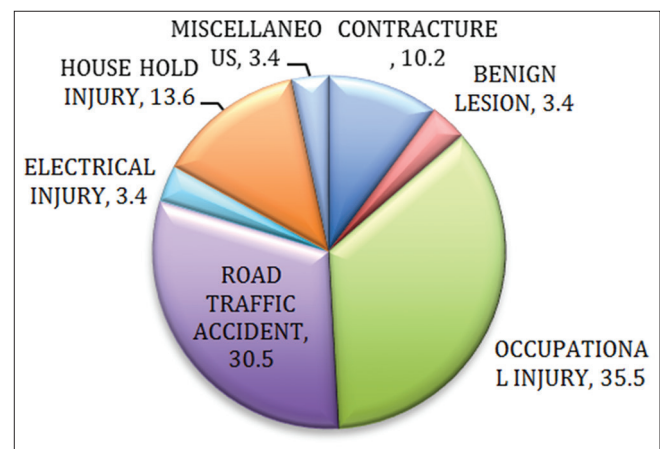
**Table 1: Types of modified cross-finger flaps done**

| Name                                     | Number |
|--|--------|
| Modifications in design                  |        |
| Proximally based cross-finger flap       | 12     |
| Distally based cross-finger flap         | 4      |
| Cross reverse dorsal digital artery flap | 3      |
| Cross-finger adipofascial flap           | 3      |
| Modifications in technique               |        |
| Folded cross-finger flap                 | 10     |
| Innervated cross-finger flap             | 4      |
| Reverse dermis cross-finger flap         | 6      |
| Modifications in the donor finger        |        |
| Multiple cross-finger flap               | 6      |
| Filletted cross-finger flap              | 3      |
| Hugging cross-finger flap                | 5      |
| Jumping cross-finger flap                | 3      |

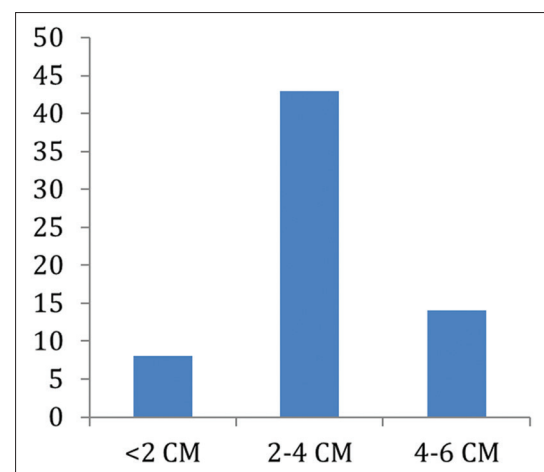
The total healing time for the flaps was analyzed and it was found to be 5-8 weeks. There were no major complications such as total flap loss. There were minor complications in 3 patients (5%), who had a marginal necrosis, and all these flaps were managed with dressings, and they went on to heal well. There were minor complications of partial graft loss on the donor site in 4 patients (6.7%), and these were also managed with dressings alone.



**Figure 1: Age group analysis of patients who underwent modified cross-finger flaps**



**Figure 2: Analysis of cause of soft-tissue defect**



**Figure 3: Analysis of size of modified cross-finger flaps**

The sensation on the flap was analyzed after 6 months. The 2 PD was found to be 6-10 mm in the 30 patients who were available for follow-up.

## DISCUSSION

### The Classical Cross-finger Flap

The cross-finger flap was first described by Gurdin and Pangman. Classically, defects on the volar aspect of the finger, in the position of the middle phalanx or the distal phalanx are covered with the cross-finger flap harvested from the dorsal aspect of the adjoining finger. Although the adjoining fingers can be used as donor fingers for the cross-finger flap, when there is a defect on the middle finger, the flap can be harvested from the ring finger or the index finger. We customarily avoid harvesting a flap from the index finger, as it is prudent to avoid any scarring on the index finger.

The flap is usually designed as a rectangular flap, which is raised on 3 sides and is classically planned on the dorsal aspect of the middle phalangeal region. The base of the flap is designed on the neutral line of the donor finger, and is usually on the side adjacent to the finger that is injured. This base acts such as a hinge, which provides the vascularity of the flap. The flap is raised superficial to the extensor paratenon, taking care to preserve this delicate, filmy tissue over the extensor tendon, to ensure a good take of skin graft applied over the donor site.

1. Indications of the classical cross-finger flap:
  - Defect on the fingers on the volar aspect over the middle phalangeal and distal phalangeal regions, arising after trauma, burns or after the release of contractures (Figure 5), and excision of tumors.
2. Advantages of the classical cross-finger flap
  - Easy to perform.
  - Reliable flap with large margin of safety. Can be harvested even from injured fingers, where the dorsal skin appears intact (Figure 6).
  - Negligible donor-site morbidity.
  - Can be performed under regional block anesthesia.
  - Can be used even for coverage of thumb defects.
  - Can be performed in children safely and reliably (Figure 7).
  - The contour reconstruction when given for tip and pulp defects is satisfactory. (Figure 8a and b).
  - Can be combined with other flaps when there are other injuries to the adjoining fingers (Figure 9).
3. Disadvantages
  - It is a two-staged procedure.
  - Skin color match may not be perfect.
  - May not be suitable for a variety of defects such as defects on the dorsum of the fingers, radial or ulnar borders, stumps of fingers, or proximal defects on fingers.

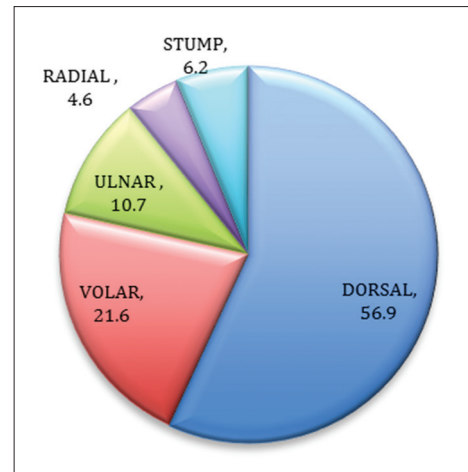


Figure 4: Analysis of site of modified cross-finger flaps

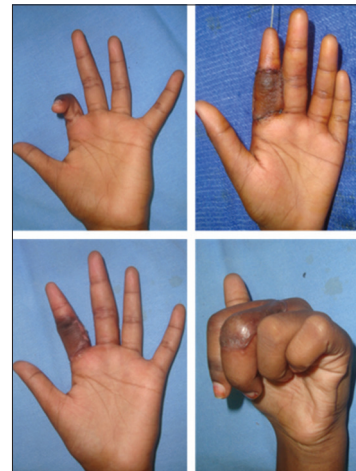

Figure 5: Classical cross-finger flap for coverage of defect after contracture release

### Modifications of the Cross-finger Flap Done

#### Modifications of design

#### Proximally based cross-finger flap (Figure 10)

In total, 12 patients had a proximally based cross-finger flap done. The proximally based flap<sup>5</sup> design was used for defects on the dorsal aspects of the fingers. Of these defects, 4 defects were on the radial aspect of the middle finger, for which a proximally based flap from the dorsum of index finger was used. 3 defects were on the ulnar aspect of the middle finger for which flaps were taken from the dorsal aspect of the ring finger. 4 on the index finger ulnar aspect, for which proximally based cross-finger flaps were taken from the middle finger dorsum, and there was 1 defect on the radial aspect of the little finger, for the coverage of which, a proximally based flap was harvested from the ring finger. All the flaps survived fully, and the donor sites healed well with complete recovery of range of motion of the donor finger.



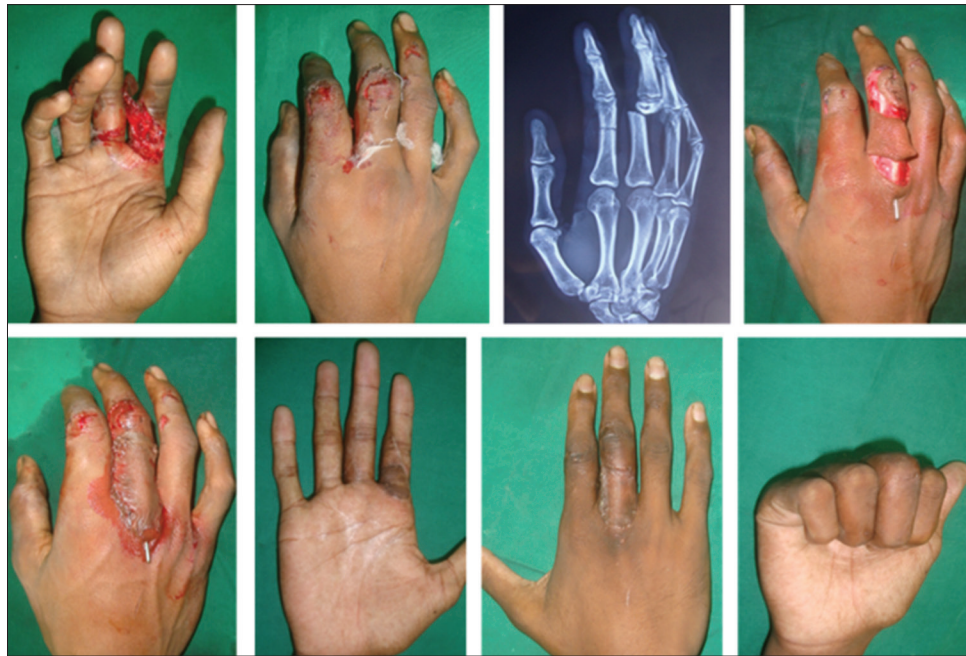

Figure 6: Cross-finger flap raised from PPX region of an injured finger

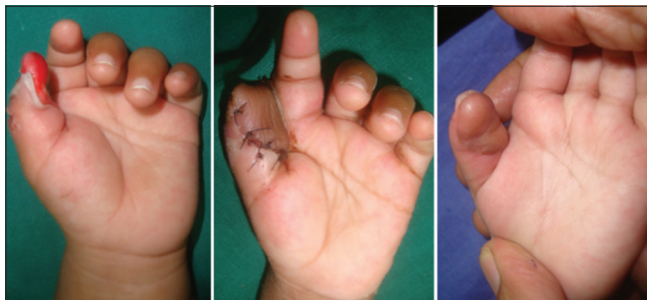

Figure 7: Use of cross-finger flap for a child

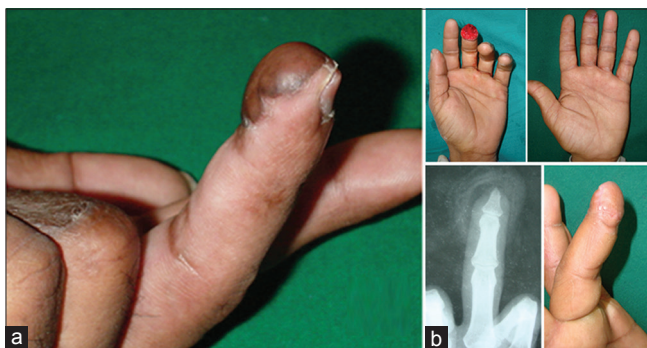


Figure 8: Contour cosmesis after reconstruction of pulp (a) and tip defects (b) with cross-finger flaps

The flap was designed with the base extending from the neutral line to the neutral line (Figure 11). The length of the flap was made such that it would transpose comfortably to the recipient defect on the adjoining finger.

After dressings are done, a volar POP is to be applied to the hand.

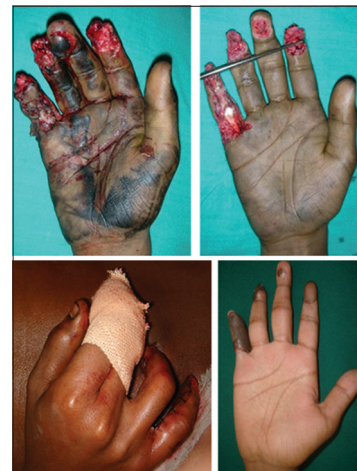

Figure 9: Cross-finger flap to the index finger, and step ladder abdominal flaps to ring and little fingers

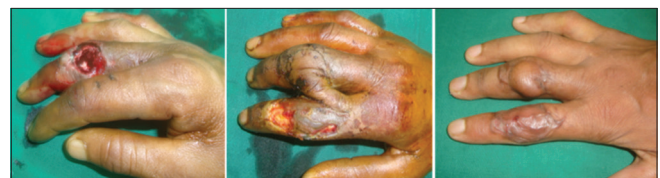

Figure 10: Proximally based cross-finger flap

#### 1. Indications

- The indication for this flap was a defect on the dorsal/dorsolateral aspects of the middle or ring fingers or the ulnar or radial aspects of the index and little fingers, respectively. The defect was classically at the level of the proximal interphalangeal joint or proximal to it, as the distal

most edge of the proximally based cross-finger flap was the distal interphalangeal joint crease on the dorsal aspect.

2. Advantages
  - This modification of the classical cross-finger flap covers defects on the proximal aspect of the fingers.
3. Disadvantages
  - A longer flap will have to be raised to allow it to transpose comfortably to cover the defect.
  - The bridging segment is longer than in the classical cross-finger flap.

#### Distally based cross-finger flap (Figure 12)

Four patients had a reconstruction of defects on the dorsum of the fingers with distally based cross-finger flaps.<sup>6</sup> All the defects were on the middle fingers. This flap was ideal for patients who had distal soft-tissue defects mainly on the dorsolateral aspect of the finger, requiring a good quality skin cover, which would allow the future reconstruction or surgery. For such similar defects, reverse dermis cross-finger flap or cross-finger adipofascial flap may be indicated, but these flaps need a skin graft over them, and hence the quality of skin cover is reduced.

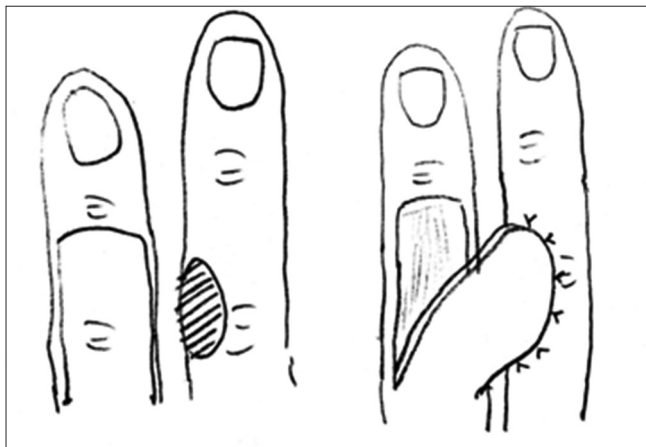


Figure 11: Design of the proximally based cross-finger flap

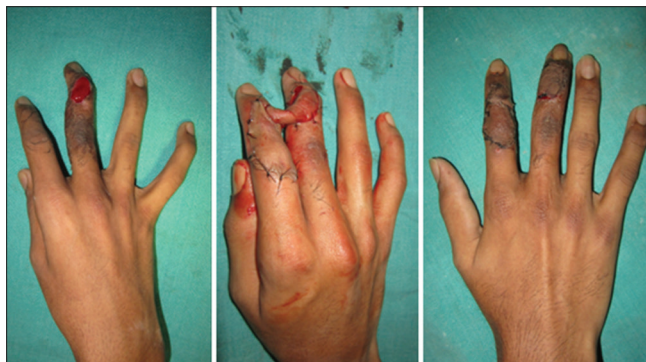


Figure 12: Distally based cross-finger flap from index finger to middle finger

The distally based cross-finger flap is raised with the base oriented distally (Figure 13). The flap must be long enough to allow transposition to the defect; hence, dorsolateral defects are safely covered with such flaps. The donor site is skin grafted and after dressings are done, a volar POP slab is applied.

#### Indication

1. Soft-tissue defects on the dorsolateral aspect of the finger requiring good quality skin cover.
2. Advantage
  - Provides good quality skin cover.
3. Disadvantages
  - Can be used only for dorsolateral aspect of the fingers.

Can be used only for distal defects, distal to the proximal interphalangeal joint level.

#### Cross-finger reverse dorsal digital artery flap (Figure 14)

The cross-finger reverse dorsal digital artery flap was done in 3 patients. This flap is very similar to the distally based cross-finger flap except for a small modification in the design. The base of the distally based cross-finger flap must extend from one mid-axial line to the other, and as a result, the flap must be longer to allow transposition to cover the defect on the adjacent finger. However, this carries a little risk of compromised vascularity of

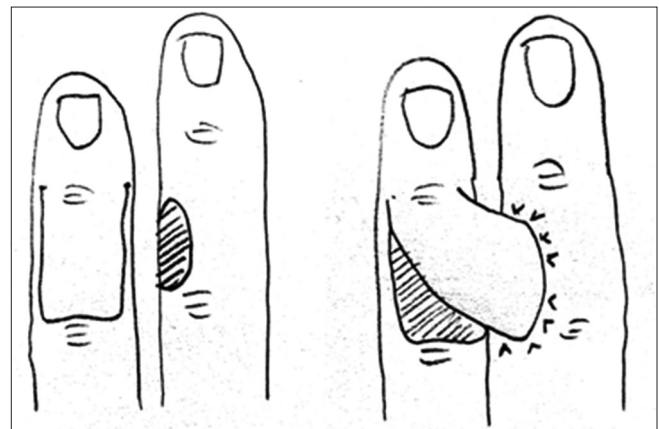


Figure 13: Design of the distally based cross-finger flap

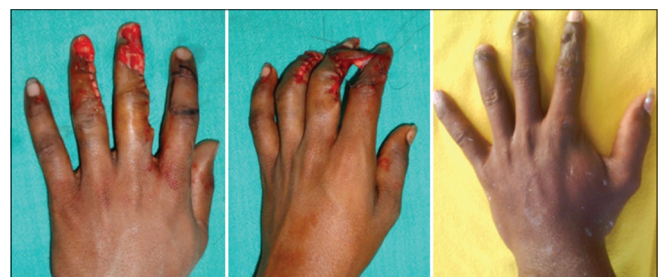

Figure 14: Cross-finger reverse dorsal digital artery flap



the flap and also limited arc of rotation. There is a system of arterial communications<sup>7</sup> between the volar aspect and dorsal aspect of the finger, which occurs at designated levels, such as the neck and base of the middle and proximal phalanges (Figure 15). While the distally based cross finger is being planned, the communication mentioned above can be marked, and the flap can be almost islanded (Figure 16). The incision would be on almost all 4 sides, with a skin bridge protecting the vascular pedicle. It is not essential to skeletonize the vessel. This technique will improve the arc of rotation of the flap, and at the same time, will not compromise the vascularity.

#### 1. Indication

- For the coverage of soft-tissue defects with good quality skin cover on the dorsum of the fingers distal to the proximal interphalangeal joint.

#### 2. Advantages

- A better play of the flap movements and ability to cover more distal defects. Lesser length will be required of the flap from the donor finger.

#### 3. Disadvantage

- Needs more meticulous dissection at the site of vascular pedicle.

### Cross-finger adipofascial flap (Figure 17)

Three patients underwent a cross-finger adipofascial flap cover. 2 of the defects were on the dorsal aspect of

the proximal phalangeal region of the index finger, and 1 patient had a defect on the dorsal aspect of the middle phalangeal region of the middle finger. When the defect is on the dorsum of the finger, a reverse dermis cross-finger flap can be done, but the disadvantages that a larger skin graft will be required to cover both the donor defect and the undersurface of the flap, and the possibility of inclusion cysts occurring following de-epithelialization.

The flap is marked just like a classical cross-finger flap, with the base of the flap on the contiguous side with the injured finger and close to the defect. Another marking is made of a similar size with the base on the opposite side neutral line. This marking denotes the dermal flap that is to be raised, at a plane just deep to the dermis, preserving the subdermal plexus. Once the dermal flap is raised and opened like a book, opposite to the site of the defect, the soft tissues covering the extensor paratenon are raised as an adipofascial flap in the same way that a classical cross-finger flap is raised. This adipofascial tissue is then used to cover the defect on the injured finger (Figures 18-20). The dermal flap is repositioned to cover the donor site of the flap, and a skin graft is needed to cover only the soft tissues of the adipofascial flap on the recipient finger. After application of dressings, the POP slab must be applied on the volar aspect of the hand.

The second stage of division is done as for the classical cross-finger flap.

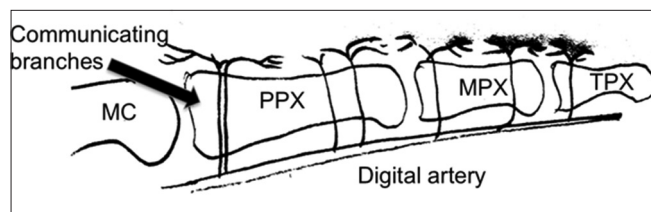


Figure 15: Schematic diagram showing the arterial communications to the dorsum of the finger

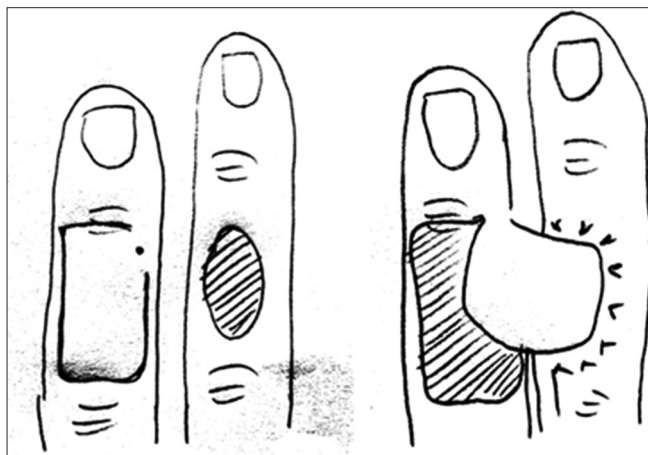


Figure 16: Design of the cross finger reverse dorsal digital artery flap

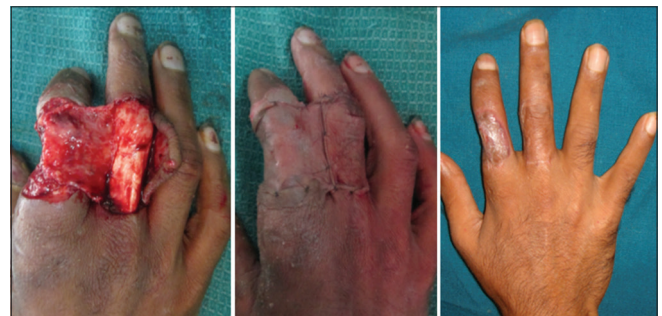

Figure 17: Cross-finger adipofascial flap

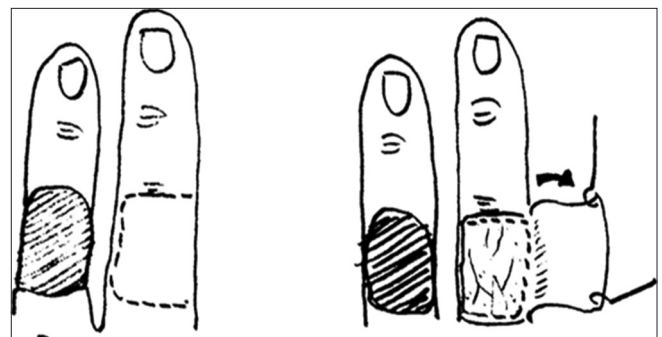


Figure 18: Marking of the dermal flap on the donor finger and raised dermal flap

1. Indication
  - Soft-tissue defects on the dorsal aspect of the fingers.
2. Advantages
  - Skin graft is required only to cover the adipofascial tissue over the defect.
  - Cosmesis is better as there is no skin graft over the donor finger as in a reverse dermis cross-finger flap, which can be used for such defects.
  - No possibility of inclusion cysts.
3. Disadvantages
  - The adipofascial tissue is a delicate layer which barely covers the defect.
  - Requires careful elevation of the dermal flap over the donor finger.
  - Possibility of partial necrosis of the dermal flap.
  - Graft take is not optimum over the adipofascial flap.

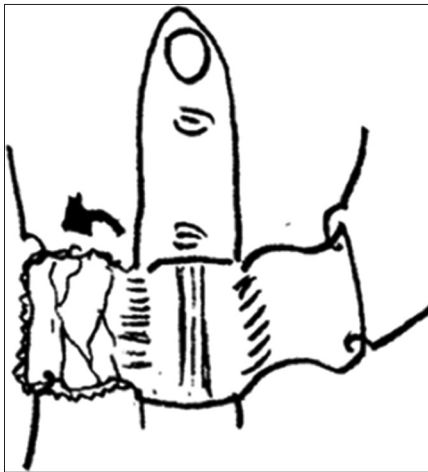


Figure 19: Adipofascial flap raised and used to cover the defect



Figure 20: Adipofascial flap after inset ready for skin graft and the dermal flap repositioned and sutured on donor finger

### Modifications of technique

#### Folded cross-finger flap (Figure 21)

Ten patients had injuries on the tips of the fingers, involving both the dorsal aspect and the volar aspect. 6 patients had injuries on the index finger, 2 had injuries on the ring finger, and 1 each had injuries on the little finger and thumb. The patient with the thumb injury refused a Littler's neurovascular island flap, and hence a folded cross-finger flap with innervation was planned. When the classical flap is expected to fold over the stump, a small modification is done in the design. A back cut is made in the flap to allow the distal end of the flap to fold over to cover the stump and the dorsal aspect (Figures 22-24). Since this entails a back cut, it is important to remember that this may cut into the blood supply of the flap. Hence, it must be done carefully.

#### 1. Indication

- This modification of the flap is useful when covering the tips of the finger or end stumps of the fingers.

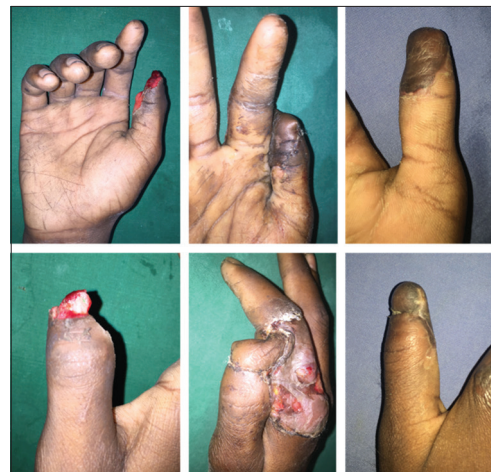

Figure 21: Folded cross-finger flap for coverage of tip and pulp of thumb

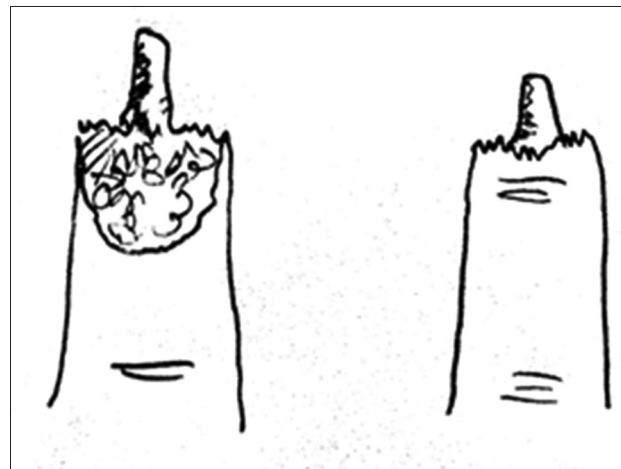


Figure 22: Typical defect for a folded cross-finger flap

2. Advantage
  - Covers both the volar and dorsal aspects with a single flap.
3. Disadvantage
  - The back cut can compromise the vascularity of the flap and result in partial necrosis of the dorsal aspect of the flap.

#### Innervated cross-finger flap (Figure 25)

Four patients had an innervated cross-finger flap for reconstruction of soft-tissue defects on the tip of the finger. Three of the patients had injuries on the index finger and one patient had an injury on the ring finger.

These flaps were done to ensure a good return of sensation to the tip of the finger.<sup>8-10</sup> When the debridement of the wound was done, the cut digital nerve stump was identified and tagged. While the flap was being raised, the sensory

twigs on the dorsal aspect of the finger were identified and tagged (Figure 26). At the time of flap inset, the tagged digital nerve at the edge of the defect was coapted to the tagged sensory nerve twig on the flap with 10.0 polyamide suture. The second stage of the division was carried out as usual.

The sensation achieved in these 4 patients was analysed after 6 months and showed a 2PD of 6-7.5 mm.

1. Indications
  - For coverage of soft-tissue defects on the terminal phalangeal region of the fingers, to achieve improved sensation.
2. Advantage
  - Improved sensation can be achieved on the tips of the fingers.
3. Disadvantage
  - Needs more expertise in microneural coaptation.

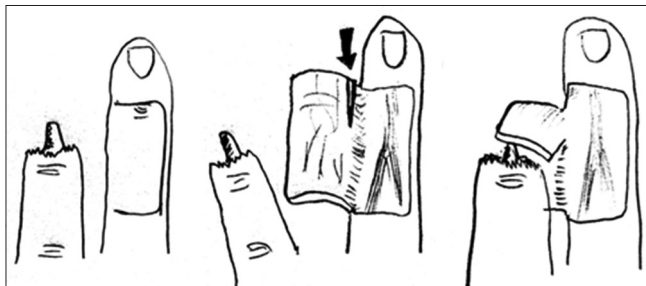

Figure 23: Flap raised, back cut given, and flap folded over

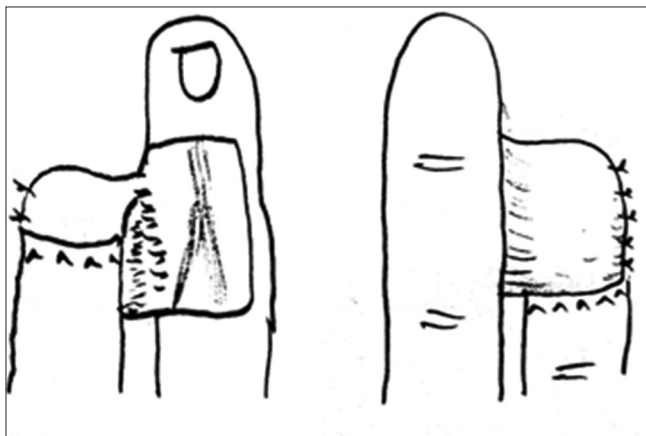


Figure 24: After final flap inset of the folded cross-finger flap

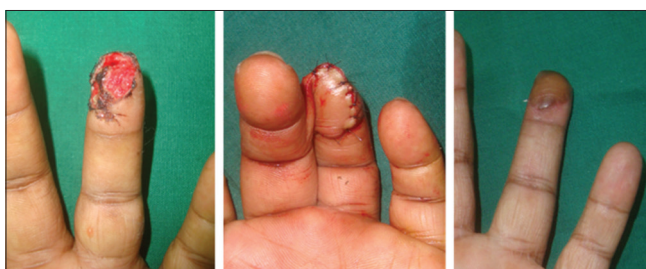

Figure 25: Innervated cross-finger flap

#### Reverse dermis cross-finger flap (Figure 27)

In our series, there were 6 patients who had a reverse dermis cross-finger flap<sup>11-14</sup> done. The defects were on the dorsal aspect of single fingers. 3 patients had a defect on the terminal phalangeal region of the index fingers with loss of nail complex, 2 patients had similar defects on the ring fingers and on the middle finger.

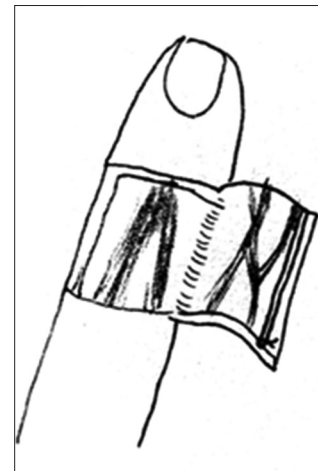


Figure 26: Tagged proximal end of the sensory nerve twig on the flap

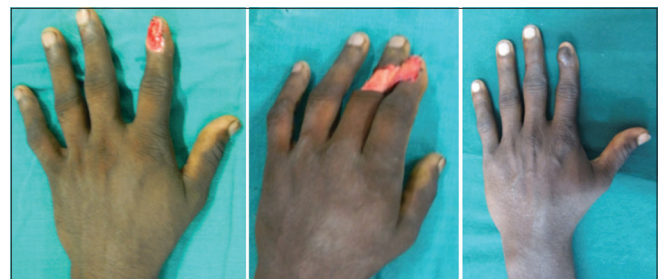


Figure 27: Reverse dermis cross-finger flap



The technique of this flap was to de-epithelialize the skin on the proposed area of the cross-finger flap which is planned on the dorsal aspect of the middle phalangeal region of the contiguous finger. After de-epithelialization, the flap is raised similar to the classical cross-finger flap, superficial to the extensor paratenon. The flap is then hinged like a book and the dermis side is laid over the soft-tissue defect on the dorsal aspect of the injured finger (Figures 28 and 29). The entire area consisting of the donor site defect, and the flap over the defect site are then covered with a split thickness skin graft. After dressings are done, the POP application must be on the volar side, to allow for quick monitoring and dressings of the flap.

The second stage of division is done just as the classical cross-finger flap.

#### 1. Indication

- For coverage of soft-tissue defects on the dorsal aspect of the terminal phalangeal region of a single finger.

#### 2. Advantages

- Simple procedure which is reliable, and can be done under regional block anesthesia.
- This flap contains tissue which is more robust than the adipofascial flap, as it contains the dermis.

#### 3. Disadvantage

- There is a possibility of developing inclusion cysts from the de-epithelialized area under the flap.

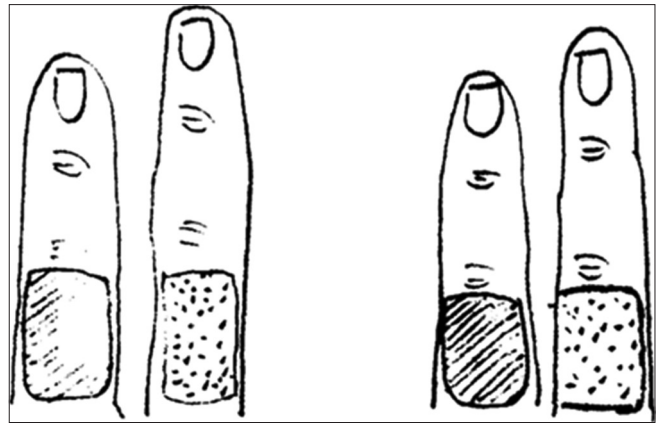
### *Modifications in donor finger*

#### **Multiple cross-finger flaps (Figure 30)**

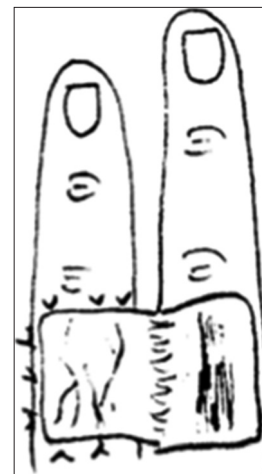
Six patients had multiple defects on fingers, and each of the defects, required a cross-finger flap. 5 patients had defects on 2 fingers and 1 patient had defects on three contiguous fingers. When there are multiple defects on the fingers, there may be a modification necessary in the form of multiple cross-finger flaps. These flaps can be done only if the defects are only in the terminal phalangeal region, involving the pulp tissue. Defects proximal to this will preclude the use of multiple flaps, as the finger with a defect will always have to be donor site of a flap. Since the flap is harvested from the dorsum of the middle phalangeal region, if the defect involves the volar aspect of the middle phalangeal region, there is a problem of making the wound circumferential, which must be avoided.

The flaps can be raised one after the other after the debridement of the wounds is over. Similarly, flap inset can be given, and then the donor sites covered with skin grafts.

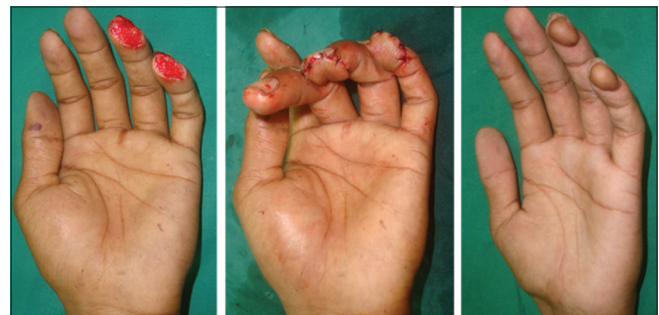These multiple flaps may involve increasing flexion of the interphalangeal joints in contiguous fingers. These flaps may not be possible in patients who have short, stubby fingers, as they may not be pliable enough to accommodate



**Figure 28: Deepithelialized portion on the dorsum of the donor finger and marking for raising the flap**



**Figure 29: Reverse dermis flap raised and inset given, and ready for the skin graft to both recipient and donor areas**



**Figure 30: Double cross-finger flaps to ring and little fingers**

the increasing interphalangeal joint flexion, when multiple flaps are harvested. Similarly, these flaps may not be ideal for elderly people with stiffness of the joints of the hand. Hence, these multiple flaps are preferably done in younger patients, and vigorous physiotherapy instituted once the flaps are divided.

#### 1. Indication

- Multiple soft-tissue defects on 2 or three fingers involving only the pulp tissue of the

terminal phalangeal region, preferably in younger individuals with long fingers with pliable joints.

2. Advantage
  - Multiple finger defects can be treated simultaneously with the safe and reliable cross-finger flap.
3. Disadvantage
  - Involves more pliability of the finger joints, hence may not be advisable in some groups of patients.

#### Filletted cross-finger flap

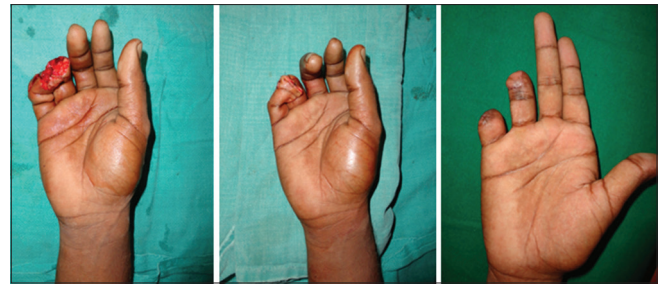
When there are injuries to multiple fingers, as occurs in industrial accidents, a classical cross-finger flap may not be possible. If there is a defect on a finger, requiring a cross-finger flap, and when the adjoining finger has been partially amputated, with loss of the distal segment and revascularization is not possible, the injured finger can be filleted, and the filleted skin flap can be used to resurface the defect on the recipient finger (Figure 31). In 3 patients, this filleted cross-finger flap was done in our series. 2 patients had a filleted flap from an amputated ring finger to little finger, and one patient had a filleted flap from an amputated middle finger to a soft-tissue defect on the index finger.

1. Indication
  - When there are multiple injuries to fingers and there is a partially amputated finger adjoining a finger with a soft-tissue defect requiring a flap cover. This can be done only if there is no option of revascularizing the partially amputated finger, or the patient does not want reconstruction of the amputated finger.
2. Advantage
  - This modification of the cross-finger flap makes use of tissue that may have to be discarded.
3. Disadvantage
  - The partially amputated finger may by itself have a precarious vascularity and using the filleted flap from this finger to cover a defect on the adjoining finger may not be reliable. This procedure precludes reconstruction of the partially amputated finger.

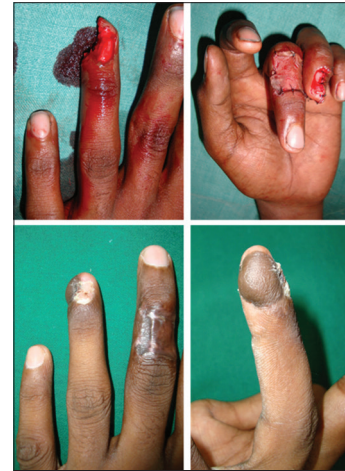#### Hugging cross-finger flap

In this modification of the cross-finger flap, the recipient finger placed over secondary defect (Figure 32).

In the classical cross-finger flap, the donor finger and the recipient finger lie side by side, with no overlap. However, when the defect on the finger is more on the radial side or ulnar side of the finger, the recipient finger will have to adduct toward the donor finger, so that the flap can get a comfortable inset. In this situation, the recipient finger will lie over the secondary defect on the donor finger. This flap can only be done for defects on the radial or ulnar side of the terminal phalangeal region of the finger.



**Figure 31: Filleted cross-finger flap from amputated ring finger to the little finger**



**Figure 32: Example of the hugging cross-finger flap**

Five such flaps were done in our series. 4 of them involved a defect on the ulnar side defect of ring finger and one for a radial side defect on an index finger. Since the recipient finger lies over the donor finger, the bridging segment is lesser than the classical cross-finger flap.

1. Indication
  - Defects on the terminal phalangeal region of the finger involving the radial or ulnar border alone.
2. Advantage
  - It gives a comfortable inset to three sides of the defect.
3. Disadvantage
  - There is some overlapping of the recipient finger over the donor finger, which may cause soddening of the volar aspect of the recipient finger, some graft loss on the donor site and stiffness at the metacarpophalangeal joint of the recipient finger because of the deviation.

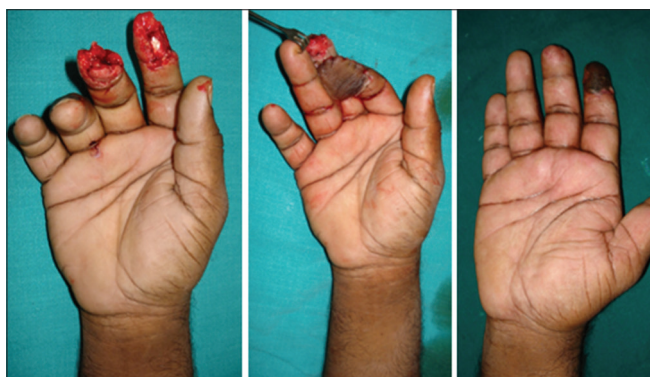
#### Jumping cross-finger flap

In this modification of the classical cross-finger flap, the injured adjacent finger skipped (jumped over) (Figure 33).

This flap was performed when there was an injury to the dorsal aspect of the adjoining finger and a classical

**Table 2: Algorithm for use of the cross-finger flap and its modifications**

| Name                                     | Indication - location of soft-tissue defect on the finger/s   |
|--|---|
| Classical cross-finger flap              | Defects on the volar aspect over the middle phalangeal and/or distal phalangeal regions not extending dorsal to the midaxial lines  |
| Modifications in design                  |   |
| Proximally based cross-finger flap       | Defects on the proximal aspect of the dorsum of the fingers   |
| Distally based cross-finger flap         | Soft-tissue defects on the dorsolateral aspect of the finger requiring good quality skin cover  |
| Cross reverse dorsal digital artery flap | For the coverage of soft-tissue defects with good quality skin cover on the dorsum of the fingers distal to the proximal interphalangeal joint  |
| Cross-finger adipofascial flap           | For coverage of soft-tissue defects on the dorsal aspect of a single finger limited by mid-axial lines  |
| Modifications in technique               |   |
| Reverse dermis cross-finger flap         | For coverage of soft-tissue defects on the dorsal aspect of a single finger limited by mid-axial lines  |
| Innervated cross-finger flap             | For coverage of soft tissue defects on the terminal phalangeal region of the fingers, to achieve improved sensation   |
| Folded cross-finger flap                 | Defects involving the tips of the finger or end stumps of the fingers requiring skin cover for the volar and dorsal aspects   |
| Modifications in the donor finger        |   |
| Multiple cross-finger flap               | Multiple soft-tissue defects on 2 or three fingers involving only the pulp tissue of the terminal phalangeal region, preferably in younger individuals with long fingers with pliable joints                                |
| Filletted cross-finger flap              | When there is a partially amputated finger adjoining a finger with a soft-tissue defect similar to the one described in (1)   |
| Hugging cross-finger flap                | Defects on the terminal phalangeal region of the finger involving the radial or ulnar border alone  |
| Jumping cross-finger flap                | Similar to that for the classical cross-finger flap (1), but the adjoining finger is so injured that it cannot serve as a donor for a flap. The third finger from the finger requiring the cross-finger flap must be intact |

**Figure 33: Cross-finger flap from the ring finger to the index finger, bypassing the injured middle finger**

cross-finger flap could not be performed. This modification of the cross-finger flap was done in 3 patients. All three patients had an injury to the index and middle fingers, and the ring finger was intact. The flap was raised from the dorsal aspect of the ring finger and inset on to the soft-tissue defect on the volar aspect of the index finger in all three patients. The middle finger was positioned dorsal to the donor and recipient fingers. The middle finger injury was to the tip, and were covered with skin graft in 2 patients and treated conservatively in one patient.

#### 1. Indication

- This flap is indicated when the defect of soft tissues is restricted to the volar aspect of the terminal phalanx of the finger, and the adjoining finger is so injured that it cannot serve as a donor for the classical cross-finger flap. The third finger from the finger requiring the cross-finger flap must be intact.

#### 2. Advantage

- Can be used as a simple flap reconstruction even if the adjoining finger precludes the use of cross-finger flap.

#### 3. Disadvantage

- Will involve slight deviation at the donor and recipient finger metacarpophalangeal joints, which can be corrected after the division of the flap at 2 weeks.

The following Table 2 sums up the various modifications of the cross-finger flap and their indications.

## CONCLUSION

In spite of changes in design, technique, and modifications in the donor finger, the cross-finger flap has good outcomes and less complications. The modifications are required in situations where the classical cross-finger flap may not be ideal. These modifications also allow more types of defects to be covered. Hence, it is once again proved that the cross-finger flap is a workhorse flap for finger defects, and use of the modifications increases the armamentarium of flaps for the coverage of soft-tissue defects in the fingers.

## REFERENCES

- Gurdin M, Pangman WJ. The repair of surface defects of fingers by trans-digital flaps. *Plast Reconstr Surg* 1950;5:368-71.
- Tempest MN. Cross-finger flaps in the treatment of injuries to the finger tip. *Plast Reconstr Surg* 1952;9:205-22.



3. Kappel DA, Burech JG. The cross-finger flap. An established reconstructive procedure. *Hand Clin* 1985;1:677-83.
4. Špokevičius S. A review of the cross finger flap history. *Balt Am Clin* 2008;14:106-9.
5. Germann G, Levin SL. Intrinsic flaps in soft tissue reconstruction of the hand. *J Hand Surg* 1981;6:3-405.
6. Patil RK, Chavre S. Distally based cross-finger flaps for amputation stumps in avulsion amputations. *Indian J Pharm Sci* 2012;45:504-11.
7. Vuppalapati G, Oberlin C, Balakrishnan G. Distally based dorsal hand flaps: Clinical experience, cadaveric studies and an update. *Br J Plast Surg* 2004;57:653-67.
8. Miura T. Thumb reconstruction using radial-innervated cross-finger pedicle graft. *J Bone Joint Surg Am* 1973;55:563-9.
9. Lee NH, Pae WS, Roh SG, Oh KJ, Bae CS, Yang KM. Innervated cross-finger pulp flap for reconstruction of the fingertip. *Arch Plast Surg* 2012;39:637-42.
10. Gellis M, Pool R. Two-point discrimination distances in the normal hand and forearm: Application to various methods of fingertip reconstruction. *Plast Reconstr Surg* 1977;59:57-63.
11. Braga-Silva J, Kuyven CR, Albertoni W, Faloppa F. The adipofascial turnover flap for coverage of the dorsum of the finger: A modified surgical technique. *J Hand Surg Am* 2004;29:1038-43.
12. Thatte RL. Deepithelialized turnover flaps. *Plast Reconstr Surg* 1989;84:172-3.
13. Thatte RL, Gopalakrishna A, Prasad S. The use of de-epithelialised turnover flaps in the hand. *Br J Plast Surg* 1982;35:293-9.
14. Atasoy E. Reversed cross-finger subcutaneous flap. *J Hand Surg Am* 1982;7:481-3.

**How to cite this article:** Karthikeyan G, Renganathan G, Subashini R. Versatility and Modifications of the Cross-finger Flap in Hand Reconstruction. *Int J Sci Stud* 2017;5(6):35-46.

**Source of Support:** Nil, **Conflict of Interest:** None declared.