

Occurrence of Adenomyosis in Hysterectomy Specimen and its Clinical Correlation in a Tertiary Care Hospital in Mandya, Karnataka, India

M S Siddegowda¹, M R Manjunath¹, S Shivakumar²

¹Associate Professor, Department of Pathology, Mandya Institute of Medical Sciences, Mandya, Karnataka, India, ²Professor and Head, Department of Pathology, Mandya Institute of Medical Sciences, Mandya, Karnataka, India

Abstract

Background: Adenomyosis is a common pathologic finding significantly related to reproductive and menstrual characteristics of the patients. It is characterized by the presence of endometrial tissue with or without hypertrophy or hyperplasia of surrounding myometrium. The pre-operative diagnosis based on clinical findings is very poor. This study is aimed at evaluating the occurrence of adenomyosis in hysterectomy specimen and to correlate the symptoms of patients with adenomyosis with histological features.

Materials and Methods: Case records of the patients who have undergone a hysterectomy in our institute from January 2011 to December 2014 were reviewed and clinical data recorded. Morphological findings were recorded and the number of cases diagnosed to have adenomyosis and adenomyosis associated co-morbid conditions were recorded.

Results: The adenomyosis was present in 158 patients out of 952 patients underwent the hysterectomy during the study period. The co-morbid conditions were seen in 78 patients. Majority were in the age group of 31-50 years. Menorrhagia, dysmenorrhea, metrorrhagia, intermenstrual pelvic pain, post-menopausal bleeding, and dyspareunia were the common presenting symptoms.

Conclusions: The adenomyosis was found in 16.59% of hysterectomy specimen commonly in multiparous women of 31-50 years presenting with menorrhagia, dysmenorrhea, metrorrhagia, intermenstrual pelvic pain, post-menopausal bleeding, and dyspareunia. Hence, a pre-operative diagnosis of adenomyosis may be considered in patients presenting with these symptoms without any definitive evidence of uterine fibroid, utero-vaginal prolapse, or ovarian mass.

Key words: Adenomyosis, Dysmenorrhea, Hysterectomy, Multipara

INTRODUCTION

Our understanding of benign myometrial lesions like adenomyosis lags far behind in spite of increasing prevalence of adenomyosis.¹ The adenomyosis is a benign gynecological disorder characterized by invasion of endometrial glands and stroma located haphazardly and deeply within the uterine myometrium.² It may be associated with hyperplasia and/or hypertrophy of adjacent myometrium.¹

Frequency of adenomyosis increases with age, peaks at 40-50 years and levels - off after menopause. Increase in frequency is also associated with multiparity.³ Menstrual irregularities, smoking, dilatation, and curettage are said to increase the risk of adenomyosis.⁴

The pre-operative diagnosis of adenomyosis based on clinical findings is very poor. It is asymptomatic in up to 1/3 to 1/2 of the cases. The symptomatic patients present with progressively increasing the severity of menorrhagia, dysmenorrhea, metrorrhagia, intermenstrual pelvic pain, and rarely dyspareunia.^{1,3,5} Chronic symptoms such as menorrhagia and dysmenorrhea correlate with the depth of myometrial involvement and age.⁶

In the majority of the patients, diagnosis is based on histological examination of hysterectomy specimen.⁴ Radiological procedures and serum CA125 assay are

Access this article online



www.ijss-sn.com

Month of Submission : 07-2015
Month of Peer Review : 08-2015
Month of Acceptance : 08-2015
Month of Publishing : 09-2015

Corresponding Author: Dr. MS Siddegowda, Department of Pathology, Mandya Institute of Medical Sciences, Mandya - 571 401, Karnataka, India. Phone: +91-9448054730. E-mail: chinmayimsg@yahoo.com

of limited diagnostic utility.⁴ A high frequency of pathological lesions are associated with adenomyosis which include leiomyoma, endometriosis, endometrial hyperplasia, carcinoma, and ovarian cyst, suggesting the possibility of a common underlying disorder like hyperestrogenism.^{1,6}

Reported prevalence of adenomyosis in hysterectomy specimen has varied from 8% to 20% in various studies conducted in Greece, Italy, Germany, and the USA. The prevalence is reported to be as high as 57% in Pakistan.⁷ Some studies have reported a prevalence as high as 61.5%. Wide variation in the prevalence is partially due to the difference in histological criteria adopted for diagnosis and also may be due to the difference in frequency of co-morbidities in different population that necessitate hysterectomy.⁷

Termination of pregnancy might affect the pathogenesis of adenomyosis, and may influence the myometrial depth and the number of foci.⁸ The adenomyosis is more common among post-menopausal breast cancer patients who were on treatment with tamoxifen.⁹

The purpose of this study is to characterize the prevalence of adenomyosis in hysterectomy specimen and correlate the symptoms of uterine adenomyosis with histological features and associated co-morbidities.^{10,11}

MATERIALS AND METHODS

The present study is a retrospective study conducted in the Department of Pathology, Mandya Institute of Medical Sciences (MIMS), Mandya for a period of 4 years from January 2011 to December 2014. Prior clearance was taken from the Institutional Scientific Committee and Institutional Ethical Committee. The study sample consisted of women who had undergone the hysterectomy and diagnosed to have adenomyosis and adenomyosis associated co-morbid conditions of uterus and ovary on histopathological examination. All pre-menopausal and post-menopausal women who underwent hysterectomy were included in the study. Case records of the patients were reviewed and clinical data such as age, gravida, parity, menstrual history, history of previous surgery, obstetric history, intermenstrual bleeding, dysmenorrhea, dyspareunia, and intermenstrual pelvic pain were noted. Where ever available, information regarding previous dilatation and curettage for gynecological indications was noted. The pre-operative indication of hysterectomy for adenomyosis and associated co-morbid conditions were recorded.

RESULTS

A total of 952 patients underwent the hysterectomy at MIMS, Mandya during the study period. The criteria adopted for diagnosis of adenomyosis include the presence of endometrial glands and stroma at a distance of more than one low power field in the myometrium when measured from the lower border of the endometrium (Figure 1). Additional criteria include the presence of cystically dilated glands and intraluminal bleeding residue in the glands (Figure 2). The adenomyosis was present in 158 patients (16.59%). The youngest patient who underwent hysterectomy was of 21 years of age, and the oldest patient was of 80 years of age. The mean age of the patients who underwent hysterectomy was 50.5 years. The majority (136 patients, 86.07%) of the patients with adenomyosis were in the age group of 30-49 years. Among these patients, 42 patients (26.58%) were in the age group

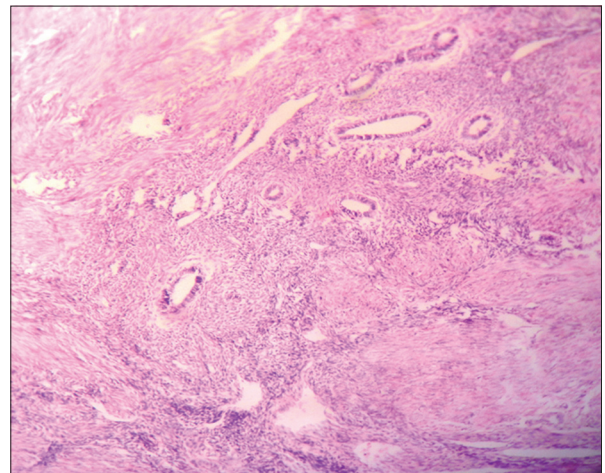


Figure 1: Photomicrograph is showing many endometrial glands and stroma lying deep in the myometrium, (H and E stain x4)

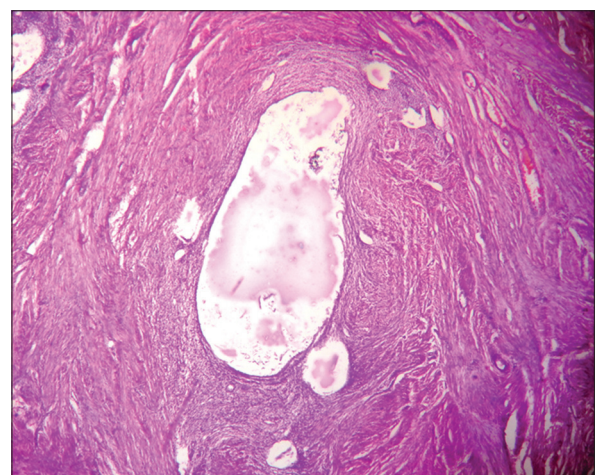


Figure 2: Photomicrograph showing endometrium with cystically dilated glands surrounded by hypertrophic smooth muscle bundles in the myometrium, (H and E stain x4)

of 31-40 years and 94 patients (59.49%) were in the age group of 41-50 years. Only 5 (3.16%) patients were in the age group of 21-30 years and 17 (10.75%) patients were in the age group of 51-80 years (Table 1).

Out of 158 patients, 78 (49.36%) patients had one or more associated co-morbid conditions. About 72 patients were associated with a single co-morbid condition. Among these patients 52 patients had associated leiomyoma of uterus, 5 patients had associated endometrial atrophy, 7 patients had associated endometrial hyperplasia without atypia, 2 patients had associated adenomatous polyp of endometrium, 2 patients had associated serous cystadenoma of ovary, 1 patient had associated mucinous cystadenoma of ovary, 1 patient had associated torsion of benign ovarian cyst, 1 patient had associated mature cystic teratoma of ovary, and one patient had associated cervical intraepithelial neoplasia (CIN) Grade III changes in the cervix. 7 patients of adenomyosis were associated with multiple co-morbid conditions. They include 1 patient with endometrial hyperplasia with atypia, leiomyoma of uterus, and serous cystadenoma of ovary; 1 patient with leiomyoma of uterus and endometriosis of ovary; 1 patient with CIN Grade III of cervix and adenomatous polyp of uterus; 2 patients with endometrial hyperplasia without atypia and leiomyoma of uterus; and 2 patients with leiomyoma and adenomatous polyp of uterus.

The risk of adenomyosis was high in women who complained of heavy menstrual flow in comparison with those patients who were reported to have normal menstrual flow and in patients who did not undergo dilatation and curettage. Likewise, patients who complained of dysmenorrhea and intermenstrual pelvic pain had increased the risk of adenomyosis. Most of the patients 149 (94.29%) were multiparous, and the majority of the patients were of parity 2 and 3. So, adenomyosis was more common among multiparous women. The pre-operative clinical diagnosis was dysfunctional uterine bleeding in 380 patients (39.91%), fibroid in 249 patients (26.15%), ovarian tumor in 41 patients (4.30%), utero-vaginal prolapse in 161 patients (16.91%), and post-menopausal bleeding in 121 patients (12.71%). Age of menarche, menopausal status, normal menstrual flow, and dyspareunia had no correlation with adenomyosis.

Table 1: Age-wise distribution of patients

Age in years	Numbers	Percentage
21-30	05	3.16
31-40	42	26.58
41-50	94	59.49
51-60	11	6.96
61-70	05	3.16
71-80	01	0.63

DISCUSSION

The true prevalence of adenomyosis is unknown but various factors such as genetic factor, hyperestrogenic state, increased the intrauterine pressure of pregnancy in parous women, and prior uterine surgery are proposed as possible etiological factors. In the present study of 952 women who had undergone hysterectomy, adenomyosis was seen in 158 patients (16.59%). Similar prevalence was reported in the study conducted by Shaikh (20.6%), Anwar Ali (20.6%), Sharqill *et al.* (26%), and Vavilis (24.9%). In our study, a total number of 136 patients in the age group of 31-50 years (89.47%) showed adenomyosis. Similar prevalence of adenomyosis for the age group of 31-50 years was reported in the studies by Anwar Ali (90%) and Sabin (95.5%). In our study, only 5 patients (3.16 %) were in the age group 21-30 years. Similar prevalence was reported by Sabin (2%) and Anwar Ali (1.6%) for these age groups. Our study also had adenomyosis in one patient (0.63%) between the age group of 71-80 years, 5 patients (3.16%) between the age group of 61-70 years, and 11 patients (6.96%) between the age group of 51-60 years.

In our study, 110 (69.60%) patients suffered from menorrhagia, 105 (66.45%) patients suffered from dysmenorrhea, 26 (16.45%) patients suffered from utero-vaginal prolapsed, and 7 (4.43%) patients suffered from post-menopausal bleeding (Table 2). In the study by Kheisat, 64% of patients suffered from dysmenorrhea and 3.92% of patients suffered from post-menopausal bleeding. In the study by Arunachalam *et al.*, 70.4% of patients suffered from menorrhagia, 18.4% of patients had utero-vaginal prolapse, and 2.8% of patients had post-menopausal bleeding.

In our study, 94.29% of patients with adenomyosis were multiparous women (Table 3). Similar study by Kheisat showed 96% parity of more than 3. Similar findings were observed in the study by Arunachalam *et al.* This fact favored the hypothesis that increased intrauterine pressure and invasive nature of trophoblasts in pregnancy probably facilitated implantation of endometrial tissue into the myometrium.

The pre-operative diagnosis of adenomyosis based on clinical signs and symptoms is very low. The observation by Reinhold showed the pre-operative clinical diagnosis of adenomyosis in 2.6-26% patients, and the study by Arunachalam *et al.* showed 21.2%. Similarly, in our study also pre-operative clinical diagnosis of adenomyosis was 18.4% and was made in the absence of a definite pre-operative diagnosis of uterine fibroid, utero-vaginal prolapse, or ovarian pathology in patients who presented with dysfunctional uterine bleeding, intermenstrual pelvic pain, etc.

Table 2: The symptoms in adenomyosis (overlap of symptoms)

Symptoms	No. of patients	Percentage
Menorrhagia	110	69.60
Dysmenorrhea	105	66.45
Metrorrhagia	52	32.90
Utero-vaginal prolapse	26	16.45
Post-menopausal bleeding	7	4.43
Intermenstrual pelvic pain	6	3.79
Dyspareunia	4	2.53

Table 3: Parity in patients with adenomyosis

Parity	No. of patients	Percentage
0	2	1.26
1	7	4.43
2	59	37.34
3	71	44.93
4	12	7.59
≥5	7	4.43

In our study, patients with adenomyosis had coexisting morbidities like fibroid (26.15%). Similar findings were observed in the studies by Gerson Weiss *et al.*; Shaikh *et al.* and Vavilis *et al.*

CONCLUSION

The prevalence of adenomyosis in hysterectomy patients was found to be 16.59% in our study. It was the most common seen in the age group of 31-50 years. It was also very common in multiparous women with a parity of more

than 2. The presenting symptoms of adenomyosis include menorrhagia, dysmenorrhea, metrorrhagia, intermenstrual pelvic pain, post-menopausal bleeding, and dyspareunia. Hence, clinical diagnosis of adenomyosis should be considered in patients presenting with these symptoms without any definitive evidence of uterine fibroid, utero-vaginal prolapse, or ovarian mass.

REFERENCES

1. Arunachalam B, Manivasakan J. A clinico – Pathological study of adenomyosis. J Clin Diagn Res 2012;6:428-30.
2. Brucker SY, Huebner M, Wallwiener M, Stewart EA, Ebersoll S, Schoenfish B, *et al.* Clinical characteristics indicating adenomyosis coexisting with leiomyomas: A retrospective, questionnaire-based study. Fertil Steril 2014;101:237-241.e1.
3. Parazzini F, Vercellini P, Panazza S, Chatenoud L, Oldani S, Crosignani PG. Risk factors for adenomyosis. Hum Reprod 1997;12:1275-9.
4. Reinhold C, Tafazoli F, Wang L. Imaging features of adenomyosis. Hum Reprod Update 1998;4:337-49.
5. Vavilis D, Agorastos T, Tzafetas J, Loufopoulos A, Vakiani M, Constantinidis T, *et al.* Adenomyosis at hysterectomy: Prevalence and relationship to operative findings and reproductive and menstrual factors. Clin Exp Obstet Gynecol 1997;24:36-8.
6. Bird CC, McElin TW, Manalo-Estrella P. The elusive adenomyosis of the uterus – revisited. Am J Obstet Gynecol 1972;112:583-93.
7. Bergholt T, Eriksen L, Berendt N, Jacobsen M, Hertz JB. Prevalence and risk factors of adenomyosis at hysterectomy. Hum Reprod 2001;16:2418-21.
8. Levgur M, Abadi MA, Tucker A. Adenomyosis: Symptoms, histology, and pregnancy terminations. Obstet Gynecol 2000;95:688-91.
9. Cohen I, Beyth Y, Shapira J, Tepper R, Fishman A, Cordoba M, *et al.* High frequency of adenomyosis in postmenopausal breast cancer patients treated with tamoxifen. Gynecol Obstet Invest 1997;44:200-5.
10. Thomas JS Jr, Clark JF. Adenomyosis: A retrospective view. J Natl Med Assoc 1989;81:969-72.
11. Azziz R. Adenomyosis: Current perspectives. Obstet Gynecol Clin North Am 1989;16:221-35.

How to cite this article: Siddegowda MS, Manjunath MR, Shivakumar S. Occurrence of Adenomyosis in Hysterectomy Specimen and its Clinical Correlation in a Tertiary Care Hospital in Mandya, Karnataka, India. Int J Sci Stud 2015;3(6):61-64.

Source of Support: Nil, **Conflict of Interest:** None declared.