

# Otological Assessment in Basal Skull Fractures: An Observational Study

Amit Kumar<sup>1</sup>,  
S Nizamuddin<sup>2</sup>,  
Hari Gupta<sup>2</sup>,  
S K Jain<sup>3</sup>

<sup>1</sup>Assistant Professor, Department of ENT, Teerthanker Mahaveer Medical College & Research Centre, Moradabad, Uttar Pradesh, India, <sup>2</sup>Associate Professor, Department of ENT, Teerthanker Mahaveer Medical College & Research Centre, Moradabad, Uttar Pradesh, India, <sup>3</sup>Professor, Department of Anatomy, Teerthanker Mahaveer Medical College & Research Centre, Moradabad, Uttar Pradesh, India

**Corresponding Author:** Dr. S.K Jain, Department of Anatomy, Teerthanker Mahaveer Medical College & Research Centre, Moradabad, Uttar Pradesh, India. Phone: +91-9997168754. E-mail: drskjain2005@rediffmail.com

## Abstract

**Introduction:** Motor vehicle accidents and other road traffic accidents are common causes of skull base injuries. In skull base injury temporal bone involvement is a necessary phenomenon, which based on the type and impact of force leads to a different type of otological complications. The aim of this study is to evaluate and treat those otological complications.

**Materials and Methods:** A total of 40 cases of skull base fractures were included in this study. Before including in the study otolaryngological examination was made by the authors of this study, and Institutional Research and Ethical Committee approval was also taken. A careful history and examination (both clinical and radiological) was done to assess the type and extent of complications. In the case of life-threatening complications, immediate surgery as required was performed.

**Results:** In fractures of skull base occipital bone was most commonly involved (48%) and frontal bone the least (8%). Temporal bone involvement was seen in 22% of cases. Otorrhoea (34/40) and hearing loss (18/40) were the most common complications observed.

**Conclusion:** We concluded the study with the fact, that temporal bone injury is the usual phenomenon associated with basal fractures of the skull and before going to surgical treatment immediately, except in life-threatening cases, we should wait for some time as most of the complications resolve within a specific period of time.

**Keywords:** Accident, Facial nerve, Skull base, Temporal bone

## INTRODUCTION

Anatomical knowledge of base of the skull is of prime importance in understanding the complications that arise from temporal bone fractures. There are many important intracranial structures it-self are present in the petrous part of the temporal bone. Knowledge of these vital structures is of utmost importance to otolaryngologist and head and neck surgeons. In India alone approximately 12,000,000 patients are admitted as new cases of head injury whereas in UK, the number is little less.<sup>1</sup>

It has been noted that there is approximately 20% temporal fractures occur secondary to skull injuries, with more chances of unilateral fractures when compared to bilateral.<sup>2</sup>

On the basis of direct of impact temporal bone fractures are categorized into longitudinal and transverse type. In longitudinal type, middle ear components are more involved while in transverse type internal auditory canal is most frequently involved. However, it may also vary with the thrust that occurs at the time of injury.<sup>3</sup>

The force of impact and direction of impact at the time of injury ultimately decides the fate of complications occurring secondary to temporal bone fractures.

## MATERIALS AND METHODS

A total of 40 cases of basal skull fractures who were admitted in the Emergency Department, Teerthanker Mahaveer Medical College and Research Centre, Moradabad, Uttar Pradesh, India were taken for this

study. Patients who were taken for this study were selected on the basis of both, clinical and radiological confirmation. Institutional Ethical and Research Committee approval was taken before starting the study. A careful history was obtained from the attendants of patients, many of which were included on the basis of history alone while others were evaluated by radiological imaging and then included in the study group.

Patient follow-up for inclusion in the study was carried out as under after proper resuscitation.

- a. Examination of head, neck and vertebral column
- b. Evaluation of associated injuries
- c. Any history or on examination blood from an external ear (Hemotympanum)
- d. Accumulation of blood around eyes.

Radiological examination of basal fractures of the skull done by high-resolution imaging modality.

## RESULTS

The patients of all age group from school going to near 90 years were taken for the study. However, some older patients and their relative were not confirmed about the exact age. There were 12 females, and 28 males were included in the study. In basal fractures of skull most common bone involved was occipital 48% and least was in frontal 8%. Temporal bone injury was present in 22% of cases. As evaluated at the time of examination following sign and symptoms could be noted in these patients. These were evaluated and shown in Table 1 and Figure 1.

## DISCUSSION

Fractures involving base of the skull are life threatening.<sup>4</sup> They vary from hearing loss, hemotympanum, vertigo, facial nerve injuries etc.<sup>2,3,5-7</sup> Temporal bone fractures are associated with hearing loss, the degree of which is related to direction and force of the injury. If impact of injury is transverse, it leads to sensorineural loss, and if longitudinal it leads to conductive type.<sup>8</sup> In our study, we noted that 18 out of 40 patients suffered conductive type of hearing loss. However, in a study conducted by,<sup>9</sup> there was more sensorineural deafness, which may cause due to different force of and direction of impact. We found that about 76% recovered from conductive type of hearing loss in next 6 months, due to recovery of intracranial pathways. The patients who were not able to recover from deafness were provided hearing aid. In this study 25% patients suffered cerebrospinal fluid (CSF) rhinorrhea, they were put on antibiotics. Most of the patients recovered with

the use of antibiotics except three patients who developed meningitis as a sequel to it. Facial nerve injury occurred only 1 out of 40 patients in our study, but in a study conducted by<sup>10</sup> facial nerve injuries occurred to the extent of 4.2%. According to (Chang and Cass, 1999) most facial nerve injuries occur due to intra-neural hematoma.<sup>11</sup> In our study, 2 (5%) patients suffered carotid injury, the results of our study are very similar to that performed by<sup>12</sup> CSF rhinorrhea occurred in about 25% of cases in this study. Otic capsule injury is one of the causative factor for this.<sup>13</sup>

## CONCLUSION

Temporal bone involvement is usual in basal skull fractures. Temporal bone involvement accentuates various ontological complications, based on the direction and impact of force leading to longitudinal and transverse type of temporal bone fractures. These fractures associated complications require surgical intervention. Evaluation of surgical intervention depends on the fact, that whether this complication requires urgent intervention (life-threatening) or it may be taken at a later stage (waiting for complication to resolve it-self like facial nerve injury) etc. We as the authors of this study recommend complete clinical and radiological investigation before making your decision for going immediate surgery or delaying it for some time.

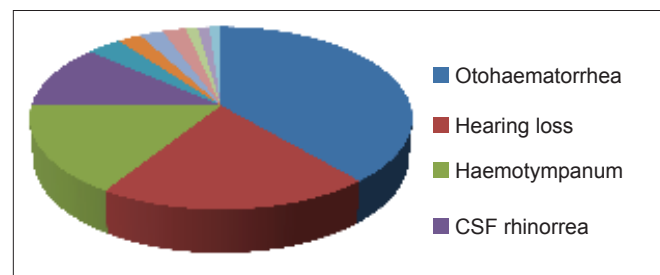


Figure 1: Otological complications in temporal bone fracture in descending order

Table 1: Otological complications in temporal bone fracture in descending order

Otological complications in descending order	Number of patients
Otohemorrhage	34
Hearing loss	18
Hemotympanum	14
CSF rhinorrhea	10
Meningitis ( late occurrence)	3
Vertigo	2
Chorda tympani injury	2
Carotid injury	2
Facial nerve palsy	1
Tinnitus	1
Cholesteatoma (late occurrence)	1

CSF: Cerebrospinal fluid

## REFERENCES

1. Head injuries in Scottish hospitals. Scottish Head Injury Management Study. *Lancet* 1977;2:696-8.
2. Brodie HA, Thompson TC. Management of complications from 820 temporal bone fractures. *Am J Otol* 1997;18:188-97.
3. Lee D, Honrado C, Har-El G, Goldsmith A. Pediatric temporal bone fractures. *Laryngoscope* 1998;108:816-21.
4. Johnson F, Semaan MT, Megerian CA. Temporal bone fracture: Evaluation and management in the modern era. *Otolaryngol Clin North Am* 2008;41:597-618, x.
5. Ort S, Beus K, Isaacson J. Pediatric temporal bone fractures in a rural population. *Otolaryngol Head Neck Surg* 2004;131:433-7.
6. Zimmerman WD, Ganzel TM, Windmill IM, Nazar GB, Phillips M. Peripheral hearing loss following head trauma in children. *Laryngoscope* 1993;103:87-91.
7. Kim SH, Kazahaya K, Handler SD. Traumatic perilymphatic fistulas in children: Etiology, diagnosis and management. *Int J Pediatr Otorhinolaryngol* 2001;60:147-53.
8. Lambert PR, Brackmann DE. Facial paralysis in longitudinal temporal bone fractures: A review of 26 cases. *Laryngoscope* 1984;94:1022-6.
9. Griffiths MV. The incidence of auditory and vestibular concussion following minor head injury. *J Laryngol Otol* 1979;93:253-65.
10. Coker NJ, Kendall KA, Jenkins HA, Alford BR. Traumatic intratemporal facial nerve injury: Management rationale for preservation of function. *Otolaryngol Head Neck Surg* 1987;97:262-9.
11. Chang CY, Cass SP. Management of facial nerve injury due to temporal bone trauma. *Am J Otol* 1999;20:96-114.
12. Dempewolf R, Gubbels S, Hansen MR. Acute radiographic workup of blunt temporal bone trauma: Maxillofacial versus temporal bone CT. *Laryngoscope* 2009;119:442-8.
13. Savva A, Taylor MJ, Beatty CW. Management of cerebrospinal fluid leaks involving the temporal bone: Report on 92 patients. *Laryngoscope* 2003;113:50-6.

**How to cite this article:** Kumar A, Nizamuddin, Gupta H, Jain SK. Otological Assessment in Basal Skull Fractures: An Observational Study. *Int J Sci Stud* 2014;2(6):101-103.

**Source of Support:** Nil, **Conflict of Interest:** None declared.