

Anatomical Variations of the Osteomeatal Complex as a Cause of Chronic Sinusitis and Correlation with Surgical Results Following Functional Endoscopic Sinus Surgery

P Venkateswaran¹, B Muthukumar¹, Heber Anandan²

¹Assistant Professor, Department of Otorhinolaryngology, Government Rajaji Hospital and Madurai Medical College, Madurai, Tamil Nadu, India, ²Senior Clinical Scientist, Department of Clinical Research, Dr. Agarwal's Healthcare Limited, Tirunelveli, Tamil Nadu, India

Abstract

Introduction: Chronic sinusitis is the most common disease for which consultation of otorhinolaryngologist is sought. The approach to patients with chronic rhinosinusitis is endoscopic surgery which aims at removing the obstruction of the main drainage pathway. The osteomeatal complex (OMC)-based essentially on the concept that such obstruction perpetuates the sinus disease.

Aim: To study the anatomical variations of OMC in chronic sinusitis patients.

Materials and Methods: Patients with chronic sinusitis with anatomical variations were randomly selected from our outpatients department. Patients with the evidence of chronic sinusitis were treated with functional endoscopic sinus surgery. They were followed for 3 months. The patients were assessed every 2 weeks by questioning them for reduction of symptoms.

Results: The most common anatomical variation on computed tomography scan was deviated nasal septum in 62% patients, concha bullosa was found in 38% patients, while medialized uncinate narrowing OMC was seen in 30% patients, enlarged bulla was found in 12% patients, Haller cells were found in 4% patients, and agger cells were found in 2%.

Conclusion: Deviated nasal septum was the most common anatomical variation encountered in our study followed by concha bullosa.

Key words: Chronic sinusitis, Osteomeatal complex, Paranasal sinuses

INTRODUCTION

Chronic rhinosinusitis (CRS) is the most common disease for which consultation of otorhinolaryngologist is sought. The approach to patients with CRS has changed after Messerklinger published the first comprehensive account of technique of nasal endoscopy and its application to the diagnosis and treatment of sinonasal diseases.^{1,2} The endoscopic surgery aims at removing the obstruction of the

main drainage pathway - in the osteomeatal complex (OMC)-based essentially on the concept that such obstruction perpetuates the sinus disease.³ The key underlying concept behind minimally invasive functional endoscopic sinus surgery (FESS) is the OMC – the small compartment located in the region between the middle turbinate and the lateral nasal wall in the middle meatus – represents the region for drainage of anterior ethmoid, maxillary, and frontal sinuses.⁴ Obstruction of OMC causes a vicious cycle of events that lead to sinusitis. Its obstruction leads to mucosal congestion that decreases airflow and leads to further obstruction.

The role of anatomical variants in the sinusitis genesis is controversial. Theoretically, these variants could shift and compress OMC components, determining an obstruction to the paranasal sinuses (PNS) mucus drainage. Researchers

Access this article online



www.ijss-sn.com

Month of Submission : 07-2017
Month of Peer Review : 08-2017
Month of Acceptance : 09-2017
Month of Publishing : 09-2017

Corresponding Author: Dr. B Muthukumar, Department of Otorhinolaryngology, Government Rajaji Hospital and Madurai Medical College, Madurai, Tamil Nadu, India. Phone: +91-9751768983. E-mail: dr.bmkbbs@gmail.com

on this theme consider that, if anatomical variants really predispose to sinusitis, one should expect that these variants were more frequently found at computed tomography (CT) in patients with sinus disease (symptomatic) than in the general population (asymptomatic).⁵⁻⁷

Aim

The aim of the study was to study the anatomical variations of an OMC in chronic sinusitis patients and to study the correlation of anatomical variations of an OMC with chronic sinusitis by relief of symptoms after correction by FESS.

MATERIALS AND METHODS

Prospective study of patients with chronic sinusitis who attended the Department of Ear, Nose, and Throat at Kilpauk Medical College Hospital. Patients with chronic sinusitis with anatomical variations were randomly selected from our outpatients department. The patients selected were subjected to diagnostic nasal endoscopy (DNE) and CT scans of PNS. Patients with evidence of chronic sinusitis were treated with FESS. They were followed for 3 months. The patients were assessed every 2 weeks by questioning them for reduction of symptoms.

Inclusion Criteria

Age 18–50 years, clinical and radiological evidence of OMC narrowing, patients with chronic sinusitis without other comorbid condition.

Exclusion Criteria

Patients with sinonasal polyposis, malignant condition of nose, patients with other medical disorder were excluded from the study. About 50 patients, who met the above criteria, were selected for the study. All these patients underwent DNE and CT-PNS.

RESULTS

Of the total 50 patients, 30 were male and 20 were female, in the age group of 18-40 years. 40% of the patients were in the age group of 18-25 years, 30% were in the age group of 26-30 years, 14% were in the age group of 31-35 years, and 16% were in the age group of 36-40 years. 76% cases belonged to the lower socioeconomic group, 30 cases belonged to middle socioeconomic group. Of the 50 cases, 36% cases were from the rural population and 64% cases from the urban population. In our study, DNE was done for all patients, 62% patients had septal deviation which was the most common anatomical variant, 52% had enlarged middle turbinate, 38% had medialized uncinate, 18% had enlarged bulla, and 28% had paradoxical middle turbinate (Figure 1). Accessory ostium which is one of the signs of

chronic sinusitis was found in 15% patients. All patients had discharge in the middle meatus while the discharge was mucopurulent in 50% of the patients; it was purulent in 28% patients and mucoid in 22% patients. CT scan of PNS showed the following variations the majority of cases had Grade I disease 54%, i.e., minimal disease limited to OMC followed by Grade II - 26%, Grade III - 14%, and Grade IV - 6% (Figure 2). The most common anatomical variation on CT scan was deviated nasal septum in 62% patients, concha bullosa was found in 38% patients, while medialized uncinate narrowing OMC was seen in 30% patients, enlarged bulla was found in 12% patients, Haller cells were found in 4% patients and agger cells were found in 2% (Figure 3). Out of the 50 patients, 44 patients (88%) had nasal obstruction, 40 patients (80%) had headache, 39 patients (78%) had post-nasal discharge, and 3 patients had loss of smell (Figure 4). All the patients had anatomical variations and signs strongly suggestive of chronic sinusitis on DNE and CT scan PNS. The patients underwent FESS by Messerklinger technique for the treatment of chronic sinusitis (Figure 5). Following clearance of sinusitis, improvement of symptoms was assessed. Out of the 50 patients, 96% showed good improvement while 2% patients showed partial improvement and 2% showed no improvement at all. Since 96% of the patients, in the study who came for the symptoms of chronic sinusitis, with variations on CT-PNS and signs of sinusitis and anatomical variations on DNE showed improvement following surgical correction, it shows that there is a strong correlation between anatomical variations of OMC and chronic sinusitis (Figure 6). The detailed anatomy of OMC as displayed by CT scan, acts as a roadmap for surgery, before endoscopic sinus surgery. Finally, since 96% of patients showed improvement after surgical correction, it is to be understood that surgical correction for chronic sinusitis with OMC variations has an important role in relieving the patients' symptoms and diseases.

DISCUSSION

The surgical management of chronic sinusitis has evolved over the years. External facial incisions, extensive nasal packing, and prolonged hospital stays have been replaced by minimally invasive surgery. This involves opening the obstructed ostia to provide normal ventilation with preservation of adjacent mucosa.^{8,9} While excellent results have been reported in literature to date,^{10,11} given the close relation of the PNS to important structures such as the orbit and skull base, if complications occur in surgery, they are usually dangerous and harmful.

Liu *et al.*, who observed the prevalence of about 81% anatomical variations in chronic rhinosinusitis cases.¹² Araújo Neto *et al.* reported relatively less anatomical variations 65% in the OMC of the CRS cases.¹³ Pérez-Piñas

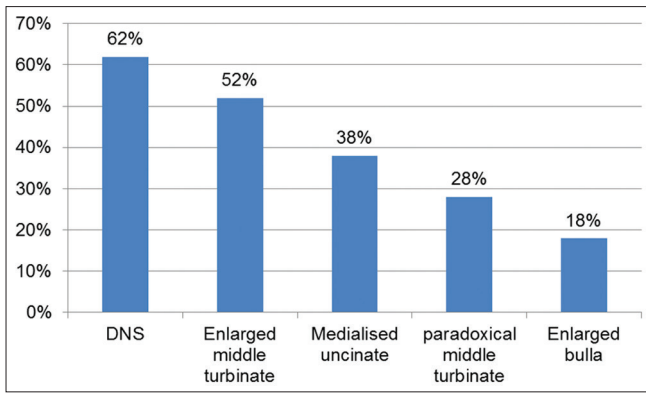


Figure 1: Anatomical variations on diagnostic nasal endoscopy

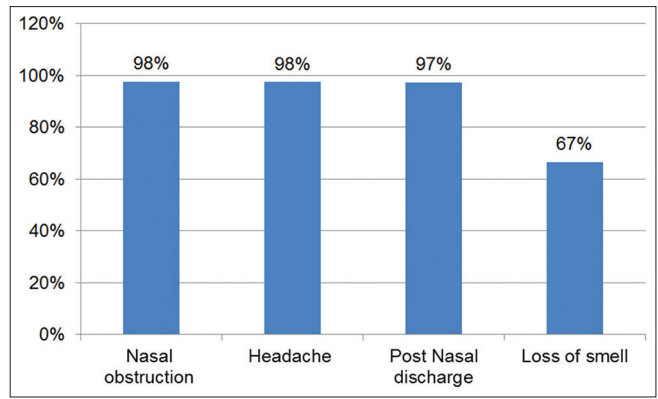


Figure 4: Improvement of symptoms

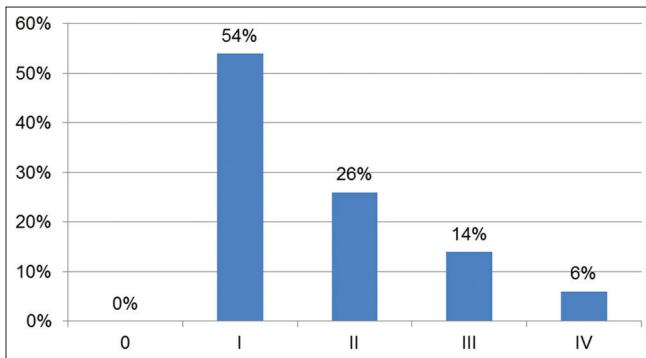


Figure 2: Computed tomography scan paranasal sinus findings

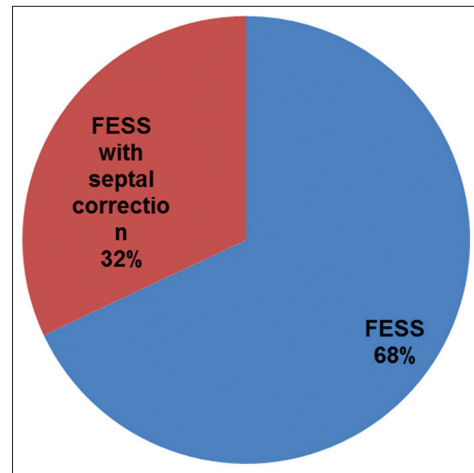


Figure 5: Surgical procedure done for the clearance of sinusitis

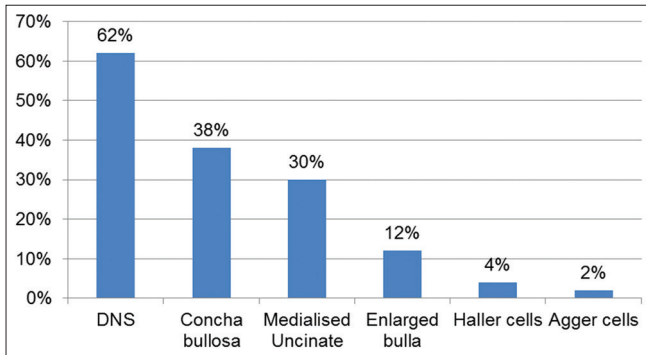


Figure 3: Computed tomography scan paranasal sinuses anatomical variations

et al. also observed the similar prevalence of anatomical variations in the chronic sinusitis cases.¹⁴

Concha bullosa (pneumatized middle turbinate) has been implicated as a possible etiological factor in the causation of recurrent chronic sinusitis. It is due to its negative influence on PNS ventilation and mucociliary clearance in the middle meatus region as quoted by Tonai.¹⁵

Zinreich *et al.*¹⁶ and Zinreich *et al.*¹⁷ described Haller's cells as ethmoid air cells found inferior to the ethmoid bulla adhering to the roof of the maxillary sinus, in continuity with the proximal infundibulum, which formed part of

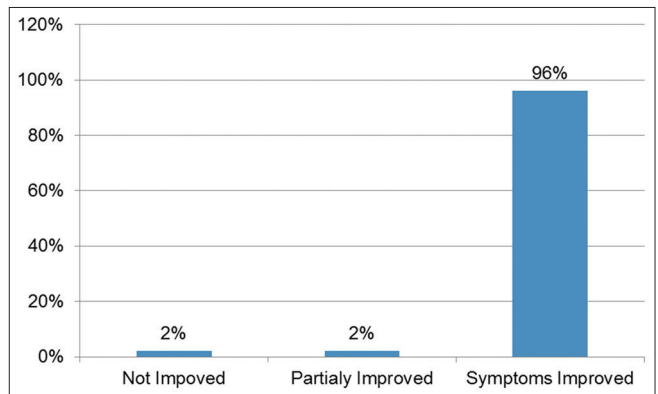


Figure 6: Result of surgery

the lateral wall of the infundibulum. They are considered as ethmoid cells that grow into the floor of orbit and may narrow the adjacent ostium of the maxillary sinus especially if they become infected.¹⁸

CONCLUSION

Deviated nasal septum, concha bullosa medialized uncinate, enlarged bulla, and in order of frequency are

the most common anatomical variants of nose and PNS, predisposing to sinusitis. Anatomical variations lead to narrowing of OMC is a major cause of chronic sinusitis. Clearance of sinusitis by FESS has a favorable effect on improving symptoms particularly major symptoms such as nasal obstruction, headache, post-nasal discharge, and loss of smell. Symptoms are improved following correction of anatomical variations by FESS suggest that there is correlation between the anatomical variation of OMC and chronic sinusitis. FESS has emerged as an effective and reliable procedure for clearance of sinusitis.

REFERENCES

1. Wani AA, Kanotra S, Lateef M, Ahmad R, Qazi SM, Ahmad S. CT scan evaluation of the anatomical variations of the ostiomeatal complex. *Indian J Otolaryngol Head Neck Surg* 2009;61:163-8.
2. Messerklinger W. *Endoscopy of the Nose*. Baltimore, MD: Urban & Schwarzenberg; 1978.
3. Stammberger HR, Kennedy DW, Anatomic Terminology Group. Paranasal sinuses: Anatomic terminology and nomenclature. *Ann Otol Rhinol Laryngol Suppl* 1995;167:7-16.
4. Freitas AP, Boasquesvisque EM. Anatomical variants of the ostiomeatal complex: Tomographic findings in 200 patients. *Radiol Bras J* 2008;41:149-54.
5. Samuel SB, Daniel GB. *Diagnosis and Management of Disorders of the Nose and Sinuses*. Available from: http://www.sinustreatmentcenter.com/BOOK/chapter11_0109.pdf. [Last accessed on 2017 Jul 15].
6. Dua K, Chopra H, Khurana AS, Munjal M. CT scan variations in chronic sinusitis. *Indian J Radiol Imag* 2005;15:315-20.
7. Bolger WE, Butzin CA, Parsons DS. Paranasal sinus bony anatomic variations and mucosal abnormalities: CT analysis for endoscopic sinus surgery. *Laryngoscope* 1991;101:56-64.
8. Schaefer SD, Manning S, Close LG. Endoscopic paranasal sinus surgery: Indications and considerations. *Laryngoscope* 1989;99:1-5.
9. Kennedy DW, Senior BA. Endoscopic sinus surgery. A review. *Otolaryngol Clin North Am* 1997;30:313-30.
10. Salhab M, Matai V, Salam MA. The impact of functional endoscopic sinus surgery on health status. *Rhinology* 2004;42:98-102.
11. Damm M, Quante G, Jungehuelsing M, Stennert E. Impact of functional endoscopic sinus surgery on symptoms and quality of life in chronic rhinosinusitis. *Laryngoscope* 2002;112:310-5.
12. Liu X, Zhan G, Xu G. Anatomic variations of osteomeatal complex and correlation with chronic sinusitis: CT evaluation. *Zhonghua Er Bi Yan Hou Ke Za Zhi* 1999;34:143-6.
13. Araújo Neto SA, Leite Martins PS, Souza AS, Baracat EC, Nanni L. The role of osteomeatal complex anatomical variants in chronic rhinosinusitis. *Radiol Bras* 2004;39:227-32.
14. Pérez-Piñas, Sabaté J, Carmona A, Catalina-Herrera CJ, Jiménez-Castellanos J. Anatomical variations in the human paranasal sinus region studied by CT. *J Anat* 2000;197:221-7.
15. Tonai A, Baba S. Anatomic variations of the bone in sinonasal CT. *Acta Otolaryngol Suppl* 1996;525:9-13.
16. Zinreich SJ, Kennedy DW, Rosenbaum AE, Gayler BW, Kumar AJ, Stammberger H. Paranasal sinuses: CT imaging requirements for endoscopic surgery. *Radiology* 1987;163:769-75.
17. Zinreich SJ, Kennedy DW, Gayler BW. Computer tomography of nasal cavity and paranasal sinuses: An evaluation of anatomy for endoscopic sinus surgery. *Clear Images* 1988;1:2-10.
18. Llyod GA, Lund VJ, Scadding GK. CT of the paranasal sinuses and functional endoscopic surgery: A critical analysis of 100 symptomatic patients. *Laryngol Otol* 1991;105:181-5.

How to cite this article: Venkateswaran P, Muthukumar B, Anandan H. Anatomical Variations of the Ostiomeatal Complex as a Cause of Chronic Sinusitis and Correlation with Surgical Results Following Functional Endoscopic Sinus Surgery. *Int J Sci Stud* 2017;5(6):198-201.

Source of Support: Nil, **Conflict of Interest:** None declared.